

Herpes simplex virus-2-associated esophagitis in immunocompetent host

Haider A. Naqvi^{1,2,3,4}, Sumanthkumar Bandaru^{1,2,3,4}, Adrien L. Janvier^{3,5}, Muhammad Nadeem Yousaf^{1,2,3,4}

¹Department of Medicine, Medstar Union Memorial Hospital, Baltimore, USA

²Department of Medicine, MedStar Good Samaritan Hospital, Baltimore, USA

³Department of Medicine, Medstar Franklin Square Medical Center, Baltimore, USA

⁴Department of Medicine, MedStar Harbor Hospital, Baltimore, USA

⁵Department of Medicine, MedStar Georgetown University Hospital, Washington, USA

Gastroenterology Rev 2021; 16 (3): 248–251
DOI: <https://doi.org/10.5114/pg.2020.100757>

Address for correspondence: Haider A. Naqvi MD, Department of Medicine, Medstar Union Memorial Hospital, MedStar Good Samaritan Hospital, Medstar Franklin Square Medical Center, Baltimore, MedStar Harbor Hospital, 201 E University Parkway, Baltimore, MD, USA, phone: (929) 434-1759, e-mail: haider.a.naqvi@medstar.net

Herpes esophagitis (HE) is typically caused by herpes simplex virus type 1 (HSV-1), although less frequently, it is caused by HSV type 2 (HSV-2). Most cases of HE occur in immunocompromised hosts, but occasionally immunocompetent patients develop this condition. Thus, HSV-2 esophageal infection in immunocompetent individuals is comparatively rare [1]. Canalejo Castrillero *et al.* performed a review of published HE cases (English and Spanish language) in immunocompetent patients from 1950 to 2009. The HSV type was identified in only 27 out of 56 cases. However, among the identified cases, 96% (26) were due to HSV-1 and only 4% (1) was due to HSV-2 [1]. The overall reported incidence of HE is 1.8% [2]. Common risk factors for HE include a history of HIV, AIDS, malignancy, solid organs transplant, use of steroids, immunosuppressant medications, chemotherapy, and radiation therapy [1, 3–7]. An estimated 10–15% of bone marrow transplant patients and up to 20% of AIDS patients may develop HE [8]. The mode of esophageal infection in immunocompromised individuals is either viral reactivation or new infection, whereas in immunocompetent individuals, new infection is the primary mode [1].

We present a case of HE that is unique because it is due to HSV-2 in an immunocompetent patient who was found to have esophageal lesions, atypical for HSV-2 esophagitis on endoscopic visualization.

A 31-year-old woman with a history of intravenous drug use, anemia, and recent hip fracture repair after a motor vehicle accident presented with a right foot infection. She was admitted and initially treated with antibiotics. The hospital course was complicated by an episode of hematemesis and a decline in hemoglobin

(HGB) from 7 mg/dl on admission to a nadir of 6.1 mg/dl (baseline HGB 10 mg/dl). She only noted some throat discomfort. She had no abdominal pain or tenderness on examination. A fecal occult blood test was positive. For the evaluation of a possible upper gastrointestinal bleed, she underwent esophagogastroduodenoscopy (EGD) which demonstrated an erythematous posterior oropharynx. Upper endoscopy also revealed multiple nonbleeding patches of linear ulcers involving the longitudinal folds of the proximal and distal esophagus (Figure 1). No source of active bleeding from the esophagus, stomach or duodenum was identified. Linear esophageal ulcers were thought to be due to cytomegalovirus (CMV) esophagitis on endoscopic visualization. Multiple biopsies of the esophageal ulcers were taken for diagnostic confirmation and she was empirically started on ganciclovir. Biopsy results revealed squamous epithelium with a viral cytopathic effect consistent with herpes simplex virus (Figure 2). Immunohistochemical staining was positive for HSV-2 and negative for *Helicobacter pylori*, CMV and HSV-1 (Figure 3). Based on the pathology results, ganciclovir was switched to valacyclovir for 2 weeks. A blood test for HIV was negative.

The vast majority of HE patients are immunocompromised men with HSV-1 infections. In fact, HE is three times more common in men as compared to women [4–6]. The reason for this uneven distribution is unknown. Only a handful of HE cases due to HSV-2 have been published (Table I). Our patient reported throat discomfort which may have been part of a prodrome. Many patients do not experience prodromal symptoms such as fever, malaise, pharyngitis or respiratory symptoms [1, 3–6]. She was incidentally found to have esophagitis

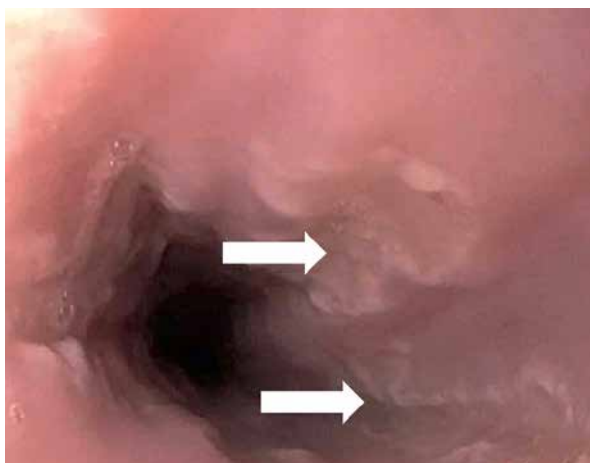


Figure 1. Upper endoscopy showing multiple injuries on the esophageal wall that were white linear ulcerative lesions surrounded by a non-erythematous base (white arrows); these lesions were prominent in the distal third of the esophagus, indicative of an infectious process

during an investigation for possible upper gastrointestinal bleeding. Typical presenting symptoms associated with HE include acute-onset odynophagia, dysphagia, nausea, vomiting, retrosternal chest pain and epigastric pain [1, 3–9]. Odynophagia is the most common presenting symptom in both immunocompetent and immunocompromised patients, accounting for slightly more than 75% of the cases [4].

Globally, HSV-1 is a common cause of orolabial infections, whereas HSV-2 is more frequently associated with genital infections [10]. In patients with HE due to HSV-1, herpes labialis will be present in 20% of cases prior to the onset of odynophagia [3, 5, 6]. Irrespective of the type, HSV from the oral cavity or pharynx is thought to be transmitted to the esophagus, where it invades the esophageal mucosa and results in ulcerative lesions. HSV has a predilection for traumatized esophageal mucosa that may result from gastroesophageal reflux disease or even from endoscopic interventions [1]. The distal esophagus is the predominant location of HE (68.3%); however, any portion of the esophagus and even the stomach can be infected [1, 3–6, 9]. The characteristic findings on endoscopic visualization are multiple, discrete small vesicles [1, 3–7, 9]. The lesions can be divided into two stages based on lesion characteristics [3–5]. In the early stages, small vesicular lesions are usually visualized on EGD; these may eventually slough off and become circumscribed ulcers. In the late stages, necrosis of esophageal mucosa may be seen. Punched out lesions are pathognomonic of HE and likely represent a transitional stage [9]. To confirm the diagnosis, brush border cytology or

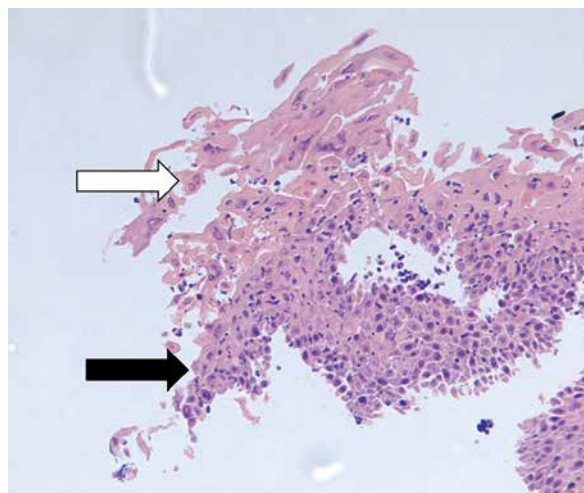


Figure 2. Histopathologic examination of the esophagus showing acute inflammation (black arrow) and ulceration with the presence of multinucleated cells (white arrow) consistent with herpetic infection (hematoxylin-eosin)

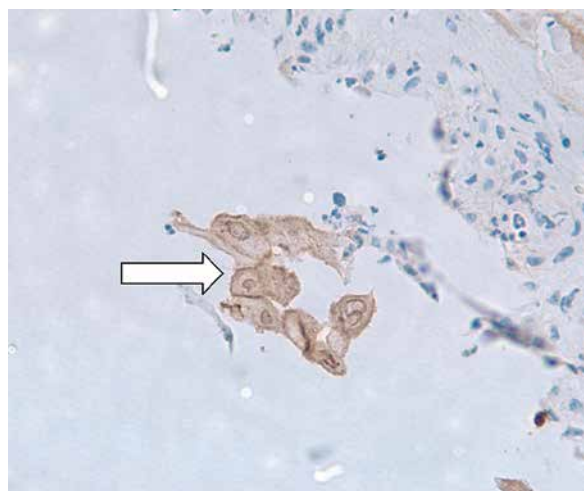


Figure 3. Immunohistostaining highlighting the presence of an HSV-2 viral particle (white arrow) within the esophageal epithelium revealing the infectious etiology surrounded by the acute inflammatory cells

biopsies should be obtained from the ulcer edges [1, 5]. Cowdry inclusion bodies (eosinophilic intranuclear inclusion bodies) and giant multinucleated cells are diagnostic of HSV in only 67% of cases [1, 4, 5, 7]. Although the traditional gold standard test is virus isolation from cell culture, polymerase chain reaction (PCR) of the HSV DNA has the highest sensitivity (92–100%) and specificity (100%) [5, 11]. In our case, confluent linear ulcers were noted on EGD from the oropharynx to the distal esophagus. Tissue samples revealed a viral cytopathic

Table I. Currently reported cases of Herpes simplex virus type 2 esophagitis in immunocompetent hosts

Authors	Study year	Age [years]	Sex	Presenting symptoms	Predisposing risk factors	Endoscopic findings	Treatment
Naqvi <i>et al.</i> (current case)	2020	31	Female	Asymptomatic	None	Linear ulcerative lesions	Oral valacyclovir
Kurosawa <i>et al.</i> [14]	2019	46	Male	Sore throat Fever	Hemophagocytic lymphohistiocytosis	Multiple lesions	IV acyclovir and transitioned to oral valacyclovir for total of 21 days
Gani <i>et al.</i> [12]	2019	29	Female	Odynophagia Fever	Solid organ transplantation	White exudative lesions	IV acyclovir for total of 21 days
Kadayakkara <i>et al.</i> [3]	2016	28	Male	Dysphagia Odynophagia Epigastric pain	N/A	Small ulcers with exudate	IV acyclovir and transitioned to oral valacyclovir for total of 14 days
Hodnette <i>et al.</i> [13]	2014	45	Male	Dysphagia Odynophagia	AIDS	Black esophagus	IV acyclovir and transitioned to oral valacyclovir
Wishingrad [15]	1999	32	Male	Odynophagia Fever Retrosternal pain	N/A	Multiple superficial ulcers	N/A
Wandl-Huinberger <i>et al.</i> [16]	1998	36	Male	Dysphagia	Homosexuality	Multiple small ulcers	N/A

N/A – not available, IV – intravenous.

effect. Given the initial endoscopic appearance, there was a concern for CMV esophagitis. However, immunohistochemistry confirmed an HSV-2 infection and ruled out HSV-1 and CMV.

Only a few of the published HSV-2-associated esophagitis cases presented with dysphagia or odynophagia, unlike most HSV-1 cases (Table I) [3, 12–16]. The majority of reported cases presented in the third to fourth decade of life with male predominance. Organ transplantation is the most common predisposing risk factor for HE, followed by AIDS and hematological malignancies (Table I). Upon endoscopic evaluation, patients were found to have multiple superficial lesions. Complete resolution of lesions with a 2–3-week course of intravenous and oral antiviral treatment was reported.

HE in immunocompetent individuals is a self-limiting disease [1, 4]. In a meta-analysis of 56 immunocompetent patients with HE, 30 patients received no antiviral therapy. Resolution within 2 weeks is reported in the majority of studies [3, 4, 6]. Since there are no randomized controlled trials (RCTs) on the management of HE in immunocompetent patients, it is unclear whether treatment with antiviral medication hastens recovery. However, treatment to avoid severe complications such as upper gastrointestinal hemorrhage or esophageal perforation in high risk patients seems reasonable [4]. In our case, the patient was treated with a 2-week course of valacyclovir, resulting in complete resolution of her lesions.

In conclusion, Herpes esophagitis is usually due to HSV-1 and typically occurs in immunocompromised individuals. However, esophagitis due to HSV-2 in immunocompetent individuals does occur and patients may present without classic odynophagia or retrosternal chest pain. A sore throat in the proper clinical context could be a clue. Thus, a high index of clinical suspicion is required to diagnose HE in immunocompetent patients. Upper endoscopy with biopsy of esophageal mucosal lesions is an essential modality for the diagnosis. Immunohistochemistry and PCR from tissue samples are diagnostic tests with a high sensitivity and specificity. Although RCTs are lacking, it seems reasonable to treat immunocompetent HE patients with a course of antiviral medication to reduce the incidence of complications.

Conflict of interest

The authors declare no conflict of interest.

References

1. Canalejo Castrillero E, Garcia Duran F, Cabello N, et al. Herpes esophagitis in healthy adults and adolescents: report of 3 cases and review of the literature. *Medicine* 2010; 89: 204-10.
2. Itoh T, Takahashi T, Kusaka K, et al. Herpes simplex esophagitis from 1307 autopsy cases. *J Gastroenterol Hepatol* 2003; 18: 1407-11.
3. Kadayakkara DK, Candelaria A, Kwak YE, et al. Herpes simplex virus-2 esophagitis in a young immunocompetent adult. *Case Rep Gastrointest Med* 2016; 2016: 7603484.

4. Geraci G, Pisello F, Modica G, et al. Herpes simplex esophagitis in immunocompetent host: a case report. *Diagn Ther Endosc* 2009; 2009: 717183.
5. Choudens FCR, Sethi S, Pandya S, et al. Atypical manifestation of herpes esophagitis in an immunocompetent patient: case report and literature review. *World J Clin Infect Dis* 2017; 7: 46-9.
6. Marinho AV, Bonfim VM, de Alencar LR, et al. Herpetic esophagitis in immunocompetent medical student. *Case Rep Infect Dis* 2014; 2014: 930459.
7. Owensby LC, Stammer JL. Esophagitis associated with herpes simplex infection in an immunocompetent host. *Gastroenterology* 1978; 74: 1305-6.
8. Génèreau T, Rozenberg F, Bouchaud O, et al. Herpes esophagitis: a comprehensive review. *Clin Microbiol Infection* 2008; 3: 397-407.
9. Ramanathan J, Rammouni M, Baran J Jr, et al. Herpes simplex virus esophagitis in the immunocompetent host: an overview. *Am J Gastroenterol* 2000; 95: 2171-6.
10. Eymard D, Martin L, Doummar G, et al. Herpes simplex esophagitis in immunocompetent hosts. *Can J Infect Dis* 1997; 8: 351-3.
11. Ullah W, Abdullah HMA, Amjad W, et al. Herpes simplex esophagitis in immunocompetent patients: a rare but easily managed condition. *S D Med* 2019; 72: 344-7.
12. Gani I, Kosuru V, Saleem M, et al. Simultaneous candida albicans and herpes simplex virus type 2 esophagitis in a renal transplant recipient. *BMJ Case Rep* 2019; 12: e230410.
13. Hodnette C, Lamendola O, Banda V. Black esophagus: a case of acute esophageal necrosis secondary to HSV2 infection. *Am J Gastroenterol* 2014; 109: S234-473.
14. Kurosawa S, Sekiya N, Fukushima K, et al. Unusual manifestation of disseminated herpes simplex virus type 2 infection associated with pharyngotonsillitis, esophagitis, and hemophagocytic lymphohistiocytosis without genital involvement. *BMC Infect Dis* 2019; 19: 65.
15. Wishingrad M. Sexually transmitted esophagitis: primary herpes simplex virus type 2 infection in a healthy man. *Gastrointest Endosc* 1999; 50: 845-6.
16. Wandl-Huinberger VI, Pichler W, Lechner G, et al. Ulzeröse Herpes-Simplex-Virus-II Ösophagitis. *Fortschr. Röntgenstr* 1988; 148: 215-6.

Received: 10.09.2020

Accepted: 13.10.2020