



Taibah University

Journal of Taibah University Medical Sciences

www.sciencedirect.com



Case Report

Mycoplasma pneumoniae-associated mucositis syndrome: A rare and clinically challenging disease in a Saudi child



Elham E. Bukhari, MD^{a,*}, Fawzia E. Alotaibi, MD^b, Amani S. Bugshan, MD^a, Hind M. Bakheet, MD^a, Salman M. Binsufayan, MD^c and Muslim M. Alsaadi, MD^d

^a Department of Paediatrics, Infectious Disease Section, Prince Abdullah bin Khalid, Coeliac Disease Research Chair, King Saud University, King Khalid Hospital, King Saud University Medical City, Riyadh, KSA

^b Department of Pathology and Laboratory Medicine, King Saud University, King Saud University Medical City, KSA

^c Department of Paediatrics, Paediatric Pulmonology Section, King Saud University, King Saud University Medical City, KSA

^d Department of Dermatology, King Saud University, King Saud University Medical City, KSA

Received 5 October 2016; revised 3 December 2016; accepted 6 December 2016; Available online 13 January 2017

المخلص

التهاب الأغشية المخاطية الذي تسببه المفضورة الرئوية هو مظهر للعدوى بالمفضورة الرئوية خارج الرئتين، الذي قد يظهر كأضرار مخاطية معزولة (مثل العين، والفم والجهاز الهضمي التناسلي) أو في مزيج من الأضرار المخاطية والجلدية الصغيرة. ويعتبر التهاب الأغشية المخاطية الذي تسببه المفضورة الرئوية مظهرا نادرا يشكل سلسلة لحمايات عديدة الأشكال رئيسية ومتلازمة ستيفن جونسون. نقدم حالة طفل عمره ١٢ عاما حضر بمظاهر سريرية تقليدية لالتهاب الأغشية المخاطية بالمفضورة الرئوية، وكان تفاعل البلمرة المتسلسل للمفضورة الرئوية إيجابيا بقوة. عولج المريض بالعلاجات المضادة للجراثيم وقد تم شفاؤه. يجب على الطبيب أن يكون على دراية بهذه الحالة النادرة ويعالج المرضى وفقا لذلك.

الكلمات المفتاحية: طب الأمراض الجلدية؛ التهاب الغشاء المخاطي؛ المفضورة الرئوية؛ التهاب الجلد؛ متلازمة ستيفن جونسون

Abstract

Mycoplasma pneumoniae-associated mucositis (MPAM) is an extra-pulmonary manifestation of *M. pneumoniae* infection and may present as isolated mucosal lesions

(e.g., ocular, oral, and urogenital) or as a combination of mucosal and minimal cutaneous lesions. MPAM is a rare entity that lies on the spectrum of erythema multiform (EM) major and Stevens–Johnson syndrome (SJS). We present a 12-year-old boy who presented with classical clinical manifestations of MPAM and strongly positive *M. pneumoniae* PCR results. The patient was treated with antimicrobial therapy and had an uneventful recovery. Physicians should be aware of this rare entity and manage patients accordingly.

Keywords: Dermatology; Mucositis; *Mycoplasma pneumoniae*; Skin infection; Steven Johnson

© 2017 The Authors.

Production and hosting by Elsevier Ltd on behalf of Taibah University. This is an open access article under the CC BY-NC-ND license (<http://creativecommons.org/licenses/by-nc-nd/4.0/>).

Introduction

Mycoplasma pneumoniae is an important infectious cause of community-acquired pneumonia in children that is often associated with extrapulmonary complications such as mucocutaneous eruptions, including Stevens–Johnson syndrome (SJS) and toxic epidermal necrolysis (TEN) which are, in most cases, almost exclusively attributed to drugs.¹ However, in the case of *M. pneumoniae* infections, these severe cutaneous reactions may differ from drug-

* Corresponding address: Department of Paediatrics, Infectious Disease Section, Prince Abdullah bin Khalid, Coeliac Disease Research Chair, King Saud University, King Khalid Hospital, King Saud University Medical City, Riyadh, KSA.

E-mail: ebukhari@ksu.edu.sa (E.E. Bukhari)

Peer review under responsibility of Taibah University.



Production and hosting by Elsevier

induced SJS or viral-associated erythema multiforme.² *M. pneumoniae*-associated mucositis exhibits prominent mucositis and sparse cutaneous involvement, although cutaneous involvement varies.³ Here, we present a rare case of SJS associated with *M. pneumoniae* in a Saudi child and review the literature for similar cases.

Case report

A 12-year-old boy with no significant past medical history presented initially with a history of fever, productive cough and shortness of breath for 10 days. A chest radiograph showed infiltration of the left lung (Figure 1). He was diagnosed with atypical pneumonia and given oral Clarithromycin (500 mg, every 8 h) which improved his symptoms. On day 4 of antibiotic treatment, the patient complained of mild eye itching. The next morning, he developed lid swelling with marked erythema in both eyes and whitish eye discharge. He also developed bullae inside the mouth and small pruritic lesions on both palms. Upon examination, he appeared healthy with no respiratory distress or fever (36.5 °C, axillary). His respiratory rate was 24 breaths/min, his blood pressure was 115/70 mmHg, and his SpO₂ was 97%. A mouth examination showed severe oral mucositis with haemorrhagic vesiculobullous eruptions over the buccal mucosa, the soft and hard palate and the tonsillar pillars but not the gingiva (Figure 2). An eye examination revealed bilateral conjunctival injection and pseudomembrane formation (Figure 3). A skin examination showed only one red papule over the trunk. The palms of both hands exhibited target skin lesions (Figure 4). Systemic and chest examinations were normal with neither hepatosplenomegaly nor significant lymphadenopathy. No evidence of any lesion in the genital, anal or perianal area was found upon examination. Laboratory tests, including serology, revealed a white blood cell count of 12.6 K/ μ L and negative findings for mononucleosis, Herpes Simplex Virus (HSV) 1 and 2, and

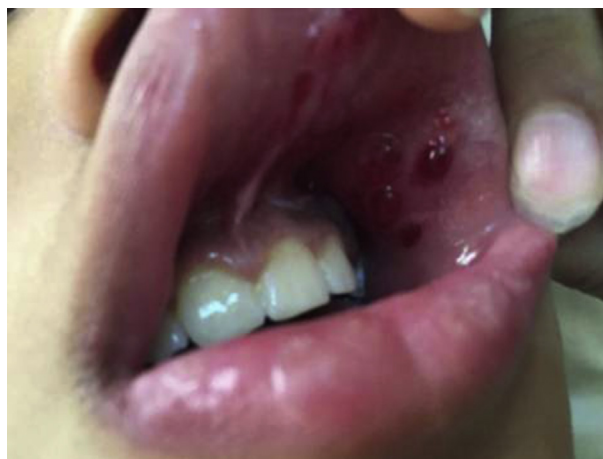

Figure 2: Severe oral mucositis with haemorrhagic vesiculobullous eruptions.

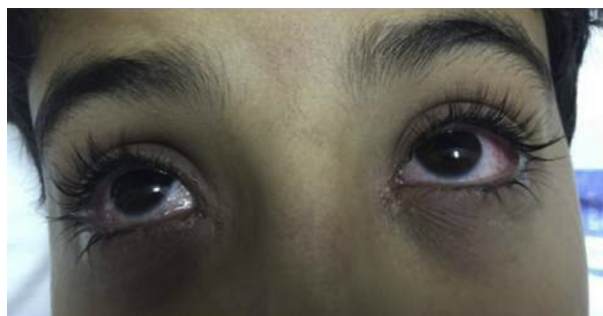

Figure 3: Moderate conjunctivitis in both eyes.

influenza viruses. Serology for *M. pneumoniae* IgM and *M. pneumoniae* PCR were both positive. An enzyme-linked immunosorbent assay (ELISA), also known as an enzyme immunoassay (EIA), is a biochemical technique used mainly in immunology to detect the presence of an antibody or an

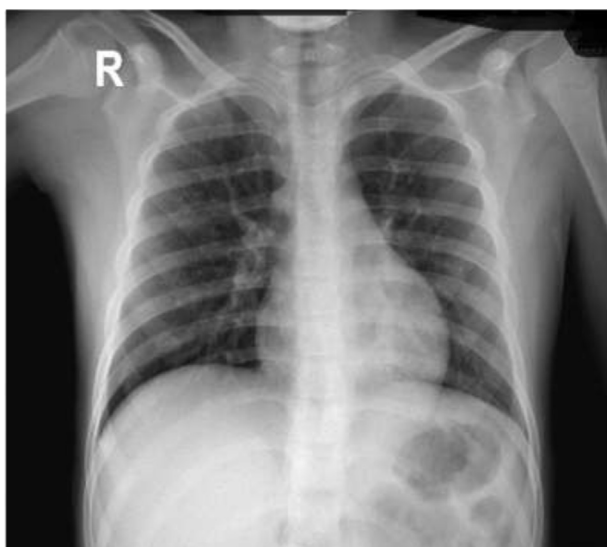


Figure 1: Chest Radiograph showing scattered, fine, bilateral infiltration.

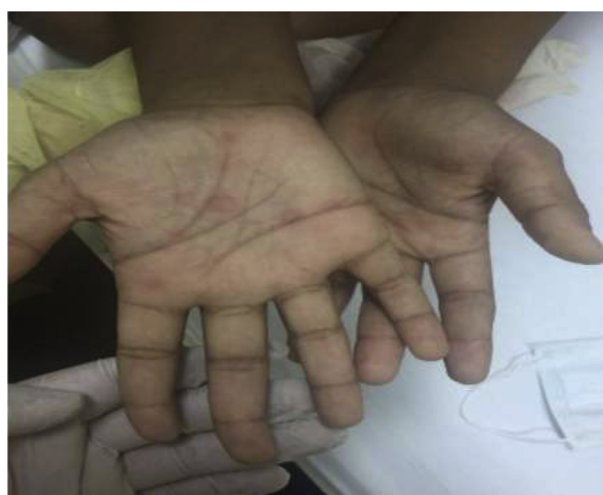

Figure 4: Multiple targetoid skin lesions in the palms of both hands.

antigen in a sample. In an ELISA, an unknown amount of antigen is affixed to a surface, and then a specific antibody is applied over the surface so that it can bind to the antigen. This antibody is linked to an enzyme, and in the final step, a substance that the enzyme can convert to some detectable signal, most commonly a color change in a chemical substrate, is added. PCR was used for detection of the 16S rRNA gene.

The patient was treated with supportive management including intravenous fluids for hydration and analgesics including oral paracetamol (10 ml) for pain if needed, and he was given lubricant ofloxacin eye drops and mouth wash for the buccal lesions. He was discharged within four days of admission in stable condition. Ophthalmological follow-up disclosed healing of his conjunctivitis, and subsequent clinical follow up after two weeks showed complete resolution.

Discussion

M. pneumoniae is a significant cause of community-acquired pneumonia in children. In rare cases, patients may present with extra-pulmonary manifestations of *M. pneumoniae*, such as SJS, and may require hospitalization and, occasionally, intensive care for respiratory failure.³ Most reported cases of SJS and TEN, which are life-threatening conditions, are almost exclusively attributed to drugs.¹ The incidence in children has been reported to be lower than that in adults and has a better outcome.¹ In developed countries, the most common precipitating cause of SJS in children has been reported to be infections, particularly *M. pneumoniae* and HSV. However, in India, drugs have been reported to be the most common trigger.⁴

The literature consists of many reports of mycoplasma induced mucocutaneous skin lesions/rash that were diagnosed based on clinical and/or radiographic evidence of pneumonia, with positive serology tests consisting of either positive cold agglutination or elevated IgM antibodies against *M. pneumoniae*.^{2,5,6} In a systematic review, patients were often young (mean age: 11.9 years) and male (66%). Cutaneous involvement ranged from absent (34%), sparse (47%), or moderate (19%). Oral, ocular, and urogenital mucositis were reported in 94%, 82%, and 63% of cases, respectively.² Four cases were described by Latsch et al. and Ravin et al.^{5,6} of three male and one female patient with genital involvement. Latsch reported two adolescents who presented with severe exudative and ulcerative stomatitis accompanied by conjunctivitis and genital erosions.⁵ Ravin also reported two patients with genital involvement.⁶ All cases were diagnosed by positive Mycoplasma PCR (throat/sputum) and microparticle agglutination assays (IgM, IgA, IgG), and all received Clarithromycin. Patients in other reports were diagnosed only by positive serology.^{7,8} Bressan et al.⁷ reported a case of MPAM in a 9-year-old girl who presented with genital involvement. The patient was diagnosed based on IgM agglutination assays and received intravenous immunoglobulin. Another similar case was reported by Trapp et al.,⁸ who described a 13-year-old boy who presented with mucositis and genital involvement and was diagnosed serologically by the detection of Mycoplasma-specific IgM antibodies. Incomplete Stevens–Johnson syndrome secondary

to atypical pneumonia has been reported.⁹ Our patient showed similar presentations to other reported cases, exhibited prominent mucositis and sparse cutaneous involvement, and had positive sputum PCR results, and his follow up showed complete recovery. Treatment is usually supportive, and specific treatment with immunosuppressive drugs or immunoglobulins did not show a better outcome in most studies and remains controversial.¹⁰ We report this case because paediatricians should be aware of the clinical entity of atypical or incomplete *M. pneumoniae*-associated mucositis, particularly when the patient has a clinical presentation suggestive of prior *M. pneumoniae* infection along with a mild disease course and positive serology and/or PCR results.

Authors' contributions

EEB wrote the manuscript, produced the concept and designed the study. FEA collected the data and the reference material. ASB collected data and shared in manuscript writing. HMB collected data and information. SMB collected data and information. MMA collected data and information.

Conflicts of interests

The authors have no conflict of interest to declare.

Acknowledgements

This work was financially supported by King Saud University through the vice Deanship of Research Chairs, Prince Abdullah Bin Khalid, Coeliac Disease Research Chair.

References

1. Ferrandiz-Pulido C, Garcia-Patos V. A review of causes of Stevens–Johnson syndrome and toxic epidermal necrolysis in children. *Arch Dis Child* 2013; 98: 998–1003.
2. Canavan TN, Mathes EF, Frieden I, Shinkai K. Reply to: “Diagnosing *Mycoplasma pneumoniae*-induced rash and mucositis (MIRM) in the emergency room”. *J Am Acad Dermatol* 2015; 72: 239–245.
3. Mockenhaupt M. The current understanding of Stevens–Johnson syndrome and toxic epidermal necrolysis. *Expert Rev Clin Immunol* 2011; 7(6): 803–813.
4. Manwani NS, Balasubramanian S, Dhanalakshmi K. Stevens Johnson syndrome in association with *Mycoplasma pneumoniae*. *Indian J Pediatr* 2012; 79(8): 1097–1099.
5. Latsch K, Girschick HJ, Abele-Horn M. Stevens-Johnson syndrome without skin lesions: case report. *J Med Microbiol* 2007; 56(Pt 12): 1696–1699.
6. Ravin KA, Rappaport LD, Zuckerbraun NS, Wadowsky RM, Wald ER, Michaels MM. *Mycoplasma pneumoniae* and atypical Stevens-Johnson syndrome: a case series. *Pediatrics* 2007; 119(4): e1002–e1005.
7. Bressan S, Mion T, Andreola B, Bisogno G, Da Dalt L. Severe *Mycoplasma pneumoniae*-associated mucositis treated with immunoglobulins. *Acta Paediatr* 2011; 100(11): e238–e240.
8. Trapp LW, Schrantz SJ, Joseph-Griffin MA, Hageman JR, Waskow SE. A 13-year-old boy with pharyngitis, oral ulcers,

- and dehydration. *Mycoplasma pneumoniae*-associated mucositis. **Pediatr Ann** 2013; 42(4): 148–150.
9. Ramasamy A, Patel C, Conlon C. Incomplete Stevens–Johnson syndrome secondary to atypical pneumonia. **BMJ Case Rep** 2011. <http://dx.doi.org/10.1136/bcr.08.2011.4568>. pii: bcr0820114568.
10. Roland G, Mathias N, Thomas S. Toxic epidermal necrolysis and Stevens-Johnson syndrome: a review. **Crit Care Med** 2011; 39(6): 1521–1532.

How to cite this article: Bukhari EE, Alotaibi FE, Bugshan AS, Bakheet HM, Binsufayan SM, Alsaadi MM. *Mycoplasma pneumoniae*-associated mucositis syndrome: A rare and clinically challenging disease in a Saudi child. *J Taibah Univ Med Sc* 2017;12(4): 356–359.