

*Teaching Point*  
(Section Editor: A. Meyrier)

## A dialysis patient with blurred vision

Charles J. Diskin, Thomas J. Stokes, Linda M. Dansby, Lautrec Radcliff, Thomas B. Carter and Allen Lazenby

HNNT, Auburn University, Suite #3, 2609 Village Professional Drive, Opelika, AL 36801, USA

**Keywords:** complications; haemodialysis; papilloedema; thrombosis; vascular access

### Introduction

Papilloedema is a term that describes a non-inflammatory swelling of the optic nerve head that is now restricted only to patients with increased intracranial pressure. It thus implies a clinical diagnosis in addition to a physical finding while the term optic disc swelling is employed for the mere clinical description. We describe a haemodialysis patient who developed sudden onset of optic disc oedema with a blurred vision that was not associated with increased intracranial pressure and resolved spontaneously.

### Case report

A 36-year-old man of African-American descent with end-stage renal disease who had been on haemodialysis for 11 years with a large well-functioning left forearm AV fistula presented with a 1-day history of blurred vision and headaches. His physical examination revealed papilloedema (+4 diopters) despite a blood pressure of only 120/80 mmHg. Visual fields examination was normal and venous pulsations were present with no haemorrhages on funduscopic examination. The only abnormal findings on physical examination were dilated collateral veins on the left side of his neck. After a brain CT was found to be unremarkable with no sign of increased intracranial pressure, a fistulogram (Figure 1a) revealed that the left brachiocephalic vein was thrombosed just beyond the insertion of the left common jugular vein (striped arrow). Contrast dye revealed that there was retrograde flow through the left common jugular (white arrow, Figure 1b) to the brain, where after crossing the cavernous and intercavernous sinuses, a much-diluted contrast then returned in an antegrade

fashion through the right jugular. Repeated funduscopic examination revealed increased rather than decreased venous pulsations and there were no haemorrhages or exudates.

Thrombolysis of the occluded brachiocephalic vein was impossible to perform percutaneously despite repeated attempts. The headaches were mild and lasted only 2 days. Because of the lack of alternative accesses, the patient refused ligation of his access, and while the cardiothoracic surgeon pondered a bypass, his symptoms and signs resolved. His headaches resolved within a day and the blurred vision within a month. Weekly funduscopic examinations revealed a resolution of the optic disc oedema within weeks with a normal physical examination within 8 months despite the occluded central vein.

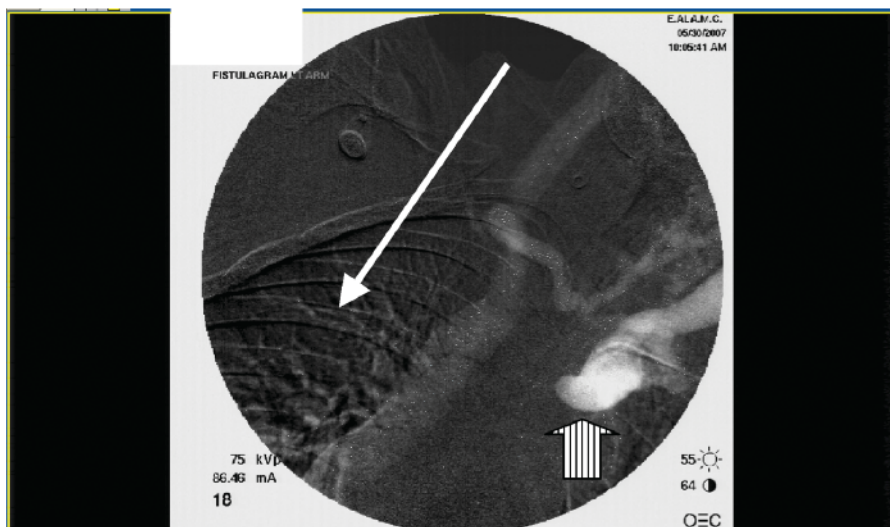
### Discussion

Although optic disc swelling was first associated with intracranial pressure due to intracranial tumours, the term papilloedema was not applied until 1908 and defined to indicate more than two diopters of swelling [1]. While optic disc swelling and papilloedema are indistinguishable funduscopically, papilloedema is now usually reserved for optic disc swelling associated with increased intracranial pressure. The disc is the ophthalmoscopic view of the nerve entrance, which is defined by the sclerochoroidal foramen through which the optic nerve emerges from the eyeball. The papilla consists of the tissues in front of the disc, namely the nerve fibres that have converged from all directions to form the optic nerve. The papilla occupies a larger area than the disc and is subject to both expansion and elevation. The term papilla is thought to date back to 1676 when the examination of post-mortem eyeballs gave the optic nerve a raised appearance, although there is no such prominence in living tissues.

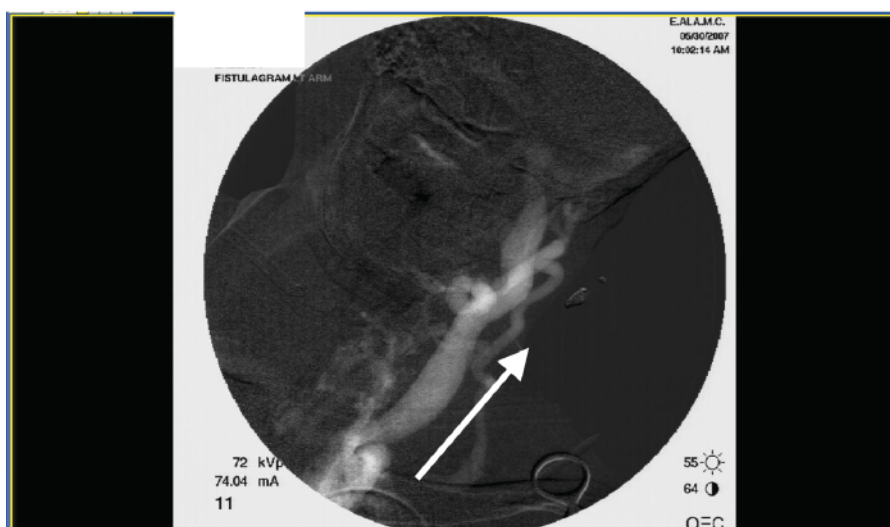Optic disc oedema is the end result of many pathological processes, some that are relatively benign while some that have devastating visual and neurological consequences. Our patient appeared to have the former rather than the latter. It has been reported to occur in chronic obstructive pulmonary disease (COPD) [2], congestive heart failure

*Correspondence and offprint requests to:* Charles J. Diskin, HNNT, Auburn University, Suite #3, 2609 Village Professional Drive, Opelika, AL 36801, USA. Fax: +334-742-0242; E-mail: hndt512@bellsouth.net

(a)



(b)



**Fig. 1.** (a) After passing through the cavernous and intercavernous sinuses, there is now antegrade flow (white arrow) down the right internal jugular. The obstruction is marked at the brachiocephalic vein by a striped arrow. (b) There is retrograde flow (white arrow) up the left internal jugular from the obstruction.

(CHF) and after the ingestion of tetracycline and vitamin A [3]. Clinical clues that may have suggested raised intracranial pressure in our patient included bilaterality and headache [4]; however, the mild headaches that our patient suffered resolved quickly, and the absence of pulsatile tinnitus, bradycardia and hypertension and the presence of venous pulsations were in agreement with the diagnosis of normal intracranial pressures on CT examination.

Monitoring venous pulsation by direct ophthalmoscopy has been regarded as a good indicator of normal intracranial pressure [5]. Although impaired cerebral drainage can result in increased intracranial pressures with papilloedema, the presence of what appeared to be exaggerated venous pulsations in our patient was the first indication that it was retrograde fistula flow producing the papilloedema. One

could not be sure that pulsations in the presence of an arteriovenous fistula might be misleading, but the absence of hyperaemia and retinal haemorrhages, exudates, cotton wool patches and elevated blood pressure continued to confirm the benign aetiology with the absence of increased intracranial pressures [6] in addition to the persistently normal visual fields. More unusual possibilities such as congenital anomalies, like optic disc drusen, tend to be rare in patients of African-American descent, and it was well documented that he had no optic disc swelling on any of his many previous admissions. Papilloedema, due to a reaction to the dialysis procedure itself that spontaneously resolved, has been previously reported [10], but our patient appeared to have optic disc oedema due to retrograde flow through his retinal veins from his haemodialysis fistula. Since the

ophthalmic veins and the cavernous sinuses lack valves to prevent retrograde flow, we hypothesize that papilloedema can result from high flow through an arteriovenous fistula in the presence of the central venous obstruction.

The pathogenesis of disc swelling has long been subject to debate and remains so today. One early theory was that venous engorgement of the distal portion of the optic nerve occurs from increased intracranial pressure due to constriction of the vein that drains the nerve where the vein traverses the intravaginal space and suddenly receives the impact of the increased cerebrospinal fluid pressure [1]. Such a mechanism was reproducible in the laboratory by obstruction of blood flow. More recently papilloedema has been reported with central retinal vein occlusion [7] and has even been reported unilaterally due to vasospasm (optic vein migraine) after vaccination [8]; however, compression of the central retinal vein in experimental models does not result in disc oedema [9]. The other general mechanisms of papilloedema that have been evoked to explain its appearance in COPD and CHF as noted above [2] are explained by the autoregulative mechanism or its breakdown through hypercapnia, tissue anoxia or severe hypertension [11].

There are several unexplained observations, however. Why did not ischaemia of the optic nerve develop as is thought to happen with persistent optic disc oedema? Did the increased oxygen content prevent nerve ischaemia and further autoregulative breakdown? Enlargement of the physiologic blind spot is the earliest and sometimes the only defect to occur in mild cases, but our patient developed no such enlargement as seen by his visual fields. Was it due to the pulsatile manner or the fact that the blood was mixed arterial and venous blood, or is this an indication that the current theory of vision loss in papilloedema is in error?

After our patient had recovered, there was a report of another haemodialysis patient developing papilloedema from retrograde flow through the jugular from a large arteriovenous fistula; however, that patient quickly died from pneumonia [12] before the long-term course of this problem could be delineated. Our patient's course suggests that the problem may spontaneously resolve in time. We have not documented a mechanism but suspect that as vasodilatation occurs, pressures in the cavernous sinuses and ophthalmic veins drop and a benign course may ensue.

### Teaching points

1. Optic disc oedema clinically resembling papilloedema may result from central venous occlusion in patients

with large functioning fistulas who present with blurred vision.

2. Workup should always be performed to exclude true papilloedema with increased intracranial pressures.
3. While venous pulsations are usually useful to follow as a marker of intracranial pressure, the presence of such pulsations may not be reliable in the presence of arteriovenous fistulas.
4. The optic disc oedema appears to be the result of retrograde flow through the intrajugular, cavernous sinus and optic vein, which have no valves to prevent retrograde flow.
5. Although it is impossible to extrapolate from an isolated case, the long-term prognosis may be good with the resolution of the oedema in time and the preservation of vision. The reason for such a favourable prognosis is unclear but could possibly be related to a lack of ischaemia due to the oxygenated blood from the fistula.

*Conflict of interest statement.* None declared.

### References

1. Paton L, Holmes G. The pathology of papilloedema. *Brain* 1911; 33: 389–411
2. François J, Candaele-Baeten Y. Congestion of the retinal veins and papillary edema in a case of malignant evolutive emphysema. *Bull Soc Belge Ophthalmol* 1965; 141: 604–610
3. Friedman DI. Medication-induced intracranial hypertension in dermatology. *Am J Clin Dermatol* 2005; 6: 29–37
4. Sadun AA, Currie JN, Lessell S. Transient visual obscurations with elevated optic discs. *Ann Neurol* 1984; 16: 489–494
5. Van Stavern GP. Optic disc edema. *Semin Neurol* 2007; 27: 233–243
6. Bessmerthý MZ. Mechanism of optic nerve congestive disk development during acute period of closed craniocerebral injury. *Vestn Oftalmol* 2000; 116: 36–38
7. Hamann S, Johansen S. Combined central retinal artery and vein occlusion in Churg-Strauss syndrome: case report. *Acta Ophthalmol Scand* 2006; 84: 703–706
8. Fledelius HC. Unilateral papilloedema after hepatitis B vaccination in a migraine patient. A case report including forensic aspects. *Acta Ophthalmol Scand* 1999; 77: 72
9. Hayreh SS. Optic disc edema in raised intracranial pressure. *V Pathog Arch Ophthalmol* 1977; 95: 1553–1565
10. Zhioua R, Lasram L, Mallouche N *et al.* Macular edema and chronic renal insufficiency. *J Fr Ophthalmol* 1991; 14: 650–652
11. Primrose J. Pathogenesis of papilloedema. *Doc Ophthalmol* 1976; 40: 391–408
12. Kornhuber ME, Markau S, Surov A *et al.* Pseudotumor cerebri due to proximal haemodialysis fistula. *Nephrol Dial Transplant* 2007; 22: 654

*Received for publication:* 18.12.07

*Accepted in revised form:* 11.1.08