

## Malignant melanoma of the lung: case series

Katarzyna Postrzech-Adamczyk<sup>1</sup>, Mariusz Chabowski<sup>2</sup>, Bożena Głuszczyk-Ferenc<sup>1</sup>,  
Agnieszka Wodzińska<sup>3</sup>, Beata Muszczyńska-Bernhard<sup>4</sup>, Andrzej Szuba<sup>1</sup>, Dariusz Janczak<sup>5</sup>

<sup>1</sup>Department of Internal Medicine, 4<sup>th</sup> Clinical Military Hospital, Wrocław, Poland

<sup>2</sup>Department of Surgery, 4<sup>th</sup> Clinical Military Hospital, Wrocław, Poland

<sup>3</sup>Department of Radiology, 4<sup>th</sup> Clinical Military Hospital, Wrocław, Poland

<sup>4</sup>Department of Pathology "Hist-Med", Wrocław, Poland

<sup>5</sup>Department of Clinical Proceedings, Faculty of Health Science, Wrocław Medical University, Wrocław, Poland



Kardiologia i Torakochirurgia Polska 2015; 12 (1): 72-76

### Abstract

Extracutaneous locations of primary malignant melanoma are rare. In the respiratory system most melanomas present as metastatic tumors. For the diagnosis of primary lung melanoma, strict histopathological and clinical criteria should be met. In this paper we present three cases of malignant melanoma which showed in the respiratory system. The first 2 case studies present primary lung melanomas, while the last one shows late lung metastasis of tumor originated from vaginal mucosa. The treatment of choice for localized disease as well as single metastasis is surgical excision.

**Key words:** melanoma, primary lung melanoma.

### Streszczenie

Pozaskórne lokalizacje pierwotnego czerniaka złośliwego występują rzadko. W obrębie układu oddechowego zdecydowaną większość czerniaków stanowią guzy przerzutowe. Rozpoznanie pierwotnego czerniaka płuc wymaga spełnienia określonych kryteriów histopatologicznych i klinicznych. W pracy zaprezentowano 3 przypadki pacjentów ze stwierdzonym czerniakiem w obrębie układu oddechowego. Pierwsze dwa opisy dotyczą pierwotnego czerniaka płuc, w ostatnim przedstawiono przypadek późnych przerzutów do płuc w przebiegu czerniaka pochwy. Leczeniem z wyboru w przypadku zarówno zlokalizowanej choroby, jak i pojedynczych przerzutów pozostaje leczenie chirurgiczne.

**Słowa kluczowe:** czerniak, pierwotny czerniak płuc.

### Introduction

Malignant melanoma (MM) is a skin malignant tumor which derives from melanocytes and can originate in any part of the body that contains these cells. It is characterized by high malignancy due to rapid growth and early metastasis. Primary extracutaneous MM is rare and can present in ocular, rectal, mucosal, under the nail, conjunctival, vaginal, urogenital, esophageal, and meningeal locations [1]. In the respiratory system most cases are metastases. Primary lung melanoma occurs only in 0.01% of all primary lung tumors [2]. Treatment strategies of MM include surgery, radiotherapy, chemotherapy and the latest management option is biological treatment. Surgical excision of the primary lesion can be curative only for patients with localized disease. In patients who present with disseminated disease, the treatment aims to extend survival and improve quality of life. In this article we present 3 cases of the respiratory system malignant melanomas, two primary lung melanomas and one metastatic melanoma originated from vaginal mucosa.

### Case 1

A 69-year-old female was admitted to the Department of Pulmonology with a history of persistent cough and exertional dyspnea. Chest X-ray showed atelectasis of the right upper lobe and solid tumor in the same area. Computed tomography (CT) revealed a large solid and cystic lesion in the upper right lobe expanding from the apex along the anterior chest wall. Additionally paratracheal, inferior tracheobronchial, sub- and supraclavicular lymph nodes were enlarged (Fig. 1). Positron emission tomography (PET) scan showed no other malignancy except for findings in CT. Bronchoscopy exposed a darkly pigmented, endobronchial mass obstructing the right upper lobe bronchus, visually mimicking thrombus. Cytological examination revealed non-small cell cancer, but full histopathological examination resulted in the diagnosis of malignant melanoma. Immunohistochemistry of tissue biopsy tested positive for S100 protein, HMB45, Melanin A and negative for panCK, TTF1, CK7, p63 and CK5/6 (Fig. 2). The pa-

**Address for correspondence:** Katarzyna Postrzech-Adamczyk, Department of Internal Medicine, 4<sup>th</sup> Clinical Military Hospital, 5 Weigla St., 50-981 Wrocław, Poland, phone: 261 660 864, e-mail: kpostrzech.adamczyk@gmail.com

tient was qualified to adjuvant chemotherapy, unfortunately progression of the disease was observed and the patient died 6 months after diagnosis.

## Case 2

A 63-year-old male with a medical history of hypertension and diabetes mellitus presented in the Emergency Department with right-sided hemiparesis lasting for 2 days. Computed tomography of the head showed numerous supra- and infratentorial lesions with hemorrhage (Fig. 3), chest X-ray revealed a round shadow in the middle zone of the left lung. For further assessment the patient was admitted to the Department of Internal Medicine. Physical examination was unremarkable except for a right-sided hemiparesis, no skin lesions suggestive of skin cancer were found. Computed tomography of the chest showed solid tumor in the upper lobe of the left lung and one similar smaller lesion in the same lung (Fig. 4). Bronchoscopy did not yield diagnosis thus transthoracic biopsy was performed. Cytological examination disclosed malignant melanoma cells. Due to disseminated lesions in the central nervous system and the right lung the patient was disqualified from surgery. At that moment, because of hemorrhagic changes in the brain radiotherapy was not indicated either. Treatment with systemic corticosteroids was introduced and improvement of hemiparesis was observed although the general condition of the patient gradually de-

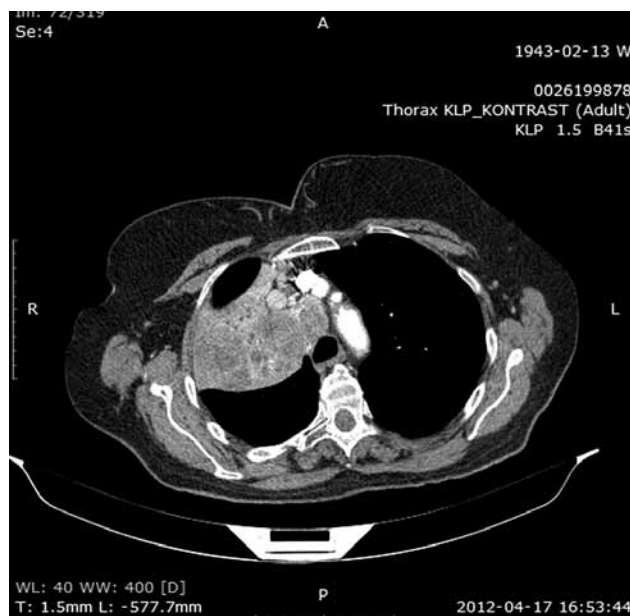


Fig. 1. Female, 69-year-old. Computed tomography examination of the chest. Solid cystic mass in the upper pole of the right hilum

teriorated. Due to no available effective management further examinations were not performed. With the diagnosis of stage IV malignant melanoma in the stable clinical condition the patient was released to palliative care.

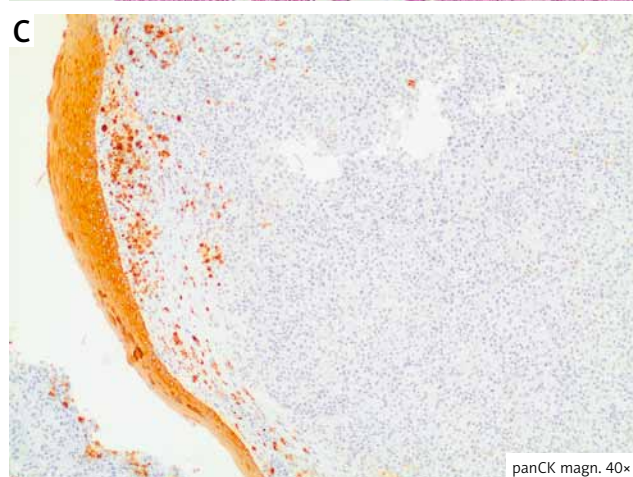
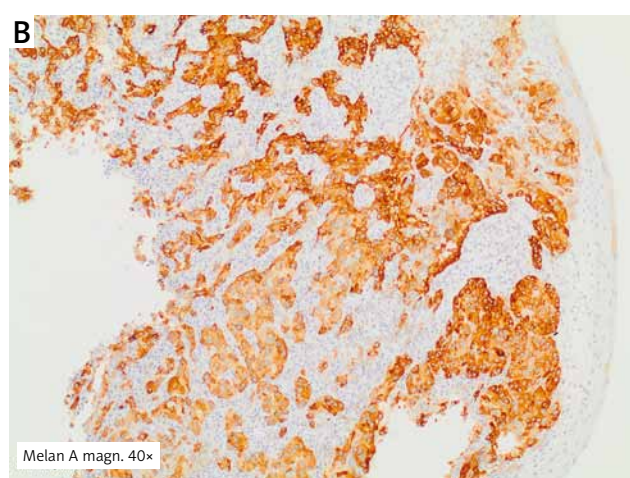
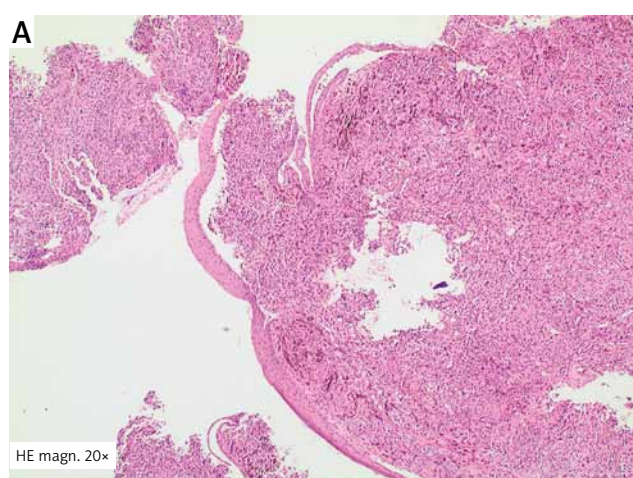


Fig. 2. A) HE stain: bronchial mucosa infiltrated by epithelioid tumor cells. Some of them contain a dye in the cytoplasm. B) Immunohistochemistry: Melan A-positive reaction. C) Immunohistochemistry: panCK-negative reaction

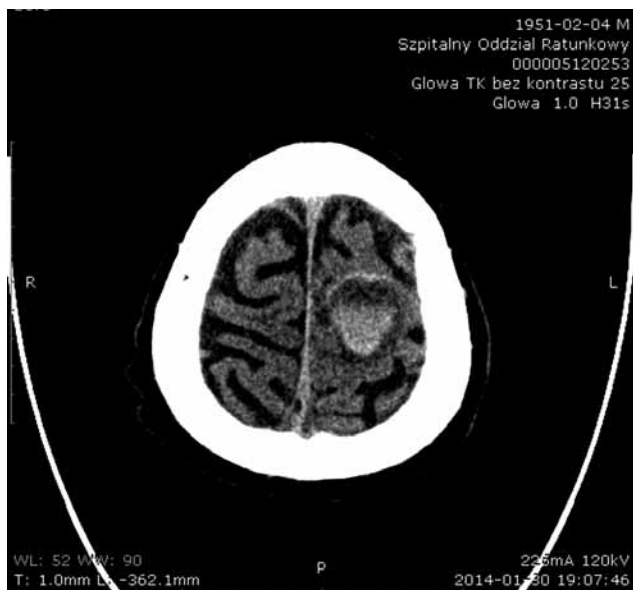

Fig. 3. Male, 63-year-old, right-sided hemiparesis. Axial scan of non-contrast computed tomography examination of the head. Lesion in the left parietal lobe with hyperdense fluid-fluid level, surrounded with white matter edema that could be suspicious for the brain metastasis with the hemorrhage

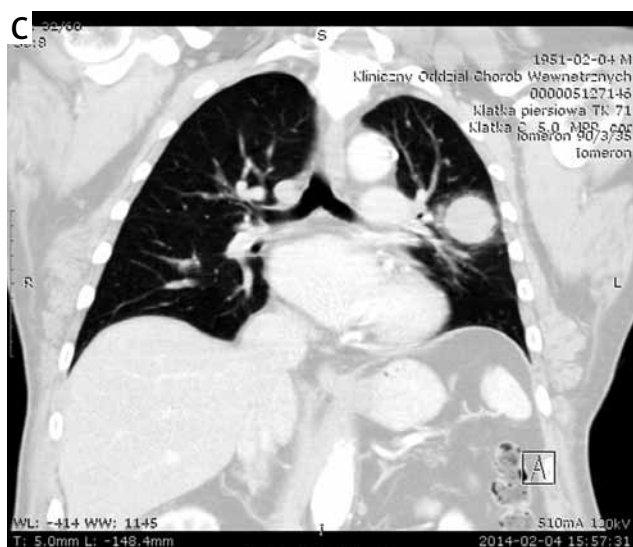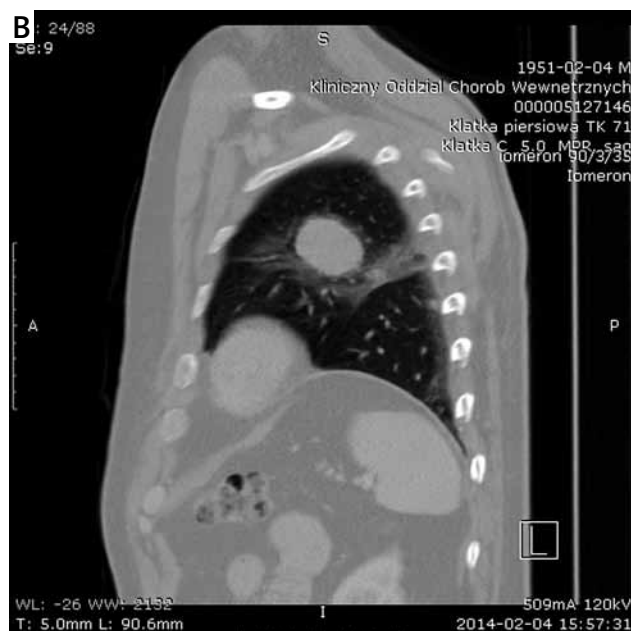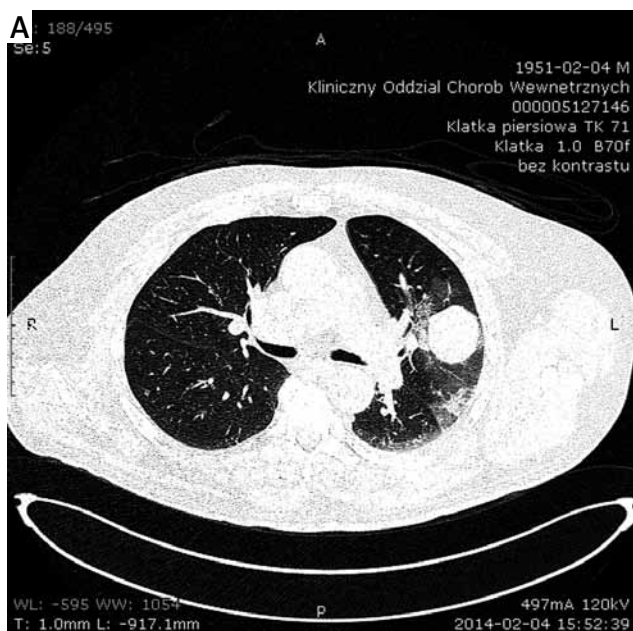


Fig. 4. Male, 63-year-old, right-sided hemiparesis. Computed tomography examination of the chest after i.v. contrast administration. Large rounded mass in the 3<sup>rd</sup> segment of the left lung surrounded with ground-glass opacity. A) axial section, B) sagittal section, C) coronal section

### Case 3

A 50-year-old female after surgically treated MM of vaginal mucosa 7 years before and reoperation for local recurrence 4 years later presented with persistent cough. Computed tomography of the chest revealed 3 circular solid tumors (0.6 cm in diameter) in the right lung and 2 similar lesions in the left lung (Fig. 5). Positron emission tomography scan showed increased glucose metabolism in the same locations and additionally in the iliac lymph nodes. The patient was qualified for surgical excision of lung tumors. Right thoracotomy and subsequently left thoracotomy with wedge resection of metastatic tumors was performed. Histopathological examination confirmed metastatic malignant melanoma. The patient was referred to adjuvant chemotherapy. Despite treatment, control PET scan revealed rapid progression and the patient died 15 months later.

### Discussion

In Poland, MM is responsible for 1.7% cancer morbidity in men and 1.9% in women but these numbers have been still growing for the past three decades. At the time of diagnosis in approximately 80% of patients melanoma is a localized skin lesion, 15% of patients present with regionally advanced disease and 5% with disseminated cancer [3, 4]. No data regarding occurrence of primary extracutaneous MM in our country are available. In the literature only 4-5% of all primary melanomas do not arise from the skin. Most frequently they originate from the mucous membranes lining the respiratory, digestive, and genitourinary tracts or in the eyes as well as in the cerebral meninges [1]. Among lung tumors, primary MM represent 0.01% [2]. Frequently cited criteria for diagnosing primary melanoma of the lung proposed by Allen and Darsh and others in the 1960s include pathological (1 – junctional change with a “dropping off” or “nesting” of malignant cells containing melanin just beneath the bronchial epithelium; 2 – invasion of the bronchial epithelium by the melanoma cells in an area where the bronchial epithelium is not ulcerated; 3 – an obvious melanoma beneath the above described changes) as well as clinical features (1 – no history of a cutaneous, mucous membrane or ocular melanoma; 2 – solitary lung tumor; 3 – absence of any other tumor at the time of diagnosis) [2, 4, 5]. Presented case 1 meets the above criteria. The patient had no history of neoplasm, PET scan excluded other malignancy locations except for the respiratory system, the lesion presented as solitary, dark pigmented tumor obstructing bronchus, histopathological staining was typical for melanoma cells. Case 2 cannot be so unambiguously considered as primary lung melanoma because of lack of examinations certainly excluding other origin of MM, however solitary lung tumor with no pigmented skin lesions suggests that it could be primary disease. A complete endoscopic or imaging diagnostic procedure in this case was not performed due to severe and gradually worsening general condition of the patient. The respiratory system is a frequent location for metastasis from different neoplasms. Case 3 presents metastatic

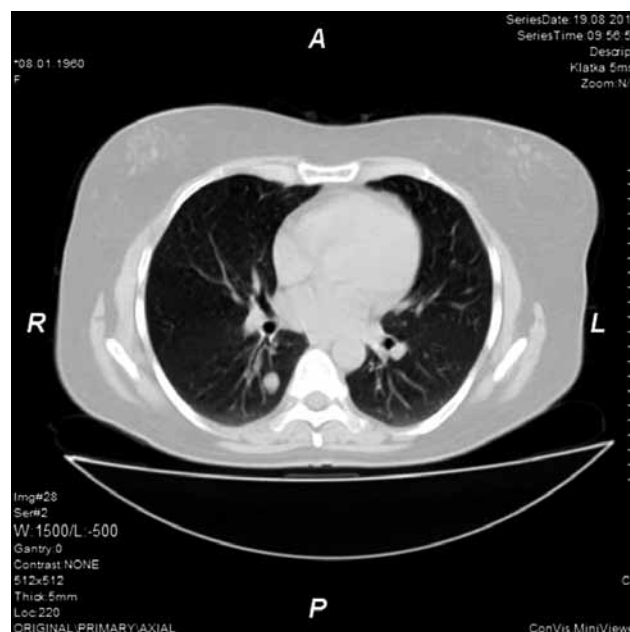


Fig. 5. Female, 50-year-old. Computed tomography examination of the chest. Rounded nodules in both lungs

melanoma of the lung. We included this case study in this article because of primary origin in vaginal mucosa which is quite rare. It occurs in less than 1% of all malignant melanomas and less than 3% of all primary malignant tumors of the vagina [6]. Contemporary treatment of malignant melanoma includes surgery, radiotherapy and systemic therapy with chemo- and immunotherapy. As there are no specific guidelines for primary lung MM recommendations for cutaneous melanoma are usually adapted in such cases. The first line treatment is surgical excision of the primary lesion with an oncologically adequate margin. Lymphadenectomy is performed in confirmed metastasis to lymph nodes. Radiotherapy can be beneficial in particular locations (head and neck) as palliative management in order to prevent or delay hemorrhagic complications and neurologic symptoms. In presented case 2, the patient already has hemorrhagic changes in central nervous system which disqualified him from this type of treatment. Systemic therapy has limited effects. Response is observed in only 15% of patients [3, 6]. Adjuvant therapy with interferon  $\alpha$ -2b should be considered on a case-by-case basis [6]. A promising option seems to be immunotherapy. Recently few drugs have been registered for melanoma. Although data show prolonged median survival [3, 7, 8] these drugs are still investigated. According to Polish guidelines in 2013 patients with advanced melanoma are recommended to be considered for inclusion into prospective clinical trials with immunotherapy drugs. Unfortunately most of these clinical trials exclude patients with brain metastases which require steroids, as in our case 2. The prognosis for primary lung melanoma is rather poor. Median 5-year survival is about 10% [2]. Results of treatment of disseminated MM also remain unsatisfactory, median survival is about 6-10 months [3].

## Conclusions

Lung melanomas are rare lung tumors. Most of them are metastatic. Primary lung melanoma should be considered in cases with no extrapulmonary disease which presents as a solitary lesion especially when bronchoscopy reveals dark pigmented and endobronchial mass. First line treatment in localized disease is surgical excision. Long-term survival is uncommon.

## Disclosure

Authors report no conflict of interest.

## References

1. Hussein MR. Extracutaneous malignant melanomas. *Cancer Invest* 2008; 26: 516-534.
2. Gong L, Liu XY, Zhang WD, Zhu SJ, Yao L, Han XJ, Lan M, Li YH, Zhang W. Primary pulmonary malignant melanoma: a clinicopathologic study of two cases. *Diagn Pathol* 2012; 7: 123.
3. Rutkowski P, Wysocki P, Nowecki Z, Rudnicka L, Nasierowska-Guttmejer A, Fijuth J, Kalinka-Warzocha E, Świtaj T, Wojtukiewicz M, Zegarski W, Jeziorowski A, Krzemieniecki K, Zaucha R, Filipczyk-Cisarż E, Herman K, Krzakowski M. Cutaneous melanoma – diagnostic and therapeutic guidelines in 2013. *Przegl Dermatol* 2013; 100: 1-15.
4. National Cancer Registry.
5. Dountsis A, Zisis C, Karagianni E, Dahabreh J. Primary malignant melanoma of the lung: a case report. *World J Surg Oncol* 2003; 1: 26.
6. Chaudhuri S, Das D, Chowdhury S, Gupta AD. Primary malignant melanoma of the vagina: A case report and review of literature. *South Asian J Cancer* 2013; 2: 4.
7. Palmer DC, Chan C-C, Gattinoni L, Wrzesinski C, Paulos ChM, Hinrichs ChS, Powell DJ, Jr., Klebanoff ChA, Finkelstein SE, Fariss RN, Yu Z, Nussenblatt RB, Rosenberg SA, Restifo NP. Effective tumor treatment targeting a melanoma/melanocyte-associated antigen triggers severe ocular autoimmunity. *Proc Natl Acad Sci U S A* 2008; 105: 8061-8066.
8. Chu MB, Fesler MJ, Armbrrecht ES, Fosko SW, Hsueh E, Richart JM. High-dose interleukin-2 (HD IL-2) therapy should be considered for treatment of patients with melanoma brain metastases. *Chemother Res Pract* 2013; 2013: 726925.