

A Case of Meningococcal Pyomyositis in an Otherwise Healthy Adult

Monique T. Barakat,¹ Kiran Gajurel,² Katrina Fischer,³ Kathryn Stevens,⁴ Errol Ozdalga,³ and José G. Montoya^{5,6}

¹Division of Gastroenterology & Hepatology, ²Division of Infectious Disease & Geographic Medicine, ³Department of Medicine, ⁴Department of Radiology, ⁵Division of Infectious Diseases and Geographic Medicine, Stanford University School of Medicine, and ⁶Toxoplasma Serology Laboratory, National Reference Center for the Study and Diagnosis of Toxoplasmosis, Palo Alto, California

The clinical spectrum of *Neisseria meningitidis* can range from nasopharyngeal colonization to life-threatening invasive diseases such as meningitis. However, its etiologic role in invasive pyomyositis (PM) has never been reported before in the English language. In this study, we report the first case of PM in the English language and the second case in the literature caused by *N meningitidis*.

Keywords. cellulitis; meningococcus; myositis; *Neisseria meningitidis*; pyomyositis.

Bacterial pyomyositis (PM) is an infection of the skeletal muscle and is an uncommon complication of bacteremia [1, 2]. Also called tropical PM, it is primarily reported in the tropics, where it accounts for up to 4% hospitalizations [3]. It is usually caused by *Staphylococcus aureus* [4–6]. Pyomyositis caused by Gram-negative bacteria is rare, but it is thought to be more common in temperate climates, especially in people with underlying comorbid conditions [5]. In an extensive review of Gram-negative bacteria-associated PM, 180 cases were described between 1979 and 2011, with *Escherichia coli*, *Salmonella*, and *Klebsiella* species being the predominant pathogens [7]. To the best of our knowledge, PM caused by *Neisseria meningitidis* (meningococcus), a Gram-negative bacterium, has never been described in the English language. In this study, we report the first case of invasive meningococcal PM in the English language.

INITIAL PRESENTATION AND HOSPITAL COURSE

The patient is a 45-year-old man who developed a cough, rhinorrhea, and sore throat after his children and wife had developed similar symptoms. His past medical history included hypertension. His symptoms gradually improved over the course of 10 days, when he spiked a fever to 103°F and developed profound pain in the lower back and left thigh. He was urgently evaluated and found to be tachycardic with a pulse rate of 115 per minute, a blood pressure of 109/65 millimeter mercury, an oxygen saturation of 98% on room air, and fever of 103.2°F.

There was tenderness and faint erythema over the lumbar paraspinal muscles and medial aspect of his left thigh, with overlying edema. He had a limited range of motion of the left leg due to muscle weakness and pain.

He did not report headache, neck stiffness, or confusion. There was no significant history of tobacco or alcohol use. He denied the use of illicit drugs or supplements. He had recently visited Hawaii but had not traveled outside the United States for the past several years. There was no exposure to animals other than his family dog and cat, and he denied recent insect bites. His family history was noncontributory.

He was admitted to a hospital, blood cultures were drawn, and he was started on vancomycin, clindamycin, and piperacillin/tazobactam. His fever improved with ibuprofen and acetaminophen, but it consistently recurred within 6 hours of dosing each of these agents. Blood cultures grew *N meningitidis*, and antibiotic coverage was narrowed to penicillin G 3 days after presentation. After this transition, his white blood cell count (WBC) rose from 11 000/mm³ to 14 000/mm³ and he remained febrile, with fevers up to 103°F multiple times per day. The following day, he developed worsening erythema and pain in the left thigh and back and new erythema and pain on the dorsum of his left hand. A magnetic resonance imaging (MRI) study of the thoracic spine was performed and showed edema and enhancement of the left paraspinal muscles compatible with myositis (Figure 1). An MRI scan of the thigh demonstrated edema and enhancement in the anterior and medial muscle compartments of the left thigh (Figure 2). The vastus medialis muscle in particular was enlarged and edematous. There were a few ill-defined areas of patchy nonenhancement in the vastus medialis, but no rim-enhancing fluid collections to suggest abscess. At this time, the patient requested a transfer to a tertiary referral center for more specialized care.

Upon presentation to Stanford University Hospital, the patient had received 5 days of antibiotic therapy (3 days with vancomycin, clindamycin, and piperacillin/tazobactam and 2 days with penicillin G). His WBC was 15 400/mm³ (65% polymorphonuclear cells,

Received 20 January 2016; accepted 29 April 2016.

Correspondence: M. T. Barakat, Division of Gastroenterology & Hepatology, Stanford University School of Medicine, 300 Pasteur Drive, Stanford, CA 94305 (barakat@stanford.edu).

Open Forum Infectious Diseases®

© The Author 2016. Published by Oxford University Press on behalf of the Infectious Diseases Society of America. This is an Open Access article distributed under the terms of the Creative Commons Attribution-NonCommercial-NoDerivs licence (<http://creativecommons.org/licenses/by-nc-nd/4.0/>), which permits non-commercial reproduction and distribution of the work, in any medium, provided the original work is not altered or transformed in any way, and that the work is properly cited. For commercial re-use, please contact journals.permissions@oup.com. DOI: 10.1093/ofid/ofw087

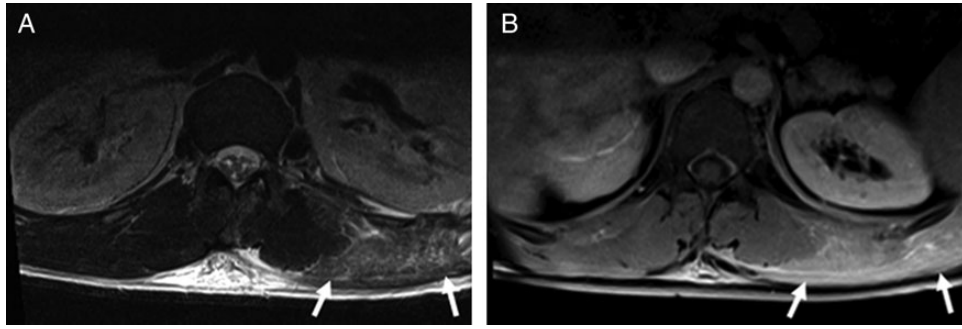


Figure 1. Axial T2 (A) and T1-weighted (B) images with fat saturation through the thoracolumbar region after intravenous gadolinium administration demonstrating high T2 signal and enhancement in the left paraspinal muscles (arrows), and there is prominent edema in the overlying soft tissues.

10% bands), and erythrocyte sedimentation rate was 112 millimeter per hour. The patient had mild elevation of the transaminases at presentation, which was thought to be due to muscle involvement, but had a normal creatine kinase. The left thigh was erythematous and edematous from the groin to the knee, nontender, with significant progression of erythema beyond the demarcation line drawn at the local hospital (Figure 3). He also had nonerythematous swelling of the left knee, but no joint effusion or pain with range of motion, and no evidence of hip joint involvement. Nontender erythema was also noted over the bilateral paraspinal muscles from L1 extending down to the gluteal cleft. His clinical presentation was thought to be due to PM from *N meningitidis*. He shortly became febrile to 101°F, and his antibiotic regimen was broadened to ceftriaxone and vancomycin due to presumed lack of response. The following day, there was significant improvement of erythema over the left thigh and back, and the leukocytosis had decreased to 11 800/mm³. A MRI of the thoracolumbar spine again revealed diffuse edema and enhancement in the left paraspinal musculature, with no rim-enhancing fluid collections. There was marked edema in the subcutaneous tissues of the lower back, measuring at least

20 cm in the transverse dimension and 26 cm craniocaudally. A follow-up MRI examination of the thigh again revealed edema and enhancement in the anterior and medial compartment musculature of the thigh. However, small foci of nonenhancing muscle with peripheral enhancement were now seen within the vastus medialis muscle, compatible with discrete areas of muscle necrosis (Figure 4). There was decreased edema and enhancement in the overlying subcutaneous tissues and along the interfascial planes compared with the earlier scan. General surgery was consulted and, given the absence of frank abscess, opted to defer surgical management. He remained intermittently febrile throughout the next 24 hours, and ceftriaxone was increased to 2 grams every 12 hours. He also began to describe intermittent pain and swelling of his right groin. On examination, he had mild right inguinal fullness but was nontender, with minimal overlying erythema.

On hospital day 8, the patient remained afebrile, his leukocytosis steadily decreased, erythema and edema continued to improve, and knee swelling resolved. Vancomycin was discontinued on hospital day 8. Repeat blood cultures were negative, and he was discharged home to complete a 2-week course of ceftriaxone. The patient recovered completely and almost 1 year later after

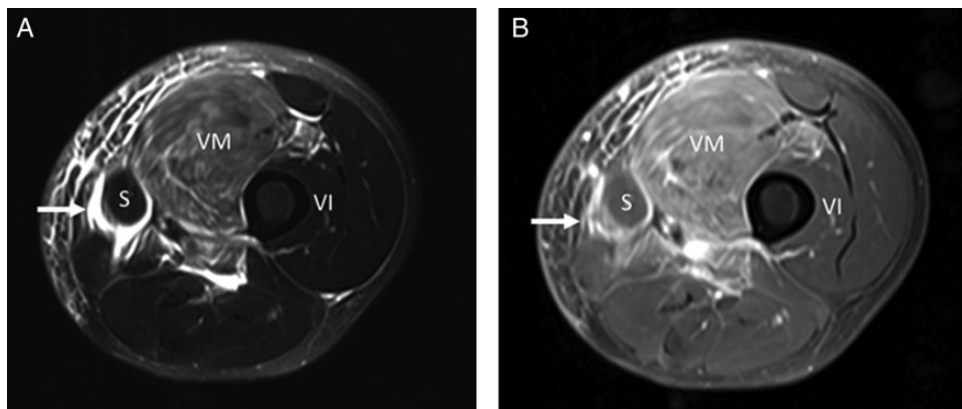


Figure 2. Axial T2 (A) and T1-weighted (B) images with fat saturation through the left mid-thigh after intravenous gadolinium administration demonstrate edema and enhancement in the anteromedial thigh musculature, with a swollen and edematous vastus medialis (VM) muscle. High T2 signal and enhancement also tracks along the interfascial planes, most marked around the sartorius muscle (S) (arrows).

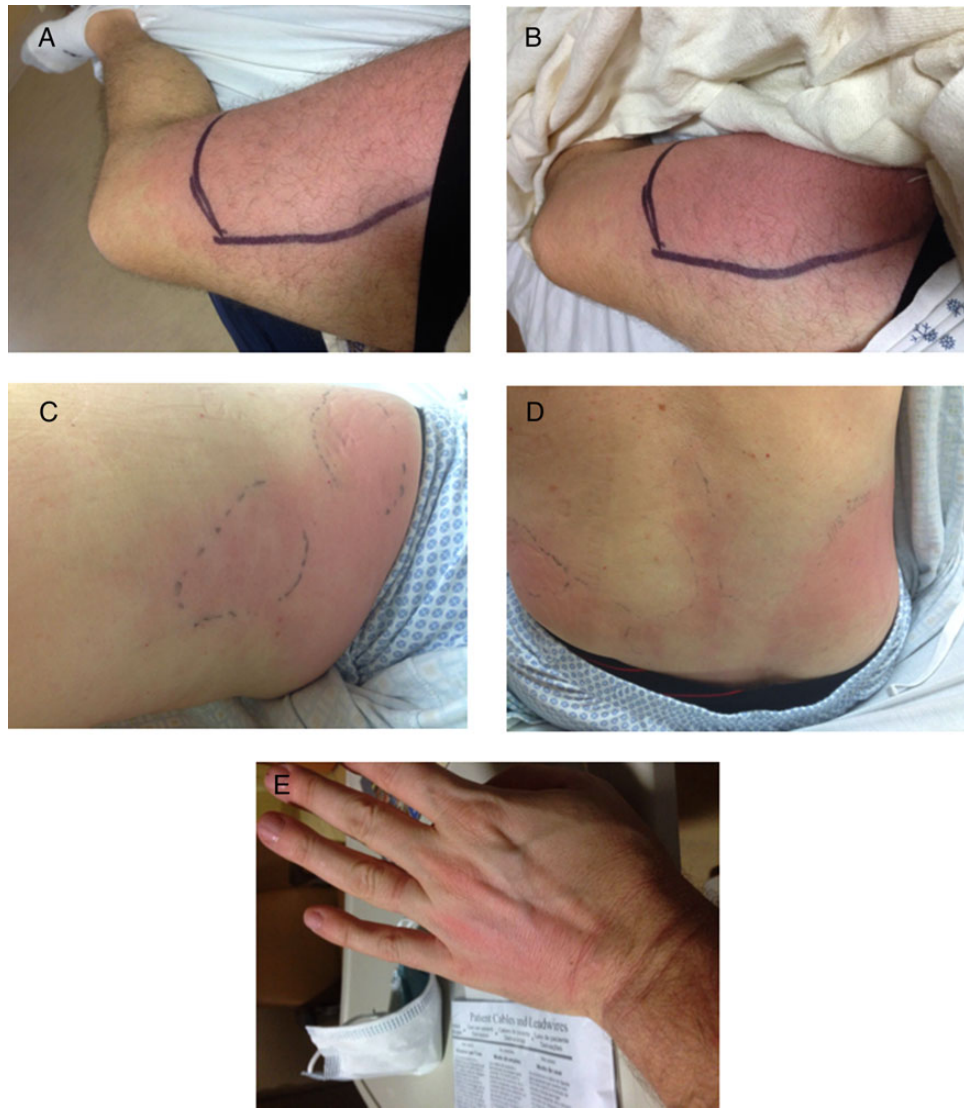


Figure 3. Cellulitis is seen over sites of radiologically documented muscle inflammation in the medial thigh (A and B) and paraspinal regions (C and D), clearly progressing beyond the previously marked margins. Cellulitis is also seen over the dorsum of the left hand (E), in a distribution clinically thought to reflect underlying tenosynovitis.

the illness he is doing well without any local or systemic sequelae. His initial blood cultures were sent to the Microbial Diseases Laboratory of the California Department of Public Health, eventually returning as *N meningitidis* capsular group C. Of note, the patient's children spontaneously recovered from their illnesses, but the patient's wife developed respiratory distress and epiglottitis for which she was hospitalized, and she was also found to have *N meningitidis*, isolated from a pharyngeal swab.

DISCUSSION

Neisseria meningitidis can present with a wide spectrum of clinical manifestation ranging from colonization in the nasopharynx to devastating invasive diseases. Even in the antibiotic era, invasive meningococcal disease carries a high case fatality rate of 10%–15%, and another 10%–20% of survivors experience long-term

complications that include amputation and neurologic deficits [8–10]. Meningitis and meningococemia are the most common forms of invasive disease. Other less commonly reported clinical presentations are pneumonia, septic arthritis, pericarditis, conjunctivitis, sinusitis, epiglottitis, urethritis, and proctitis [11]. Although petechial and ecchymotic lesions have been commonly associated with invasive meningococcal disease, PM and cutaneous infections such as abscesses and cellulitis are uncommon and are not mentioned even in standard reference textbooks of infectious diseases. There is only 1 reported case of a cutaneous abscess associated with thyroglossal duct cyst that was successfully treated with drainage and antimicrobials [12]. Seventeen cases of meningococcal cellulitis have been described to date, and 13 of them were recently reviewed by Ozaki et al [13–16]. Thirteen of the 17 cases were described in females. Almost 60% had bacteremia detected. Nine cases occurred

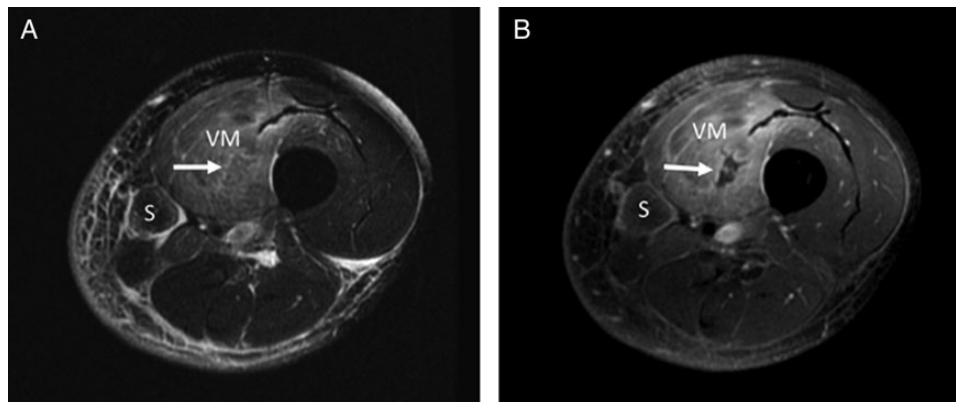


Figure 4. Follow-up magnetic resonance imaging (MRI) 4 days later. Axial T2 (A) and T1-weighted (B) images with fat saturation through the left mid-thigh after intravenous gadolinium administration demonstrate persistent edema and enhancement in the anteromedial thigh musculature, with a swollen and edematous vastus medialis (VM). However, there is now a small focus of nonenhancing muscle in the vastus medialis muscle (arrow) but no corresponding high signal intensity fluid collection on the T2-weighted image (arrow). Decreased edema and enhancement is seen in the subcutaneous tissues compared with the MRI scan 4 days earlier.

in children and 8 in adults. Children typically presented with peri-orbital cellulitis, whereas extremity involvement was more common in males. Sixty-seven percent of adults and none of the children had underlying comorbidities. The outcome was generally good, with only 1 attributed death. However, none of these cases were reported to have PM, although it is possible that some patients could have had unrecognized underlying muscle inflammation [17]. In fact, no cases of primary invasive meningococcal PM have been reported in the English language, even though proinflammatory cytokine-induced myositis (as evidenced by myalgia and elevated creatinine kinase) has been described [18]. We are aware of only 1 prior case of meningococcal PM reported in the French literature [19]. It describes a 7-year-old male child with right hip septic arthritis with associated osteomyelitis of the acetabulum who developed bilateral pelvic muscle abscesses. The blood, right hip synovial fluid, and left pelvic muscle cultures were sterile, but a polymerase chain reaction analysis of right hip synovial fluid confirmed capsular group B *N meningitidis*.

We believe our patient had early invasive PM rather than cytokine-induced myositis based on the fact that there was cellulitis overlying sites of radiologically documented muscle inflammation in the thigh and paraspinal muscles. The vastus medialis muscle in particular was diffusely swollen and edematous, with mildly heterogeneous enhancement at initial presentation. Edema and enhancement was also seen in the adjacent fascial planes and overlying subcutaneous tissues. Antibiotic therapy was commenced at this point, and it probably prevented the development of abscesses. It should be acknowledged that the confirmation of the etiology of PM was not obtained directly from the soft tissue and was assumed on the basis of positive blood cultures.

The patient likely developed primary meningococemia followed by bacterial seeding of the skeletal muscles in the thigh, paraspinal region, and dorsum of the hand in a pattern of multifocal

involvement that has been described in up to 43% of cases [6]. Similar to most other cases of bacterial PM, our patient was male and had prominent involvement of the thigh muscles without any history of trauma. Creatinine kinase was also normal, as can be seen in more than 75% cases of bacterial PM [5]. In contrast to other Gram-negative bacteria associated PM, our patient did not have significant medical comorbidities except for hypertension.

CONCLUSIONS

Meningococcal capsular group C, along with capsular groups B and Y, is responsible for the vast majority of meningococcal disease in the United States [9]. In a recent Canadian Study of invasive meningococcal disease, group C was associated with a worse outcome compared with other capsular groups, but this association was not found to be statistically significant in their multivariate analysis [8]. Meningococcal vaccination against capsular groups A, C, Y, and W is recommended for adolescents and people with risk factors for invasive meningococcal disease. Recently, vaccination against capsular group B has also been recommended for high-risk individuals more than 10 years of age in the United States. It may also be used in adolescents and young adults aged 16–23 without high risk factors for short-term protection [20]. However, it should be noted that different countries have varying schedules of different meningococcal vaccines dependent on local epidemiology, with vaccines currently available for capsular groups A, B, C, W, and Y.

Acknowledgments

Potential conflicts of interest. All authors: No reported conflicts. All authors have submitted the ICMJE Form for Disclosure of Potential Conflicts of Interest.

References

1. Fowler VG Jr, Olsen MK, Corey GR, et al. Clinical identifiers of complicated *Staphylococcus aureus* bacteremia. *Arch Intern Med* 2003; 163:2066–72.

2. Smith IM, Vickers AB. Natural history of 338 treated and untreated patients with staphylococcal septicaemia (1936–1955). *Lancet* **1960**; 1:1318–22.
3. Chauhan S, Jain S, Varma S, Chauhan SS. Tropical pyomyositis (myositis tropicans): current perspective. *Postgrad Med J* **2004**; 80:267–70.
4. Christin L, Sarosi GA. Pyomyositis in North America: case reports and review. *Clin Infect Dis* **1992**; 15:668–77.
5. Crum NF. Bacterial pyomyositis in the United States. *Am J Med* **2004**; 117:420–8.
6. Chiedozi LC. Pyomyositis: review of 205 cases in 112 patients. *Am J Surg* **1979**; 137:255–9.
7. Gousseff M, Lanternier F, Ferroni A, et al. *Enterobacter cloacae* pyomyositis complicating chronic granulomatous disease and review of Gram-negative bacilli pyomyositis. *Eur J Clin Microbiol Infect Dis* **2013**; 32:729–34.
8. Sadarangani M, Scheifele DW, Halperin SA, et al. Outcomes of invasive meningococcal disease in adults and children in Canada between 2002 and 2011: a prospective cohort study. *Clin Infect Dis* **2015**; 60:e27–35.
9. Cohn AC, MacNeil JR, Clark TA, et al. Prevention and control of meningococcal disease: recommendations of the Advisory Committee on Immunization Practices (ACIP). *MMWR Recomm Rep* **2013**; 62:1–28.
10. Cohn AC, MacNeil JR, Harrison LH, et al. Changes in *Neisseria meningitidis* disease epidemiology in the United States, 1998–2007: implications for prevention of meningococcal disease. *Clin Infect Dis* **2010**; 50:184–91.
11. Stephens DS, Bennett JE, Dolin R eds. *Mandell, Douglas, and Bennett's Principles and Practice of Infectious Diseases*. 8th ed. New York: Elsevier & Saunders, Vol 213: pp 2425–2445.e6.
12. Gupta R, Levent F, Healy CM, Edwards MS. Unusual soft tissue manifestations of *Neisseria meningitidis* infections. *Clin Pediatr (Phila)* **2008**; 47:400–3.
13. Ozaki B, Kittai A, Chang S. *Neisseria meningitidis* as a cause of facial cellulitis. *BMJ Case Rep* **2014**; 2014:doi: 10.1136/bcr-2014-203774.
14. Porras MC, Martinez VC, Ruiz IM, et al. Acute cellulitis: an unusual manifestation of meningococcal disease. *Scand J Infect Dis* **2001**; 33:56–9.
15. Guarner J, Greer PW, Whitney A, et al. Pathogenesis and diagnosis of human meningococcal disease using immunohistochemical and PCR assays. *Am J Clin Pathol* **2004**; 122:754–64.
16. Kennedy KJ, Roy J, Lamberth P. Invasive meningococcal disease presenting with cellulitis. *Med J Aust* **2006**; 184:421.
17. Cartolano GL, Barbier C, Arnoult L, et al. Fatal acute cellulitis due to *Neisseria meningitidis*. *J Clin Microbiol* **2003**; 41:3996–7.
18. Carrol ED, Thomson AP, Mobbs KJ, et al. Myositis in children with meningococcal disease: a role for tumour necrosis factor-alpha and interleukin-8? *J Infect* **2002**; 44:17–21.
19. Rousseau V, Descours G, Chaker M, et al. [Primary meningococcal B osteomyelitis and arthritis with multifocal pyomyositis in a child: a case report]. *Arch Pediatr* **2012**; 19:1330–3.
20. Folaranmi T, Rubin L, Martin SW, et al. Use of serogroup B meningococcal vaccines in persons aged ≥ 10 years at increased risk for serogroup B meningococcal disease: recommendations of the advisory committee on immunization practices, 2015. *MMWR Morb Mortal Wkly Rep* **2015**; 64:608–12.