

Received: 2017.06.30

Accepted: 2017.10.05

Published: 2018.01.30

Long-Term Outcomes of Ante-Situm Resection and Auto-Transplantation in Conventionally Unresectable Hepatocellular Carcinoma: A Single-Center Experience

Authors' Contribution:
Study Design A
Data Collection B
Statistical Analysis C
Data Interpretation D
Manuscript Preparation E
Literature Search F
Funds Collection G

ADG 1,2 Qifa Ye
BCEF 1 Cheng Zeng
BC 1 Yanfeng Wang
BF 2 Yingzi Ming
BC 2 Qiquan Wan
BF 1 Shaojun Ye
B 1 Yan Xiong
BF 1 Ling Li

1 Wuhan University, Zhongnan Hospital of Wuhan University, Institute of Hepatobiliary Diseases of Wuhan University, Transplant Center of Wuhan University, Hubei Key Laboratory of Medical Technology on Transplantation, Wuhan, Hubei, P.R. China
2 The 3rd Xiangya Hospital of Central South University, Research Center of National Health Ministry on Transplantation Medicine Engineering and Technology, Changsha, Hunan, P.R. China

Corresponding Author: Qifa Ye, e-mail: yqf_china@163.com
Source of support: Departmental sources

Background: Ante-situm resection and auto-transplantation (ante-situm for short) provides a more aggressive approach to conventionally unresectable hepatocellular carcinoma (HCC). We described the long-term outcomes of patients with HCCs who underwent this technique.


Material/Methods: Between October 2005 and December 2016, we performed 23 ante-situm liver resections. We evaluated post-operative complications, 90-day mortality, recurrence, and long-term survival rates, and reviewed the literature on this topic.

Results: Five types of complications associated with six patients were observed.: 1) primary nonfunctioning liver, thus receiving a liver transplantation; 2) initial poor liver function with recovery two weeks after treatment; 3) diagnoses of portal vein tumor thrombosis, biliary fistula, and small-for-size syndrome, respectively. The median follow-up was 3.6 years; 12 out of 23 patients were alive at the end of the study. One patient who had hepatic recurrence was lost to follow-up after three months. One patient died of multiple organ dysfunction syndrome after the operation, nine patients died due to hepatic recurrence and/or extrahepatic metastasis of HCC. The one-year, three-year, five-year, and 10-year survival rates were 65.2%, 56.5%, 50.9%, and 20.3%, respectively. The one-year, three-year, five-year, and 10-year recurrence rates were 60.9%, 50.7%, 50.7%, and 50.7%, respectively. The chi-square test revealed the patients with recurrence after ante-situm technique were more likely to have poor prognosis (mortality of patients with recurrence versus no-recurrence: 88.9% versus 14.3%, $p < 0.05$) and a strong association was evidenced by Cramer's V statistic (Cramer's $V = 0.734$).

Conclusions: Ante-situm procedure showed benefits in select patients with HCCs who had contraindications for conventional resection operations. In our case series, the ante-situm technique resulted in lower mortality compared to other *ex-vivo* hepatic resection techniques reported in the literature and similar long-term efficacy compared to cases of HCCs suitable for conventional resections. HCCs recurrence was a major risk factor associated with the survival rate of ante-situm technique.

MeSH Keywords: Carcinoma, Hepatocellular • Liver Transplantation • Surgical Procedures, Operative

Full-text PDF: <https://www.annalsoftransplantation.com/abstract/index/idArt/905983>

 3157

 3

 2

 38



Background

Hepatocellular carcinoma (HCC) is one of the most common causes of death, accounting for about 90% of primary hepatic cancer in China [1]. Resection or downstaging followed by resection for HCC remains the major strategy due to its better long-term outcomes compared with other nonsurgical treatments such as transarterial chemoembolization, radiofrequency ablation, percutaneous ethanol injections [2–6].

However, there are still some HCCs that are considered contraindications for a conventional resection due to the difficulty in accessing the tumor such as conditions involving the venous confluence and/or retrohepatic vena cava, or hepatic segments nearby to these major vessels [7]. The ante-situm auto-transplantation technique, a type of *ex-vivo* hepatic resection technique, was first described by Hannoun in 1991. Ante-situm resection includes dissection of the suprahepatic inferior vena cava with preservation of the portal pedicle, hypothermic perfusion for liver preservation *in situ*, and application of veno-venous bypass for maintenance of hemodynamics, liver mobilization, and tumor resection followed by auto-transplantation. This technique has advantages: 1) a tumor that is difficult to access can be removed via mobilization of liver; 2) it avoids additional risks related to the hepatic arterial and portal vein anastomoses; 3) the warm ischemia time tolerated by the liver can be extended due to liver hypothermic perfusion *in situ*.

Although many articles about ante-situm technique have been published, they have been limited by the sample size and follow-up time, and the long-term outcomes of HCC after ante-situm resection have not yet been reported. To our knowledge, this paper is the first to present long-term results of a case series of patients with HCC undergoing ante-situm technique for HCC.

Material and Methods

Patients and indications

Between October 2005 and December 2016, ante-situm resection was performed in 23 patients with conventionally unresectable HCCs that were located at the venous confluence and/or the retrohepatic vena cava. The study was approved by the Medical Science Ethical Committee of our hospital. All the patients received sufficient preoperative explanation and provided their written informed consent.

The selection criteria included: HCC could not be resected by conventional method; Child-Pugh class A or Child-Pugh class B without associated disorders; indocyanine green retention

rate of 15 minutes (ICGR-15) <20%; residual liver volume after resection \geq 50% by preoperative 3-D volumetric CT reconstruction; no or mild cirrhosis with well-preserved liver function; no liver steatosis or steatosis \leq 30%; the glucose of patients with diabetes should be reduced to normal level before the operation; no active infection by bacteria, virus, or fungus; no gastrointestinal ulcer; and no psychosis history.

Surgery

The ante-situm resection was described in detail by Hannoun et al. [8], and the procedure was performed according to this original description. Considerations include ensuring that the hepatoduodenal ligament was dissected, and the portal vein completely exposed; these two steps helped mobilize the liver under hypothermic perfusion and veno-venous bypass. To guarantee that sufficient length of the inferior vena cava (IVC) was retained below the clamp for vascular reconstruction, the suprahepatic IVC and the surrounding diaphragm were usually clamped together. If the tumor had infiltrated into the vena cava, the retrohepatic cava vein was resected partly or completely for complete removal of the tumor; we preferred autologous veins for subsequent reconstruction of the retrohepatic cava vein. The total vascular exclusion of the liver was usually performed in the normal sequence: after the infrahepatic portion of the IVC was clamped, the hemodynamics under the veno-venous bypass was confirmed. Subsequently, the hepatic pedicle was clamped to stop inflow to the liver, and then another clamp was placed on the suprahepatic IVC. After the suprahepatic IVC below the clamp was transected, hypothermic perfusion via the portal vein was started with 4°C perfusate. The high perfusion pressure was associated with excessive shear-stress injury to vascular endothelial cells. To ensure that the protection of hypothermic perfusion would not be counterbalanced by excessive shear-stress injury, we maintained the perfusion flow rates between 100 and 150 mL/minute. When the liver, together with the IVC, was rotated out of the anatomic sites, it was important not to twist the portal vein, as this could disturb the hypothermic perfusion via the portal vein. To keep the liver temperature at about 4°C, the resection was accompanied by continuous hypothermic perfusion. During hypothermic perfusion, the warming blankets were used to maintain the patients' body temperature. Resection was performed according to individual patient findings. In principle, vascular interruption should be carefully avoided in structures to be preserved. The liver resection procedure was carried out in the conventional manner. After resection was finished, vessels or bile ducts which were unligated and open should be identified by perfusing the individual system; open large vessels must be ligated or over-sewn to avoid severe bleeding after auto-transplantation. Because small leakage of the perfusate from the resection surface has been associated with postoperative bleeding after the blood supply was

recovered, small leaking sites were carefully checked for and covered with fibrin glue for complete closure.

Statistical analysis

All statistical analysis was performed by SPSS 16.0 software. The results of continuous data are provided as the mean \pm standard deviation (SD). The overall survival and recurrence curves were calculated by using the Kaplan-Meier method. The chi-square test was used for categorical data. Cramer's V statistic was used to determine the strength of the association between recurrence and mortality (≥ 0.5 represents a strong association). Values with $p < 0.05$ were considered as statistically significant.

Results

Clinical profile of patients

A total of 23 patients (15 men and eight women) had a mean of age of 46.5 ± 8.3 years. All patients were diagnosed with HCC considered not eligible for conventional liver resection due to a difficult anatomical location of the tumor. As Table 1 shows, these tumors were located at or nearby the venous confluence and/or the retrohepatic vena cava. Except for one patient with Child-Pugh B who had mild liver cirrhosis, the other patients were all Child-Pugh A. Hepatitis B virus (HBV) infection was the most common etiological factor of HCC, seen in 21 patients (91.3%). The maximum diameter of tumor size ranged from 2 cm to 30 cm.

Intraoperative outcome

Liver parenchymal damage was not severe in any of the patients. The duration of surgery was 6.33 ± 1.71 hours, the anhepatic period was 4.16 ± 1.15 hours, and the mean intraoperative hemorrhage was 524.29 ± 41.86 mL. Intraoperative complication occurred in one patient who developed asystolic cardiac arrest related to hyperkalemia after portal revascularization. The patient was successfully resuscitated with chest compressions combined with 5% bicarbonate injection.

Postoperative outcome

The mean length of postoperative hospitalization was 24 days. According to Azoulay et al. [9], the 90-day mortality rate after liver resection reflects true risk of liver surgery more effectively than the 30-day mortality rate. Therefore, we analyzed the 90-day mortality in our study and the result was 1 out of 23 patients (4%). The patient who died was resuscitated from asystolic cardiac arrest related to hyperkalemia after blood supply recovered during operation, however, he died at postoperative day 8 owing to multiple organ dysfunction syndrome (MODS).

There were five complications associated with six patients. Based on the definition of Ploeg et al. [10], one patient had primary nonfunction (PNF) and received liver transplantation. Two patients had initial poor function (IPF) and recovered after treatment for two weeks. Three patients were diagnosed with portal vein tumor thrombosis, biliary fistula, and small-for-size syndrome (SFSS), respectively. No complications related to infection were found.

Follow-up

Median follow-up was 3.6 years. At the end of the study 12 out of 23 patients were alive and one patient with hepatic recurrence was lost to follow-up after postoperative month 3 (Table 2). Except for one patient who died of MODS postoperatively, nine patients died due to hepatic recurrence and/or extrahepatic metastasis of HCC (Table 2). The one-year, three-year, five-year, and 10-year survival rates were 65.2%, 56.5%, 50.9%, 20.3%, respectively (Figure 1). The one-year, three-year, five-year, and 10-year recurrence rates were 60.9%, 50.7%, 50.7%, and 50.7%, respectively (Figure 2). The chi-square test revealed the patients with recurrence after the ante-situm technique were more likely to have poor prognosis (mortality of patients with recurrence versus no-recurrence: 88.9% versus 14.3%, $p < 0.05$) and a strong association was evidenced by Cramer's V statistic (Cramer's $V = 0.734$). Large HCCs (tumor size 10 cm or greater) was demonstrated as an important risk factor for recurrence. The patients in the large HCCs subgroup had a higher recurrence (60%) than patients in the small HCCs subgroup (23.1%), however, the difference was not significant ($p > 0.05$).

Discussion

Most of the articles concerning ante-situm liver surgery have a mix of patients with a variety of tumors and *ex-vivo* techniques. Therefore, for a complete review of the ante-situm technique, an expanded PubMed search was performed with terms such as "*ex-situ in-vivo*", "total vascular exclusion", "*ex situ*", "*in situ* hypothermic perfusion", "ante-situm" or "extra-corporeal hepatic resection". The studies involving ante-situm liver resections are shown in Table 3 [8,11–15].

Ante-situm technique benefits patients with HCCs involving the venous confluence and/or the retrohepatic vena cava, or hepatic segments nearby to these major vessels

To date, three types of *ex-vivo* resection techniques have been developed. Based on the different approaches, they were categorized as "ante-situm" (or "*ex-situ in-vivo*") [8], "*in situ*" [16], and "*ex situ*" resection [17].

Table 1. Patients and tumor characteristics.

Patient	Child-Pugh	Age, years/sex	HBsAg	Size and Location
1	A	35/F	+	4.7×4.8×5.6 cm, 0.8×1.9×2.6 cm; II, VII, VIII segments
2	A	33/M	+	8.0×10.0×9.1 cm; IV, V, VI, VII segment
3	A	45/M	+	3.8×3.0×3.3 cm, 3.4×2.3×3.0 cm; V, VII, VIII segments
4	A	34/M	+	6×7×5 cm; V, VII, VIII segments
5	A	59/M	+	4×5×6 cm; I, IV, VIII segments
6	A	59/M	+	6×8×10 cm; IV, VIII segments
7	A	53/F	+	8×6×5 cm, 6×6×6 cm; IV, VIII segments
8	A	49/M	+	6×8×12 cm, 1.5×2×3 cm; II, III, IV, VIII, VII segments
9	A	46/M	+	4×5×3 cm; I, IV segments
10	A	48/F	+	6×8×8 cm; V, VI, VIII segments
11	A	53/M	+	7×9×3 cm, between the angle of middle HV and IVC
12	B	55/M	+	11×10.4×7.9 cm; I segment
13	A	38/F	+	10×6×5 cm, 1×1.5×1.5 cm; II, IV, VIII segments
14	A	48/M	+	6×8×10 cm; IV, V segments
15	A	55/M	+	10×8×6 cm; IV, V, VIII segments
16	A	49/F	-	5.5×5×6 cm; I segments
17	A	42/F	+	9×8×6 cm; V, VII, VIII segments
18	A	59/M	+	20×30×12 cm; V, VI, VII, VIII, IV segments
19	A	45/M	-	15×15×15 cm; IV, V, VI, VII, VIII segments
20	A	38/F	+	5×6×5 cm, between the angle of left and middle HV
21	A	50/F	+	8×8×5 cm; V, VI, VII, VIII segments
22	A	35/M	+	5×5×6 cm, 1×2×2 cm; V, VII, VIII segments
23	A	41/M	+	6×10×10 cm; V, IV, VIII segments

F – female; M – male; HV – hepatic vein; IVC – inferior vena cava.

The common aspects of the three techniques include liver hypothermic perfusion for organ preservation, utilization of veno-venous bypass, mobilization, and resection of the liver followed by auto-transplantation.

The techniques have been distinguished in three ways: 1) “ante-situm” technique with dissection of the suprahepatic inferior vena cava without the division of the portal pedicle [8]; 2) “*in situ*” liver resection only with cross-clamping of the major vessels [16]; and 3) “*ex situ*” resection with complete liver removal followed by hepatic resection as a bench procedure [17].

Overall, the “*ex-situ*” resection is associated with numerous drawbacks such as the additional ischemia time required to complete vascular reconstructions and an increased risk of bile duct anastomotic leakage or stricture. A prohibitively high mortality rate of 30% has been reported [18]. The consensus has

been that the morbidity and mortality rate in *ex situ* techniques was much higher than the other two approaches due to the additional risks inherent in the excessively complex surgical procedures. Our findings were consistent with this conclusion.

The debate over whether ante-situm technique or *in situ* technique should be used for liver tumors with difficult locations remains unresolved. Dubay et al. [12] and Yamamoto [15] reported seven cases of ante-situm for liver tumors respectively, with 90-day mortality rates of 14%. These results were similar to previous studies that reported rates ranging from 11% to 19.5% [9,19,20]. Mehrabi et al. [14] results and our results were 0% and 4%, respectively, which were not only similar to the reported perioperative mortality (<5%) of conventional resection [21], but also much better than reported by other articles reviewed and shown in Table 3.

Table 2. Follow up of the 23 patients underwent ante-situm resection and autotransplantation.

Patients	Metastasis and recurrence	Survival time (years)	Cause of death
1		10 years, alive	
2	Hepatic recurrence at postoperative month 2, pulmonary metastasis at postoperative year 1	1.2 years, dead	Pulmonary metastasis
3	Hepatic recurrence at postoperative month 3	7 years, dead	Hepatic recurrence
4	Hepatic recurrence and widely metastasis at postoperative month 3	7.4 years, dead	Hepatic recurrence and widely metastasis
5		7.4 years, alive	
6	Hepatic recurrence at postoperative month 5	2.1 years, dead	Hepatic recurrence
7		6.7 years, alive	
8	Double pulmonary metastasis at postoperative year 1	1 years, dead	Pulmonary metastasis
9		6.4 years, alive	
10	Hepatic recurrence at postoperative month 3	Lost	
11		5.5 years, alive	
12		5 years, alive	
13	Hepatic recurrence and extrahepatic metastasis at postoperative month 2	1 years, dead	Brain and pulmonary metastasis
14	Hepatic recurrence at postoperative year 3	4.5 years, dead	Hepatic recurrence
15		4.5 years, alive	
16		4.4 years, alive	
17		8 days, dead	MODS
18	Hepatic recurrence at postoperative month 10	1 years, dead	Hepatic recurrence
19	Hepatic recurrence and pulmonary metastasis at postoperative month 3	7 months, dead	Hepatic widely metastasis
20		3 years, alive	
21		9 months, alive	
22		7 months, alive	
23		7 months, alive	

MODS – multiple organ dysfunction syndrome.

However, all previous articles were limited by the heterogeneity of the tumors and length of follow-up time, indicating that it is hard to determine the specific long-term outcomes attributed to one approach for HCC. To our knowledge, our study represents the largest patient series focusing on patient-related outcomes after ante-situm resection only for HCC. To discuss the survival of HCC after ante-situm technique, we compared our results with HCCs which were suitable for conventional liver resections. In our study, the patients were all outside the Milan criteria and the five-year survival rate was 50.9%. It has been previously reported the five-year survival rate of patients outside the Milan criteria after conventional liver techniques

ranged from 31% to 98% [22]. Our result was similar to conventional resections in terms of the five-year survival rate. These findings can be attributed to several reasons. First, our center had proficiency in hepatobiliary surgery, liver transplantation, and key technical aspects of ante-situm liver resection: due to the formidable challenge presented by the procedure, only surgeons very proficient in both hepatobiliary surgery and liver transplantation performed the ante-situm resection.

Second, we used restrictive selection criteria, as patients without cirrhosis can tolerate major liver resections with low rates of lethal complications. In candidates with cirrhosis, careful

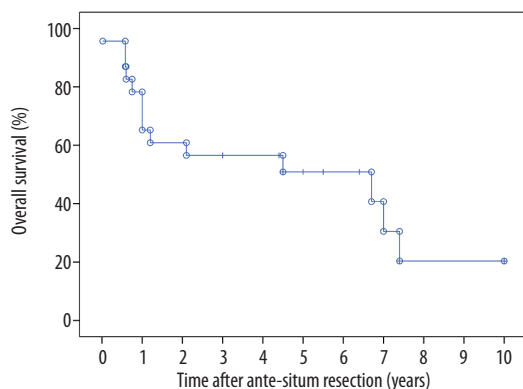


Figure 1. The overall survival rates of the 23 patients with HCC after ante-situm resection.

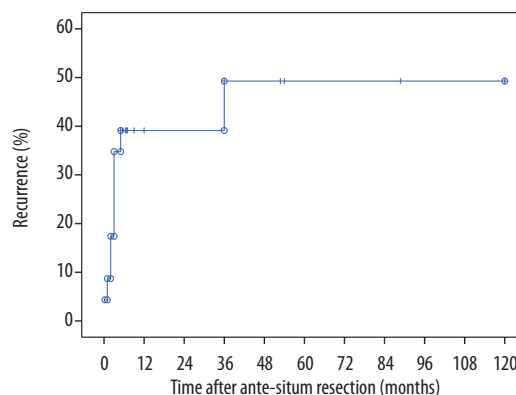


Figure 2. The recurrence rates of the 23 patients with HCC after ante-situm resection.

Table 3. Literature reports of ante-situm liver resection and autotransplantation(articles in English).

Report	Year	Cases	90-day mortality of HCC after ante-situm	Total 90-day mortality of ante-situm
Hannoun [8]	1991	3	0%	0%
Delrivie're [11]	1995	15	NA	6%
Dubay [12]	2009	7	NA	14%
Malde [13]	2011	3	0%	0%
Mehrabi [14]	2011	7	0%	0%
Yamamoto [15]	2013	7	20%	14%

NA – not available.

selection of patients has been shown to be crucial to avoid technique-related complications [23,24]. Therefore, we selected patients who did not have cirrhosis or had mild cirrhosis with well-preserved liver function. The Child-Pugh classification has been reported to be the most common measure to evaluate liver function before liver resection [25], and patients with highly impaired liver function (Child-Pugh class C or advanced Child-Pugh class B) have been reported to have poor outcomes after hepatic resection [26]. Hence, the Child-Pugh classification in our study was Child-Pugh class A or Child-Pugh class B without accompanying disorders. However, it should be noted that while the selection of candidates for liver surgery has been based on the Child-Pugh classification for years [27], this strategy does not result in consistent predictive values all the time. Some Child-Pugh A individuals already have impaired liver function with raised concentrations of bilirubin, significant portal hypertension, or even severe ascites fluid [28]. ICG-R15 has been demonstrated as an effective index to assess the liver function reserve even when the patient has an absence of ascites and hyperbilirubinemia [29]. Many studies have shown that cirrhotic candidates with an ICG-R15 up to

10% to 20% are expected to tolerate a major liver resection. Our experience shows that ICG-R15 <20% can be considered another important indicator to evaluate the liver function reserve. Several reports have shown a relationship between the volume of the future liver remnant (FLR) and hepatic function reserve in HCC patients [30,31]. Individuals who have normal hepatic function can undergo resection of up to 60% of the nontumorous liver [30]. It is our experience, that to attenuate the risks related to the ante-situm technique, the volume of FLR after resection should be more than 50% by preoperative 3-D volumetric CT reconstruction.

Third, the most dreaded complication of major hepatectomy in association with total vascular exclusion is massive ischaemia reperfusion injury manifesting as liver failure, overwhelming sepsis and death. Particularly, ante-situm surgery needs much more time to finish the resection and reconstruction precisely compared with conventional resection under total vascular exclusion. Therefore, an effective assistant way to expand the liver ischemic tolerance is necessary. It has been demonstrated that hypothermic perfusion not only lowers cellular

metabolism but also markedly prolongs ischemic tolerance (up to 4 hours) [8]. Moreover, this technique can reduce ischemia reperfusion injury to the liver during the reperfusion stage [32,33]. In addition, the perfusate is another important factor. In our experience, HTK-Bretschneider (HTK) solution is a good choice for hypothermic perfusion via the portal vein. The solution has a potent histidine buffer which can play an efficient role in moderate hypothermia. Thus, the rewarming of the liver, which cannot be avoided completely in ante-situm approach, may be less harmful. In addition, HTK solution has a low concentration of potassium (10 pmol/L) which reduces the risk of cardiac arrest at the time of reperfusion. In the early phase of our study, we used UW solution for hypothermic perfusion. However, after a case of cardiac arrest after reperfusion due to hyperkalemia using UW solution, we replaced UK solution with HTK solution. In addition, before the hepatic blood supply recovered, about 100 mL to 300 mL intrahepatic residual solution was flushed out from the suprahepatic vena cava with saline, accompanied with the use of calcium gluconate and sodium bicarbonate. With these precautions, no cardiac arrest occurred during the period of reperfusion in the subsequent patients.

The recurrence of HCCs underwent ante-situm resection

Another issue which deserves discussion is the recurrence of HCC after radical resection. HCC recurrence has been reported to be responsible for the disappointing long-term outcomes [18]. Our results showed a strong association between HCC recurrence and poor prognosis after ante-situm resection. To date, no study about HCC recurrence rate associated with ante-situm technique has been published due to the limitations in terms of the sample size and follow-up time. Therefore, we compared our findings with published trials of conventional resection. The five-year cumulative recurrence rate of HCC has been reported to be 70% to 89% [34–36]. In China, Huang et al. [36] reported the three-year, five-year, and 10-year recurrence rates after initial hepatic resection were 73.2%, 89%, and 98.8%, respectively. In our study, the three-year, five-year, and 10-year cumulative recurrence rates were maintained at 50.7%, indicating our results were much lower than the conventional resection study results. However, we cannot conclude that ante-situm resection contributed to the decrease of HCC recurrence due to the one-year recurrence rate of 60.9% in our study, which was higher than reported for the conventional technique (42.7%) [36]. These differences may be related to the large tumor size in our study. Tumor size is an important predictor of survival after liver resection. The large size of a HCC suggests that the lesion has already advanced, indicating a greater possibility for tumor spread due to macrovascular invasion or satellite nodules [37]. These advanced tumors often carried a higher risk of recurrence. As a result,

the advantage of hepatic resection for HCC becomes marginal. When the tumor size exceeds 3 cm, particularly 10 cm or greater, the survival decreases [35,38]. Unlike results reported by Huang et al. [36], 10 out of 23 patients with HCC 10 cm or greater were observed in our study. Although the size difference was not significant, possibly due to the small sample size, a much higher recurrence (60%) in the large tumor size subgroup was observed compared with the small tumor size subgroup (23.1%). Thus, the poor outcomes of large tumors 10 cm or greater may counteract the benefit of ante-situm technique.

Limitations

Our study indicated that the ante-situm technique improved the long-term outcomes of HCCs that had difficult accessibility more effectively than the other two *ex-vivo* techniques and our study findings were comparable to conventional resection study findings. However, a randomized controlled trial comparing the ante-situm technique with other *ex-vivo* and conventional approaches needs to be performed to verify this conclusion due to the retrospective nature and the relatively small sample size of our study. Meanwhile, the excessively strict selection criteria for patients and the high requirements for surgery limit its wide application. How to expand the selection criteria and improve the surgical procedure also needs to be studied in the future.

Conclusions

The ante-situm procedure can benefit select patients with HCC involving the venous confluence and/or the retrohepatic vena cava, or hepatic segments nearby to these major vessels. In our case series, ante-situm technique resulted in lower mortality compared to other *ex-vivo* hepatic resection techniques reported in the literature and similar long-term efficacy to HCCs suitable for conventional resections. HCC recurrence is also a major risk factor for poor long-term outcomes of patients who underwent an ante situm technique, particularly when the tumor size was 10 cm or greater.

Acknowledgements

The authors thank Dr. Guizhu Peng, Yi Zhang, Xiaoli Fan, Xuan Li, Zibiao Zhong, Lin Fan, Zhiping Xia, and Zhen Fu for data collection and follow-up of patients

Conflicts of Interest

None.

References:

- Tang ZY, Ye SL, Liu YK et al: A decade's studies on metastasis of hepatocellular carcinoma. *J Cancer Res Clin Oncol*, 2004; 130: 187–96
- Simmonds PC, Primrose JN, Colquitt JL et al: Surgical resection of hepatic metastases from colorectal cancer: A systematic review of published studies. *Br J Cancer*, 2006; 94: 982–99
- Isenberg J, Fischbach R, Kruger I, Keller HW: Treatment of liver metastases from colorectal cancer. *Anticancer Res*, 1996; 16: 1291–95
- Kamran AU, Liu Y, Li FE et al: Transcatheter arterial chemoembolization with gelatin sponge microparticles treated for BCLC stage B hepatocellular carcinoma: A single center retrospective study. *Medicine (Baltimore)*, 2015; 94: e2154
- Livraghi T, Meloni F, Di Stasi M et al: Sustained complete response and complications rates after radiofrequency ablation of very early hepatocellular carcinoma in cirrhosis: Is resection still the treatment of choice? *Hepatology*, 2008; 47: 82–89
- Rahbari NN, Mehrabi A, Mollberg NM et al: Hepatocellular carcinoma: Current management and perspectives for the future. *Ann Surg*, 2011; 253: 453–69
- Raab R, Schlitt HJ, Oldhafer KJ et al: *Ex-vivo* resection techniques in tissue-preserving surgery for liver malignancies. *Langenbecks Arch Surg*, 2000; 385: 179–84
- Hannoun L, Panis Y, Balladur P et al: *Ex-situ in-vivo* liver surgery. *Lancet*, 1991; 337: 1616–17
- Azoulay D, Lim C, Salloum C et al: Complex liver resection using standard total vascular exclusion, venovenous bypass, and *in situ* hypothermic portal perfusion: An audit of 77 consecutive cases. *Ann Surg*, 2015; 262: 93–104
- Ploeg RJ, D'Alessandro AM, Knechtle SJ et al: Risk factors for primary dysfunction after liver transplantation – a multivariate analysis. *Transplantation*, 1993; 55: 807–13
- Delriviere L, Hannoun L: *In situ* and *ex situ in vivo* procedures for complex major liver resections requiring prolonged hepatic vascular exclusion in normal and diseased livers. *J Am Coll Surg*, 1995; 181: 272–76
- Dubay D, Gallinger S, Hawryluck L et al: *In situ* hypothermic liver preservation during radical liver resection with major vascular reconstruction. *Br J Surg*, 2009; 96: 1429–36
- Malde DJ, Khan A, Prasad KR et al: Inferior vena cava resection with hepatectomy: challenging but justified. *HPB (Oxford)*, 2011; 13: 802–10
- Mehrabi A, Fonouni H, Golriz M et al: Hypothermic ante situm resection in tumors of the hepatocaval confluence. *Dig Surg*, 2011; 28: 100–8
- Yamamoto Y: Ante-situm hepatic resection for tumors involving the confluence of hepatic veins and IVC. *J Hepatobiliary Pancreat Sci*, 2013; 20: 313–23
- Fortner JG, Shiu MH, Kinne DW et al: Major hepatic resection using vascular isolation and hypothermic perfusion. *Ann Surg*, 1974; 180: 644–52
- Pichlmayr R, Grosse H, Hauss J et al: Technique and preliminary results of extracorporeal liver surgery (bench procedure) and of surgery on the *in situ* perfused liver. *Br J Surg*, 1990; 77: 21–26
- Oldhafer KJ, Lang H, Schlitt HJ et al: Long-term experience after *ex situ* liver surgery. *Surgery*, 2000; 127: 520–27
- Azoulay D, Andreani P, Maggi U et al: Combined liver resection and reconstruction of the supra-renal vena cava: The Paul Brousse experience. *Ann Surg*, 2006; 244: 80–88
- Cauchy F, Brustia R, Perdigo F et al: *In situ* hypothermic perfusion of the liver for complex hepatic resection: Surgical refinements. *World J Surg*, 2016; 40: 1448–53
- Grazi GL, Ercolani G, Pierangeli F et al: Improved results of liver resection for hepatocellular carcinoma on cirrhosis give the procedure added value. *Ann Surg*, 2001; 234: 71–78
- Tiong L, Maddern GJ: Systematic review and meta-analysis of survival and disease recurrence after radiofrequency ablation for hepatocellular carcinoma. *Br J Surg*, 2011; 98: 1210–24
- Belghiti J, Hiramatsu K, Benoist S et al: Seven hundred forty-seven hepatectomies in the 1990s: An update to evaluate the actual risk of liver resection. *J Am Coll Surg*, 2000; 191: 38–46
- Bralet MP, Regimbeau JM, Pineau P et al: Hepatocellular carcinoma occurring in nonfibrotic liver: Epidemiologic and histopathologic analysis of 80 French cases. *Hepatology*, 2000; 32: 200–4
- Child CG, Turcotte JG: Surgery and portal hypertension. *Major Probl Clin Surg*, 1964; 1: 1–85
- Nagasue N, Kohno H, Tachibana M et al: Prognostic factors after hepatic resection for hepatocellular carcinoma associated with Child-Turcotte class B and C cirrhosis. *Ann Surg*, 1999; 229: 84–90
- Pugh RN, Murray-Lyon IM, Dawson JL et al: Transection of the oesophagus for bleeding oesophageal varices. *Br J Surg*, 1973; 60: 646–49
- D'Amico G, Garcia-Tsao G, Pagliaro L: Natural history and prognostic indicators of survival in cirrhosis: A systematic review of 118 studies. *J Hepatol*, 2006; 44: 217–31
- Imamura H, Seyama Y, Kokudo N et al: One thousand fifty-six hepatectomies without mortality in 8 years. *Arch Surg*, 2003; 138: 1198–206; discussion 206
- Kubota K, Makuuchi M, Kusaka K et al: Measurement of liver volume and hepatic functional reserve as a guide to decision-making in resectional surgery for hepatic tumors. *Hepatology*, 1997; 26: 1176–81
- Shirabe K, Shimada M, Gion T et al: Postoperative liver failure after major hepatic resection for hepatocellular carcinoma in the modern era with special reference to remnant liver volume. *J Am Coll Surg*, 1999; 188: 304–9
- Henry SD, Nachber E, Tulipan J et al: Hypothermic machine preservation reduces molecular markers of ischemia/reperfusion injury in human liver transplantation. *Am J Transplant*, 2012; 12: 2477–86
- Guarrera JV, Henry SD, Samstein B et al: Hypothermic machine preservation in human liver transplantation: the first clinical series. *Am J Transplant*, 2010; 10: 372–81
- Forner A, Llovet JM, Bruix J: Hepatocellular carcinoma. *Lancet*, 2012; 379: 1245–55
- El-Serag HB: Hepatocellular carcinoma. *N Engl J Med*, 2011; 365: 1118–27
- Huang ZY, Liang BY, Xiong M et al: Long-term outcomes of repeat hepatic resection in patients with recurrent hepatocellular carcinoma and analysis of recurrent types and their prognosis: a single-center experience in China. *Ann Surg Oncol*, 2012; 19: 2515–25
- Pawlik TM, Delman KA, Vauthey JN et al: Tumor size predicts vascular invasion and histologic grade: Implications for selection of surgical treatment for hepatocellular carcinoma. *Liver Transpl*, 2005; 11: 1086–92
- Zhou YM, Li B, Xu DH, Yang JM: Safety and efficacy of partial hepatectomy for huge (>=10 cm) hepatocellular carcinoma: A systematic review. *Med Sci Monit*, 2011; 17(3): RA76–83