

New Technologies in Rhinoplasty: A Comprehensive Workflow for Computer-assisted Planning and Execution

Robin V. Willaert, MD, DMD*†
 Yasmin Opdenakker, MD, DMD*
 Yi Sun, Msc, PhD†
 Constantinus Politis, MD,
 DMD, PhD†
 Hubert Vermeersch, MD, PhD‡

Summary: Rhinoplasty in facial cleft patients is among the most challenging types of reconstructive facial surgery due to its variability. Advances in 3-dimensional imaging enable improved preoperative assessment in rhinoplasty. In complex cases with bony support irregularities and asymmetry, it is rational to initiate planning with reconstruction of the aberrant substructure (ie, “bottom-up” planning) rather than starting the surgical design with soft-tissue morphing.

We present a new comprehensive workflow in which novel advanced technologies are implemented to perform “bottom-up” computer-assisted planning and execution in complex rhinoplasty cases. This workflow enables meticulous planning, use of grafting templates, and 3-dimensional-guided osteotomies with integration of piezotome and intraoperative navigation.

Previous reports separately discuss some of these innovations. However, greater benefit lies in the combination of these techniques, with emphasis on preoperative computer analysis, virtual planning, and transfer to the operation theater.

Surgeons are seeking new ways to enhance minimally invasive approaches and to obtain predictable and favorable clinical results. The presently introduced workflow allows clinicians to plan complex cases in a simple, effective, and safe manner, with the combination of different techniques to produce consistent results. (*Plast Reconstr Surg Glob Open* 2019;7:e2121; doi: 10.1097/GOX.0000000000002121; Published online 20 March 2019.)

INTRODUCTION

The performance of 3-dimensional (3D) computer-assisted surgery is becoming increasingly common, especially in osseous procedures.¹ Unfortunately, 3D computer-assisted techniques are not yet routinely applied in rhinoplasty, which is among the most challenging types of facial surgery due to its variability.² Nasal bone osteotomies are typically guided solely by visual inspection and manual feel, and depend on the surgeon’s experience.³

In complex cases with bony support irregularities (eg, congenital deviations, revisions, and posttraumatic cases), it seems rational to start with the aberrant substructure, that is, “bottom-up” planning. Although new technological developments warrant a paradigm shift, for many surgeons, it remains challenging to combine these technologies and integrate them into clinical practice. Here we present a novel workflow to illustrate the potential use of these advanced technologies, and demonstrate the implementation (Table 1).

From the *Department of Head, Neck and Maxillofacial Surgery, Ghent University Hospital, Ghent, Belgium; †Department of Oral and Maxillofacial Surgery, Leuven University Hospitals, Leuven, Belgium; and ‡Department of Plastic and Reconstructive Surgery, Ghent University Hospital, Ghent, Belgium.

Received for publication October 12, 2018; accepted December 5, 2018.

Presented at the European Rhinoplasty Course, March 9, 2018, Brussels, Belgium.

Drs. Willaert and Opdenakker contributed equally and they should both be considered first authors.

Copyright © 2019 The Authors. Published by Wolters Kluwer Health, Inc. on behalf of The American Society of Plastic Surgeons. This is an open-access article distributed under the terms of the Creative Commons Attribution-Non Commercial-No Derivatives License 4.0 (CCBY-NC-ND), where it is permissible to download and share the work provided it is properly cited. The work cannot be changed in any way or used commercially without permission from the journal.

DOI: 10.1097/GOX.0000000000002121

WORKFLOW

Step 1: Advanced Imaging

Advances in digital imaging enable the creation of advanced augmented 3D models of patient skulls. The cone beam computed tomography (CBCT) optimal slice thickness is adjusted to generate images with a limited contrast-to-noise ratio, without additional radiation exposure. Digital imaging and communications in medicine (DICOM) data are then imported into plan-

Disclosure: The authors have no financial interest to declare in relation to the content of this article.

Table 1. Workflow of Computer-assisted Planning and Execution in Complex Rhinoplasty Cases

1. Preoperative planning
- Advanced imaging and postprocessing: CBCT (0.3 mm slice thickness/less radiation), orientation, 3D rendering, segmentation
- Computer analysis: 3D detailed measurements, (a)symmetry, volume measurement, bony deficiency/excess
- Virtual planning and simulation: multiple osteotomies (level and size), bone graft (position size, fixation technique), multidisciplinary discussion, surgical feasibility
2. Transfer to operation theater
- Navigation hardware and software, compatibility with planning software, STL import
- Supplementary 3D-printed osteotomy/drilling surface guides
- Supplementary 3D-printed graft templates
3. Surgery
- Powered, accurate instruments (eg, piezotome)
- Navigational tracking of surgical instruments
- Imaging interface to display real-time execution of virtual plan
4. Postoperative evaluation and correction

CBCT, cone beam computed tomography; STL, stereolithography.

ning software, such as ProPlan (Materialise, Leuven, Belgium), to create a virtual skull for 3D rendering and detailed analysis. By visualizing digital landmarks, such as the piriform aperture and nasofrontal sutures, detailed measurements can be determined for analysis of skull symmetry. Volume measurements reveal osseous deficiencies and excesses in various dimensions, for example, when evaluating alar base support.

Step 2: Planning

ProPlan software facilitates the performance of virtual osteotomies of the nasal bone, and visualization of the need for additional bone grafts. The segmentation of separate regions enables planning of a precise osteotomy cut location in 1 or multiple levels. Bone graft donor and receptor sites are evaluated to determine the size, position, and appropriate fixation techniques. Virtual simulations provide insights regarding the technical feasibility of a procedure, and enable preliminary evaluation of the treatment outcome. Moreover, the 3D skeletal model can be augmented with stereophotogrammetric pictures to evaluate the results at the soft-tissue level. However, these virtual simulations cannot be compared with 3D morphing techniques—both require different interpretation. The combination of digital and clinical assessment generates a tailored treatment plan that can be discussed with the patient. Digital imaging and virtual simulation may

help in explaining the treatment plan in multidisciplinary communication, and when informing the patient (Fig. 1).

Step 3: Transfer

After approval, the virtual planning is exported in stereolithography (STL) STL format, and imported into the navigational software. This phase is crucial because preoperative planning is only useful when followed by meticulous execution. Two elements are indispensable: accurate and compatible software/hardware for transferring the plan, and precise surgical tools to enact the plan in real life.

At the University Hospital of Ghent, the Brainlab navigation system (Brainlab AG, Munich, Germany) is used. However, other navigation systems can be implemented. Navigation is used to determine the exact position of the skin markings according to the preoperative virtual plan. For a percutaneous approach, the skin markings comprise stab incisions at crucial landmarks, without subperiosteal tunnels. Tracking devices can be attached to the surgical instruments. For accuracy and precision, we attach navigational tracking to a piezotome 2 (Satelec Acteon, Merignac, France). Piezosurgery uses ultrasonic piezoelectric vibrations to perform a selective bony cut, while avoiding mucosal lacerations. This technique allows precise control of the osteotomy cut, with the piezotome tip visible on the monitor dur-

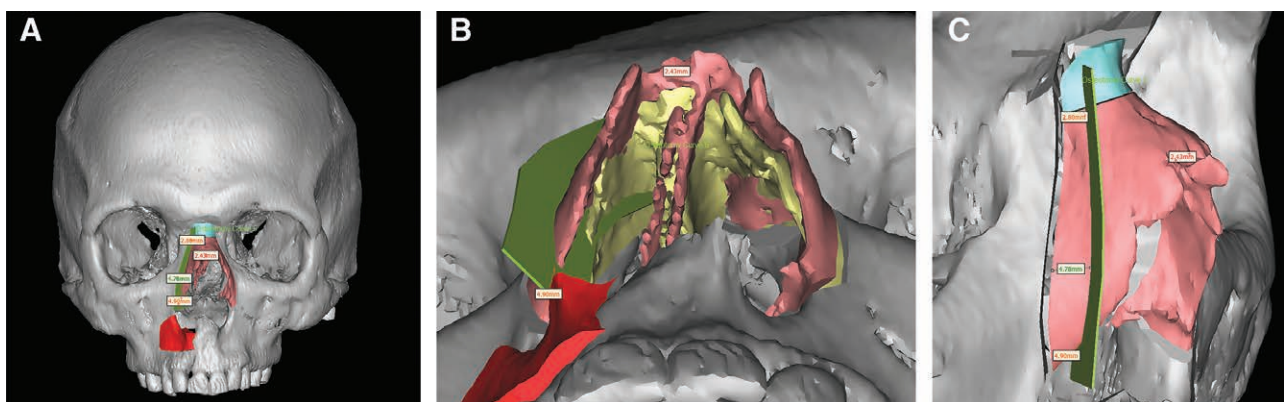


Fig. 1. Preoperative virtual analysis and planning. A, Frontal view: measurements to perform a monobloc reduction of the nasal pyramid and bone grafting of the right apertura piriformis. B, Baseline view. C, Right lateral view: precise measurements to determine the level of the asymmetric/parallel osteotomy lines.

ing the procedure. This enables osteotomy performance without extensive periosteal elevation and reduces postoperative swelling. Moreover, the use of a fine tip enables the translation of exact measurements to a precise callus and hump excision, as determined by the preoperative 3D assessment.⁴⁻⁶ Any connecting osteotomy can be performed, and 3D navigation allows septoplasty performance through a very limited incision. Another approach for transferring the planning to the surgical procedure is the use of a 3D printed guide or surgical template—for example, as a guiding duplicate to shape an autologous graft.

Step 4: Evaluation

The reduction is immediately evaluated with navigation and is visualized on the monitor. Any sliding of the fragments can be corrected at this point.

DISCUSSION

Rhinoplasty cases requiring extensive reconstruction can be difficult.² For example, in a crooked nose, the length from the piriform aperture to the midline is shorter on the deviated side. This necessitates asymmetrical resection at the lateral sides and a vomerine osteotomy because nose asymmetry will persist if both sides of the newly created pyramid are not equal and the vomer is not osteotomized.^{7,8} The skin surrounding the nasal bone can be very thin, and therefore, there is limited room for error. Hence, nasal bone osteotomies are considered the most challenging facial osteotomies. Many types of software exist to aid surgeons and to facilitate patient communication. However, to date, the virtual revolution has largely involved soft-tissue morphing of clinical photographs and profile templates (ie, “top-down” planning).⁴ Surgical templates are expensive and can shift during surgery, and soft-tissue swelling hides the real amount of clinical change.¹ Therefore, in complex cases with bony irregularities, it seems logical to first assess the aberrant infrastructure, that is, “bottom-up” planning.

The implementation of new ideas and innovations typically requires time, expertise, and new infrastructure. Although the software and hardware needed for 3D planning have become more accessible, surgeons are often unaware that they are available in their hospitals. The

presently described workflow encourages surgeons to take advantage of these tools. Peroperative navigation helps to avoid incomplete fracture lines and key anatomical structures, and provides detailed evaluations of more complex cases, such as monobloc-parallel osteotomies. Postoperative evaluation of nasal midline alignment, nose symmetry, and esthetic outcome enables more precise and reliable results. Although these novelties are separately discussed in the literature, the greatest benefits lie in the combination of these techniques.

CONCLUSIONS

The presently introduced workflow can help to plan rhinoplasty cases requiring extensive reconstructions. It eliminates the need for “blind maneuvers.”

Robin V. Willaert, MD, DMD

Department of Head, Neck and Maxillo-Facial Surgery
Ghent University Hospital
Corneel Heymanslaan 10, 9000 Gent, Belgium
E-mail: robin.willaert@icloud.com

REFERENCES

- Hierl T, Arnold S, Kruber D, et al. CAD-CAM-assisted esthetic facial surgery. *J Oral Maxillofac Surg.* 2013;71:e15–e23.
- Codazzi D, Bruschi S, Mazzola RF, et al. Bergamo 3D rhinoplasty software: select, store, and share surgical maneuvers in a three-dimensional nasal model. *Plast Reconstr Surg.* 2016;137:313e–317e.
- Ogino A, Onishi K, Nakamichi M, et al. Navigation-assisted nasal bone osteotomy for malunited fracture. *J Craniofac Surg.* 2018;29:156–158.
- Koc B, Koc EA, Erbek S. Comparison of clinical outcomes using a piezosurgery device vs. a conventional osteotome for lateral osteotomy in rhinoplasty. *Ear Nose Throat J.* 2017;96:318–326.
- Ong AA, Farhood Z, Kyle AR, et al. Interventions to decrease postoperative edema and ecchymosis after rhinoplasty: a systematic review of the literature. *Plast Reconstr Surg.* 2016;137:1448–1462.
- Robiony M, Toro C, Costa F, et al. Piezosurgery: a new method for osteotomies in rhinoplasty. *J Craniofac Surg.* 2007;18:1098–1100.
- Inanli S, Sari M, Yanik M. Intraoperative evaluation and measurement of a crooked nose. *J Craniofac Surg.* 2009;20:985–986.
- Han SK, Chun KW, Park DK, et al. Corrective osteotomy technique for a posttraumatic deviated nose. *J Craniofac Surg.* 2008;19:476–481.