

Dynamic Anterior Stabilization of the Shoulder With Adjustable-Loop Device



Jose Carlos Garcia Jr., M.D., Ph.D., Ricardo Berriel Mendes, M.D.,
Paulo Cavalcante Muzy, M.D., Mauricio de Paiva Raffaelli, M.D., and
Marcelo Boulos Dumans e Mello, M.D.

Abstract: Dynamic anterior stabilization of the shoulder is a surgical procedure based on a triple soft-tissue block. This procedure is designed to fit within a gray zone between the Bristow-Latarjet procedure and the Bankart procedure, where the patient would not need a bone graft; however, capsular reconstruction alone may be insufficient to yield reliable stabilization. This article describes dynamic anterior stabilization of the shoulder using the adjustable-loop device.

Anterior shoulder instability remains one of the main issues within shoulder surgery. There are several studies showing that arthroscopic Bankart repair is successful in treating traumatic anterior shoulder instability without bone loss.¹ On the other hand, glenoid bone loss greater than 21% to 25% and engaging lesions seem to present better results when bony procedures such as the Bristow and Latarjet procedures are performed,²⁻⁵ and both techniques present similar results.⁶ Some authors have suggested that other predictive factors—age at the first episode, sport, and so on—need to be considered when choosing the surgical procedure, whereas others have suggested that even 13.5% of glenoid bone loss can be deemed critical bone loss.^{1,7} Indeed, there is a gray zone in the treatment of anterior shoulder instability, which can be treated by both the Bankart and Bristow-Latarjet procedures.

Some authors have presented an arthroscopic belt-and-suspenders procedure combining principles of the Bankart and Bristow-Latarjet procedures to improve shoulder stability by using only soft-tissue stabilizers; however, this procedure is time-consuming, uses a large medial bone tunnel, and presents a recurrence rate of 8%.⁸ Many authors have reported that the long head of the biceps (LHB) does not have an important function related to shoulder stability. In addition, some studies have suggested that the LHB is just a vestigial structure, presenting a not suitable mechanic axis for not quadrupid animals.⁹⁻¹²

On the basis of these fundamentals, it seems more rational to use the LHB to provide both the sling and direct block effects.¹³ These 2 biomechanical stabilizer mechanisms in a lateralized fashion associated with the Bankart procedure can achieve better results in the aforementioned gray zone. Indeed, some authors have described performing this procedure using interference screws^{14,15} and anchors.¹⁶ The adjustable-loop device is a fixation method that allows a strong fixation and biologic healing. Thus, our technique joins the idea of the triple soft-tissue block of the dynamic anterior stabilization (DAS) with a better LHB healing condition by using the adjustable-loop device.

Surgical Technique

The patient is placed in the beach-chair position under general anesthesia. Through the standard posterior portal, the articular inspection is performed, and the lesions are examined under an arthroscopic view. An anteroinferolateral portal is created 1 cm inferior and just lateral to the standard anterior portal. The best location for this portal can be confirmed with a

From NAEON Institute, São Paulo, Brazil.

The authors report the following potential conflicts of interest or sources of funding: J.C.G. is a consultant for Zimmer-Biomet Latin America and receives royalties for developing orthopaedic devices from Razek, outside the submitted work. M.d.P.R. is a consultant for Implantcast, outside the submitted work. Full ICMJE author disclosure forms are available for this article online, as supplementary material.

Received July 20, 2022; accepted August 25, 2022.

Address correspondence to Jose Carlos Garcia Jr, M.D., Ph.D., NAEON Institute, Avenida Ibirapuera 2907, Sala 1206, Sao Paulo (SP), Brazil 04029-200. E-mail: josecarlos@naeon.org.br

© 2022 THE AUTHORS. Published by Elsevier Inc. on behalf of the Arthroscopy Association of North America. This is an open access article under the CC BY-NC-ND license (<http://creativecommons.org/licenses/by-nc-nd/4.0/>).

2212-6287/22938

<https://doi.org/10.1016/j.eats.2022.08.055>

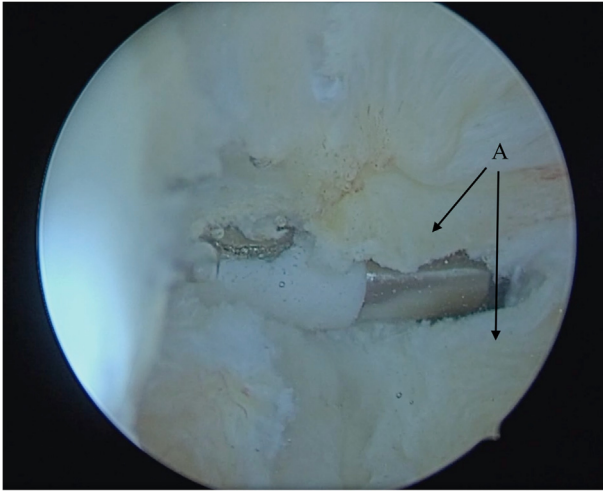


Fig 1. Split subscapularis tendon (A), with optics through posterior portal.

16-gauge needle. The portal needs to be in line with the humeral head equator. Through this portal, the subscapularis tendon is gently opened in the direction of its fibers by using a Kelly device. At this moment, an electrocautery device and/or shaver is useful to widen the subscapularis split (Fig 1). A standard anterior portal is also created, through which the surgeon performs LHB tenotomy. The anterior glenoid rim is exposed, and the bone is shaved to expose the bone marrow, allowing better healing, similar to the Bankart procedure.

Thereafter, the scope is inserted into the antero-inferolateral portal. The scope moves downward in the direction of the pectoralis major insertion. Visualization of the axillary nerve is highly suggested at this point. Other instruments are inserted through the anterior portal. The optic is inserted into the anterior

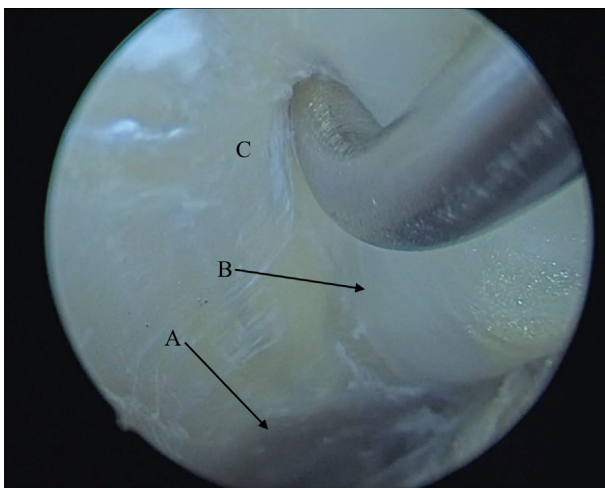


Fig 2. Pectoralis major tendon (A), long head of biceps (B), and humerus (C), with optics through posterior portal.

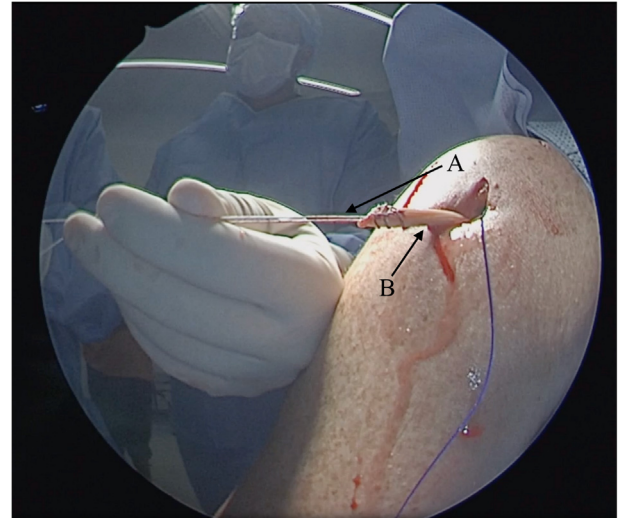


Fig 3. (A) High-resistance wire. (B) Long head of biceps.

portal, and the LHB tendon is then pulled out just over the pectoralis major using a regular probe (Fig 2). Thereafter, the LHB is pulled out of the body through the antero-inferolateral portal by use of a grasper. If the surgeon does not release the LHB just over the pectoralis major, the LHB cannot present free motion, and the patient can lose movement after surgery.

Krackow sutures are placed on the LHB by use of high-resistance #5 Maxibraid (Zimmer-Biomet, Warsaw, IN) (Fig 3). A 4.5-mm drill is inserted using the guide of the DAS FastFit Button (Razek, São Carlos, Brazil) (Figs 4 and 5) through the subscapularis split, and the size of the glenoid is measured. Its insertion point is just medial to the anterior glenoid rim at the 3- to 4-o'clock position. If the LHB diameter is superior to 4.5 mm, the surgeon can make a vertical incision on the LHB in order to reduce its diameter for this tendon's proximal 2 cm or can enlarge the hole by using a 5.5- or 6.5-mm drill for the initial 2 cm (Fig 4); sizes larger than those mentioned earlier are not recommended.

A perforated Kirschner wire is inserted with a No. 0 nylon wire using its blunt side from anterior to posterior to avoid nerve lesions (Fig 6). This nylon is used as a guide for the FastFit Button to be passed from anterior to posterior. The one side of the high-resistance wire inserted in the LHB passes within the loops of the FastFit Button. The FastFit Button is inserted through the subscapularis split on the anterior glenoid rim, and the LHB is sutured to the loop (Figs 7 and 8). The sutured LHB is pulled into the hole by pulling the terminal adjustable-loop device wires. This maneuver will drive and lock the loops and the sutured LHB into the hole; ideally, 2 cm within the hole is enough (Fig 9). Two 1.6-mm FastFit Anchors (Razek) are inserted above and under the LHB tendon through the subscapularis split by using a cannula in the antero-inferolateral portal, allowing the surgeon to perform labral

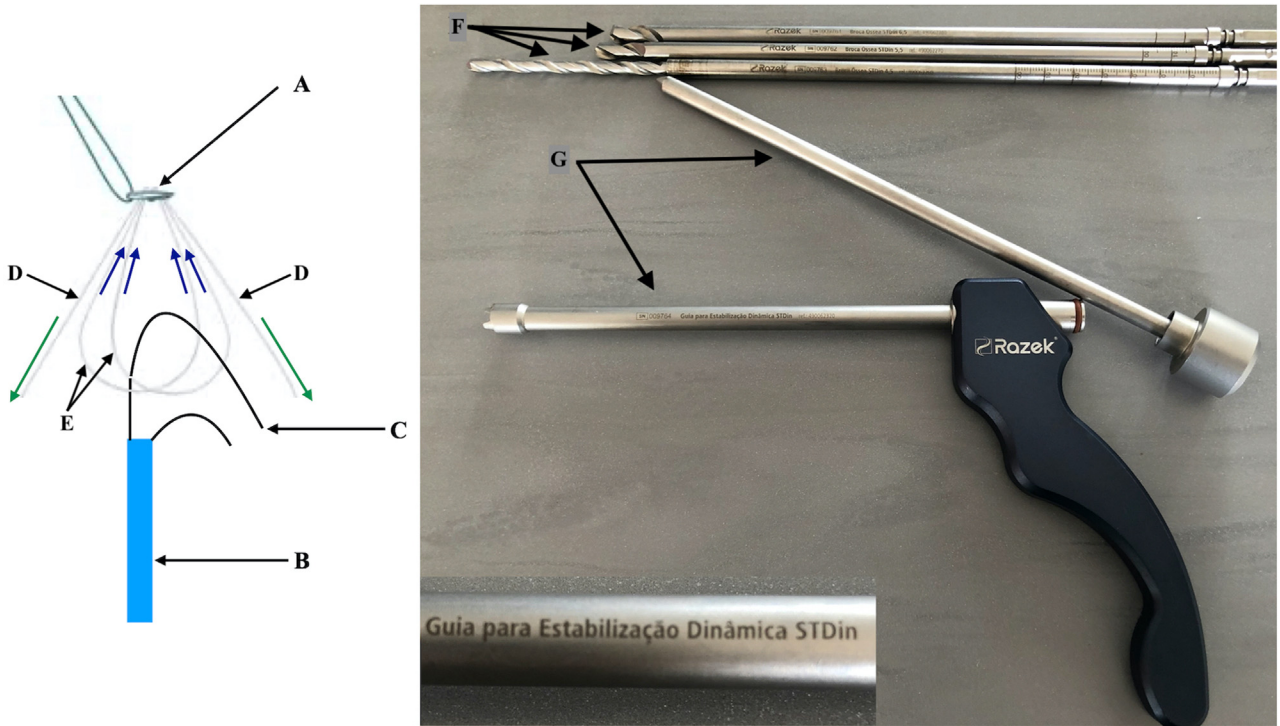


Fig 4. (A) adjustable-loop device. (B) Long head of biceps. (C) High-resistance wire. (D) Terminal adjustable-loop device wires. (E) adjustable-loop device loops. (F) Drills. (G) Dynamic anterior stabilization guide : Drills: 4.5-mm drill for fastfit-Button and 2 drills to enlarge insertion hole, 5.5 mm and 6.5 mm, for wider biceps diameters.

reconstruction (Fig 10, Video 1). Pearls and pitfalls of the described procedure are presented in Table 1.

Discussion

The sling effect is the main stabilizer of the shoulder in the Bristow and Latarjet procedures. It is responsible for 51% to 77% of the shoulder stabilization,

depending on the upper-limb position.¹³ DAS of the shoulder provides the same soft-tissue benefits as the Bristow and Latarjet procedures associated with labral reconstruction in the Bankart procedure, presenting a triple soft-tissue block.

The key goals achieved using the described procedure are tension to the inferior part of the subscapularis during abduction and external rotation, a direct block effect of the LHB in its new position, and labral

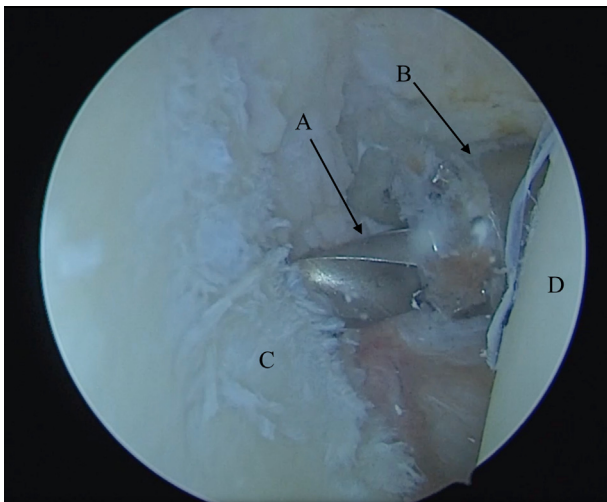


Fig 5. Insertion of 4.5-mm drill (A) and dynamic anterior stabilization guide (B), with optics through posterior portal glenoid (C), humeral head (D).

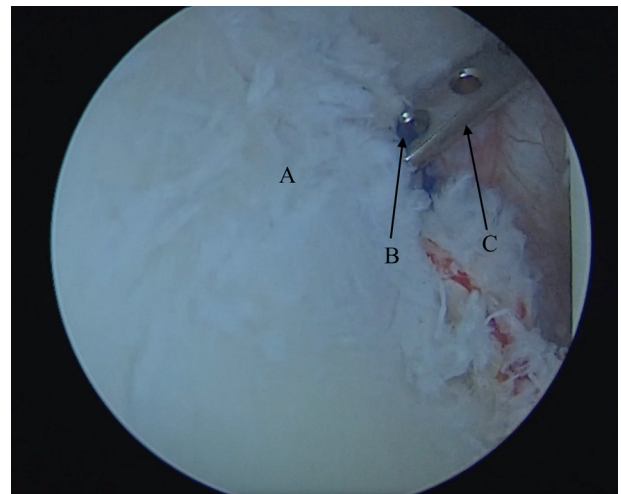


Fig 6. Glenoid (A). No. 0 guide nylon (B). Perforated Kirschner (C). Optics through posterior portal.

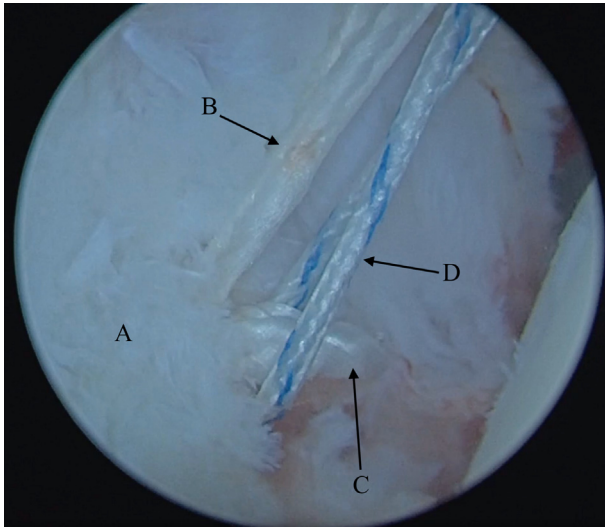


Fig 7. Glenoid (A), terminal adjustable-loop device wires (B), EndoButton loops (C), and high-resistance wire (D), with optics through posterior portal.

reconstruction. This procedure changes the shoulder kinematics similar to the Latarjet procedure but with no bone block.¹⁷ Some biomechanical studies have shown that at end-range position for abduction and external rotation of the shoulder the capsule, conjoined tendon's direct block and the sling effect can be the only responsible for the stability on the Latarjet procedure.¹³

A similar triple soft-tissue block was described using the conjoined tendon⁸ instead of the LHB. However, because of the large transverse area of the conjoined tendon, the interference screw needs to have a greater diameter, as does its introduction hole.

In other procedures involving the LHB, interference screws were used for fixation; however, some

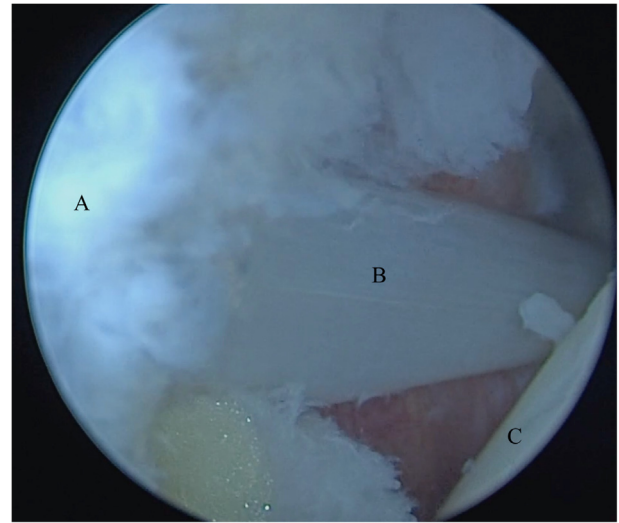


Fig 9. Glenoid (A), long head of biceps (B), and humeral head (C), with optics through posterior portal.

drawbacks of using interference screws are possible osteolysis and a smaller tendon–bone marrow contact area.¹⁸⁻²⁰ Prior studies have used suture anchors¹⁶; however, suture anchors will present with inferior load to failure compared with the adjustable-loop device for many applications, and it is rational to think the same way about DAS. In addition, anchors are less predictable for changing LHB tendon tension. Insertion of 20 mm of the LHB tendon within the bone is desirable to keep its suitable tension.¹⁵ Table 2 presents a comparison between fixation methods.

For Bristow procedures medialization of the graft can increase recurrence rates of shoulder instability. Once DAS presents a similar biomechanic of Bristow

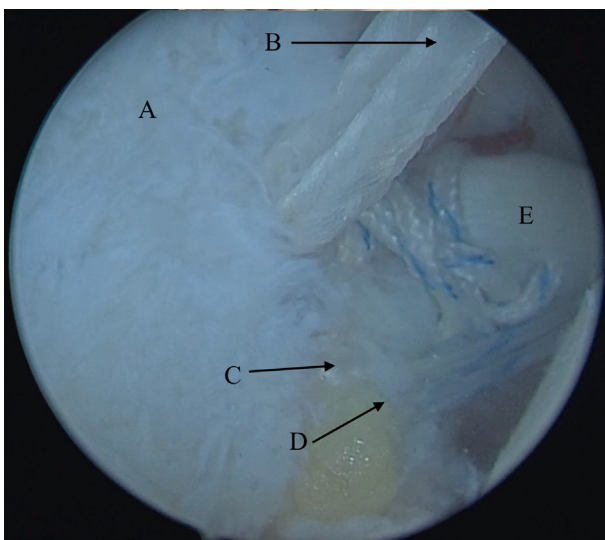


Fig 8. Glenoid (A), terminal adjustable-loop device wires (B), EndoButton loops (C), high-resistance wire (D), and long head of biceps (E), with optics through posterior portal.




Fig 10. Suturing of labrum, with optics through posterior portal.

Table 1. Pearls and Pitfalls

	Pearls and Pitfalls
Anterolateral portal	The ideal point is 45° anterior to the scapular axis, just over the biceps deflection, guided by an 18-gauge needle in an intra-articular view, with the scope in the posterior portal.
Anteroinferolateral portal	The ideal point is through the subscapularis tendon, near its insertion in the humerus, in line with the humeral head equator, guided by an 18-gauge needle in an intra-articular view, with the scope in the posterior portal.
LHB cutting	An anteroinferolateral portal or standard anterior portal is used. Do not cut so proximal, do that where the elliptical diameters seem to be more similar to those of the LHB.
Assessment of superior portion of pectoralis tendon	The scope is inserted in the anteroinferolateral portal, in the subdeltoid space, in the direction of the pectoralis major insertion. The bursa is carefully shaved; the LHB emerges from the bicipital tunnel under the superior portion of the pectoralis major, beneath the short head. Special care is needed for bleeding in this region because vessels can be close.
Insertion point	Just drill the tunnel after the LHB tendon is pulled out. The guidewire is inserted just over the LHB, through the subscapularis split, with no cannula. The guidewire is inserted just medial to the glenoid rim at the 3-o'clock position, similar to anchor insertion. The hole can extend to the glenoid. A cannula is not used.
Guide	The guide is inserted just medial to the glenoid rim at the 3-o'clock position flush with the articulation, similar to anchor insertion. A cannula is not used in this moment.
Tunnel diameter	The diameter needs to be the same size as the LHB tendon. More suitable diameters can be chosen according the biceps diameter.
Anchor insertion	Once the space is small, preference should be given to soft-tissue anchors. A cannula is used through the regular anterior portal as in regular Bankart reconstruction to access the labrum.

LHB, long head of biceps.

procedure a more lateral position for insertion of the LHB, as suggested on this paper, will allow better shoulder stability.²¹

There is no consensus on the role of the dynamic stabilizers of the shoulder. Thus far, all biomechanical studies using cadavers have rendered ineffective dynamic assessments. Labral proprioception can also play an important and neglected role in shoulder stability.²² We suggest that the described procedure and similar procedures^{14-16,23} will add not just biomechanical stabilization²⁴ but also tendon proprioception of the LHB; moreover, the subscapularis split can play an important role in shoulder stabilization.

Some authors have described a similar technique but with different, more demanding surgical steps and no attachment of the labrum.²³ Reattaching the labrum is essential to our technique, and proprioception is one of the pillars behind the success of this technique; no preservation of the labrum and capsule can result in higher redislocation rates.²²

Similarly to other authors, we believe that the LHB is a residual structure derived from the ancient coracoid bone in quadrupeds.^{12,25} In bipeds, this bone also followed the natural axis of the biceps originating from the coracoid process with 90° rotation of the original coracoid bone.^{12,25} Some primates do not present an LHB similar to that in humans, whereas in some, the LHB can even originate on the pectoralis major insertion or in the humeral head.^{26,27} Indeed, the real kinematic importance of the LHB is still controversial.

The described procedure will not substitute for bone block procedures when more than 20% of glenoid bone loss is present; instead, it will add more stability to the current soft-tissue procedures in the presence of smaller amounts of bone loss. It could also be useful in athletes and high-demand patients.^{1,4,7} Advantages and disadvantages of this procedure compared with other DAS procedures are presented in Table 2.

When performing the described procedure, it is possible to incorporate other procedures, such as

Table 2. Comparison Between Fixation Methods

	DAS Fixation		
	Interference Screw	Anchor	Adjustable-loop device
Intraoperative complications	Fracture of anterior glenoid, loosening of fixation of interference screw	Lower bicipital tension, Popeye deformity	Possible neurologic lesion if surgeon does not drill hole parallel to glenoid equator
Postoperative complications	Osteolysis	None	None
Fixation	Strong	Intermediate	Strong
Biological integration	Intermediate	Intermediate	Better

DAS, dynamic anterior stabilization.

remplissage. In addition, in case of failure of this procedure, it is possible to apply the Bristow or Latarjet procedure. There is a possibility of LHB tendon rupture, glenoid fracture, and cyst formation, although we have never observed these conditions. The surgical time to access the superior insertion of the pectoralis major is longer with this procedure than with the Bankart procedure, as is arthroscopic training. If the LHB is pathologic and presents areas of disruption, it can also be oversized in its intra-articular portion. In this case, opening the intertubercular ligament can be an option to release the LHB. In our opinion, this surgical procedure and similar procedures^{15,23} can fit exactly in the gray zone between the Bankart and Bristow-Latarjet procedures.²⁵

References

- DeFroda S, Bokshan S, Stern E, Sullivan K, Owens BD. Arthroscopic Bankart repair for the management of anterior shoulder instability: Indications and outcomes. *Curr Rev Musculoskelet Med* 2017;10:442-451.
- Beran MC, Donaldson CT, Bishop JY. Treatment of chronic glenoid defects in the setting of recurrent anterior shoulder instability: A systematic review. *J Shoulder Elbow Surg* 2010;19:769-780.
- Itoi E, Lee SB, Berglund LJ, Berge LL, An KN. The effect of a glenoid defect on anteroinferior stability of the shoulder after Bankart repair: A cadaveric study. *J Bone Joint Surg Am* 2000;82:35-46.
- Burkhart SS, De Beer JF. Traumatic glenohumeral bone defects and their relationship to failure of arthroscopic Bankart repairs: Significance of the inverted pear glenoid and the humeral engaging Hill-Sachs lesion. *Arthroscopy* 2000;16:677-694.
- Lo IK, Parten PM, Burkhart SS. The inverted pear glenoid: An indicator of significant glenoid bone loss. *Arthroscopy* 2004;20:169-174.
- García JC, Amaral FM, Belchior RJ, Carvalho LQ, Markarian GG, Montero EFS. Comparative systematic review of fixation methods of the coracoid and conjoined tendon in the anterior glenoid to treat anterior shoulder instability. *Orthop J Sports Med* 2019;7, 2325967118820539.
- Shaha JS, Cook JB, Song DJ, et al. Redefining "critical" bone loss in shoulder instability: Functional outcomes worsen with "subcritical" bone loss. *Am J Sports Med* 2015;43:1719-1725.
- Boileau P, Bicknell RT, Fegoun ABE, Chuinard C. Arthroscopic Bristow procedure for anterior instability in shoulders with a stretched or deficient capsule: The "belt-and-suspenders" operative technique and preliminary results. *Arthroscopy* 2007;23:593-601.
- Giphart JE, Florian EF, Dewing CB, Torry MR, Millett PJ. The long head of the biceps tendon has minimal effect on in vivo glenohumeral kinematics. A biplane fluoroscopy study. *Am J Sports Med* 2012;40:202-212.
- Kuarm VP, Satkum K, Balasubramaniam P. The role of the long head of biceps brachii in the stabilization of the head of the humerus. *Clin Orthop Relat Res* 1989;244:172-175.
- García JC, Cardoso AM, Mello MBD. Arthroscopic long head biceps tenodesis in coracoid associated with its transfer to the conjoined tendon. *Acta Shoulder Elbow Surg* 2017;2:7-10.
- García JC, Nunes CV, Raffaelli MP, et al. Long head of biceps a vestigial structure? *Acta Shoulder Elbow Surg* 2017;2:22-27.
- Yamamoto N, Steinmann SP. The biomechanics of the Latarjet reconstruction: Is it all about the sling? *Oper Tech Sports Med* 2019;27:49-54.
- García JC, Belchior RJ, Mello MBD, Cardoso AM. The long head of the biceps Bristow-Bankart procedure for anterior shoulder instability. *Arthrosc Tech* 2019;8: e1185-e1191.
- Collin P, Lädermann A. Dynamic anterior stabilization using the long head of the biceps for anteroinferior glenohumeral instability. *Arthrosc Tech* 2018;7:e39-e44.
- Azevedo CC, Angelo AC. All-suture anchor dynamic anterior stabilization produced successful healing of the biceps tendon: A report of 3 cases. *JBJS Case Connect* 2021;11:e20.00149.
- Barrett Payne W, Kleiner MT, McGarry MH, Tibone JE, Lee TQ. Biomechanical comparison of the Latarjet procedure with and without a coracoid bone block. *Knee Surg Sports Traumatol Arthrosc* 2016;24:513-520.
- Balestro JC, Young AM, Cristobal M, Walch G. Graft osteolysis and recurrent instability after the Latarjet procedure performed with bioabsorbable screw fixation. *J Shoulder Elbow Surg* 2015;24:711-718.
- Buchholz A, Martetschläger F, Siebenlist S, et al. Biomechanical comparison of intramedullary cortical button fixation and interference screw technique for subpectoral biceps tenodesis. *Arthroscopy* 2013;29:845-853.
- Potapov A, Laflamme YG, Gagnon S, Canet F, Rouleau DM. Progressive osteolysis of the radius after distal biceps tendon repair with the bioabsorbable screw. *J Shoulder Elbow Surg* 2011;20:819-826.
- Hovellius L, Körner L, Lundberg B, et al. The coracoid transfer for recurrent dislocation of the shoulder. Technical aspects of the Bristow-Latarjet procedure. *J Bone Joint Surg Am* 1983;65:926-934.
- Tsuda Y, Amako M, Hirahara Y, Kawaguchi M. Shoulder joint proprioception for patients with traumatic shoulder instability compared to normal subjects. *J Shoulder Elbow Surg* 2018;27:1537-1538.
- Tang J, Zhao J. Arthroscopic transfer of the long head of the biceps brachii for anterior shoulder instability. *Arthrosc Tech* 2017;6:e1911-e1917.
- Mehl J, Otto A, Imhoff FB, et al. Dynamic anterior shoulder stabilization with the long head of the biceps tendon: A biomechanical study. *Am J Sports Med* 2019;47:1441-1450.
- Luo ZX. Origin of the mammalian shoulder. In: Dial KP, Shubin NH, Brainerd EL, eds. *Great transformations: Major events in the history of vertebrate life*. Chicago: The University of Chicago Press, 2015;167-187.
- Kemp TS. *The origin and evolution of mammals*. Oxford: Oxford University Press, 2005.
- Diogo R, Wood B. *Comparative anatomy and phylogeny of primate muscles and human evolution*. Boca Raton, FL: CRC Press, 2012.