



Published in final edited form as:

J Pediatr Surg Case Rep. 2020 January ; 52: . doi:10.1016/j.epsc.2019.101356.

Necrotizing enterocolitis following diazoxide therapy for persistent neonatal hypoglycemia

Christina M. Theodorou^{*}, Shinjiro Hirose

University of California, Davis Medical Center. Department of Pediatric General, Thoracic and Fetal Surgery, USA

Abstract

Recalcitrant neonatal hypoglycemia poses a treatment challenge for clinicians. When a patient's hypoglycemia does not respond to dextrose infusion, several medication options are available, including diazoxide(1,2). Several side effects of diazoxide are described in the literature, including fluid retention with the risk of development of congestive heart failure(3,4). We describe a case of necrotizing enterocolitis in a patient with Beckwith-Wiedemann Syndrome with persistent neonatal hypoglycemia who was treated with increasing doses of diazoxide.

1. Introduction

Persistent neonatal hypoglycemia is often seen in conjunction with hyperinsulinemia [1]. In these patients, the hypoglycemia persists despite continuous intravenous glucose infusion. One of the mainstays of treatment of this condition is diazoxide, a pancreatic β -cell K-ATP channel agonist. The mechanism of action involves inhibition of insulin secretion, and thus this medication has some success in treating hyperinsulinemic hypoglycemia [1,2]. Diazoxide doses generally start low, at 5 mg/kg/day divided into twice or thrice daily dosing. The dose can be escalated up to 20 mg/kg/day [1]. At higher doses, the benefits of therapy must be balanced with the risk of known side effects such as fluid retention [3]. In severe cases, fluid retention can result in congestive heart failure even in infants without predisposing cardiac disease [3]. There are several case reports describing these side effects in neonatal patients [2–4]. We present a case of an infant with neonatal hypoglycemia who was treated with escalating doses of diazoxide resulting in necrotizing enterocolitis, which resolved following discontinuation of diazoxide.

This is an open access article under the CC BY-NC-ND license (<http://creativecommons.org/licenses/by-nc-nd/4.0/>).

^{*}Corresponding author. University of California, Davis Medical Center. 2335 Stockton Boulevard Room 5107, Sacramento, CA, 95817, USA. c.theodorou@ucdavis.edu (C.M. Theodorou).

Authorship

All authors attest that they meet current ICMJE criteria for Authorship. CT, SH.

Declaration of competing interest

CT: There is no conflict of interest, see funding disclosure for NIH financial support.

There are no conflicts of interest and the following authors have no financial disclosure: SH.

Patient consent

The consent to publish the case report was not obtained. This report does not contain any personal information that could lead to the identification of the patient.

2. Case report

The patient is an infant born at 35 weeks and 3 days of gestation with a birthweight of 3050 g via Caesarian section for decreased fetal movement. At birth he was noted to have respiratory distress, decreased tone, macroglossia, hypoglycemia, and thrombocytopenia. An endocrinology consultation was obtained and he was found to have Beckwith-Wiedemann Syndrome. The patient's hypoglycemia was initially treated with dextrose-containing intravenous fluids. Testing included insulin levels, growth hormone, β -hydroxy-butyrate, and cortisol levels. Glucose levels remained low despite supplementation, with insulin levels found to be appropriately suppressed, and normal β -hydroxy-butyrate and cortisol levels, suggesting nonketotic hypoinsulinemic hypoglycemia. On day of life 17 the patient was started on diazoxide at 3 mg/kg/day divided into three doses. The dose was gradually increased to 16 mg/kg/day over the following eleven days due to persistent hypoglycemia (Fig. 1).

On day of life 32, the patient developed progressive edema, increased abdominal distention, increased work of breathing, decreased urine output, and hyponatremia. Due to concern for diazoxide toxicity, the medication was discontinued. Abdominal X-rays showed pneumatosis intestinalis and an abdominal ultrasound showed portal venous gas, and a diagnosis of necrotizing enterocolitis was made. The patient was placed on bowel rest and started on cefotaxime, metronidazole, and ampicillin for 10 days. Serial abdominal imaging showed improving pneumatosis, and his necrotizing enterocolitis resolved without surgical intervention.

3. Discussion

This is the first report in the literature of necrotizing enterocolitis following diazoxide administration. Previously reported side effects of diazoxide include fluid retention, hyponatremia, congestive heart failure, and respiratory failure [2–4]. Our experience with this patient suggests necrotizing enterocolitis as a possible side effect of diazoxide therapy in the neonatal period given the onset of symptoms coinciding with escalating doses of diazoxide, and the subsequent gradual resolution following discontinuation of diazoxide. Necrotizing enterocolitis has been previously reported as a side effect in children who had been treated with octreotide for congenital hyperinsulinemia not responsive to diazoxide [5,6]. In those cases, the necrotizing enterocolitis occurred within weeks to months of initiation of octreotide therapy and was thought to be a result of a dose-dependent reduction in splanchnic perfusion. Octreotide is thought to work by hyperpolarization of the β -cell membrane and subsequent inhibition of insulin secretion. In the case of diazoxide, given its mechanism of action on β -cell potassium channels, it is less clear how it would result in necrotizing enterocolitis, although there remains the possibility that, in a similar manner to octreotide, splanchnic blood flow is diminished. Interestingly, in two of the reported cases of necrotizing enterocolitis following octreotide administration, the patients had previously been treated with diazoxide as well [5,7].

4. Conclusion

We report the development of necrotizing enterocolitis following escalating diazoxide doses, with subsequent resolution following discontinuation of the drug, suggesting necrotizing enterocolitis as a potential side effect of high-dose diazoxide therapy in the neonatal period. Consideration should be given to this diagnosis when patients decompensate on diazoxide therapy. Further research is required to elucidate the pathophysiology of this adverse effect.

Acknowledgments

Funding

The project described was supported by the National Center for Advancing Translational Sciences, National Institutes of Health, through grant number UL1 TR001860 for author CT. The content is solely the responsibility of the authors and does not necessarily represent the official views of the NIH.

References

- [1]. Kane C, Lindley KJ, Johnson PR, et al. Therapy for persistent hyperinsulinemic hypoglycemia of infancy. Understanding the responsiveness of beta cells to diazoxide and somatostatin. *J Clin Investig* 1997;100(7):1888–93. [PubMed: 9312191]
- [2]. Abu-osba YK, Manasra KB, Mathew PM. Complications of diazoxide treatment in persistent neonatal hyperinsulinism. *Arch Dis Child* 1989;64(10). 1496–500. [PubMed: 2684032]
- [3]. Silvani P, Camporesi A, Mandelli A, Wolfler A, Salvo I. A case of severe diazoxide toxicity. *Paediatr Anaesth* 2004;14(7):607–9. [PubMed: 15200661]
- [4]. Tas E, Mahmood B, Garibaldi L, Sperling M. Liver injury may increase the risk of diazoxide toxicity: a case report. *Eur J Pediatr* 2015;174(3):403–6. [PubMed: 25618267]
- [5]. Hawkes CP, Adzick NS, Palladino AA, De león DD. Late presentation of fulminant necrotizing enterocolitis in a child with hyperinsulinism on octreotide therapy. *Horm Res Paediatr* 2016;86(2):131–6. [PubMed: 26867223]
- [6]. Reck-burneo CA, Parekh A, Velcek FT. Is octreotide a risk factor in necrotizing enterocolitis? *J Pediatr Surg* 2008;43(6):1209–10. [PubMed: 18558210]
- [7]. Alsaedi AA, Bakkar AA, Kamal NM, Althobiti JM. Late presentation of necrotizing enterocolitis associated with rotavirus infection in a term infant with hyperinsulinism on octreotide therapy: a case report. *Medicine (Baltim)* 2017;96 (40):e7949.

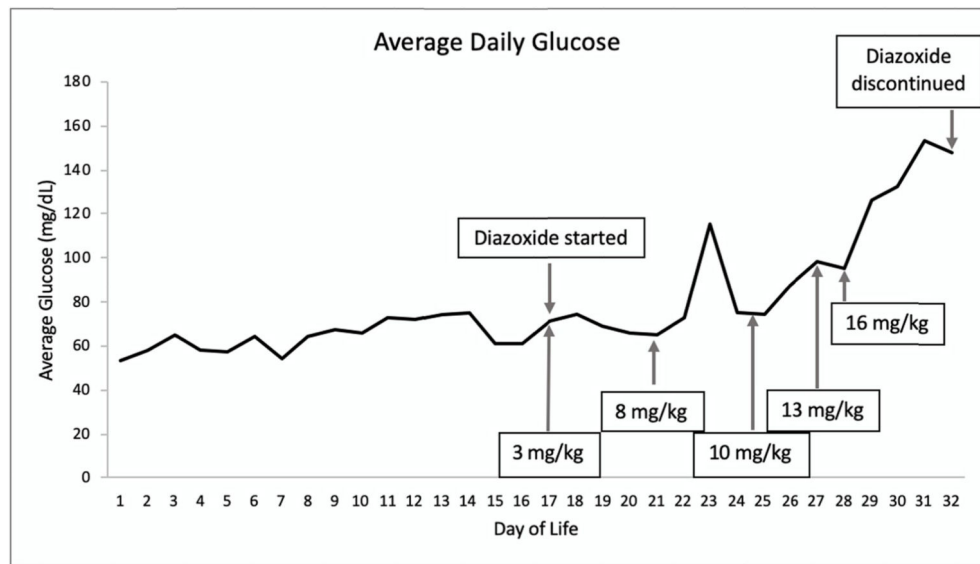


Fig. 1. Daily Average Glucose by Day of Life. Boxes display daily total diazoxide dose, divided into 3–4 daily doses.
Note: boxes display daily total diazoxide dose, divided into 3–4 daily doses.