



Contents lists available at ScienceDirect

International Journal of Surgery Case Reports

journal homepage: www.casereports.com

Perforated duodenal diverticulum: Surgical treatment and literature review

Vitor Costa Simões^{a,*}, Bruno Santos^a, Sara Magalhães^b, Gil Faria^a, Donzília Sousa Silva^a, José Davide^a^a Department of Surgery, Centro Hospitalar do Porto, Porto, Portugal^b Department of Radiology, Centro Hospitalar do Porto, Porto, Portugal

ARTICLE INFO

Article history:

Received 18 May 2014

Accepted 15 June 2014

Available online 19 June 2014

Keywords:

Perforation
Duodenum
Diverticulum
Surgery
Complication
Treatment

ABSTRACT

INTRODUCTION: Duodenum is the second most frequent location for a diverticulum in the digestive tract. Complications are rare and perforation was only reported in less than 200 cases.**PRESENTATION OF CASE:** A 79-year-old female was admitted to Emergency Department with abdominal pain and vomiting for the last 24 h. A CT scan was performed and moderated extra-luminal air was identified. During surgery a fourth portion perforated duodenal diverticulum was diagnosed and duodenal resection was performed.**DISCUSSION:** First reported in 1710, the incidence of duodenal diverticula can be as high as 22%. Nevertheless complications are extremely rare and include haemorrhage, inflammation, compression of surrounding organs, neoplastic progression, cholestasis and perforation.

As perforations are often retroperitoneal, symptoms are nonspecific and rarely include peritoneal irritation, making clinical diagnose a challenge.

CT scan will usually present extra-luminal retroperitoneal air and mesenteric fat stranding, providing clues for the diagnosis.

Although non-operative treatment has been reported in selected patients, standard treatment is surgery and alternatives are diverse including diverticulectomy or duodenopancreatectomy.

CONCLUSION: Perforated diverticula of the fourth portion of the duodenum are extremely rare and current evidence still supports surgery as the primary treatment modality.© 2014 The Authors. Published by Elsevier Ltd. on behalf of Surgical Associates Ltd. This is an open access article under the CC BY-NC-ND license (<http://creativecommons.org/licenses/by-nc-nd/3.0/>).

1. Introduction

First reported by Chomel in 1710, the incidence of duodenal diverticula (DD) can be as high as 22% and complications can be estimated at 0.03% per year.¹ Duodenum is the second most common site for diverticula in the alimentary tract being the second portion the most frequent location.^{2–4}

Perforation is a rare complication of DD, only reported in 162 cases,⁵ but also the most serious one,² representing a diagnostic challenge,⁶ and a difficult surgical problem.

Few cases of perforated third and fourth portions of the DD are reported in literature and so their diagnosis, management and outcomes are based on those reports.

We present a rare case of perforated diverticulum from the fourth part of the duodenum and its successful surgical management.

2. Presentation of case

A 79 years old female patient with dementia, hypertension, mitral insufficiency and paroxysmal atrial fibrillation, is admitted to the Emergency Department with abdominal pain and vomiting for the last 24 h.

On arrival her vital signs showed auricular temperature of 36 °C, heart rate of 73/min and blood pressure of 125/65 mm Hg. Physical examination elicited pain on palpation of the four quadrants without signs of peritoneal irritation. Blood tests showed 28,040 white blood cells/ μ L with 88% neutrophils in the differential count, haemoglobin value of 13.1 g/dL, platelets count of 259,000/ μ L, C-reactive protein of 100.23 mg/L, creatinine of 0.94 mg/dL, urea of 42 mg/dL, lactate dehydrogenase of 368 U/L, amylase of 107 U/L, with normal liver tests, lipase level and arterial blood gases.

* Corresponding author at: Department of Surgery, Centro Hospital do Porto, Largo Prof. Abel Salazar, 4099-001 Porto, Portugal. Tel.: +351 934140762; fax: +351 222053218.

E-mail address: costa.simoese@gmail.com (V. Costa Simões).

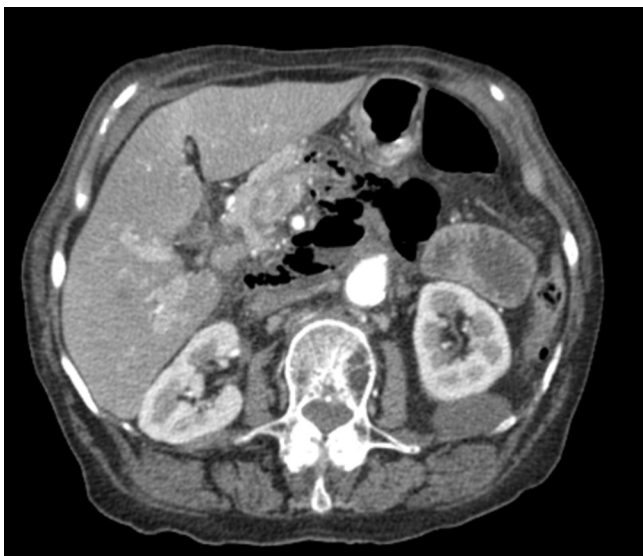

Fig. 1. CT scan evidencing a retroperitoneal perforation with retroperitoneal free air.

Abdominal X-ray showed no intra-peritoneal free air and computer tomography of the abdomen showed moderated extraluminal retroperitoneal gas (Fig. 1).

An emergent laparotomy was performed. After mobilization of the Treitz angle pus and biliary content was found and further mobilization of the duodenum showed a perforated diverticulum in the fourth portion of the duodenum (Fig. 2), accompanied by extensive retroperitoneal phlegmon. With these findings we carried out a partial duodenectomy of portions 3 and 4 with end-to-side hand-sewed single-layer duodenojejunostomy (Figs. 3 and 4). The post-operative course was uneventful and the patient was discharged 12 days after surgery.

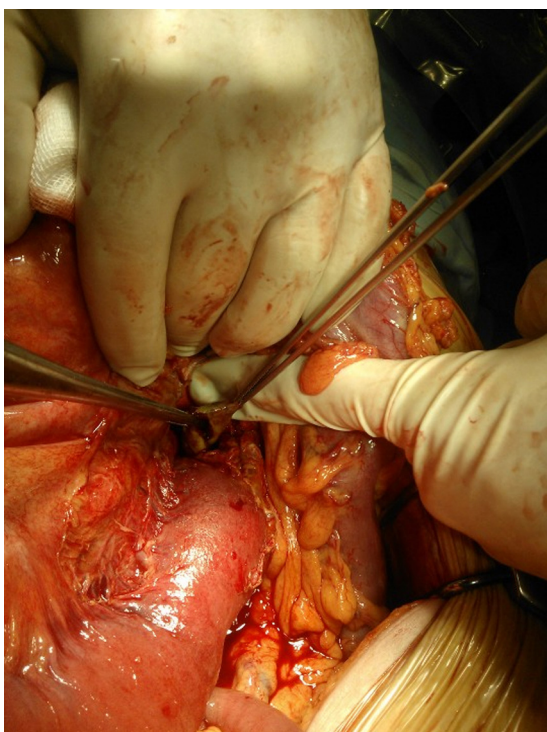


Fig. 2. Perforated diverticulum of the fourth part of the duodenum.

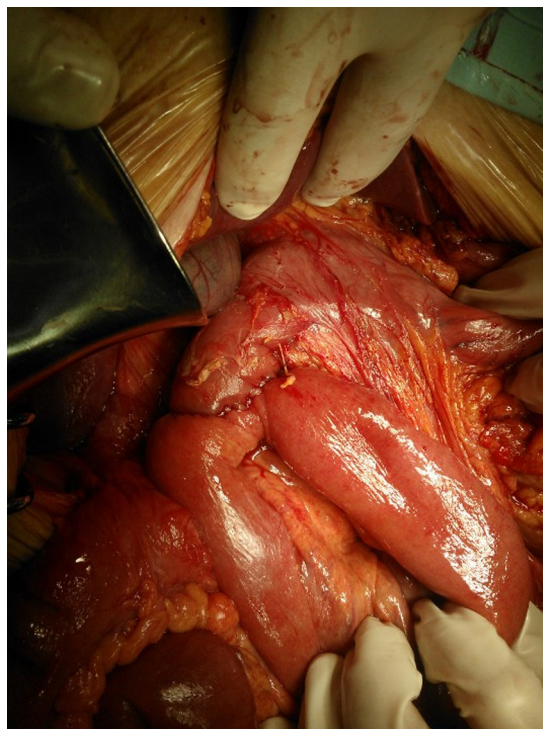

Fig. 3. Duodeno-jejunostomy.

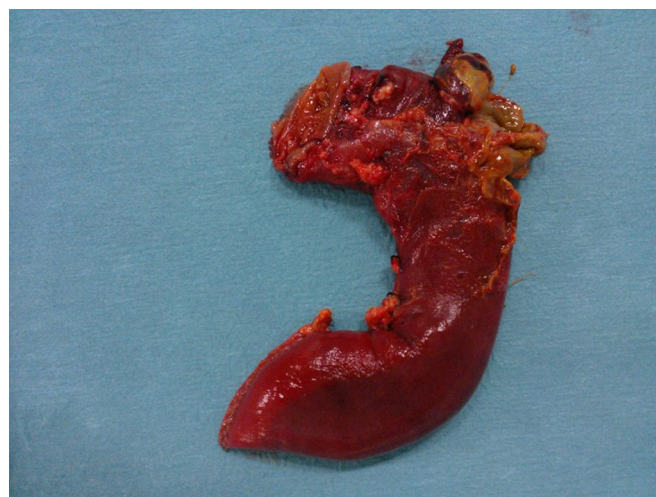


Fig. 4. Surgical specimen.

3. Discussion

DD can be congenital and acquired, with the latter being most common. Congenital diverticula contain all layers of the duodenal wall and acquired ones represent pulsion diverticula due to a protrusion of mucosa, *muscularis* mucosa and submucosa through a wall weakness, being the papillae one of those and explaining why the area within 2.5 cm of the ampullae of Vater is the predilection site for such pathology.^{1,7,8}

Haemorrhage, inflammation, compression of surrounding organs, neoplastic progression,⁹ cholestasis and perforation are rare complications of DD, being the last one the least frequent, only reported in 162 cases,⁵ but also the most serious one.² Causes of perforation are multiple and include diverticulitis, enterolithiasis,

ulceration, foreign body, trauma, iatrogenic perforation during an ERCP and most frequently ischaemia due to distention related to food retention inside the diverticulum.^{5,10}

As most perforations are retroperitoneal,¹⁰ symptoms are usually nonspecific including right upper abdominal pain associated with nausea and vomiting,⁶ and rarely include peritoneal irritation.³ Blood samples are also unspecific and elevated pancreatic tests might be present due to the inflammation in the vicinity of the diverticulum.¹ Retroperitoneal contamination leads to retroperitoneal abscess formation and sepsis.

Conventional radiological examination will show no abnormalities in half the patients with duodenal perforation.¹¹ Upper abdominal series can diagnose the DD and if extraversion of contrast is observed confirms its perforation. Ultrasound studies are rarely informative. Abdominal CT, usually requested without any hint of suspicion for complicated duodenal pathology,¹ will provide diagnosis. Its findings include mesenteric fat stranding, thickened bowel wall and extra-luminal retroperitoneal air.^{12,13}

Proper diagnosis and improvements in both antibiotics and intensive care explain the mortality reduction seen in last decades although it remains high, up to 13%.¹¹

In selected patients that are only mildly affected and had no evidence of impending sepsis, non-operative treatment for perforated DD is safe and a practical alternative to surgery.^{6,7} Treatment includes nasogastric suction, bowel rest, intravenous antibiotic therapy, parenteral nutrition, endoscopic cleaning of the infected pouch and combined endoscopic and percutaneous drainage of retroperitoneal abscess.^{14,15} Close clinical observation is mandatory and surgical intervention is indicated if conservative management fails.

Standard treatment for perforated DD is surgical intervention.^{6,11} Diverticulectomy with single or double-layer closure is the most frequent reported alternative if inflammation permits.¹⁵ Some cases of simple intra-abdominal drainage were also successful.^{2,16} When substantial duodenal or retroperitoneal inflammation is present, more complex procedures like duodenal diversion, pyloric exclusion, gastro-enteric anastomosis, tube duodenostomy, segmental duodenal resection or even

pylorus preserving Whipple might be adequate.^{11,15} Laparoscopic approach have also been described with good results.⁶

Surgical morbidity includes duodenal leak or fistula, abscess, iatrogenic injury to the common bile duct, acute pancreatitis and persistent sepsis. Identification of the papilla during surgery might be performed by inserting a catheter through cholecystostomy or choledochotomy.¹⁵

4. Conclusion

Third and fourth parts DD perforation is extremely rare, its diagnosis is challenging and surgical intervention is recommended. Non-operative management should be reserved for selected patients.

Conflict of interest

The authors declare that there is no conflict of interest in undertaking this article.

Funding

None.

Ethical approval

Written informed consent was obtained from the patient for publication of this case report, collecting data and accompanying images. A copy of the written consent is available for review by the Editor-in-Chief of this journal on request.

Author contributions

Vitor Costa Simões: Surgery, writing.
Bruno Santos: Surgery, writing.
Sara Magalhães: Radiologic evaluation.
Gil Faria: Surgery, revision.
Donzília Sousa Silva: Surgery, revision.
José Davide: Surgery, revision.

Key learning points

- Perforated diverticula of the fourth portion of the duodenum are rare.
- Surgery is still the primary treatment modality.

References

1. de Perrot T, Poletti PA, Becker CD, Platon A. The complicated duodenal diverticulum: retrospective analysis of 11 cases. *Clin Imaging* 2012;**36**(July–August (4)):287–94.
2. Ming TY, Feng HK, Cheng YJ, Chuan CD, Pai LT, Chi LY. Clinical challenge: diverticulitis of third and fourth portion of the duodenum with perforation. *Rev Esp Enferm Dig* 2012;**104**(March (3)):156–7.
3. Favre-Rizzo J, Lopez-Tomassetti-Fernandez E, Ceballos-Esparragon J, Santana-Cabrera L, Hernandez-Hernandez JR. Duodenal diverticulum perforated by foreign body. *Rev Esp Enferm Dig* 2013;**105**(July (6)):368–9.
4. Yeo CJ. *Shackelford's surgery of the alimentary tract*. 7th ed. Philadelphia, PA: Elsevier/Saunders; 2013.
5. Volchok J, Massimi T, Wilkins S, Curletti E. Duodenal diverticulum: case report of a perforated extraluminal diverticulum containing ectopic pancreatic tissue. *Arch Surg* 2009;**144**(February (2)):188–90.
6. Rossetti A, Christian BN, Pascal B, Stephane D, Philippe M. Perforated duodenal diverticulum, a rare complication of a common pathology: a seven-patient case series. *World J Gastrointest Surg* 2013;**5**(March (3)):47–50.
7. Thorson CM, Paz Ruiz PS, Roeder RA, Sleeman D, Casillas VJ. The perforated duodenal diverticulum. *Arch Surg* 2012;**147**(January (1)):81–8.
8. Oukachbi N, Brouzes S. Management of complicated duodenal diverticula. *J Visc Surg* 2013;**150**(June (3)):173–9.
9. Furukawa M, Izumi S, Tsukuda K, Tokumo M, Sakurai J, Mano S. Duodenal carcinoma from a duodenal diverticulum mimicking pancreatic carcinoma. *Acta Med Okayama* 2012;**66**(5):423–7.
10. Duarte B, Nagy KK, Cintron J. Perforated duodenal diverticulum. *Br J Surg* 1992;**79**(September (9)):877–81.
11. Schnueriger B, Vorbürger SA, Banz VM, Schoepfer AM, Candinas D. Diagnosis and management of the symptomatic duodenal diverticulum: a case series and a short review of the literature. *J Gastrointest Surg* 2008;**12**(September (9)):1571–6.

12. Ames JT, Federle MP, Pealer KM. Perforated duodenal diverticulum: clinical and imaging findings in eight patients. *Abdom Imaging* 2009;**34**(April (2)):135–9.
13. Pearl MS, Hill MC, Zeman RK. CT findings in duodenal diverticulitis. *AJR Am J Roentgenol* 2006;**187**(October (4)):W392–5.
14. Coulier B. Duodenal diverticulitis. *JBR-BTR* 2008;**91**(November–December (6)):271.
15. Martínez-Cecilia D, Arjona-Sanchez A, Gomez-Alvarez M, Torres-Tordera E, Luque-Molina A, Valenti-Azcarate V, et al. Conservative management of perforated duodenal diverticulum: a case report and review of the literature. *World J Gastroenterol* 2008;**14**(March (12)):1949–51.
16. Chen CF, Wu DC, Chen CW, Hsieh JS, Chen CY, Wang JY. Successful management of perforated duodenal diverticulitis with intra-abdominal drainage and feeding jejunostomy: a case report and literature review. *Kaohsiung J Med Sci* 2008;**24**(August (8)):425–9.

Open Access

This article is published Open Access at sciedirect.com. It is distributed under the [IJSCR Supplemental terms and conditions](#), which permits unrestricted non commercial use, distribution, and reproduction in any medium, provided the original authors and source are credited.