

Case Report

Seizure-induced thoracolumbar burst fractures – Not to be missed

Aaron S. Robichaud, Tricia K. Barry, Sean P. Barry*

Division of Neurosurgery, Dalhousie University, Division of Neurosurgery, Halifax Infirmary, 1796 Summer Street, Halifax, NS, Canada, B3H 3A7

ARTICLE INFO

Article history:

Received 13 September 2019

Received in revised form 3 December 2019

Accepted 14 December 2019

Available online 20 December 2019

Keywords:

Seizure

Thoracic burst fracture

Lumbar burst fracture

Diagnosis

ABSTRACT

While rare, post-ictal thoracolumbar burst fractures are commonly missed due to confounding factors, resulting in delayed treatment and the potential for serious neurological deficits. This paper serves as a call for a high-degree of clinical suspicion when treating post-ictal patients to ensure they undergo a focused neurological examination of the lower extremities. If unresponsive/uncooperative, spinal precautions should be maintained until the spine can be cleared clinically or radiographically. In all events, if the patient is complaining of musculoskeletal pain possibly originating from the spine, radiographic evaluations are warranted to prevent possible deficits caused by a missed thoracolumbar fracture.

© 2019 The Authors. Published by Elsevier Inc. This is an open access article under the CC BY-NC-ND license (<http://creativecommons.org/licenses/by-nc-nd/4.0/>).

1. Introduction

Fractures are a well-known and common result of a violent and traumatic generalized tonic-clonic (GTC) seizures [1]. It is also common that the identification of fractures is often delayed due to the absence of physical signs and other pressing symptoms, the result of which is a delay in treatment [2]. The literature has shown that when a GTC seizure causes a spinal fracture, they are most commonly asymptomatic compression fractures. [3] However, there are rare reports of post-ictal thoracolumbar burst fractures and when these fractures go undiagnosed and treatment is delayed, serious neurological deficits can result [4–10]. We add to this literature, reporting on two recent cases of lumbar burst fractures following a GTC seizure, with a delay to diagnosis resulting in deficits, which strongly supports the call for maintaining a high degree of clinical suspicion post-seizure to eliminate potentially devastating fracture type.

2. Background

2.1. Case 1

A 71-year-old male presented to the emergency department (ED) following a GTC seizure. He was intubated for combativeness secondary to a decreased level of consciousness. A CT scan and MRI of his brain demonstrated a right sphenoid wing meningioma. He was transferred to neurosurgery.

Upon arrival, he was sedated and intubated, and admitted to the intensive care unit. On examination he was moving his legs

spontaneously and localizing with his right arm. Detailed neurological examination was deferred until he was extubated on day 2, when he was reporting bilateral calf pain and weakness in the ankles, graded 4/5 for all muscle movements. He complained of allodynia from the mid-calf to his toes. Bloodwork revealed a rise in serum creatine kinase (CK) and his weakness therefore was initially thought to be secondary to a potential myositis.

On day 5, the patient began to complain of lower back pain. On day 6 his catheter was removed, and he began to have urinary incontinence. A neurologic examination demonstrated ankle weakness, loss of pinprick sensation in the feet and perineum and absent ankle reflexes. An urgent CT scan of the lumbar spine revealed a burst fracture of L1. An MRI demonstrates compression of the conus medullaris with a high signal lesion yielding a diagnosis of conus medullaris syndrome.

The fracture was felt to be unstable and due to spinal cord compression, the patient was taken to the operating room (OR) for decompression via laminectomies from T12-L1, followed by T11 to L3 instrumented stabilization (Fig. 1a & b). He had continued weakness and urinary retention post-operatively and was mobilized with physiotherapy. He was transferred to the rehabilitation center, and on follow-up, was voiding independently and ambulating with a cane.

2.2. Case 2

A 53-year-old man presented to a local ED after a GTC seizure, and, while in the department, began to experience ascending lower extremity weakness. He had a history of seizure as a young adult associated with alcohol withdrawal, although he denied current alcohol use. He was admitted to the intensive care unit at the referring hospital and was subsequently noted to have urinary retention requiring placement of a catheter. He was also complaining of severe low back pain and on

* Corresponding author.
E-mail address: sbarry@dal.ca (S.P. Barry).

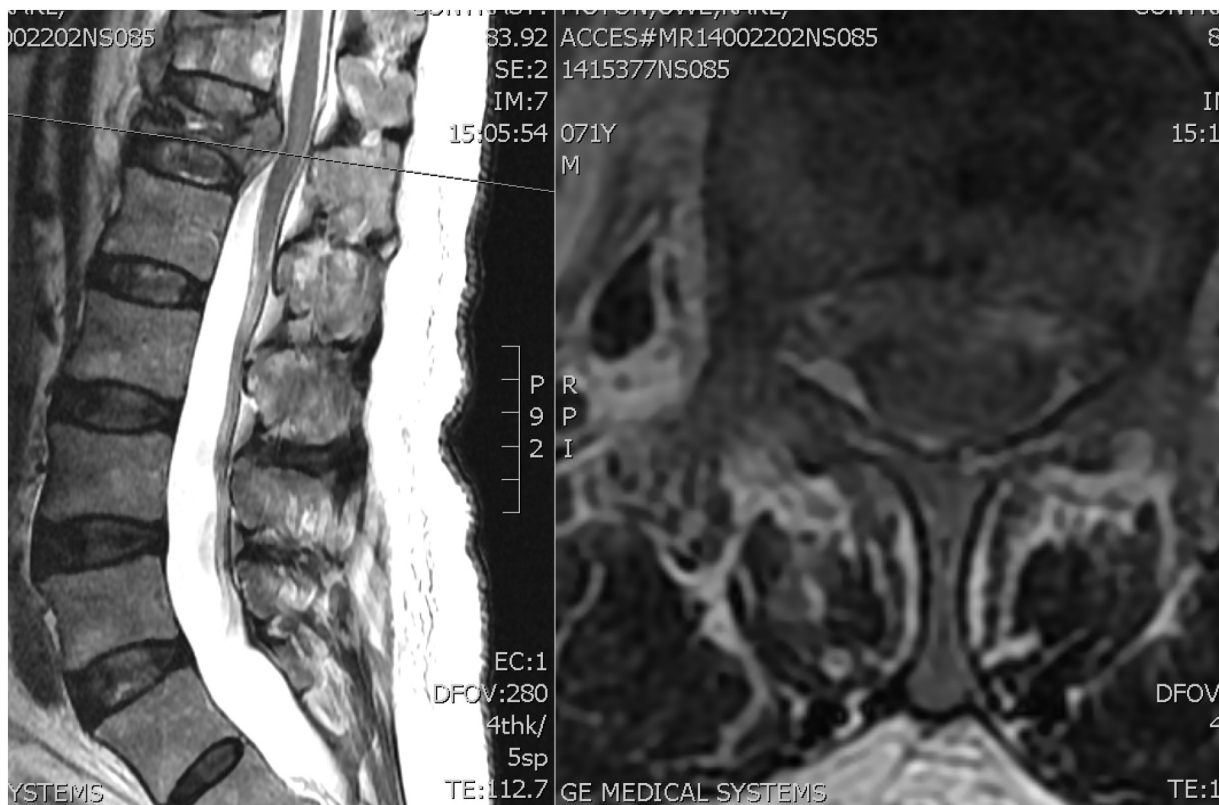


Fig. 1. a. Sagittal T2 weighted MRI of the lumbosacral spine demonstrates severe spinal canal stenosis at the L1 level from osseous retropulsion of approximately 8 mm. b. Axial T2 weighted MRI demonstrates abnormal signal intensity within the conus consistent with acute injury.

examination was found to have weakness in the legs bilaterally. On his second day following presentation, he was noted to have milder weakness in the upper extremities and was accepted by the neurology service in our tertiary center concerning for possible Guillan-Barre syndrome (GBS). At that time, an MRI of the brain and lumbar spine were pending.

Following arrival to the tertiary ED, imaging revealed an L1 burst fracture with compression of the conus medullaris and MRI of the brain was unremarkable. Examination revealed grade 0/5 weakness in the lower extremities and milder weakness in the upper extremities, worse proximally, thought to be secondary to pain. Neurology remained unsure if GBS was contributing to the symptoms but elected to proceed with an empiric trial of intravenous immunoglobulin.

Following reassessment two days after transfer, neurosurgery was consulted for an opinion and felt that the lower extremity weakness was secondary to the burst fracture given the signal intensity change within the conus on MRI. He was taken to the operating room the following day for T11 to L3 posterior decompression and instrumented stabilization (Fig. 2).

The patient remained weak post-operatively, and physiotherapy was initiated for mobilization. Further imaging was done to assess his upper extremity weakness and he was found to have bilateral scapular fractures, in addition to the L1 burst fracture. This did impair his mobility and eventually he was accepted to the spine rehabilitation center, once he was able to weight bear with his upper extremities. While admitted, he experienced ongoing lower extremity weakness. The precise etiology of his most recent seizure remained unclear.

2.3. Literature review

The occurrence of musculoskeletal injury during seizures and following GTC seizures has been known. Injuries from seizures can be caused by loss of consciousness and subsequent trauma or direct trauma because of the seizure. Injuries can range from

minor injuries, such as cutaneous lacerations or abrasions, to more serious pathologies like fractures or dislocations [1]. Patients with seizures are at higher risk for developing fractures in a number of common locations [11], and there have been reports of patients sustaining multiple fractures in different areas of the body, resulting in significant morbidity [12]. Post-ictal fractures of the spine are also found in the literature [13,14], but they are typically limited to compression fractures [3].

While the majority of spinal fractures that occur during seizures are compression fractures, reports of thoracolumbar burst fractures exist in the literature. At the time of submission, only eleven such cases have been reported [4–10,15–18]. Of these, six burst fracture cases occurred in the lumbar spine [5,7–10,15], and five in the thoracic spine [4,6,16–18]. Delay of diagnosis for post-ictal thoracolumbar fractures occurred in eight of the eleven thoracolumbar cases reviewed [4,5,7,9,15–18]. Delay can be due to lack of evidence for visible trauma distracting from apparent injuries, such as misdiagnosing weakness as Todd's paralysis [2] or slow recovery of neurologic symptoms associated with a post-ictal state. [3,4,18]. Deficits related to the fracture were noted in only four cases [7,9,10,18], while complete recovery was noted in all but one case [10]. However, this case report was published in 2015, and long-term follow-up was not available.

The literature indicates that common risks for vertebral fractures caused by seizures are increased age, osteoporosis, osteopenia, muscularity, drug withdrawal, duration and reoccurring convulsions [18]. However, the age range of patients in the 11 cases reviewed where a seizure caused a thoracolumbar burst fracture was wide, with one case at age 20 (caused by Tramadol withdrawal [18]) to the oldest at age 54 [6], and the majority between ages 35 and 45. Also, of note is that of the 11 cases reviewed, 3 occurred in females aged 35 [16], 41 [4] and 42 [15], while the other 8 occurred in males, indicating that osteopenia and osteoporosis are not a major causal factor associated with seizure induced thoracolumbar burst fractures.

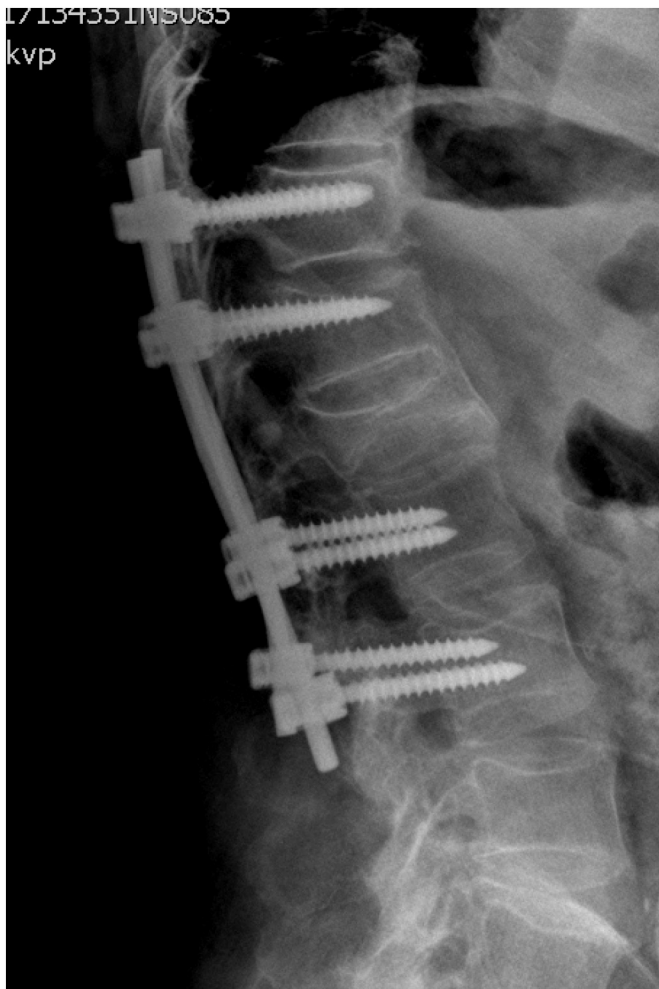


Fig. 2. Lateral x-ray of the thoracolumbar spine demonstrating post-operative stabilization from T11–L3.

3. Discussion

Relevant to the comparison of these cases and those in the literature is that there was no history of trauma or symptoms to suggest the burst fractures described above were present prior to initial presentation in either of our cases. Furthermore, the fracture characteristics on CT scan in both instances strongly suggested that these fractures were acute in nature. Neither patient had any evidence of osteopenia or osteoporosis, nor any other pertinent comorbidities which would have predisposed them to spinal fracture. This is supported by bony imaging, which in both cases, did not suggest any evidence of decreased bone mineral density. Additionally, there was no history of epilepsy in either case. This was the first seizure recorded for the first patient. The second patient had a history of alcoholism, and his medical records contained a report of a single, GTC seizure several years ago, which was attributed to alcohol withdrawal. At the time of presentation following the seizure he denied any illicit drug or alcohol use. He was thoroughly investigated following this event; however, no etiology for this second seizure was elucidated.

The two patients differed from the common trends in the literature as both were more advanced in age than the majority of reported cases, ages 53 and 71. However, there were more similarities than differences as both patients were male and both presented with neurologic deficits related to their lumbar burst fractures, but these symptoms were not identified as being related to spinal pathology until several days following admission. Moreover, both cases illustrated have commonalities as they involved the same vertebral level, L1. The imaging

characteristics of the two fractures, as well as the spinal cord injuries occurring from them, are nearly indistinguishable. The surgical management of these two cases was identical.

As seen in the 8 cases from the literature review where delay of diagnosis occurred and these additional two cases, the reasons for missed diagnosis was multifactorial. The first patient was intubated and sedated for the initial 24 h and, therefore, a complete history and physical examination was not valid. Also, a catheter was left in place for several days, precluding the identification of a neurogenic bladder until later in the course of his recovery. In addition, the presence of a known intracranial tumor dominated his diagnostic work-up, further confounding the picture for causation of his neurological features. The second patient was initially misdiagnosed with a possible GBS, thus providing an incorrect etiology for his lower extremity weakness, as is the case when a patient's weakness is misdiagnosed as Todd's Paralysis [2].

Fractures are one of the most common injuries suffered during a seizure [1]. The published literature indicates that delay of diagnosis for many types of fractures caused by the trauma of seizures, as occurred in these two cases, is unfortunately common [2,4,5,7,9,15–18]. The incidence of symptomatic spinal fracture due to the trauma caused by a seizure is low, but asymptomatic spinal fractures are relatively common, reaching up to 16% [3]. It should be noted in terms of treatment, that vertebroplasty/kyphoplasty is contraindicated in the management of unstable spinal fractures. This remains an option for treatment and management of pain in medically refractory vertebral compression fractures.

Among spinal fractures, burst fractures are rare, and thus, might not be suspected when patients present following a GTC seizure. However, given the potential for irreversible neurological injury, it is crucial to identify these injuries early so they can be appropriately treated. These two recent cases indicate that when assessing a patient post-seizure, a high index of clinical suspicion for spine injury is required. While rare, when a GTC seizure causes a thoracolumbar burst fracture, it often presents within a mixture of confounding factors and, if missed, can have devastating results.

4. Conclusion

Given the severity of deficits that can develop if injury to the spinal cord or cauda equina occurs, it is important to identify potential thoracolumbar burst fractures, so that they can be emergently treated. Their rarity and the presence of possible confounding factors, such as sedation or alternate possible diagnoses, mean that a high level of clinical suspicion is imperative post-seizure.

We recommend patients in a post-ictal state to always undergo a focused neurological examination of the lower extremities. If patients are unresponsive/uncooperative, spinal precautions should be maintained until the spine can be cleared clinically/radiographically. If a patient is complaining of musculoskeletal pain possibly originating from the spine, despite the important push for physicians to choose their diagnostic tools wisely, radiographic evaluations are warranted and provide a quick and cost-effective means of screening patients after seizures for the rare occurrence, but potentially devastating presence of a thoracolumbar burst fracture.

Grants/funding

This research did not receive any specific grant from funding agencies in the public, commercial, or not-for-profit sectors.

Declaration of interest

None for any of the three authors.

Author contributions

SB contributed to the conception of the work and provided direction and oversight. AR contributed the original research and writing of the first draft. TKB revised the work, updated the references and provided intellectual content.

References

- [1] Nguyen R, Téllez Zenteno JF. Injuries in epilepsy: a review of its prevalence, risk factors, type of injuries, and prevention. *Neurol International* 2009;1(e20):72–8.
- [2] Kristiansen B, Christensen S. Fractures of the proximal end of the humerus caused by convulsive seizures. *Injury* 1984;16(2):108–9.
- [3] Vasconcelos D. Compression fractures of the vertebrae during major epileptic seizures. *Epilepsia (Amst)* 1973;14:323–8.
- [4] McCullen GM, Brown CC. Seizure-induced thoracic burst fractures: a case report. *SPINE* 1994;19(1):77–9.
- [5] Youssef JA, McCullen GM, Brown CC. Seizure-induced lumbar burst fracture. *Spine (Phila Pa 1976)* 1995;20(11):1301–3.
- [6] Rupperecht TA, Schellinger PD, Mohr A, et al. Nocturnal vertebral fractures as the presenting feature of epileptic seizures. *Unfallchirurg* 2001;104:179–81.
- [7] Roohi F, Fox A. Burst fracture of the first lumbar vertebra and conus-cauda syndrome complicating a single convulsive seizure: a challenge of diagnosis in the emergency department. *J Emerg Med* 2006;31(4):381–5.
- [8] Mehlhorn AT, Strohm PC, Hausschildt O, et al. Seizure-induced muscle force can caused lumbar spine fracture. *Acta Chir Orthop Traumatol Cech* 2007;74(3):202–5.
- [9] Sharma A, Avery L, Novelline R. Seizure-induced lumbar burst fractures associated with conus medullaris-cauda equina compression. *Diagn Interv Radiol* 2011;17:199–204.
- [10] Napier RJ, Nolan PC. Diagnosis of vertebral fractures in post-ictal patients. *Emerg Med J* 2011;28(2):169–70.
- [11] Vestergaard P. Epilepsy, osteoporosis and fracture risk – a meta-analysis. *Acta Neurol Scand* 2005;112:277–86.
- [12] Grimaldi M, Vouaillat H, Tonetti J, et al. Simultaneous bilateral femoral neck fractures secondary to epileptic seizures: treatment by bilateral total hip arthroplasty. *Orthop Traumatol Surg Res* 2009;95(7):555–7.
- [13] Ghayem Hasankhani E, Omid-Kashani F. Multiple lumbar vertebral fractures following a single idiopathic seizure in an otherwise healthy patient; a case report. *MJIRI* 2013;27(4):233–5.
- [14] Atalar E, Gunay C, Atalar H, et al. A rarely seen multilevel thoracic vertebral fracture after a nocturnal hypoglycemic convulsion attack. *Case Rep Orthop* 2015;2015:646352 4 pages <http://dx.doi.org/10.1155/2015/646352>.
- [15] Malik SA, Mitra A, Bashir K, et al. Lumbar spine burst fracture as a result of hypoglycaemia induced seizure. *Injury Extra* 2011;42:25–8.
- [16] Alian A. Uncommon T12 burst fracture after and epileptic crisis. *Hindawi Publishing Corporation Case Rep Orthop* 2011;2011:726373 3 pages <http://dx.doi.org/10.1155/2011/726373>.
- [17] Smith RAJ, Poland N, Cope S. A seizure-induced T8 burst fracture re-presenting as an acute abdomen, *BMJ Case Rep*, 2017 published online May 12. Available from: <https://www.ncbi.nlm.nih.gov/pmc/articles/PMC5614256/> DOI: <https://doi.org/10.1136/bcr-2017-220346>.
- [18] Rahimizadeh A, Khajoo A, Rahimizadeh S, et al. Seizure induced thoracolumbar burst fracture secondary to tramadol abuse. *World Spinal Column Journal* 2012;3:50–5 Available from: <https://pdfs.semanticscholar.org/3e8f/698a3a75ff3bce28170317a582fd3ddeb97.pdf>.