

Overview of Trigeminal Autonomic Cephalalgias: Nosologic Evolution, Diagnosis, and Management

Diana Yi-Ting Wei^{1,2}, Jonathan Jia Yuan Ong^{1,2,3}, Peter James Goadsby^{1,2}

¹Department of Basic and Clinical Neuroscience, Institute of Psychiatry, Psychology and Neuroscience, Kings College London, ²NIHR-Wellcome Trust King's Clinical Research Facility, Kings College Hospital, London, United Kingdom, ³Department of Medicine, Division of Neurology, National University Health System, University Medicine Cluster, Singapore

Abstract

The term trigeminal autonomic cephalalgias (TACs) encompasses four primary headache disorders – cluster headache, paroxysmal hemicrania (PH), hemicrania continua (HC), short-lasting unilateral neuralgiform headache attacks with conjunctival injection and tearing (SUNCT)/short-lasting unilateral neuralgiform headache attacks with cranial autonomic symptoms (SUNA). All of these except HC are characterized by short-lasting headaches. HC is characterized by a continuous unilateral headache that waxes and wanes in its intensity without complete resolution. It is included in the TACs group given the overlap in the activation of the posterior hypothalamic grey, and the shared clinical feature of unilateral head pain with ipsilateral cranial autonomic symptoms. The present review gives an overview of the nosologic evolution, diagnosis, and management of TACs.

Keywords: Cluster headache, hemicrania continua, paroxysmal hemicrania, short-lasting unilateral neuralgiform headache attacks with cranial autonomic symptoms, short-lasting unilateral neuralgiform headache attacks with conjunctival injection and tearing, trigeminal autonomic cephalalgias

NOSOLOGIC EVOLUTION AND CONCEPTUALIZATION

Trigeminal autonomic cephalgia (TAC) is a term that was coined by Goadsby and Lipton^[1] in 1997, to reflect the common feature among a group of short-lasting primary headaches, that is, excessive cranial parasympathetic autonomic reflex activation to nociceptive input in the ophthalmic division of the trigeminal nerve. Trigeminal-autonomic activation is the hallmark of these syndromes, which we now commonly refer to as TACs. Subsequently, the term officially appeared in the International Classification of Headache Disorders version 2 (ICHD 2),^[2] given the research into these conditions and the unifying pathogenesis. It can be argued that such nosologic classification and reorganization of headache types has minimal impact on clinical practice and that it is purely for the research purposes. However, the ICHD should be viewed as a diagnostic aide-memoire for clinicians. This classification, based on the similarity of their pathogenesis, aids the clinician by narrowing the list of relevant differential diagnoses.

TAC is an umbrella term that encompasses four primary headache disorders – cluster headache (CH), paroxysmal hemicrania (PH), hemicrania continua (HC), short-lasting unilateral neuralgiform headache attacks with conjunctival injection and tearing (SUNCT)/short-lasting unilateral neuralgiform headache attacks with cranial autonomic symptoms (SUNA). Cranial autonomic symptoms are cardinal features of TACs. These include conjunctival injection, lacrimation, nasal congestion, rhinorrhea, and aural fullness.^[3] The unifying clinical features for these syndromes are that they all present with unilateral pain in the distribution of the trigeminal nerve with associated cranial autonomic features ipsilateral to the pain. It should be in the forefront of the clinician's mind when presented with a patient with unilateral head pain and cranial autonomic symptoms in any clinic.

Address for correspondence: Dr. Peter James Goadsby, King's College London, Wellcome Foundation Building, Denmark Hill Campus West, London SE5 9PJ, United Kingdom. E-mail: peter.goadsby@kcl.ac.uk

Access this article online

Quick Response Code:



Website:
www.annalsofian.org

DOI:
10.4103/aian.AIAN_348_17

This is an open access journal, and articles are distributed under the terms of the Creative Commons Attribution-NonCommercial-ShareAlike 4.0 License, which allows others to remix, tweak, and build upon the work non-commercially, as long as appropriate credit is given and the new creations are licensed under the identical terms.

For reprints contact: reprints@medknow.com

How to cite this article: Wei DY, Yuan Ong JJ, Goadsby PJ. Overview of trigeminal autonomic cephalalgias: Nosologic evolution, diagnosis, and management. Ann Indian Acad Neurol 2018;21:S39-44.

HC was initially categorized under “other primary headaches” in ICHD-2. However, this has since been revised under the ICHD-3 version^[3] and is now included under the category of the TACs, given the overlap in the activation of the posterior hypothalamic grey, and the shared clinical feature of indomethacin responsiveness.

PATHOGENESIS OF TRIGEMINAL AUTONOMIC CEPHALALGIAS

Our understanding of the pathogenesis for TACs has come from key bench work^[4,5] and functional neuroimaging studies. The unifying mechanism for TACs is the role of the trigeminal-autonomic reflex with parasympathetic activation.^[1] The trigeminal-autonomic reflex is a reflex pathway that consists of a brainstem connection between the trigeminal nerve and facial cranial nerve parasympathetic outflow.^[6,7]

From functional neuroimaging studies, it has been shown that the hypothalamus is activated ipsilateral to the pain in CH,^[8-11] contralateral in PH,^[12] ipsilateral^[13] and bilateral^[14] hypothalamic activation in SUNCT, and contralateral^[15] in HC. There is further evidence to support the hypothalamic involvement from deep brain stimulation targeting the posterior hypothalamus in CH^[16-18] and changes in melatonin^[19-21] and orexin^[22,23] in CH.

Short-lasting unilateral neuralgiform headache attacks with conjunctival injection and tearing/short-lasting unilateral neuralgiform headache attacks with cranial autonomic symptoms

SUNCT/SUNA is short, and typically a single attack lasts 1–10 min in duration and can occur multiple times a day, and the frequency tends to be in the hundreds. The quality of pain is typically described as stabs or jabs and has a predilection for the first division of the trigeminal nerve. There are three clinical types of SUNCT/SUNA; they can occur as individual and single stabs, a group of individual stabs, or as a “saw-tooth” pattern [Figure 1]. Each attack is associated with ipsilateral cranial autonomic symptoms. In SUNCT, there is conjunctival injection and tearing, whereas in SUNA, there may be cranial

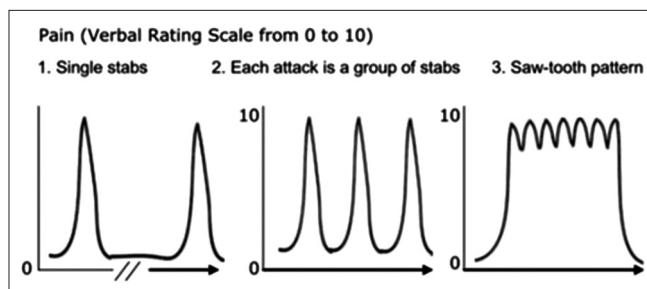


Figure 1: The three patterns of pain in short-lasting unilateral neuralgiform headache attacks with conjunctival injection and tearing/short-lasting unilateral neuralgiform headache attacks with cranial autonomic features^[24]

autonomic features other than conjunctival injection and lacrimation.

This entity is often confused with trigeminal neuralgia, given the short duration of the attacks. There are several clinical features, which may assist in the differentiation between these disorders. SUNCT/SUNA mainly affects the first division of the trigeminal nerve, whereas trigeminal neuralgia typically involves the second and third divisions, rarely affecting the first division. Furthermore, it is important to assess if attacks are consistently triggered by cutaneous stimuli. The presence of a refractory period to these triggers^[24] is a feature of trigeminal neuralgia, whereas its absence is more in keeping with SUNCT/SUNA. In general, trigeminal neuralgia should not have significant cranial autonomic features, and if this is present, one should consider SUNCT/SUNA.^[25]

Paroxysmal hemicrania

PH is a rare TAC characterized by unilateral attacks of pain lasting for 2–30 min and can recur up to forty times a day, with a mean of 11.^[26] The attacks are severe and mainly involve the periorbital and temporal area and are associated with cranial autonomic features and respond to indomethacin. Attacks are always unilateral; however, they can side-shift. Patients can have photophobia and phonophobia, and these tend to be lateralized to the side of the pain.^[27] The attacks do not typically occur at night as CH attacks do. The attacks of PH are mostly spontaneous; however, 10% can be triggered by bending or rotating the head.^[26] Alcohol can trigger attacks in one-fifth of patients, but this is less reliable as compared to its effect on triggering CH attacks. The attacks are not associated with cutaneous triggers.

PH can be classified into episodic- or chronic-based on the time of remission. Episodic PH occurs in 35% of patients and is defined when there are remission periods lasting 3 months or longer, whereas in chronic PH there is either the absence of a remission period or remissions last <3 months, for at least 1 year.

Cluster headache

CHs affect up to 0.1% of the population,^[28] and is the most common of the TAC disorders. CH patients have attacks that can last from 15 min to 3 h, however, on average, they tend to last from 45 to 90 min^[29] and can occur once every other day up to eight times a day, typically at certain times of the day with a circadian periodicity. The pain is unilateral and is concentrated in the peri-, retro-orbital, and temporal areas. In addition, there are prominent cranial autonomic features. This is one of the most painful conditions known to humans, and it has been described by patients to surpass the pain experienced from a fracture or during childbirth. During attacks patients have an intense sense of restlessness or agitation and some patients prefer to pace or fidget. Often patients apply pressure with the palm of their hands onto the epicenter of the pain, whether this is their eye or temple, to gain some pain relief.

In addition to the circadian periodicity, CH attacks demonstrate a circannual periodicity where attacks “cluster” over particular periods of the year, typically occur around the change of seasons.^[30] The periods where patients experience attacks are called “bouts” and they may last for 6–12 weeks in duration.

Depending on the time between attacks, CH can be further subclassified into episodic and chronic CH. Episodic CH is defined when there is a remission period between attacks for more than 3 months without any form of preventive treatment. Whereas, in chronic CH, there is either the absence of a remission period or remissions last <3 months for at least 1 year.^[31] During a bout, CH attacks may be triggered by alcohol,^[31,32] food containing nitrates, nitroglycerin, and strong odors such as paint and nail varnishes.^[33]

The differentiation of CH from PH can be challenging, especially as the attack duration can overlap in these conditions. Shorter and frequent CH attacks may be confused as PH attacks. There are several clinical features that may help in distinguishing these disorders. The presence of agitation during attacks and alcohol triggering attacks within a bout is consistent with CH. Anecdotally, some PH patients have found that taking higher than recommended doses of nonsteroidal anti-inflammatory drugs (NSAIDs), for example, ibuprofen, have been useful in their attacks. Patients, who have found high flow oxygen delivered through a nonrebreather mask useful in aborting their attacks within 15 min, are more likely to be suffering from CH. Although these features can help distinguish between the two TACs, ultimately for a definitive diagnosis of PH, the patient should respond to an adequate dose of indomethacin.

HEMICRANIA CONTINUA

HC is characterized by a continuous unilateral headache that waxes and wanes in its intensity without complete resolution. Like PH, it has an indomethacin response.^[34] Diagnostic uncertainty between HC and chronic migraine can occasionally arise when a patient presents with a lateralized headache with associated cranial autonomic features. This dilemma can be overcome by assessing the responsiveness to indomethacin.

In HC, there is a continuous baseline pain with intermittent worsening. This clinical picture can be confused with the interparoxysmal pain that may be associated with the other TACs, such as in SUNCT/SUNA,^[24] PH,^[26] and interparoxysmal allodynia in CH.^[35] This appears to be linked to the coexistence of TAC biology with migraine, and patients can have concomitant migraine or a family history of migraine. It is important to recognize this clinically, especially when the interparoxysmal pain becomes troublesome as TAC patients with a migrainous biology can be susceptible to medication overuse^[36] and should be treated accordingly.

CLINICAL DIAGNOSIS

When a patient presents with lateralized unilateral pain involving the trigeminal distribution together with the presence

of cranial autonomic symptoms, the consideration of several key features will help in distinguishing the various TAC entities – duration of individual attacks, attack frequency, triggers, and treatment response [Table 1].^[24,26,31,34]

In particular, the duration and frequency of the attacks can elude to the diagnosis; however, it is important to remember there is considerable overlap. In general, SUNCT/SUNA has the shortest attack duration and the highest frequency of attacks over 24 h. This is followed by PH and CH, with HC having a continuous pain superimposed with worsening [Figure 2].

One key clinical feature that distinguishes TACs from other headaches is the lateralization of associated symptoms and cranial autonomic symptoms. Although patients with unilateral migraine experience unilateral photophobia or phonophobia ipsilateral to the pain, this occurs only in <5% of patients,^[27] whereas lateralized photophobia and phonophobia are present in more than 50% of TAC patients. In addition, the lateralized cranial autonomic symptoms are less prominent in migraine as compared to TACs. Migraineurs may experience cranial autonomic features; however, this is typically bilateral, whereas in TACs, it is generally unilateral and ipsilateral to the side of the pain.^[37]

INDOMETHACIN DIAGNOSTIC TESTING FOR HEMICRANIA CONTINUA AND PAROXYSMAL HEMICRANIA

Although it is logistically easier to perform an oral indomethacin trial, such as commencing with 25 mg three times a day and gradually escalating the dosage up to 75 mg three times a day over a course of 3 weeks in the outpatient setting, there are several confounding factors that may affect the outcome of this test. These include medication compliance, pharmacodynamics, and pharmacokinetic considerations. From existing literature on oral Indomethacin tests, it has been reported that some patients needed more than 1 trial, and in one case the patient had more than 30 trials, before obtaining a positive response.^[38] Antonaci *et al.* proposed the standardized “Indotest,”^[39] using intramuscular indomethacin and a headache diary. It is expected to have a protective refractory period of 13 ± 8 h following 50 mg indomethacin injection and 13 ± 10 following 100 mg, with this protective effect starting between 22 and 73 min after the injection.^[39] It is essential to have an accurate headache diary prior the test, firstly to time the injection to the most likely expected time for an attack and to compare the number and severity of attacks pre- and post-test. To enhance the accuracy, we recommend a blinded placebo-controlled intramuscular indomethacin test with 100–200 mg, with intramuscular normal saline as the placebo. The headache diary is compared between the days placebo, and indomethacin were given^[26] to come to an accurate diagnosis.

It is important to recognize the side effects of indomethacin. Orally administered indomethacin can cause gastrointestinal irritation; we recommend the concomitant commencement of a proton-pump inhibitor (PPI). Other side effects include

Table 1: Clinical features of Trigeminal Autonomic Cephalalgias, based on studies cohort

Features	SUNCT/SUNA	PH	CH	HC
Gender ratio (male to female)	1.5:1	1:1	3:1	1:2
Pain quality	Sharp/stab/throb	Sharp/stab/throb	Sharp/stab/throb	Baseline-dull pain. During worsening can be throbbing or sharp
Pain severity	Severe	Very severe	Very severe	Baseline-mild to moderate. Worsening-moderate to severe
Distribution of maximal pain	V1>C2>V2>V3	V1>C2>V2>V3	V1>C2>V2>V3	V1>C2>V2>V3
Attacks per day	1-100	1-40	1-8	Daily in 50%
Attack duration	1-10 min	2-30 min	15-180 min	30 min to 3 days
Autonomic features	Prominent and ipsilateral to pain	Prominent and ipsilateral to pain	Prominent and ipsilateral to pain	Present during worsening and can be bilateral
Restlessness during attack (%)	65	80	95	69
Circadian periodicity	Absent	Absent	Present	Absent
Triggers				
Alcohol	-	+	+++	+
Nitroglycerin	-	+	+++	-
Cutaneous	+++	-	-	-
Associated migraine features				
Nausea (%)	10	40	50	53
Photophobia (%)	25	65	56	74
Phonophobia (%)	25	65	43	79
Treatment response				
Oxygen	No	No	Yes	No
Sumatriptan injection	No	Partial	Yes	Partial
Indomethacin	No	Yes	No	Yes

PH = Paroxysmal hemicrania, CH = Cluster headache, HC = Hemicrania continua, SUNCT/SUNA = Short-lasting unilateral neuralgiform headache attacks with conjunctival injection and tearing/short-lasting unilateral neuralgiform headache attacks with cranial autonomic features, C = Cervical, V = Trigeminal, - indicates absent or negative, + indicates trigger can be positive, +++ indicates high likelihood trigger to be positive

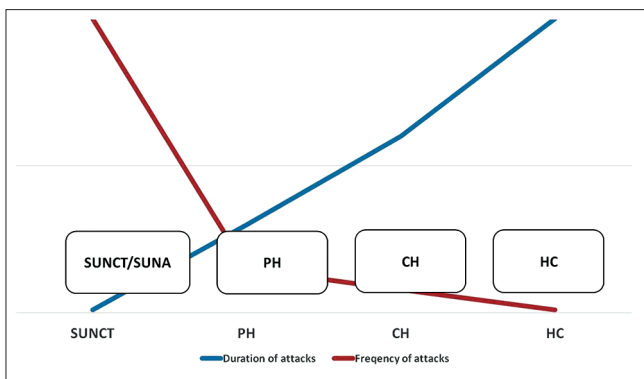


Figure 2: An overview of the trigeminal autonomic cephalalgias based on the duration and frequency of attacks. SUNCT/SUNA = Short-lasting unilateral neuralgiform headache attacks with conjunctival injection and tearing/short-lasting unilateral neuralgiform headache attacks with cranial autonomic features, PH = Paroxysmal hemicrania, CH = Cluster headache, HC = Hemicrania continua

abdominal pain, dizziness, nausea, and diarrhea.^[34] Although rare, cases of acute psychosis following parenteral indomethacin administration has been reported in the literature.^[40-46]

INVESTIGATIONS

We recommend that all new presentations of TACs be thoroughly investigated with a MRI head with gadolinium to

exclude any pituitary pathology. In addition, pituitary function testing should be pursued, as there is a known association for pituitary and peripituitary gland disease to be present with TACs. In a cohort of 84 patients with pituitary tumors and headache problems, 10% had a TAC-like headache,^[47] this is approximately a 100-fold increase compared to the normal population. Furthermore, it is important to keep in mind the secondary causes of TACs as outlined in Table 2.^[48]

After the exclusion of secondary etiology, in cases with TAC symptomatology not fulfilling diagnostic criteria, it would be reasonable to classify as “probable TAC” as set out in ICHD-3, whereas assessing the response to specific treatments such as high flow oxygen and indomethacin. It is necessary to follow-up these patients longitudinally as features may become more distinct over time.

CONCLUSION

Since the introduction of the TAC nosologic entities in 1997, we have had several advances in our understanding of SUNCT/SUNA, PH, CH, and HC. These disorders share common clinical features, which are characterized by unilateral cephalic pain affecting the trigeminal distribution associated with lateralized cranial autonomic features. This is further unified by experimental and functional neuroimaging studies implicating the hypothalamus and the trigeminal-autonomic reflex. The

Table 2: Differential diagnosis of Trigeminal Autonomic Cephalalgias

Similar secondary headaches
Tolosa–Hunt syndrome
Maxillary sinusitis
Temporal arteritis
Raeder paratrigeminal neuralgia
Trigeminal neuralgia
Secondary trigeminal autonomic Cephalalgias-cluster-like headaches
Vascular
Carotid artery dissection or aneurysm
Vertebral artery dissection or aneurysm
Pseudoaneurysm of intracavernous carotid artery
Anterior communicating artery aneurysm
Occipital lobe (AVM)
Middle cerebral artery territory AVM
AVM in soft tissue of scalp above ear
Frontal lobe and corpus callosum AVM
Cervical cord infarction
Lateral medullary infarction
Frontotemporal subdural hematoma
Tumor
Pituitary tumors
Parasellar meningioma
Sphenoidal meningioma
Epidermoid tumor in the prepontine (behind the dorsum sella turcica)
Clival epidermoid
Tentorial meningioma
High-cervical meningioma
Nasopharyngeal carcinoma
Infection
Maxillary sinusitis
Orbitosphenoidal aspergillois
Herpes zoster ophthalmicus
Post-traumatic or surgery
Facial trauma
Following enucleation of eye
Dental
Impacted wisdom tooth
Following dental extraction
Miscellaneous
Cervical syringomyelia and Chiari type 1 malformation
Idiopathic intracranial hypertension

AVM = Arteriovenous malformation

understanding and recognition of these primary headaches are crucial in clinical care as their management is so vastly distinct.

Financial support and sponsorship

Nil.

Conflicts of interest

P.J. Goadsby reports personal fees from Allergan, Amgen, and Eli-Lilly and Company; and personal fees from Akita Biomedical, Alder Biopharmaceuticals, Cipla Ltd, Dr. Reddy's Laboratories, eNeura, Electrocore LLC, Novartis, Pfizer Inc, Quest Diagnostics, Scion, Teva Pharmaceuticals, Trigemina Inc., Scion; and personal fees from MedicoLegal work, Journal

Watch, Up-to-Date, Massachusetts Medical Society, Oxford University Press; and in addition, Dr. Goadsby has a patent Magnetic stimulation for headache assigned, without fee, to eNeura.

REFERENCES

- Goadsby PJ, Lipton RB. A review of paroxysmal hemicranias, SUNCT syndrome and other short-lasting headaches with autonomic feature, including new cases. *Brain* 1997;120 (Pt 1):193-209.
- Headache Classification Subcommittee of the International Headache Society. The international classification of headache disorders: 2nd edition. *Cephalalgia* 2004;24 Suppl 1:9-160.
- Headache Classification Committee of the International Headache Society (IHS). The International Classification of Headache Disorders, 3rd edition. *Cephalalgia*. 2018;38:1-211.
- Goadsby PJ, Lambert GA, Lance JW. Effects of locus coeruleus stimulation on carotid vascular resistance in the cat. *Brain Res* 1983;278:175-83.
- Goadsby PJ, Lambert GA, Lance JW. The peripheral pathway for extracranial vasodilatation in the cat. *J Auton Nerv Syst* 1984;10:145-55.
- May A, Goadsby PJ. The trigeminovascular system in humans: Pathophysiologic implications for primary headache syndromes of the neural influences on the cerebral circulation. *J Cereb Blood Flow Metab* 1999;19:115-27.
- Akerman S, Holland PR, Summ O, Lasalandra MP, Goadsby PJ. A translational *in vivo* model of trigeminal autonomic cephalalgias: Therapeutic characterization. *Brain* 2012;135:3664-75.
- May A, Bahra A, Büchel C, Frackowiak RS, Goadsby PJ. Hypothalamic activation in cluster headache attacks. *Lancet* 1998;352:275-8.
- May A, Bahra A, Büchel C, Frackowiak RS, Goadsby PJ. PET and MRA findings in cluster headache and MRA in experimental pain. *Neurology* 2000;55:1328-35.
- Sprenger T, Boecker H, Tolle TR, Bussone G, May A, Leone M, *et al.* Specific hypothalamic activation during a spontaneous cluster headache attack. *Neurology* 2004;62:516-7.
- Morelli N, Pesaresi I, Cafforio G, Maluccio MR, Gori S, Di Salle F, *et al.* Functional magnetic resonance imaging in episodic cluster headache. *J Headache Pain* 2009;10:11-4.
- Matharu MS, Cohen AS, Frackowiak RS, Goadsby PJ. Posterior hypothalamic activation in paroxysmal hemicrania. *Ann Neurol* 2006;59:535-45.
- May A, Bahra A, Büchel C, Turner R, Goadsby PJ. Functional magnetic resonance imaging in spontaneous attacks of SUNCT: Short-lasting neuralgiform headache with conjunctival injection and tearing. *Ann Neurol* 1999;46:791-4.
- Sprenger T, Valet M, Platzer S, Pfaffenrath V, Steude U, Tolle TR, *et al.* SUNCT: Bilateral hypothalamic activation during headache attacks and resolving of symptoms after trigeminal decompression. *Pain* 2005;113:422-6.
- Matharu MS, Goadsby PJ. Functional brain imaging in hemicrania continua: Implications for nosology and pathophysiology. *Curr Pain Headache Rep* 2005;9:281-8.
- Leone M, Franzini A, Bussone G. Stereotactic stimulation of posterior hypothalamic gray matter in a patient with intractable cluster headache. *N Engl J Med* 2001;345:1428-9.
- Leone M, Proietti Cecchini A, Franzini A, Broggi G, Cortelli P, Montagna P, *et al.* Lessons from 8 years' experience of hypothalamic stimulation in cluster headache. *Cephalalgia* 2008;28:787-97.
- Schoenen J, Di Clemente L, Vandenheede M, Fumal A, De Pasqua V, Mouchamps M, *et al.* Hypothalamic stimulation in chronic cluster headache: A pilot study of efficacy and mode of action. *Brain* 2005;128:940-7.
- Waldenlind E, Gustafsson SA, Ekblom K, Wetterberg L. Circadian secretion of cortisol and melatonin in cluster headache during active cluster periods and remission. *J Neurol Neurosurg Psychiatry* 1987;50:207-13.
- Bruera O, Sances G, Leston J, Levin G, Cristina S, Medina C, *et al.*

- Plasma melatonin pattern in chronic and episodic headaches: Evaluation during sleep and waking. *Funct Neurol* 2008;23:77-81.
21. Leone M, Lucini V, D'Amico D, Grazzi L, Moschiano F, Fraschini F, *et al.* Abnormal 24-hour urinary excretory pattern of 6-sulphatoxymelatonin in both phases of cluster headache. *Cephalalgia* 1998;18:664-7.
 22. Holland P, Goadsby PJ. The hypothalamic orexinergic system: Pain and primary headaches. *Headache* 2007;47:951-62.
 23. Holland PR, Goadsby PJ. Cluster headache, hypothalamus, and orexin. *Curr Pain Headache Rep* 2009;13:147-54.
 24. Cohen AS, Matharu MS, Goadsby PJ. Short-lasting unilateral neuralgiform headache attacks with conjunctival injection and tearing (SUNCT) or cranial autonomic features (SUNA) – A prospective clinical study of SUNCT and SUNA. *Brain* 2006;129:2746-60.
 25. Maarbjerg S, Gozalov A, Olesen J, Bendtsen L. Trigeminal neuralgia – A prospective systematic study of clinical characteristics in 158 patients. *Headache* 2014;54:1574-82.
 26. Cittadini E, Matharu MS, Goadsby PJ. Paroxysmal hemicrania: A prospective clinical study of 31 cases. *Brain* 2008;131:1142-55.
 27. Irimia P, Cittadini E, Paemeleire K, Cohen AS, Goadsby PJ. Unilateral photophobia or phonophobia in migraine compared with trigeminal autonomic cephalalgias. *Cephalalgia* 2008;28:626-30.
 28. Fischera M, Marziniak M, Gralow I, Evers S. The incidence and prevalence of cluster headache: A meta-analysis of population-based studies. *Cephalalgia* 2008;28:614-8.
 29. Dodick DW, Rozen TD, Goadsby PJ, Silberstein SD. Cluster headache. *Cephalalgia* 2000;20:787-803.
 30. Kudrow L. The cyclic relationship of natural illumination to cluster period frequency. *Cephalalgia* 1987;7 Suppl 6:76-8.
 31. Bahra A, May A, Goadsby PJ. Cluster headache: A prospective clinical study with diagnostic implications. *Neurology* 2002;58:354-61.
 32. Schürks M, Kurth T, de Jesus J, Jonjic M, Roskopf D, Diener HC, *et al.* Cluster headache: Clinical presentation, lifestyle features, and medical treatment. *Headache* 2006;46:1246-54.
 33. Nesbitt AD, Goadsby PJ. Cluster headache. *BMJ* 2012;344:e2407.
 34. Cittadini E, Goadsby PJ. Hemicrania continua: A clinical study of 39 patients with diagnostic implications. *Brain* 2010;133:1973-86.
 35. Ashkenazi A, Young WB. Dynamic mechanical (brush) allodynia in cluster headache. *Headache* 2004;44:1010-2.
 36. Goadsby PJ, Cittadini E, Burns B, Cohen AS. Trigeminal autonomic cephalalgias: Diagnostic and therapeutic developments. *Curr Opin Neurol* 2008;21:323-30.
 37. Lai TH, Fuh JL, Wang SJ. Cranial autonomic symptoms in migraine: Characteristics and comparison with cluster headache. *J Neurol Neurosurg Psychiatry* 2009;80:1116-9.
 38. Pareja J, Sjaastad O. Chronic paroxysmal hemicrania and hemicrania continua. Interval between indomethacin administration and response. *Headache* 1996;36:20-3.
 39. Antonaci F, Pareja JA, Caminero AB, Sjaastad O. Chronic paroxysmal hemicrania and hemicrania continua. Parenteral indomethacin: The 'indotest'. *Headache* 1998;38:122-8.
 40. Türkoğlu G, Türkoğlu S, Kayal S, Karahan AY. Indomethacin-induced psychotic disorder. *Clin Neuropharmacol* 2016;39:161.
 41. Tharumaratnam D, Bashford S, Khan SA. Indomethacin induced psychosis. *Postgrad Med J* 2000;76:736-7.
 42. Singh RP, Sinha AK. Organic psychosis with indomethacin. *J Indian Med Assoc* 1978;71:210.
 43. Nassif JM, Ritter MA. Indomethacin-induced postoperative psychosis. *J Arthroplasty* 1999;14:769-70.
 44. Gotz V. Paranoid psychosis with indomethacin. *Br Med J* 1978;1:49.
 45. Carney MW. Paranoid psychosis with indomethacin. *Br Med J* 1977;2:994-5.
 46. Bessa O Jr. Acute psychosis due to indomethacin. *Conn Med* 1994;58:395-6.
 47. Levy MJ, Matharu MS, Meeran K, Powell M, Goadsby PJ. The clinical characteristics of headache in patients with pituitary tumours. *Brain* 2005;128:1921-30.
 48. Goadsby PJ. Trigeminal autonomic cephalalgias. *Continuum Lifelong Learn Neurol* 2012;18:883-95.