

# Third Molar Angulation Changes in Class II Div I Malocclusion Subjects Treated with Extraction of Four Premolars: A Retrospective Study

Keerthan Shashidhar<sup>1</sup>, Chrysl Karishma Castelino<sup>2</sup>, M. N. Kuttappa<sup>1</sup>, Rohit A. Nair<sup>3</sup>, Crystal Ruma Soans<sup>1</sup>, Harikrishnan S. Nair<sup>4</sup>

<sup>1</sup>Department of Orthodontics and Dentofacial Orthopaedics, A B Shetty Memorial Institute of Dental Sciences, Nitte (Deemed to be University),  
<sup>2</sup>Department of Oral and Maxillofacial Surgery, Father Muller Medical College and Hospital,  
<sup>3</sup>Department of Endodontics and Conservative Dentistry, A B Shetty Memorial Institute of Dental Sciences, Nitte (Deemed to be University),  
<sup>4</sup>Department of Pedodontics, Srinivas Institute of Dental Sciences, Mangalore, Karnataka, India

Received : 20-08-19  
 Revised : 14-06-20  
 Accepted : 25-06-20  
 Published : 28-09-20

**ABSTRACT**  
**Aim:** The aim of this study was to assess the changes in maxillary and mandibular third molar inclinations in individuals with class II div 1 malocclusion, before and after orthodontic treatment with extraction of all four first premolars.  
**Materials and Methods:** This retrospective study consisted of the pretreatment and posttreatment records of 30 patients that were obtained from the archives of the department of orthodontics and dentofacial orthopedics in A B Shetty Memorial Institute of Dental Sciences. The maxillary third molar's relation to the palatal plane and the mandibular third molar's relation to the mandibular plane were measured. The paired *t* test was used to calculate pre- and posttreatment changes. A value of  $P < 0.05$  was considered to be statistically significant.  
**Results:** The maxillary third molars showed a mean correction of  $6.15^\circ$  ( $P < 0.001$ ) and the mandibular third molars showed a mean correction of  $5.10^\circ$  ( $P < 0.001$ ).  
**Conclusion:** Maxillary third molars showed more uprighting when compared to the mandibular third molars and that both maxillary and mandibular third molars showed an improvement in their angulations to their respective planes after extraction of the first premolars. However, the results of the study cannot be analyzed to state if the third molars do become fully functional.  
**KEYWORDS:** Angle class II, bicuspid, malocclusion, mandible, maxilla, third molar, occlusal plane, orthodontics

## INTRODUCTION

The first appearance of third molars on radiographs may be observed as early as 9 years of age or as late as 16.<sup>[1,2]</sup> Usually, most of the lower third molars are mesially inclined at first, after which they become more upright up to the age of 25.<sup>[3-5]</sup> However, due to lack of space in the arch, or due to reduced arch length, the third molars may be impacted. As a matter of fact, 77.1% of young adults may have at least one impacted mandibular third molar.<sup>[6]</sup> When it comes to the maxillary third molars, they usually assume a distal angulation during the initial stages of development and therefore were mostly impacted distoangularly.<sup>[7,8]</sup> For these teeth to erupt into the oral cavity they need a certain amount

of uprighting. Approximately 25% of the impactions are distal which suggests that unsatisfactory uprighting is a common cause of impaction.<sup>[9]</sup> There have been many studies on the effect of orthodontic treatment on mandibular third molars. Although mandibular molars have shown to be more commonly impacted,<sup>[10]</sup> it is important to study the angulations of the maxillary third molars as pathologies with impacted molars are more commonly associated in the maxilla.<sup>[11]</sup> Despite

**Address for correspondence:** Dr. M. N. Kuttappa, Department of Orthodontics and Dentofacial Orthopaedics, A B Shetty Memorial Institute of Dental Sciences, Nitte (Deemed to be University), Mangalore 575018, Karnataka, India.  
 E-mail: kuttappa27@gmail.com

This is an open access journal, and articles are distributed under the terms of the Creative Commons Attribution-NonCommercial-ShareAlike 4.0 License, which allows others to remix, tweak, and build upon the work non-commercially, as long as appropriate credit is given and the new creations are licensed under the identical terms.

**For reprints contact:** reprints@medknow.com

**How to cite this article:** Shashidhar K, Castelino CK, Kuttappa MN, Nair RA, Soans CR, Nair HS. Third molar angulation changes in Class II div I malocclusion subjects treated with extraction of four premolars: A retrospective study. J Int Soc Preventive and Community Dent 2020;10:591-6.

Access this article online	
<b>Quick Response Code:</b> 	<b>Website:</b> www.jispcd.org  <b>DOI:</b> 10.4103/jispcd.JISPCD_342_19

this, the effect of premolar extractions on maxillary third molars has not been studied extensively.

Class II malocclusion may result either from dental/skeletal disharmony. Skeletal class II cases usually present with maxillary prognathism or mandibular retrognathism or a combination of both.

Enough literature is present comparing the changes in third molar angulation between extraction groups and nonextraction groups<sup>[12-17,19-21]</sup> and we do know that the extraction group tends to have more uprighted third molars than the nonextraction group.<sup>[12-17,19-21]</sup>

Hence, this study focused on the objective of finding the amount of uprighting of the third molars that occurred in subjects with Class II div 1 malocclusion before and after orthodontic treatment that included extraction of the first premolar from each quadrant. The hypothesis for this study was that there is no change in angulation of the maxillary and mandibular third molars at the end of the orthodontic treatment that included the extraction of first premolars.

## MATERIALS AND METHODS

### SOURCE OF DATA

This retrospective study included the pretreatment and posttreatment records of 1233 patient records (2006–2019) that were obtained from the archives of the Department of Orthodontics and Dentofacial Orthopedics in A B Shetty Memorial Institute of Dental Sciences. The ethical guidelines for the study were in accordance with World Medical Association declaration of Helsinki, 1975, as revised in 2013. Before the start of the study, Institutional ethical clearance was obtained (ABSM/EC/81/2019). The criteria used for inclusion and exclusion of the subjects are given below.

### INCLUSION CRITERIA

- Patients of age group 15–30 years
- Patients with a full complement of permanent dentition
- Patients with skeletal Class II relation, selected based on a set of angular [Table 1] and linear [Table 2] parameters
- Patients with Angles Class II div 1 malocclusion
- Patients undergoing fixed Conventional Orthodontic treatment using the MBT system which included extraction of all four first premolars
- Radiographic evidence of unerupted third molars at the pretreatment stage due to an angulated position relative to the second molar or the ascending ramus, or lack of space, with radiographic evidence of apical closure.
- Availability of pretreatment and posttreatment lateral cephalograms and records.

### EXCLUSION CRITERIA

- Patients with missing teeth
- Patients who had no radiographic identification of the apices of the third molars.
- Patients with partially erupted third molars.
- Patients with soft tissue impacted third molars

Of the 1233 patients from the archive, only 362 patients had skeletal Class II relation. Of the 362 patients, 147 patients required the extraction of all four first premolars. Of the 147 cases, only 58 patients had Angles Class II div I malocclusion. Of the 58 patients, only 43 patients were within the age group of 15–30. 9 patients were eliminated from the study as their treatment included the use of Begg therapy. Of the remaining 34 patients, 4 patients were eliminated from the study due to a lack of records. The period of orthodontic treatment for the subjects ranged from 1.5 years to 2 years. The remaining 30 patients were the ideal subjects for the study as they fulfilled the above-mentioned inclusion and exclusion criteria. The records of the patients who were selected for the study consisted of 16 females and 14 males.

All patients underwent conventional orthodontic treatment that included the use of transpalatal Arch for reinforcing anchorage, E chain (JJ Orthodontics) for space closure and Class 2 elastics (JJ Orthodontics) to aid in achieving class I molar relation. The lateral cephalogram of the patient was traced on a 0.003-inch acetate paper. The maxillary third molar's relation to the palatal plane and the mandibular third molar's relation to the mandibular plane were measured [Figure 1]. As the study involved all the records that were available in the department, there was no need for randomization and blinding. For the same reason selection bias was also eliminated. The study took place over a period of 2 months, where the cephalograms (pretreatment and posttreatment) were traced and retraced

**Table 1: Angular parameters to assess Class II skeletal relation and their mean value**

Angular parameter	Mean value (in degrees)	Standard deviation
SNA	87.27	2.94
SNB	81.20	2.66
ANB	6.07	1.42

**Table 2: Linear parameters to assess Class II skeletal relation and their mean value**

Linear parameter	Mean value (in mm)	Standard deviation
WITTS analysis	2.72	2.08
N perpendicular—A	3.05	4.14
N Perpendicular—B	-5.08	5.96
N perpendicular—pogonion	-5.37	6.36

by the same author to avoid interobserver error. As a rule in the institution, all the patients had signed a consent form prior to the start of their orthodontic treatment and this consent form was attached to their case history sheet.

**STATISTICAL ANALYSIS**

Descriptive statistics mean and standard deviation were calculated for all variables. As the data were normally distributed the paired *t* test was used to calculate pre- and posttreatment changes. A value of *P* < 0.05 was considered to be statistically significant. Microsoft Excel and SPSS software version 22 was used for statistical analysis.

**RESULTS**

The mean value of the angulations of the maxillary third molars pretreatment was found to be 27.2 ± 8.36° and posttreatment was found to be 21.07 ± 8.42° [Table 3 and Figure 2]. This showed a mean correction of 6.15° in the angulations of the third molars in the maxilla with and it was statistically significant (*P* < 0.001) [Table 1].

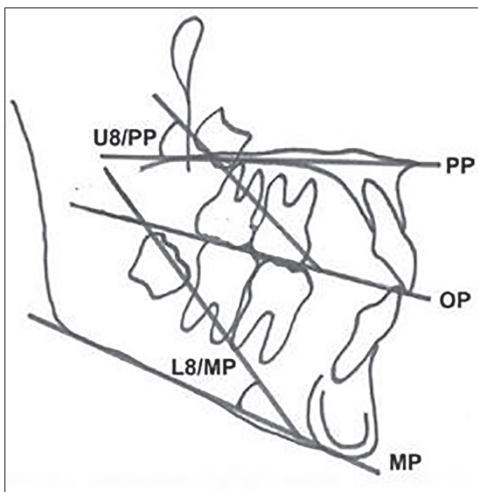
The mean value of the angulations of the mandibular third molars pretreatment was found to be 18.2 ± 9.65°

and posttreatment was found to be 13.08 ± 8.73° [Table 1 and Figure 2]. This showed a mean correction of 5.1° in the angulations of the third molars in the mandible and it was statistically significant (*P* < 0.001) [Table 1].

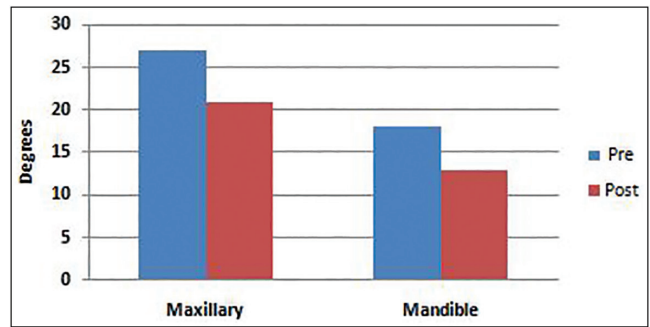
The values of the change in angulations are statistically significant; thereby we rejected the null hypothesis and accepted the alternative hypothesis. That is, there is a significant change in the angulation of the third molars after premolar extraction.

**DISCUSSION**

The study of the third molars has always been a point of interest in clinical practice. Studies conducted on third molars have mainly focused on the mandibular third molars, whereas only a few studies have focused on the changes in the maxillary third molars. This study evaluates the changes in the angulations of the third molar angulations in the maxilla and mandible in the Class II div 1 malocclusion. The age of the subjects of this study ranged from 15 to 30 years, that is, we included patients who had completed or almost completed their growth; hence, residual growth of the maxilla was not taken into consideration. However, while analyzing the results, the residual growth of the mandible was kept in mind. The reason why controls were not included in the study design was that the only way the correction



**Figure 1:** Upper third molar to palatal plane angle and the lower third molar to mandibular plane angle



**Figure 2:** Mean values of third molar angulations in maxilla and mandible before and after treatment

**Table 3: Pretreatment and posttreatment mean changes in angulation of third molars in the maxilla and mandible**

	N	Mean	Standard deviation	Mean difference	95% Confidence interval of the difference		t	Degree of freedom	P
					Lower	Upper			
Maxilla pretreatment	30	27.22	8.36	6.15	5.16	7.14	12.745	29	<0.001*
Maxilla posttreatment	30	21.07	8.42						
Mandible pretreatment	30	18.21	9.65	5.13	4.30	5.96	12.663	29	<0.001*
Mandible posttreatment	30	13.08	8.73						

\* *P* < 0.001 statistically significant, test used: paired *t* test

of angulation of third molars would have taken place could be attributed to the growth or extraction of the teeth. As the sample's age ranged from 15 to 30 and as the duration of the orthodontic treatment was less than 2 years, very minimal growth was expected. This justified the reason to not have controls in our study.

The findings of this study show that there was a statistically significant change in the angulation of the maxillary third molars after orthodontic treatment. The uprighting of the maxillary third molars occurred by a mean of 6.15°. The findings of this study are in accordance with a study done by Fan *et al.*<sup>[12]</sup> who noted a mean uprighting of 5.19°, Årtun *et al.*<sup>[13]</sup> who noted a mean uprighting of 8.83° and Staggars *et al.*<sup>[14]</sup> who reported a mean uprighting of 8.35°. Tarvade and Biday<sup>[15]</sup> conducted a study to assess the change in angulations in third molars using panoramic radiographs and noted a mean uprighting of 7.88° in the maxillary third molars, However, Ala'a Dawood and Mahmood<sup>[16]</sup> reported a mean uprighting of 17.22° and Bayram *et al.*<sup>[17]</sup> reported a mean uprighting of 13.65° which is much larger than what is reported in our study. This is mostly because the evaluations of the angulations of the third molars were done on a panoramic radiograph, whereas we used lateral cephalograms in our study.

The mandibular third molars showed uprighting of 5.1°, which was statistically significant. The findings of this study are in accordance with Årtun *et al.*<sup>[13]</sup> who reported a mean uprighting of 5.6° of the mandibular third molars in their study and Fan *et al.*<sup>[12]</sup> who reported a mean uprighting of 3.44° in mandible. Elsey and Rock<sup>[18]</sup> showed that in a group of patients who still had growth left, and underwent premolar extractions followed by full orthodontic space closure, there were changes in the orientation and position of the mandibular third molars making them more vertical and closer to the occlusal plane. The same effect is appreciated in our study too. Hence the improvement in the angulation of the mandibular third molars is in accordance with the study done by authors such as Gohilot *et al.*,<sup>[19]</sup> Poosti *et al.*,<sup>[20]</sup> and Staggars *et al.*<sup>[14]</sup> Although the above-mentioned authors did not use lateral cephalograms to assess the changes, their results indicate an uprighting of the mandibular third molars as does our study. A detailed description of the studies by various authors and their results are tabulated in Table 4.

Durgesh *et al.*<sup>[21]</sup> conducted a study to assess the Influence of premolar extraction or nonextraction orthodontic therapy on the angular changes of mandibular third molars. They concluded their study saying that although there was a change in angulation of the mandibular third molars, it was not statistically significant. This contradiction could be because the

authors used the angle between the long axis of the maxillary third molar and the occlusal plane to assess the angulation of the maxillary third molar. The occlusal plane is not a stable plane as it is directly affected by the orthodontic treatment. To assess the lower third molar's angulation, the authors used the angle formed between the long axis of the lower third molar and the inclination of the second molar. This is not a stable measurement either as the second molars can be tipped in the mesial/distal/lingual/buccal direction prior to the start of the treatment and then get corrected post orthodontic treatment. Hartono *et al.*<sup>[22]</sup> conducted a study to assess the change in angulation of mesioangular impacted lower molars before and after premolar extractions. They concluded that the extraction of premolars in orthodontic treatment did not significantly affect the angulation of impacted third molars. This contradiction could be because of the imbalance in the ages of the samples in their study. Their study had only four subjects that belonged to the age group of 17–21. The majority of the subjects belonged to the age group of 10–14. Their study had three groups of ages that were not equally distributed. In their study, a change in the second molar's angulation would directly affect the third molar's angulation because they too used the angle formed by the long axis of the second molar and third molar.

A limitation of the study of molars on lateral cephalograms is that it is subjected to bias due to differences in angulation between the superimposed contralateral images. However, the strength of this study is that severe asymmetry between the superimposed contralateral images of the third molars were absent in this study. Another point that can be raised is the calculation of the third molar angulation relative to the mandibular plane and palatal planes as the remodeling of the palatal process and the border of the mandible could change the values that are to be measured. However, such changes are likely to be small because of the short treatment time of the subjects in this study.<sup>[23]</sup> Brezulier *et al.*<sup>[24]</sup> conducted a detailed systematic review on the influence of orthodontic premolar extraction therapy on the eruption of the third molars. The review showed only eight studies that were ideal to be included in the study. Of the eight studies, only two studies showed an improvement in the angulation of the third molars. Another point to be noted is that the systematic review could find only two studies that fit into their exclusion/inclusion criteria that included the study of the change in angulations of the maxillary third molars. Our study adds into the limited evidence present on the change in angulation of the maxillary molars and also supports the theory of improvement in the third molar angulation following orthodontic treatment that involves the

**Table 4: Compiled data of mean changes of angulation in extraction groups in various studies**

Study reference number	Malocclusion studied	Radiograph used	Total sample size <i>n</i> and mean age	Mean change of angulation in degrees and <i>P</i> value	
				Maxillary third molar	Mandibular third molar
12*	Meta analysis	Lateral cephalogram and OPG	<i>N</i> = 712	5.19; <i>P</i> = <0.05	3.44; <i>P</i> = <0.05
13*	Class I, II, and III dental	Lateral cephalogram	<i>N</i> = 157; 15.3 years	8.83; <i>P</i> = <0.05	5.66; <i>P</i> = 0.77
14*	Class I skeletal and dental	OPG	<i>N</i> = 78 age not mentioned	Right: 8.40; <i>P</i> = 0.36 Left: 8.35; <i>P</i> = 0.20	Right: -0.14 <i>P</i> = 0.07 Left: -3.93; <i>P</i> = 0.74
15*	Not mentioned	OPG	<i>N</i> = 20 age not mentioned	Right: -1.44; <i>P</i> = 0.32 Left: 2.33; <i>P</i> = 0.76	Right: 2.11 <i>P</i> = 0.95 Left: -1.88; <i>P</i> = 0.39
16*	Class I skeletal and dental	OPG	<i>N</i> = 40 13.8 years	Right: 16.72; <i>P</i> = 0.05 Left: 17.22; <i>P</i> = 0.05	Right: 13.20; <i>P</i> = 0.01 Left: 12.85; <i>P</i> = 0.02
17*	Not mentioned	OPG	<i>N</i> = 41 16.6 years	Right: 13.65; <i>P</i> = 0.073 Left: 15.5; <i>P</i> = 0.001	Right: -7.22; <i>P</i> = 0.473 Left: -4.97; <i>P</i> = 0.495
18*	Not mentioned	OPG	<i>N</i> = 30 13 years	Not included in the study	7 <i>P</i> = <0.001
19*	Class I skeletal and dental	OPG	<i>N</i> = 50 age range =14-19 yrs	Right: 13.65; <i>P</i> = 0.073 Left: 15.5; <i>P</i> = 0.001	Right: 13.65; <i>P</i> = 0.073 Left: 15.5; <i>P</i> = 0.001
20*	Class I skeletal and dental	OPG	<i>N</i> = 56 12.5 years	Not included in the study	Right: 9.9; <i>P</i> = 0.002 Left: 6.6; <i>P</i> = 0.019
21*	Class I skeletal and dental	OPG	<i>N</i> = 180 13.67 years	Not included in the study	-7.3 <i>P</i> = <0.05
22*	Class I skeletal	OPG	<i>N</i> = 25 14.92 years	Not included in the study	
Our study**	Class II skeletal and Class II div I dental	Lateral ceph	<i>N</i> = 30 age range =15-30 years	6.15 <i>P</i> = <0.001	5.13 <i>P</i> = <0.001

\* Studies that compared extraction vs. nonextraction groups

\*\* Study that compared the difference in change in angulation only in extraction group

extraction of premolars; however, the results of the study cannot be analyzed to state if the third molars do become fully functional. This is one limitation of the study.

The impacted molars in our study were located below the cemento-enamel junction of the adjacent second molar and were mostly mesioangular/horizontally impacted. A study done by Nance *et al.*<sup>[25]</sup> showed that the mesioangular/horizontally impacted molars with an angulation of greater than or equal to 35° to the second molar were less likely to erupt into the oral cavity. However, our study has shown significant changes in the uprighting of the third molars and so, a long-term evaluation of the molars could give a better insight into their eruption status. It can only be said that the improvement in the angulations could lead to the eruption of the third molars and/or ease the process of removal of the third molars as the molars tend to obtain a more vertical position in relation to the occlusal plane.

Thus the clinical implication of the study would be that third molar disimpactions could be avoided/delayed in patients undergoing orthodontic therapy involving extraction of premolars and in doing so, unnecessary extraction of teeth could be avoided. However, a longitudinal study on the eruption and position of

third molars needs to be done to understand if the improvement in angulations of the third molar helps in the eruption of the tooth into the oral cavity.

The following conclusions can be made through the findings of this study

1. There is a definite improvement in the angulation of the maxillary and mandibular third molars when compared to the pretreatment values, showing a more vertical position (uprighting) in relation to the occlusal plane.
2. The maxillary third molars showed more uprighting when compared to the mandibular third molars.
3. As per the observed values of correction of angulation of the third molars, the study suggests that there is a higher chance of eruption of third molars that were impacted prior to the start of orthodontic treatment.

#### ACKNOWLEDGEMENT

We would like to acknowledge Dr. U. S. Krishna Nayak, Dr. M. S. Ravi, Dr. Satadru Roy and Dr. Taronazem Subba for their consistent support and timely help in gathering information for this study.

#### FINANCIAL SUPPORT AND SPONSORSHIP

This study was self funded.

**CONFLICTS OF INTEREST**

There are no conflicts of interest.

**AUTHORS CONTRIBUTIONS**

Dr. Keerthan Shashidhar: Concepts, design, definition of intellectual content, literature search, clinical studies, data acquisition, data analysis, statistical analysis, manuscript preparation, manuscript editing, and review. Dr. M. N. Kuttappa: Concepts, design, definition of intellectual content, statistical analysis, manuscript editing, and review. Dr. Chrysl Castelino: Concepts, design, definition of intellectual content, manuscript editing, and review. Dr. Rohit A. Nair: Literature search, data analysis, statistical analysis, manuscript preparation, manuscript editing, and review. Dr. Crystal Runa Soans: Concepts, design, definition of intellectual content, data analysis, manuscript editing, and review. Dr. Harikrishnan Nair: manuscript preparation, manuscript editing, and review.

**ETHICAL POLICY AND INSTITUTIONAL REVIEW BOARD STATEMENT**

Not applicable.

**PATIENT DECLARATION OF CONSENT**

The authors certify that they have obtained all appropriate patient consent forms. In the form the patient(s) has/have given his/her/their consent for his/her/their images and other clinical information to be reported in the journal. The patients understand that their names and initials will not be published and due efforts will be made to conceal their identity, but anonymity cannot be guaranteed.

**DATA AVAILABILITY STATEMENT**

The data for the study are available on request from Dr. Keerthan Shashidhar (e-mail: keerthan32592@gmail.com).

**REFERENCES**

- Garn SM, Lewis AB, Bonn  B. Third molar formation and its development course. *Angle Orthodontist* 1962;32:270-9.
- Liu Y, Geng K, Chu Y, Xu M, Zha L. Third molar mineralization in relation to chronologic age estimation of the Han in central southern china. *Int J Legal Med* 2018;132:1427-35.
- Yazdani J, Esmaeili F, Johari M. Comparison of the inclination of unerupted mandibular third molars on panoramic radiography and casts made after surgical incision. *J Dent Res Dent Clin Dent Prospects* 2009;3:94-7.
- Primo FT, Primo BT, Scheffer MA, Hern andez PA, Rivaldo EG. Evaluation of 1211 third molars positions according to the classification of Winter, Pell & Gregory. *Int J Odontostomat* 2017;11:61-5.
- Hattab FN. Positional changes and eruption of impacted mandibular third molars in young adults: A radiographic 4-year follow-up study. *Oral Surg Oral Med Oral Pathol Oral Radiol Endodontol* 1997;84:604-8.
- Bayoumi A, Baabdullah R, Bokhari A, Nadershah M. The prevalence rate of third molar impaction among Jeddah population. *Int J Dent Oral Health* 2016;2(4).
- Kumar SM, Al-Hobeira H, Shaikh S, Siddiqui AA, Syed J, Mian RI. Distribution of impacted third molars based on gender and patterns of angulation in dental students of the Hai'l region, Saudi Arabia: A panoramic radiographic (OPG) Study. *Int J Contemp Med Res* 2017;4:1829-32.
- Orton-Gibbs S, Crow V, Orton HS. Eruption of third permanent molars after the extraction of second permanent molars. Part 1: Assessment of third molar position and size. *Am J Orthod Dentofacial Orthop* 2001;119:226-38.
- Peterson LJ, Ellis E, Hupp JR, Tucker MR, editors. *Contemporary Oral and Maxillofacial Surgery*. St. Louis, MO: Mosby; 1988.
- Al-Dajani M, Abouonq AO, Almohammadi TA, Alruwaili MK, Alswilem RO, Alzoubi IA. A cohort study of the patterns of third molar impaction in panoramic radiographs in saudi population. *Open Dent J* 2017;11:648.
- Sejfiya Z, Koçani F, Macan D. Prevalence of pathologies associated with impacted third molars in kosovar population: An orthopantomography study. *Acta Stomatol Croat* 2019;53:72-81.
- Fan L, Kuang Q, Tang Y, Qin P. Effect of premolar extractions on third molar angulation changes: a meta-analysis. *Zhong nan da xue xue bao. Yi xue ban = J Cent South Univ. Med Sci* 2015;40:317-25.
-  rtun J, Thalib L, Little RM. Third molar angulation during and after treatment of adolescent orthodontic patients. *Eur J Orthod* 2005;27:590-6.
- Staggers JA, Germane N, Fortson WM. A comparison of the effects of first premolar extractions on third molar angulation. *Angle Orthod* 1992;62:135-8.
- Tarvade SM, Biday S. Influence of first premolar extraction on second and third molar angulation-A clinical study. *Int J Med Dent Sci* 2015;4:560-7.
- Ala'a Dawood Mahmood BD. Changes in third molar angulations after first premolar extractions during fixed orthodontic treatment. *Mustansiria Dent J* 2009;6:356-60.
- Bayram M, Ozer M, Arici S. Effects of first molar extraction on third molar angulation and eruption space. *Oral Surg Oral Med Oral Pathol Oral Radiol Endod* 2009;107:e14-20.
- Elsej MJ, Rock WP. Influence of orthodontic treatment on development of third molars. *Br J Oral Maxillofac Surg* 2000;38:350-3.
- Gohilot A, Pradhan T, Keluskar KM. Effects of first premolar extraction on maxillary and mandibular third molar angulation after orthodontic therapy. *J Oral Biol Craniofac Res* 2012;2:97-104.
- Poosti M, Basafa M, Hosseini M, Parvizi F. Changes in the position of mandibular third molars following extraction and non-extraction orthodontic treatments. *J Dent Mater Techn* 2012;1:47-52.
- Durgesh BH, Gowda KH, AlShahrani OA, Almalki AD, Almalki WD, Balharith MM, et al. Influence of premolar extraction or non-extraction orthodontic therapy on the angular changes of mandibular third molars. *Saudi J Biol Sci* 2016;23:736-40.
- Hartono DF, Soegiharto BM, Sumardi S. Mesioangular impacted lower third molars: Angulation before and after orthodontic treatment with premolar extraction. *J Phys* 2018;1073:022007.
- Heravi F, Shojaeian S, Sadafi M. A comparative study of dentoskeletal changes following orthodontic treatment with first premolar extraction in long face and normal patients. *J Dent Mater Techn* 2012;1:63-9.
- Brezulier D, Fau V, Sorel O. Influence of orthodontic premolar extraction therapy on the eruption of the third molars: A systematic review of the literature. *J Am Dent Assoc* 2017;148:903-12.
- Nance PE, White RP Jr, Offenbacher S, Phillips C, Blakey GH, Haug RH. Change in third molar angulation and position in young adults and follow-up periodontal pathology. *J Oral Maxillofac Surg* 2006;64:424-8.