

HEAD AND NECK

Systemic inflammatory response after endoscopic surgery of Zenker's diverticulum

Risposta infiammatoria sistemica dopo trattamento chirurgico endoscopico del diverticolo di Zenker

S. HERING¹, S. WIEGAND²

¹ Department of Otorhinolaryngology, Head and Neck Surgery, University Hospital Giessen and Marburg GmbH, Marburg, Germany; ² Department of Otorhinolaryngology, Head and Neck Surgery, University Hospital Leipzig, Leipzig, Germany

SUMMARY

Zenker's diverticulum can be treated with a carbon dioxide laser or linear stapling device. A retrospective study on patients undergoing elective surgery for Zenker's diverticulum with carbon dioxide laser or stapler was performed to analyse possible differences in inflammatory responses during the postoperative period. Leucocyte counts and C-reactive protein levels in peripheral blood were measured before and on days 1, 2, 3 and 5 after the operation. Statistical analysis was performed using the Mann-Whitney U-test. Of 34 patients, 16 were treated by laser and 18 by stapler. Age, sex ratio and ASA grade did not differ between the groups. Postoperative leukocytosis was significantly milder in the stapler group compared with patients who were treated by carbon dioxide laser. The mean C-reactive protein (CRP) level on day 1, 2 and 3 after surgery was significantly higher in the CO₂ laser group than in the stapler group. Leukocyte counts recovered on day 3 after surgery in both groups while CRP levels did not decline to preoperative levels at day 5 after the operation in either group. No inflammatory complications such as mediastinitis or pneumonia occurred. In conclusion, the inflammatory response in the early period after carbon dioxide laser diverticulotomy of Zenker's diverticulum is higher than after stapler-assisted surgery of Zenker's diverticulum.

KEY WORDS: Zenker's diverticulum • C reactive protein • Leukocytosis • Stapler • CO₂ laser

RIASSUNTO

Il diverticolo di Zenker può essere trattato con il laser CO₂ o con l'utilizzo di una suturatrice lineare. È stato quindi realizzato questo studio retrospettivo condotto su pazienti affetti da diverticolo di Zenker sottoposti, in elezione, a trattamento chirurgico o con laser CO₂ o con suturatrice al fine di analizzare eventuali differenze nella risposta infiammatoria durante il periodo post-operatorio. Sono state misurate la conta dei leucociti e la proteina C-reattiva nel sangue periferico sia il giorno prima dell'operazione, sia in prima, seconda, terza e quinta giornata post-operatoria. È stata quindi eseguita l'analisi statistica utilizzando il Test U di Mann-Whitney. Dei 34 pazienti, 16 sono stati trattati con laser e 18 con suturatrice. Non c'erano differenze di età, sesso e grado ASA tra i due gruppi. La leucocitosi postoperatoria è stata significativamente più modesta nei pazienti trattati con suturatrice rispetto a quelli trattati con laser; e i livelli di proteina C-reattiva in prima, seconda e terza giornata post-operatoria si sono rivelati significativamente più alti nei pazienti trattati con laser. La conta dei leucociti si è normalizzata in terza giornata postoperatoria, invece i livelli di proteina C-reattiva, in entrambi i gruppi, non sono diminuiti, neppure in quinta giornata postoperatoria. Non si sono verificate complicanze infiammatorie, quali polmoniti o mediastiniti. In conclusione, la risposta infiammatoria precoce dopo diverticolomia con laser CO₂ di un diverticolo di Zenker è maggiore rispetto a quella dopo diverticolomia tramite suturatrice.

PAROLE CHIAVE: Diverticolo di Zenker • Proteina C reattiva • Leucocitosi • Suturatrice • Laser CO₂

Introduction

Zenker's diverticulum is an acquired pulsion diverticulum of the mucosa which develops in the so-called Killian triangle, a triangular shaped area between the oblique muscle fibres of the inferior pharyngeal constrictor muscle and the horizontal muscle fibres of the cricopharyngeus muscle. Zenker's diverticula typically present in middle-aged and elderly individuals, especially during the sev-

enth and eighth decades of life. Dysphagia is the main presenting symptom; other symptoms are regurgitation of undigested food, choking, cough, halitosis, globus, aspiration, pneumonia and oesophageal obstruction. Zenker's diverticulum was first reported in 1767 by Ludlow¹, but named after the German pathologist Friedrich Albert von Zenker who published a case series in 1877². Since the first report of successful open surgical treatment

by Wheeler in 1886³, many options have been described for the treatment of Zenker's diverticulum. The external approach was the treatment of choice for many years. Mosher in 1917 introduced the treatment by rigid endoscopy, sectioning the septum of the diverticulum⁴. In the last decades, endoscopic treatment has gained more popularity also due to the use of carbon dioxide laser, which was introduced by van Overbeek et al.⁵. In 1993, Collard et al. introduced diverticulotomy by using the endostapler⁶.

Since the invention of the carbon dioxide laser and the linear stapling device, these methods have become widely used once they were demonstrated to be secure and precise⁷⁻⁹. Compared with classic surgery the main advantages of the endoscopic approach are shorter operative time, less surgical trauma and lower morbidity rate¹⁰.

Until now, it is unclear which technique is superior in terms of outcomes. It is controversial if the open wound after laser surgery leads to bacterial penetration into the mediastinum and if closure of the wound by stapler prevents a mediastinal bacterial invasion, and therefore minimises complication rates like mediastinitis. Therefore, the issue of early diagnosis of inflammatory changes in the post-operative period is important. Post-operative serial screening of white blood cell count (WBC) and C-reactive protein (CRP) is useful as an indicator of infectious complications. CRP is an acute-phase protein synthesised by hepatocytes, largely in response to pro-inflammatory cytokines¹¹. CRP is not specific for a particular disease, but can arise due to inflammation, trauma, malignancy and tissue infarction. In bacterial infection, CRP levels increase within 6 hours¹². CRP is considered to be useful for detection of an inflammatory response early in its course, and also for monitoring disease activity¹¹. Leukocytosis also commonly accompanies infection and may serve as an early marker for a developing infection. Normal WBC and CRP responses can rule out almost all early infectious complications.

There is no study that has investigated inflammatory changes after rigid endoscopic surgery of Zenker's diverticulum by laser or stapler. The objective of the present study was to investigate whether endoscopic stapler surgery causes a less pronounced release of inflammatory cytokines compared to endoscopic laser surgery.

Materials and methods

This retrospective study included patients having elective endoscopic surgery for Zenker's diverticulum by carbon dioxide laser or stapler from 2001 to 2011 and fulfilled the following inclusion criteria:

- The diagnosis of Zenker's diverticulum was made through clinical and radiologic examination.

- Patients had a baseline examination 1 or 2 days before the procedure. Blood samples for biochemistry were obtained as part of the preoperative examination (day 0) and subsequently at day 1, 2, 3 and 5 upon completion of the procedure.
- C-reactive protein (CRP) and white blood cell count (WBC) at baseline were in the normal range (CRP < 5 mg/l, WBC 4000-10,000/ μ l). Therefore, any inflammatory situations due to comorbidity could be excluded.

The procedures were performed under general anaesthesia. Patients were placed supine with their neck overextended. The diverticular sac was exposed with a Weerda distending operation laryngoscope. After transoral positioning of the laryngoscope in the hypopharynx, the wall containing cricopharyngeus muscle fibers between the diverticular sac and hypopharynx lumen was visualised. Then, division of the septum was performed by CO₂ laser or stapler. By endoscopically dividing the cricopharyngeal muscle the diverticula were marsupialised to become one cavity with the hypopharynx. Post-operatively, patients were kept on total parenteral nutrition for a period of at least 48 hours. A liquid oral diet was introduced at first, followed by solids according to the patients' acceptance. No post-operative routine radiological swallow examination was performed. All patients received intravenous fluid infusion, peri- and post-operative intravenous antibiotics [cefuroxime (1.5 g per 8 h) and metronidazole (500 mg per 12 h)], a proton pump inhibitor and analgesics.

The ASA score is a subjective assessment of a patient's overall health that is based on six classes (I to VI). I: A normal healthy patient; II: A patient with mild systemic disease; III: A patient with severe systemic disease; IV: A patient with severe systemic disease that is a constant threat to life; V: A moribund patient who is not expected to survive without the operation; VI: A declared brain-dead patient whose organs are being removed for donor purposes¹³.

Statistical analysis

The Mann-Whitney-U-test was used to compare sex, age, ASA grade, and WBC and CRP levels of both patient groups. Results were considered statistically significant if $p \leq 0.05$.

Results

In all, 34 patients fulfilled the inclusion criteria and were investigated. Of these, 18 patients underwent stapler-assisted diverticulotomy, and the remaining 16 patients were

subjected to diverticulotomy by carbon dioxide laser. All procedures were performed by an experienced surgeon, who was defined as one having more than 5 years experience as an attending surgeon. In each group, 3 patients were endoscopically treated for Zenker's diverticulum in other hospitals before. Basic parameters of both patient groups prior to Zenker's diverticulum surgery are shown in Table I. There was no significant difference between the two groups of patients in terms of age, sex ratio and ASA grade.

The mean operative time was 15 minutes shorter in the stapler group (53 vs 68 minutes); however, this difference was not statistically significant. No serious post-operative complications such as mediastinitis or pneumonia occurred in either group.

Before the operation, the levels of neither CRP nor WBC were significantly different between two groups. In both groups the WBC peaked as early as one day post-surgery, returning to normal range at the third day after surgery in all patients of both groups. However, there was a significant difference on the first day after surgery between the groups regarding the mean WBC. The patient group who was subjected to carbon dioxide laser diverticulotomy had a significant higher WBC than patients after stapler-assisted surgery ($p < 0.05$) (Fig. 1).

Mean CRP levels reached their maximum 2 days after surgery in both groups and did not decline to preoperative levels at day 5 after the operation. The increase in the carbon dioxide laser group was significantly higher than in the stapler group. Significant differences between both groups were seen on day 1, 2 and 3 after surgery ($p < 0.05$). Figure 2 shows the chronological change in the mean CRP level after surgery.

In one patient of the stapler group revision surgery was performed 6 months later due to recurrence of the diverticulum. In the other patients, no recurrence was observed.

Table I. Demographic details of patients.

	Stapler	Laser
Patients	18	16
Gender		
Male	11	9
Female	7	7
Age mean (range)	68.4 (46-86)	70.9 (56-85)
ASA grade (mean)	2.4	2.5
Primary surgery	15	13
Revision surgery	3	3

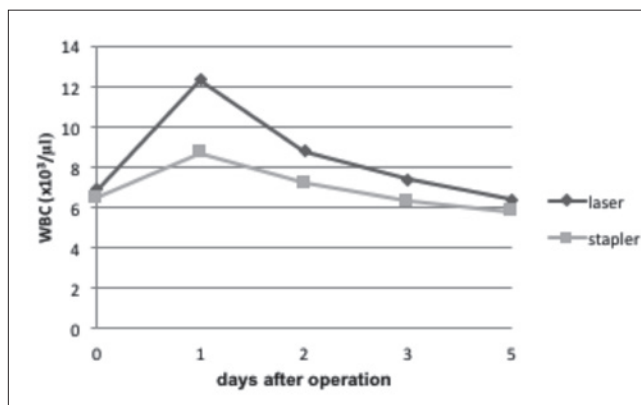


Fig. 1. WBC at baseline (0) and days 1, 2, 3 and 5 after surgery (mean values) in the carbon dioxide laser and stapler groups.

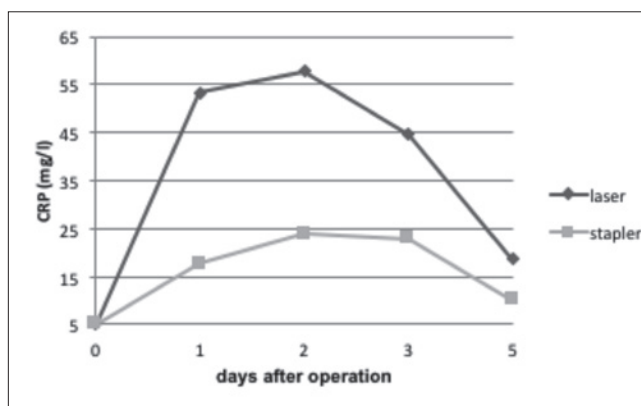


Fig. 2. CRP at baseline (0) and days 1, 2, 3 and 5 after surgery (mean values) in the carbon dioxide laser and stapler groups.

Discussion

Due to its good safety and long-term efficacy, rigid endoscopic surgery of Zenker's diverticulum has become increasingly popular, although there is some controversy about the optimal surgical method¹⁴⁻¹⁶. A recent meta-analysis demonstrated increased non-dental complications in patients treated by CO₂ laser compared to patients treated by stapler, but no difference in overall complications or revision surgery¹⁷. Endoscopic surgery for Zenker's diverticulum can be complicated by inflammatory processes and mediastinitis¹⁸. An elevated WBC and elevated CRP have been associated with an increased risk of inflammatory events. Until now, there are no studies on the inflammatory response after laser surgery or stapler surgery for Zenker's diverticulum. Therefore, the influence of carbon dioxide laser surgery and stapler surgery of Zenker's diverticulum on WBC and CRP were retrospectively investigated.

The present study shows no differences in pre-operative clinical parameters between the two groups. The results showed that endoscopic surgery for Zenker's diverticulum whether performed by carbon dioxide laser or stapler is associated with an inflammatory response. There were no differences between CRP and WBC count at baseline between both groups since values within the normal range at baseline were defined as inclusion criteria. The stapler group was superior to the carbon dioxide laser group in terms of post-operative systemic inflammation. There was a significant lower mean WBC on the first post-operative day and significant lower CRP levels on days 1, 2 and 3 after surgery in patients treated by stapler.

The reason for the lower inflammatory response in the stapler group may be that carbon dioxide laser diverticulotomy causes greater tissue trauma since the stapler has the advantage of simultaneously cutting and sealing the wound edge. It is possible that the inflammatory reactions were the result of possible unnoticed leakages. In order for a leak to occur, the peri-oesophageal fascia must be violated. Because the fascial planes in the neck are continuous with the mediastinum, leakage of oesophageal contents into the neck can cause mediastinitis. The greater physical trauma due to laser surgery may lead to an increased liberation of inflammatory cytokines and enhancing post-operative systemic inflammation. Another cause for the higher inflammatory response in the CO₂ laser group could be the longer mean operative time which was 15 minutes longer in the CO₂ laser group. This difference was not statistically significant although the longer duration of tissue injury can lead to a greater amount of released mediators resulting in a higher inflammatory response. However, in our patients no inflammatory complications occurred and there were no significant differences in outcomes. In one patient in the stapler group a recurrence of the diverticulum occurred, while in the laser group there were no recurrences.

There are some limitations to our study. The first and most obvious is that it consists of a relatively small number of patients who were studied retrospectively. We know that laser surgery is possible when stapler surgery is not, for example in cases with cricopharyngeal dysfunction or small diverticulum. Due to the retrospective nature of the study, we do not know what influences the decision for stapler or laser surgery. Additionally, all patients were treated with intravenous antibiotics in the post-operative period since these antibiotics were part of our treatment scheme. This affected post-operative inflammatory reaction, although antibiotic treatment was the same in both groups.

Conclusions

The inflammatory response in the early period after carbon dioxide laser diverticulotomy of Zenker's diverticulum is higher than after stapler-assisted surgery of Zenker's diverticulum. Prospective studies with larger numbers of patients are needed to further address this issue.

Conflict of interest statement

None declared.

References

- Ludlow A. *A case of obstructed deglutition from a preternatural dilatation of and bag formed in the pharynx*. *Med Obs Inq* 1767;3:85.
- Zenker FA, von Ziemssen H. *Krankheiten des Oesophagus*. In: Von Ziemssen H, ed. *Handbuch der speziellen Pathologie und Therapie*. Leipzig, Germany: FC Vogel; 1877. pp. 1-87.
- Wheeler WI. *Pharyngocele and dilatation of the pharynx, with existing diverticulum at lower portion of pharynx lying posterior to the esophagus, cured by pharyngotomy, being the first of the time recorded*. *Dublin J Med Science* 1886;82:349-56.
- Mosher HP. *Webs and pouches of the oesophagus, their diagnosis and treatment*. *Surg Gynecol Obstet* 1917;25:175-87.
- von Overbeek JJM, Hoeksma P, Edens ETH. *Microendoscopic surgery of the hypopharyngeal diverticulum using electrocoagulation or carbon dioxide laser*. *Ann Otol Rhinol Laryngol* 1984;93:34-6. <https://doi.org/10.1177/000348948409300108>.
- Collard JM, Otte JB, Kenstens PJ. *Endoscopic stapling technique of esophago-diverticulostomy for Zenker's diverticulum*. *Ann Thorac Surg* 1993;56:573-6. [https://doi.org/10.1016/0003-4975\(93\)90906-x](https://doi.org/10.1016/0003-4975(93)90906-x).
- Wilken R, Whited C, Scher RL. *Endoscopic staple diverticulostomy for Zenker's diverticulum: review of experience in 337 cases*. *Ann Otol Rhinol Laryngol* 2015;124:21-9. <https://doi.org/10.1177/0003489414542421>.
- Anagiotos A, Feyka M, Eslick GD, et al. *Long-term symptom control after endoscopic laser-assisted diverticulotomy of Zenker's diverticulum*. *Auris Nasus Larynx* 2014;41:568-71. <https://doi.org/10.1016/j.anl.2014.06.002>.
- Pollei TR, Hinni ML, Hayden RE, et al. *Comparison of carbon dioxide laser-assisted versus stapler-assisted endoscopic cricopharyngeal myotomy*. *Ann Otol Rhinol Laryngol* 2013;122:568-74. <https://doi.org/10.1177/000348941312200906>.
- Koch M, Mantsopoulos K, Velegrakis S, et al. *Endoscopic laser-assisted diverticulotomy versus open surgical approach in the treatment of Zenker's diverticulum*. *Laryngoscope* 2011;121:2090-4. <https://doi.org/10.1002/lary.22152>.
- Cole DS, Watts A, Scott-Coombes D, et al. *Clinical utility of peri-operative C-reactive protein testing in general surgery*. *Ann R Coll Surg Engl* 2008;90:317-21. <https://doi.org/10.1308/003588408X285865>.
- Pepys MB. *C-reactive protein fifty years on*. *Lancet* 1981;1:653-7. [https://doi.org/10.1016/s0140-6736\(81\)91565-8](https://doi.org/10.1016/s0140-6736(81)91565-8).
- <https://www.asahq.org/resources/clinical-information/asa-physical-status-classification-system>
- Verhaegen VJ, Feuth T, van den Hoogen FJ, et al. *Endoscopic carbon dioxide laser diverticulostomy versus endoscopic staple-assisted diverticulostomy to treat Zenker's diverticulum*. *Head Neck* 2011;33:154-9. <https://doi.org/10.1002/hed.21413>.

- ¹⁵ Adam SI, Paskhover B, Sasaki CT. *Laser versus stapler: outcomes in endoscopic repair of Zenker diverticulum*. Laryngoscope 2012;122:1961-6. <https://doi.org/10.1002/lary.23398>.
- ¹⁶ Seth R, Rajasekaran K, Lee WT, et al. *Patient reported outcomes in endoscopic and open transcervical treatment for Zenker's diverticulum*. Laryngoscope 2014;124:119-25. <https://doi.org/10.1002/lary.24152>.
- ¹⁷ Parker NP, Mison S. *Carbon dioxide laser versus stapler-assisted endoscopic Zenker's diverticulotomy: a systematic review and meta-analysis*. Otolaryngol Head Neck Surg 2014;150:750-3. <https://doi.org/10.1177/0194599814521554>.
- ¹⁸ Helmstaedter V, Engel A, Hüttenbrink KB, et al. *Carbon dioxide laser endoscopic diverticulotomy for Zenker's diverticulum: results and complications in a consecutive series of 40 patients*. ORL J Otorhinolaryngol Relat Spec 2009;71:40-4. <https://doi.org/10.1159/000170379>.

Received: January 16, 2017 - Accepted: December 1, 2017

How to cite this article: Hering S, Wiegand S. *Systemic inflammatory response after endoscopic surgery of Zenker's diverticulum*. Acta Otorhinolaryngol Ital 2019;39:230-234. <https://doi.org/10.14639/0392-100X-1576>

Address for correspondence: Susanne Wiegand, Department of Otolaryngology, Head and Neck Surgery, University Hospital Leipzig, Liebigstrasse 12, 04103 Leipzig, Germany. Tel. +49 0341 9721945. E-mail: susanne.wiegand@medizin.uni-leipzig.de