

SURGERY

OPEN

Pedicle Screw Placement Using Augmented Reality Surgical Navigation With Intraoperative 3D Imaging

A First In-Human Prospective Cohort Study

Adrian Elmi-Terander, MD, PhD,^{*,†} Gustav Burström, MD,^{*,†} Rami Nachabe, PhD,[‡] Halldor Skulason, MD,[§] Kyrre Pedersen, MD,[†] Michael Fagerlund, MD, PhD,[¶] Fredrik Ståhl, MD,[¶] Anastasios Charalampidis, MD,^{||,**} Michael Söderman, MD, PhD,^{*,¶} Staffan Holmin, MD, PhD,^{*,¶} Drazenko Babic, MD,[‡] Inge Jenniskens, MSc,[‡] Erik Edström, MD, PhD,^{*,†} and Paul Gerdhem, MD, PhD^{||,**}

Study Design. Prospective observational study.

Objective. The aim of this study was to evaluate the accuracy of pedicle screw placement using augmented reality surgical navigation (ARSN) in a clinical trial.

Summary of Background Data. Recent cadaveric studies have shown improved accuracy for pedicle screw placement in the thoracic spine using ARSN with intraoperative 3D imaging, without the need for periprocedural x-ray. In this clinical study, we used the same system to place pedicle screws in the thoracic and lumbosacral spine of 20 patients.

Methods. The study was performed in a hybrid operating room with an integrated ARSN system encompassing a surgical table, a motorized flat detector C-arm with intraoperative 2D/3D capabilities, integrated optical cameras for augmented reality

navigation, and noninvasive patient motion tracking. Three independent reviewers assessed screw placement accuracy using the Gertzbein grading on 3D scans obtained before wound closure. In addition, the navigation time per screw placement was measured.

Results. One orthopedic spinal surgeon placed 253 lumbosacral and thoracic pedicle screws on 20 consenting patients scheduled for spinal fixation surgery. An overall accuracy of 94.1% of primarily thoracic pedicle screws was achieved. No screws were deemed severely misplaced (Gertzbein grade 3). Fifteen (5.9%) screws had 2 to 4 mm breach (Gertzbein grade 2), occurring in scoliosis patients only. Thirteen of those 15 screws were larger than the pedicle in which they were placed. Two medial breaches were observed and 13 were lateral. Thirteen of the grade 2 breaches were in the thoracic spine. The average screw placement time was 5.2 ± 4.1 minutes. During the study, no device-related adverse event occurred.

Conclusion. ARSN can be clinically used to place thoracic and lumbosacral pedicle screws with high accuracy and with acceptable navigation time. Consequently, the risk for revision surgery and complications could be minimized.

Key words: augmented reality, image-guided surgery, intraoperative 3D cone beam computed tomography imaging, pedicle screw accuracy, scoliosis.

Level of Evidence: 3

Spine 2019;44:517–525

From the ^{*}Department of Clinical Neuroscience, Karolinska Institutet, Stockholm, Sweden; [†]Department of Neurosurgery, Karolinska University Hospital, Stockholm, Sweden; [‡]Department of Image Guided Therapy Systems, Philips Healthcare, Best, The Netherlands; [§]Department of Neurosurgery, Landspítali University Hospital, Reykjavík, Iceland; [¶]Department of Neuroradiology, Karolinska University Hospital, Stockholm, Sweden; ^{||}Department of Clinical Sciences, Intervention and Technology (CLINTEC), Karolinska Institutet, Stockholm, Sweden; and ^{**}Department of Reconstructive Orthopaedics, Karolinska University Hospital, Stockholm, Sweden.

Acknowledgment date: July 5, 2018. First revision date: August 13, 2018. Acceptance date: August 22, 2018.

Drs Elmi-Terander and Burström contributed equally to this work.

The device that is the subject of this manuscript is not FDA-approved and is not commercially available in the United States.

Philips Healthcare/the Netherlands funds were received in support of this work.

Relevant financial activities outside the submitted work: consultancy, patents, grants, employment, travel/accommodations/meeting expenses.

This is an open access article distributed under the terms of the Creative Commons Attribution-Non Commercial-No Derivatives License 4.0 (CCBY-NC-ND), where it is permissible to download and share the work provided it is properly cited. The work cannot be changed in any way or used commercially without permission from the journal.

Address correspondence and reprint requests to Rami Nachabe, PhD, Department of Image Guided Therapy Systems, Philips Healthcare, Veenpluis 6, 5684 PC Best, The Netherlands; E-mail: rami.nachabe@philips.com

DOI: 10.1097/BRS.0000000000002876

Misplaced pedicle screws can result in neurological or vascular injuries or insufficient bone purchase and need for revision surgery. The literature shows that pedicle screw placement accuracy ranges from 60% to 97.5% in the lumbar spine, and from 27.6% to 96.5% in the thoracic spine, when the surgery is performed with the free-hand method.¹

Traditionally, intraoperative 2D radiographic imaging is performed to guide and assess screw placement. However, it only detects 52% of misplaced screws compared to 3D computed tomography (CT) imaging.² Thus, 3D imaging

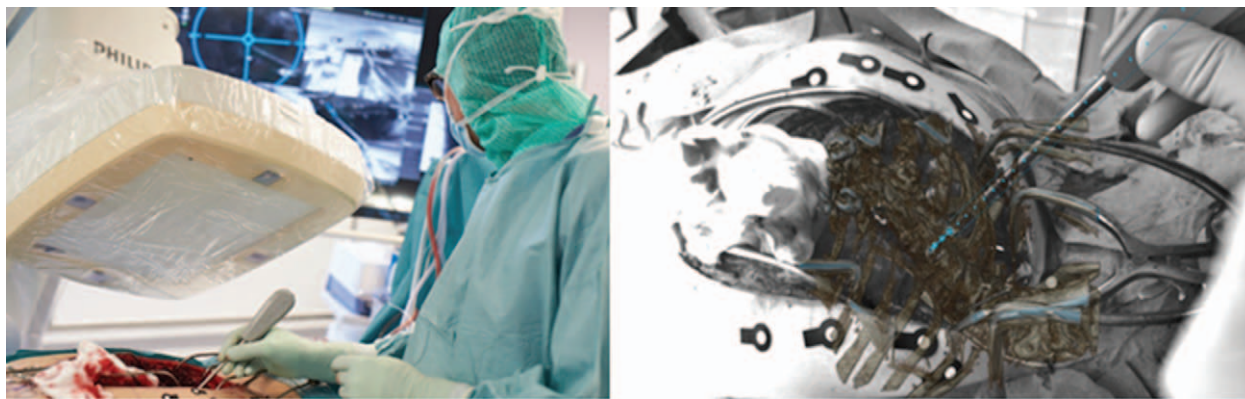


Figure 1. Operating surgeon placing an awl to create an initial entry point to the pedicle (subfigure on the left) and screenshot of displayed scene on the medical monitor showing the augmented reality with the 3D scoliotic thoracic spine of the patient and the planned path for screw placement (subfigure on the right).

becomes a necessity in the operating room (OR) to allow for the immediate evaluation and correction of misplaced screws. It has been documented that intraoperative 3D imaging enables immediate intraoperative revision in 9% of screws corresponding to 35% of the treated patients.³

Another technological advancement brought into the OR to reduce screw malposition rate is the use of intraoperative 3D imaging in combination with a navigation system. Several meta-analyses have demonstrated that pedicle screw placement accuracy using intraoperative 3D navigation (i3Dn) is significantly higher than when using the free-hand method, 2D navigation, or preoperative CT navigation.⁴⁻⁶ This is especially important in scoliosis treatment where most of the screws are placed in the thoracic spine where the pedicles are narrow.^{7,8} Consequently, i3Dn decreases the risk of revision surgery to almost half of that associated with the free-hand method.^{9,10}

State-of-the-art i3Dn systems use passive optical infrared cameras with a dynamic reference frame attached to the spine for patient tracking.¹¹ Intraoperative 3D augmented reality surgical navigation (ARSN) is a novel concept of navigation using optical video cameras to augment the surgical field with 3D intraoperative imaging with a navigation path for screw placement. Patient tracking is ensured by video tracking of noninvasive markers placed on the skin. The intraoperative 3D imaging is performed with a robotic ceiling-mounted C-arm in a hybrid OR. A preclinical study on cadavers demonstrated a significant improvement in pedicle screw placement accuracy in the thoracic spine with ARSN compared to free-hand.¹² In this study, we present the first clinical results using ARSN in a hybrid OR.

MATERIALS AND METHODS

Patient Data

The study was a prospective observational study approved by the ethics committee including patients of 16 years and older. All enrolled patients signed informed consent.

The Hybrid Operating Room with Intraoperative 3D Augmented Reality Navigation System

The study was conducted in a hybrid OR equipped with a radiolucent, motorized, carbon fiber surgical table connected to a robotic ceiling-mounted C-arm system (AlluraClarity Flexmove, Philips, Best, The Netherlands). The ARSN system is based on video input from four optical cameras mounted into the frame of the C-arm detector (Figure 1). Patient tracking is ensured by continuous video detection of flat, adhesive circular markers placed on the surface around the surgical field. The C-arm enables 3D cone-beam CT (XperCT, Philips, Best, The Netherlands) scans for planning screw placement as well as confirming proper screw position. The vertebrae and corresponding pedicles are automatically segmented on the planning XperCT scan. The optimal screw path through the vertebra as well as screw dimensions, that is, width and length, are specified by the operator (Figure 2). The intraoperative XperCT and the planned paths for screw placement are augmented to the video images showing the surgical field. The screws are navigated to the desired location by following the planned path displayed on a medical grade monitor (Figure 1).¹²

Surgical Procedure and Workflow

The subjects were placed under general anesthesia in prone position on the surgical table. The optical markers were placed on the skin around the incision after completed dissection and prior to XperCT acquisition of the region of interest. Subsequently, an automatic 3D segmentation of the region of interest to identify the vertebrae and their pedicles was performed. The surgeon selected the appropriate pedicles one at a time, and virtual screw positions were defined. If desired, the surgeon adjusted the planning for each screw. The screws to be placed were then, one by one, activated in the system; for each screw, the C-arm rotated to the proper position to display the path to follow for instrument navigation.

In deformity cases, the surgeon performed hybrid constructs where hooks were placed or levels were skipped when deemed necessary.

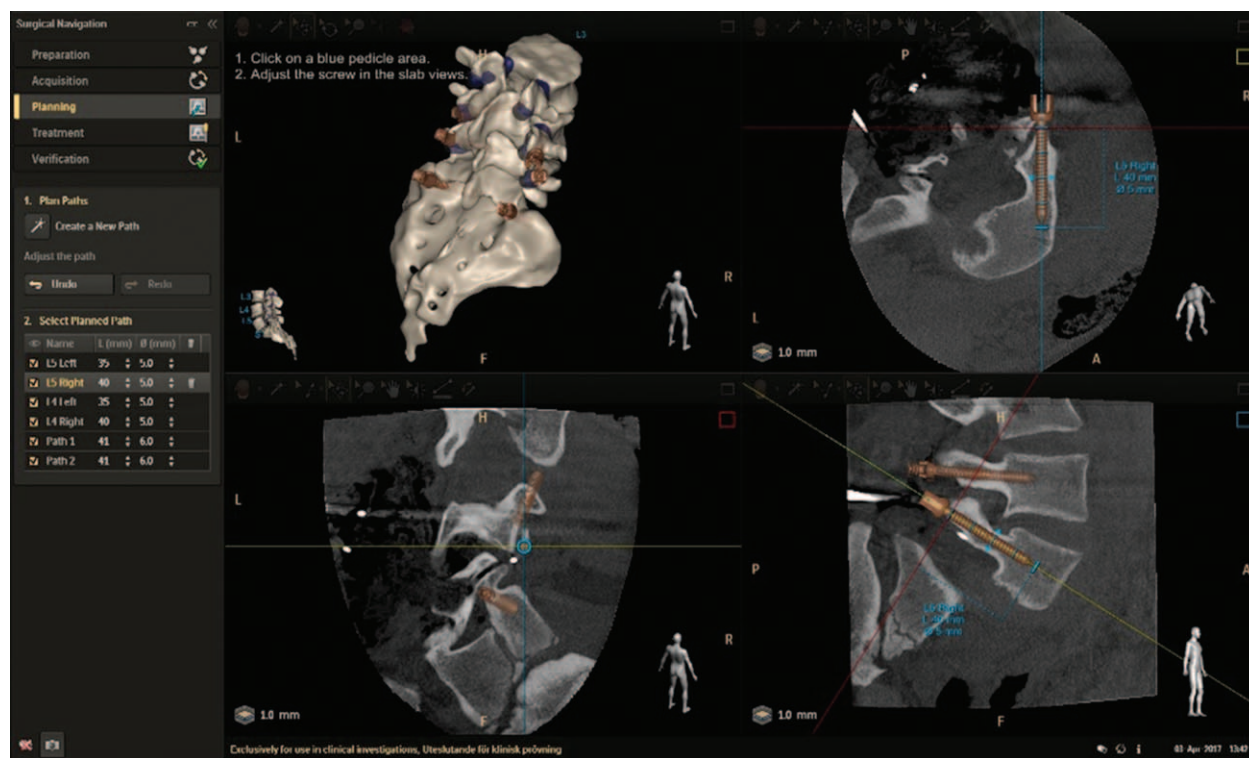


Figure 2. Screw path planning and size selection on the automatically segmented spine and pedicles.

The entry-point on the bone was identified with augmented reality and an awl was used to create an initial hole. Subsequently, a gearshift or power drill was used to navigate along the planned path and probe for cortical breach before screw placement with a screw driver with the help of the ARSN system (Figure 1).

When all screws were placed, an intraoperative XperCT was performed to verify the screw positions. A screw was revised if the surgeon judged its position unsatisfactory. Neurophysiological monitoring was performed at the end of the procedure to assess the likelihood of pedicle breach. Postoperative CT were not performed as XperCT was deemed adequate for clinical evaluation.

Navigation time per screw from preparing the entry point on the bone to final screw placement was documented. Screw diameters and intraoperative neurophysiological monitoring to assess motor and sensory responses were documented as part of standard care.

Analysis of Screw Placement Accuracy

Two neuroradiologists and an orthopedic spine surgeon independently assessed screw positions using the Gertzbein grading for clinical accuracy evaluation: grade 0 (screw within the pedicle without cortical breach), grade 1 (0–2 mm breach, minor perforation including cortical encroachment), grade 2 (>2–4 mm breach, moderate breach), and grade 3 (>4 mm breach, severe displacement).¹³ Breach direction (lateral *vs.* medial) in case of grade 2 or 3 was documented. The pedicle widths were measured to correlate with the assigned grades.¹²

Statistical Analysis

Descriptive summary statistics are expressed as mean (\pm standard deviation), median (min-max range), or frequency (percentage), as appropriate. Jonckheere-Terpstra test was applied to demonstrate trends. Normality test was applied to the data, with skewness and kurtosis calculations to identify outliers from the data distribution. Statistical significance was set at $P < 0.05$.

RESULTS

A total of 20/21 consecutive patients underwent spine surgery with 253 pedicle screws placed using ARSN between January and October 2017. One obese patient (body mass index of 37) did not undergo surgery under ARSN because proper isocentering of the spine could not be achieved causing cropped 3D visualization of the spine and limited space between the detector and the patient for navigation. Most screws (64.4%) were placed in the thoracic spine. Most patients (65.0%) had scoliotic deformity with a total of 207 implanted screws (81.8%). One of the surgeries was a complex revision surgery of an imbalanced scoliotic spine previously treated with fusion and Harrington rods. The scoliosis patients had a preoperative major curve Cobb angle of $55^\circ \pm 14^\circ$. All surgeries were performed by the same orthopedic surgeon with 18 years of experience in deformity surgery and without prior experience with any type of navigation systems. Table 1 summarizes patients' demographics and surgical characteristics.

Out of all 253 screws placed with ARSN, three (1.2%) were revised intraoperatively after being judged unsatisfactory

TABLE 1. Patient Demographics and Surgical Characteristics

Characteristics	Value
Number of patients	20 (100%)
Male-female	9–11 (45%–55%)
Age (yr)	30.5 ± 19.4
	18.5 [16–72]
Weight (kg)	58.8 ± 7.0
	60 [45–71]
BMI (kg/m ²)	19.8 ± 2.1
	19.9 [15.0–23.3]
Primary diagnosis	
Scoliosis*	13 (65%)
Spondylolisthesis	3 (15%)
Post-fracture kyphosis	1 (5%)
Stenosis	1 (5%)
Degenerative disc	1 (5%)
Kyphosis	1 (5%)
Total number of navigated screws	253 (100%)
Thoracic spine	163 (64.4%)
Lumbosacral spine	90 (35.6%)
Screw diameter (mm)	5.8 ± 1.1
	6.0 [4.35–9]

BMI indicates body mass index.
*One of the scoliosis cases was a complex revision surgery.

by the surgeon. Because all pedicles visible on XperCT were planned for screw placement, attempts to place screws were made in eight pedicles where our institutional clinical practice is to place hooks or avoid instrumenting the pedicle. Seven pedicles were instrumented by the free-hand method because the navigation system could not achieve line of sight to the bone entry-point: in two cases spine exposure was not wide enough obstructing proper alignment of the instruments, in two cases we had limited visibility and accessibility to the entry point on the bone, in one case tissue was still present on top of the bone at the entry point, and in two cases the pedicle was reported as too small with uncompleted documentation on the reason of not using navigation or placing a hook instead. These cases corresponded to one case with spondylolisthesis and four with scoliosis. These four scoliosis cases had a more severe curve size ($65^\circ \pm 10^\circ$) than the other scoliosis cases ($51^\circ \pm 13^\circ$).

Neurophysiological monitoring, including pedicle screw stimulation in the deformity cases, did not show any indication of breach and there were no ARSN device-related adverse event.

Radiation dose exposure to the main surgeon ranged from 0 to 1.1 μ Sv, and patient dose index (air kerma at patient's entrance surface) ranged from 48 and 322 mGy.

Accuracy

The number of screws judged as grade 0, 1, and 2 were 161, 77, and 15, respectively. There were no screws considered

TABLE 2. Accuracy of Navigated Screws

Screw assessment	Frequency (%)
Grade 0 + 1	238 (94.1%)
Grade 0	161 (63.6%)
Grade 1	77 (30.4%)
Grade 2 + 3	15 (5.9%)
Grade 2	15 (5.9%)
Grade 3	0 (0.0%)

severely misplaced (*i.e.*, grade 3). Thus, the ARSN accuracy for screw placement was 94.1% (Table 2). All the grade 2 screws occurred in the scoliosis cases. They were mainly lateral breaches (13/15 *vs.* 2/15 of medial breaches). Two grade 2 screws occurred in the lumbosacral region, of which one was in the revision surgery case. Figure 3 depicts the distribution of grades for all screws per spinal level along with the corresponding pedicle widths. The average pedicle width-to-screw size ratio was 1.3 ± 0.7 ; and were 1.4 ± 0.8 , 1.0 ± 0.3 , and 0.8 ± 0.2 for screws rated as grade 0, 1, and 2, respectively. The decreasing trend of this ratio with increasing level of breaches was statistically significant, $P < 0.05$ (Figure 4). The pedicle width-to-screw size ratio was superior to 1 in only 2/15 grade 2 screws.

Figure 5 shows an example of a 4.35-mm screw which was placed in a 2.5-mm wide pedicle and was judged as a grade 2 breach.

Screw Navigation Time

The navigation time for screw placement did not follow a normal distribution ($P < 0.05$). Half of the total amount of screws was navigated in less than 4.0 minutes. The average time for screw navigation was 5.2 ± 4.1 minutes. The screw placement time was skewed to lower values (skewness of 3.1) and the kurtosis was 14.7 suggesting outliers from the screw placement time distribution (Figure 6). The average screw placement time for each surgical procedure is depicted in Figure 7.

DISCUSSION

This clinical study is the first to assess ARSN for pedicle screw placement in a hybrid OR. The achieved accuracy with this navigation technology was 94.1% out of a total of 253 screw placements in 20/21 consecutive patients. Most grade 2 screws (13/15) in this study were lateral, in agreement with previously published data.¹⁴ The intraoperative screw revision rate of 1.2% was within the reported range of 0 to 3% from existing i3Dn studies, yielding a significant reduction in revision surgery thanks to the intraoperative 3D imaging in the OR.^{15–22}

The main risk factor for pedicle screw breach is narrow pedicles.^{12,23–25} The narrowest pedicles are in the mid-thoracic (T5–T8) levels with an average width of 4 mm (Figure 3).^{24,26} Consequently, the mid-thoracic region is the spinal region with the highest reported amount of grade 2 screws.^{26,27} The smallest pedicle screw diameter used in

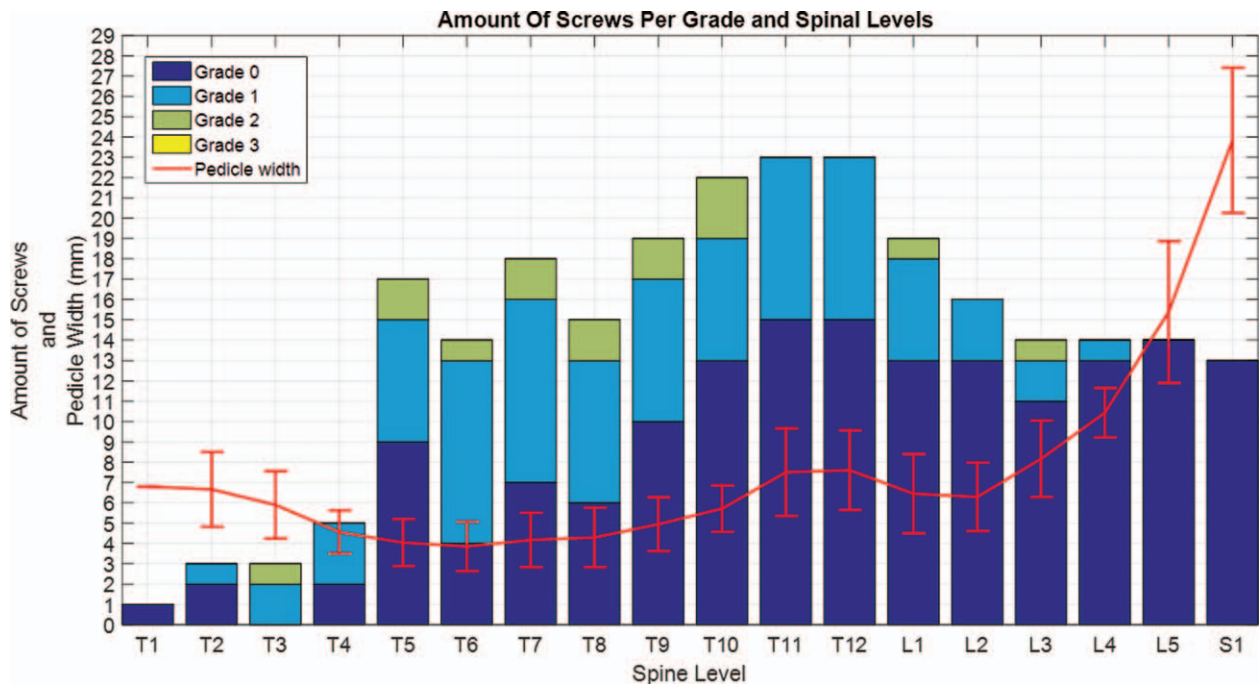


Figure 3. Distribution of amount per screws (histogram) and mean \pm standard deviation of pedicle widths (continuous line with bars) per spinal level.

this study was 4.35 mm, which consequently implies that breaches as determined by the Gertzbein scale were expected. However, neurophysiological monitoring showed no signs of neurological injuries. In idiopathic and congenital scoliosis, pedicles are dysplastic and tend to be smaller on the convex side of the deformity, especially in the upper vertebra.²⁸ The accuracy of pedicle screw placement highly depends on the size of the pedicles. Misplacement screw rate increases from 2.9% to 31.5% for pedicles between 2 and 4 mm to pedicles below 1 mm when placed by free hand.²⁵ When the screws were placed with i3Dn, the accuracy was 93.8% and 91.7% in pedicles of widths above and below 3 mm, respectively.²⁹

The pedicle-to-screw size ratio is an important factor for preventing screw pullout. It was demonstrated that the ability of i3Dn to plan and optimize screw size reduced the pedicle-to-screw size ratio from 1.6 to 1.4 for non-navigated techniques.³⁰ In this study, the pedicle-to-screw size ratio was 1.3 ± 0.7 which is comparable to reported values of 1.3 ± 0.3 by Hecht *et al*. However, our standard deviation was higher due to the high proportion of scoliosis cases in our cohort with very small pedicles.¹⁶ In some cases, we deliberately opted for screws larger than the pedicle for better bone purchase instead of placing hooks or not instrumenting the pedicles. Rajasekaran *et al*³¹ reported that 10/27 misplaced screws were intentional as the “in-out-in” technique was used. Strictly following the Gertzbein scale, although clinically safe, these screws are considered as inaccurate placements.

To compare our results with the existing literature, it is thus important to know the proportion of screws placed in the thoracic *versus* the lumbosacral spine as the smallest

pedicle widths in the thoracic spine yield lower accuracy. For the sake of proper comparison with our study, we searched available studies in the literature which (1) used i3Dn with automatic registration between the navigation and the intraoperative imaging, (2) placed screws in T1 to S1, (3) provided the numbers of screws placed in the thoracic and lumbar spine, (4) and assessed accuracy based on the Gertzbein scale. Eight studies were identified with accuracy ranging from 90.2% to 98.6%.^{15,16,27,31–35} This variation in accuracy highly correlates with the percentage of thoracic screws ranging from 8.2% to 73.9% (correlation of -0.90 , $P < 0.05$). Our accuracy falls within the range reported in literature with 64.4% of thoracic screws.

Another risk factor of pedicle screw misplacement described in the literature is the distance between the position of the dynamic reference frame for patient tracking and the operated spinal level.^{16,27,36} In scoliosis patients, screw malposition rate with i3Dn increases from 4.8% to 20.6% when instrumenting a vertebrae adjacent to the one with the reference frame *versus* three or more levels away.²⁷ With the noninvasive tracking of the markers on the patient skin, there is no such dependency. However, because the tracked markers are on the skin surface around the incision, it is important that the tissue above the surgical field is retracted widely enough to have free access to pedicles with large transverse angles. In the beginning of the study, two screws were placed using the free-hand technique at L5 because the tissue above that vertebra was obscuring the navigation systems' line of sight since the skin incision was not wide enough. L5 is known to have the pedicles with the largest transverse pedicle angle; with an angle of 30° almost twice as wide as L4.³⁷ Throughout this study and increased

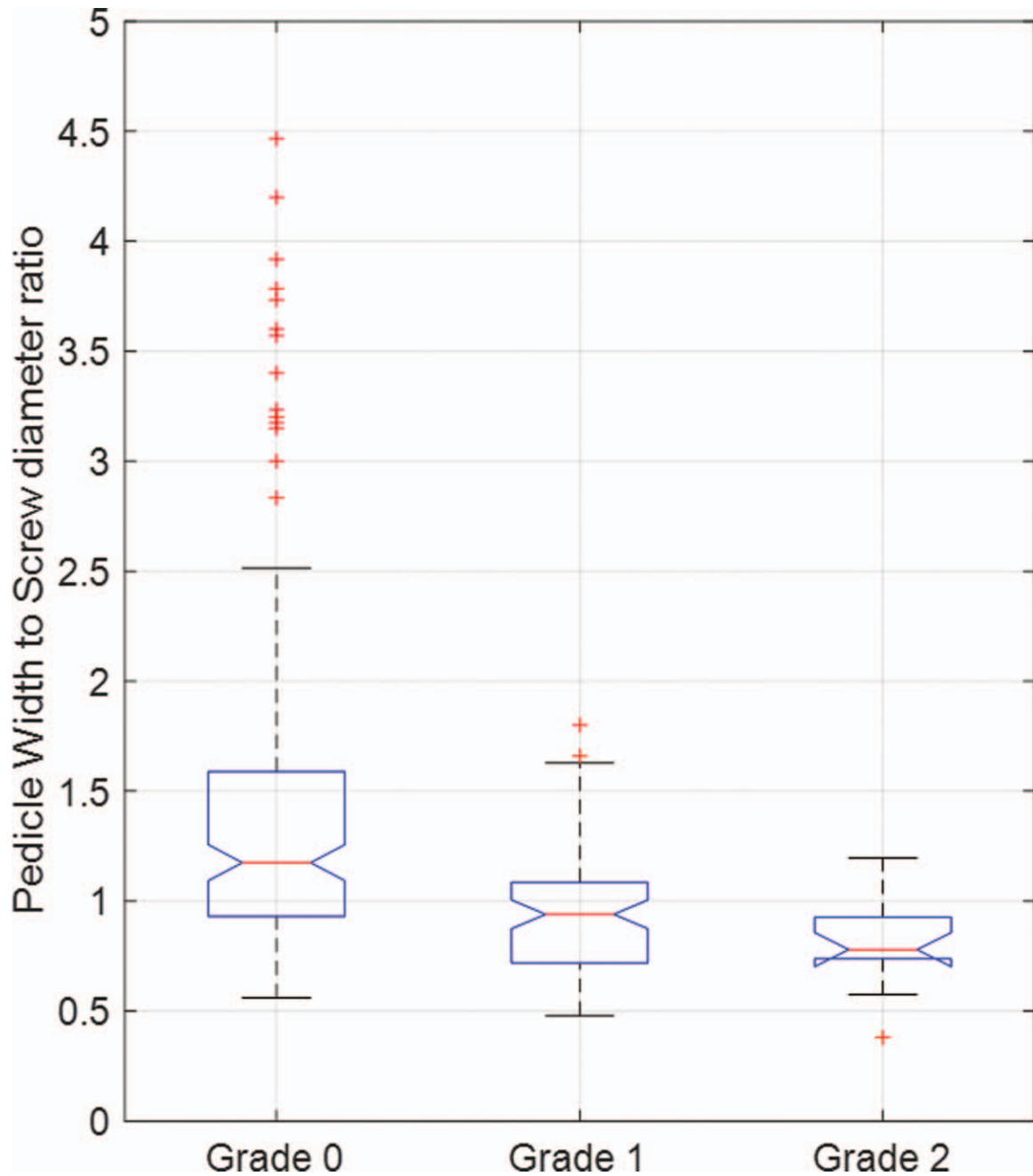


Figure 4. Pedicle width box plot per Gertzbein grade.

experience-building with the technology, adequate skin incision in the lumbosacral junction was performed to be able to properly navigate instruments with ARSN.

The average navigation time for screw placement was 5.2 ± 4.1 minutes and is comparable to values reported in other i3Dn studies, for example, Zhang *et al*⁴ and Kotani *et al*³⁸ which reported 5.1 ± 1.1 and 5.4 ± 1.1 minutes, respectively. However, our standard deviation for screw placement is larger as probably a learning curve effect is associated to it. Hence the skewness and outliers of the distribution of screw placement time is shown in Figure 6. In fact, the first case was a four-screw placement surgery in which each screw was placed in more than 17 minutes as the

surgeon took extra care for his first clinical experience with the technology. Although our average navigation time per screw placement is comparable to existing values in literature, shorter average navigation time per screw placement of 1.8 ± 0.9 minutes was reported. However, the authors nuanced this short time compared to existing literature explaining that the operating surgeon had a long experience with navigation technology and its associated learning curve.³¹

There are some differences between the augmented reality system and traditional i3Dn systems. The augmented reality system has cameras integrated within the C-arm, reducing the amount of equipment in the OR. In

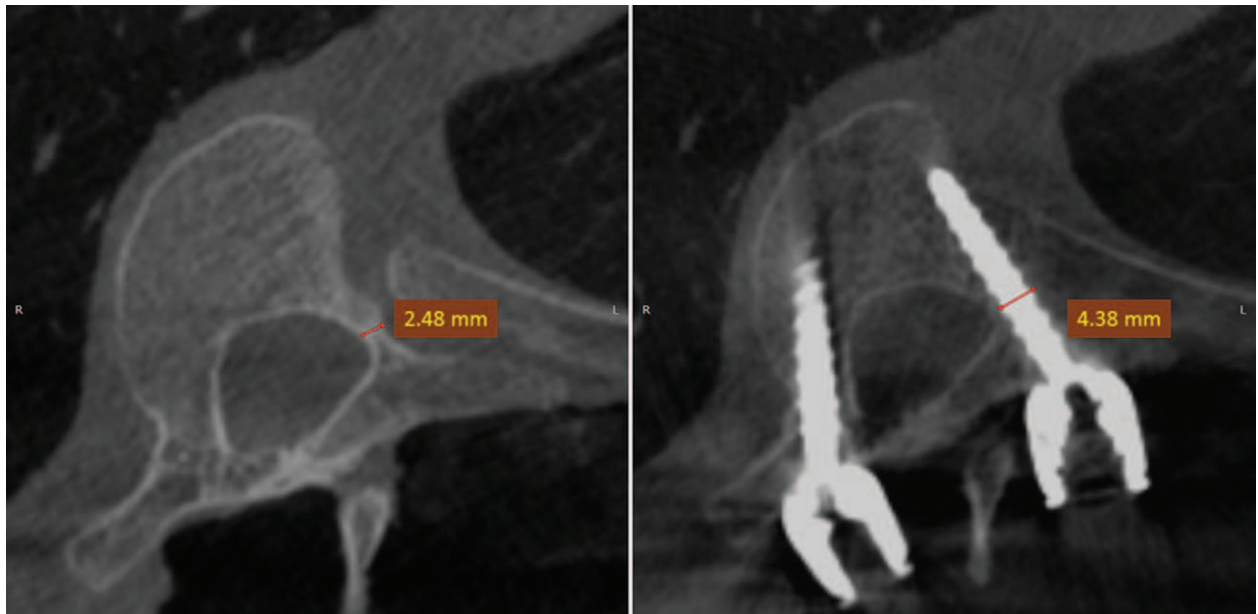

Figure 5. Planning 3D-Cone Beam CT showing pedicle isthmus measurement of 2.5 mm at T7 left in the concave side and at the apical region of a scoliotic patient (left sub-figure). Corresponding verification 3D-CBCT scan with a 4.35 mm 80% larger than the pedicle (pedicle-to-screw size) which was rated as a grade 2 screw.

addition, there are no line-of-sight issues as four cameras with four different viewing directions are used for navigation instead of only one camera with a single viewing direction such as in traditional navigation systems. The noninvasive skin markers are quick to place and their

tracking is robust; a new registration is not needed in case some markers are touched or accidentally removed. The dynamic reference frame from traditional navigation can be inadvertently touched and therefore a new registration is needed requiring an additional intraoperative 3D scans

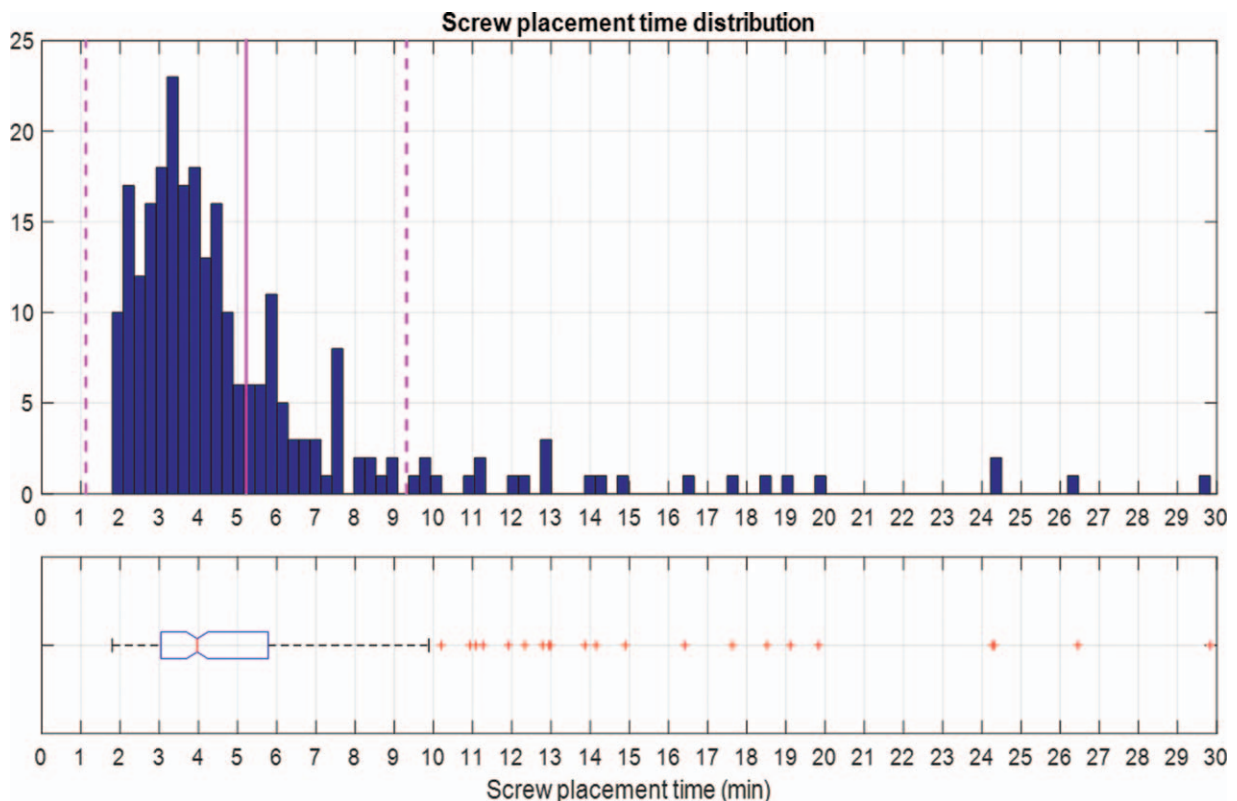


Figure 6. Distribution of screw placement time with mean (solid vertical line) and standard deviation (dashed vertical lines) as well as box plot depicting median, quantile, and outliers (red crosses) from distribution.

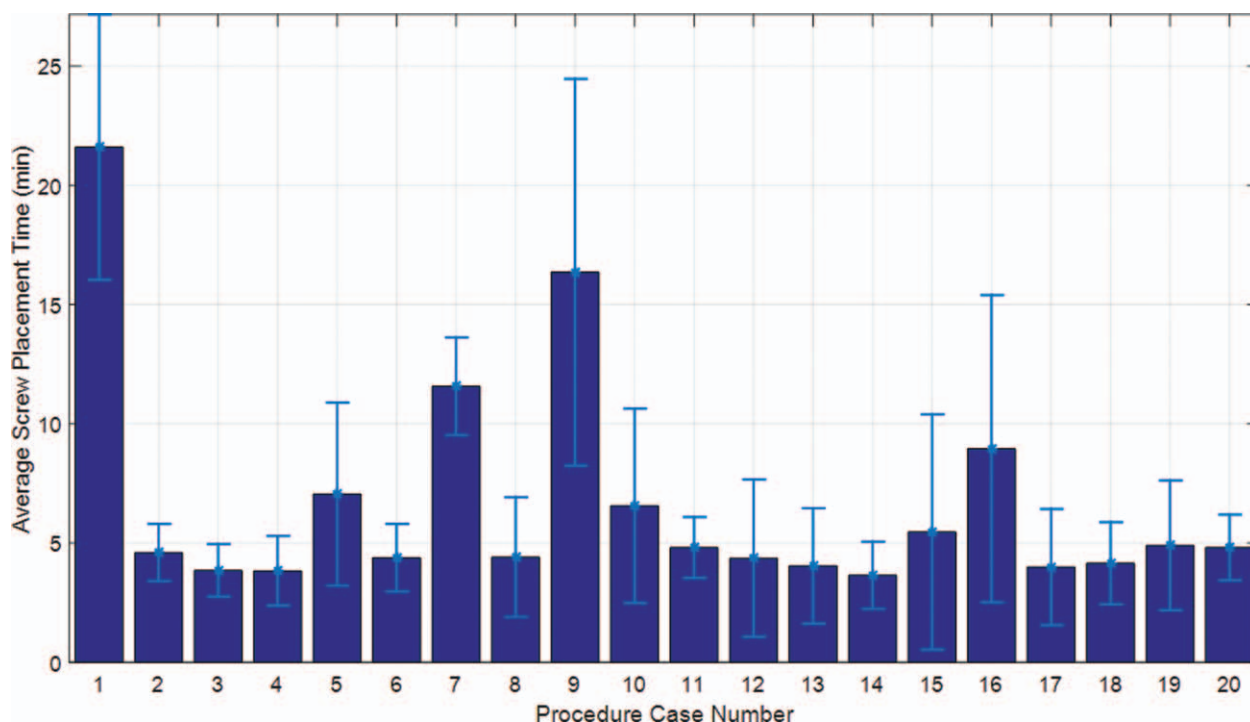


Figure 7. Average screw navigation time per case, the error bars correspond to standard deviations.

yielding extra radiation exposure to the patient and staff. Furthermore, traditional navigation accuracy decreases when the distance between the instrumented spinal levels and the vertebrae with the attached dynamic reference frame increases.³⁶ This issue is not applicable to the augmented reality navigation system as the markers are placed on a wide area of the skin surface around the surgical incision (Figure 1).

The main limitation of our study is that it is not a randomized controlled study to assess the difference in performance and clinical outcomes with a conventional method. A larger cohort study would potentially help in assessing the learning curve effect of ARSN. Rivkin *et al*³² demonstrated in 270 patients that accuracy increased from 86.8% to 98.9% when analyzing every 30 consecutive patients. Ryang *et al*³⁹ analyzed data every quarter of a year and demonstrated that accuracy increased from 83.1% to 92.4% over four quarters, whereas the average pedicle screw time decreased from a comparable time to our study of 5.3 ± 2.5 down to 3.2 ± 2.3 minutes. Finally, one enrolled subject was not treated with ARSN due to the limited gantry of the robotic C-arm which does not enable imaging of very obese patients with an x-ray source-to-detector distance of 120 cm; a 3D imaging limitation which also applies to other intraoperative imaging such as the O-arm with equal x-ray source-to-detector distance.⁴⁰

CONCLUSION

ARSN in a hybrid OR achieves high accuracy in pedicle screw placement (94.1%) with acceptable navigation time. Further studies are needed to confirm our results and

reassess the performance over a longer period with a larger cohort.

➤ Key Points

- ❑ Intraoperative 3D augmented reality navigation in a hybrid OR is feasible with a high accuracy of 94.1% in this series of primarily thoracic pedicle screws.
- ❑ There was no case of severely misplaced screws in this study, using the intraoperative 3D augmented reality navigation system.
- ❑ The risk of breach increases with the screw to pedicle diameter ratio.
- ❑ The use of ARSN with intraoperative 3D was associated with an acceptable navigation time for screw placement comparable to other navigation systems.

References

1. Kosmopoulos V, Schizas C. Pedicle screw placement accuracy: a meta-analysis. *Spine (Phila Pa 1976)* 2007;32:111–20.
2. Sarwahi V, Ayan S, Amaral T, et al. Can postoperative radiographs accurately identify screw misplacement? *Spine Deform* 2017; 5:109–16.
3. Bydon M, Xu R, Amin AG, et al. Safety and efficacy of pedicle screw placement using intraoperative computed tomography: consecutive series of 1148 pedicle screws. *J Neurosurg Spine* 2014; 21:320–8.
4. Zhang w, Takigawa T, Wu Y, et al. Accuracy of pedicle screw insertion in posterior scoliosis surgery: a comparison between

- intraoperative navigation and preoperative navigation techniques. *Eur Spine J* 2017;26:1756–64.
5. Liu H, Chen W, Liu T, et al. Accuracy of pedicle screw placement based on preoperative computed tomography versus intraoperative data set acquisition for spinal navigation system. *J Orthop Surg* 2017;25:1–8.
 6. Du JP, Fan Y, Wu QN, et al. Accuracy of pedicle screw insertion among 4 image-guided navigation systems: systematic review and meta-analysis. *World Neurosurg* 2018;109:24–30.
 7. Tian W, Zeng C, An Y, et al. Accuracy and postoperative assessment of pedicle screw placement during scoliosis surgery with computer-assisted navigation: a meta-analysis. *Int J Med Robot* 2017;13:.
 8. Chan A, Parent E, Narvacan K, et al. Intraoperative image guidance compared with free-hand methods in adolescent idiopathic scoliosis posterior spinal surgery: a systematic review on screw-related complications and breach rates. *Spine J* 2017;17:1215–29.
 9. Xiao R, Miller JA, Sabharwal NC, et al. Clinical outcomes following spinal fusion using an intraoperative computed tomographic 3D imaging system. *J Neurosurg Spine* 2017;26:628–37.
 10. Fichtner J, Hofmann N, Rienmuller A, et al. Revision rate of misplaced pedicle screws of the thoracolumbar spine-comparison of three-dimensional fluoroscopy navigation with freehand placement: a systematic analysis and review of the literature. *World Neurosurg* 2018;109:e24–32.
 11. Rahmathulla G, Nottmeier EW, Pirris SM, et al. Intraoperative image-guided spinal navigation: technical pitfalls and their avoidance. *Neurosurg Focus* 2014;36:E3.
 12. Elmi-Terander A, Skulason H, Soderman M, et al. Surgical navigation technology based on augmented reality and integrated 3D intraoperative imaging: a spine cadaveric feasibility and accuracy study. *Spine (Phila Pa 1976)* 2016;41:E1303–11.
 13. Gertzbein SD, Robbins SE. Accuracy of pedicular screw placement in vivo. *Spine (Phila Pa 1976)* 1990;15:11–4.
 14. Gelalis ID, Paschos NK, Pakos EE, et al. Accuracy of pedicle screw placement: a systematic review of prospective in vivo studies comparing free hand, fluoroscopy guidance and navigation techniques. *Eur Spine J* 2012;21:247–55.
 15. Costa F, Dorelli G, Ortolina A, et al. Computed tomography-based image-guided system in spinal surgery: state of the art through 10 years of experience. *Neurosurgery* 2015;11:59–67.
 16. Hecht N, Yassin H, Czabanka M, et al. Intraoperative computed tomography versus 3D C-arm imaging for navigated spinal instrumentation. *Spine (Phila Pa 1976)* 2018;43:370–7.
 17. Silbermann J, Riese F, Allam Y, et al. Computer tomography assessment of pedicle screw placement in lumbar and sacral spine: comparison between free-hand and O-arm based navigation techniques. *Eur Spine J* 2011;20:875–81.
 18. Patil S, Lindley EM, Burger El, et al. Pedicle screw placement with O-arm and stealth station. *Orthopedics* 2012;35:E61–5.
 19. Van de Kleef E, Costa F, Van der Planken D, et al. A prospective multicenter registry on the accuracy of pedicle screw placement in the thoracic, lumbar, and sacral levels with the use of the O-arm imaging system and StealthStation navigation. *Spine (Phila Pa 1976)* 2012;37:E1580–7.
 20. Ling JM, Dinesh SK, Pang BC, et al. Routine spinal navigation for thoraco-lumbar pedicle screw insertion using the O-arm three-dimensional imaging system improves placement accuracy. *J Clin Neurosci* 2014;21:493–8.
 21. Ammirati M, Salma A. Placement of thoracolumbar pedicle screws using O-arm-based navigation: technical note on controlling the operational accuracy of the navigation system. *Neurosurg Rev* 2013;36:157–62.
 22. Kleck C, Cullimore I, Lafleur M, et al. A new 3-dimensional method for measuring precision in surgical navigation and methods to optimize navigation accuracy. *Eur Spine J* 2016;25:1764–74.
 23. Lekovic G, Potts E, Karahalios. et al. A comparison of two techniques in image-guided thoracic pedicle screw placement: a retrospective study of 37 patients and 277 pedicle screws. *J Neurosurg Spine* 2007;7:393–8.
 24. Waschke A, Walter J, Duenisch P, et al. CT-navigation versus fluoroscopy-guided placement of pedicle screws at the thoracolumbar spine: single center experience of 4500 screws. *Eur Spine J* 2013;22:654–60.
 25. Akazawa T, Kotani T, Sakuma T, et al. Evaluation of pedicle screw placement by pedicle channel grade in adolescent idiopathic scoliosis: should we challenge narrow pedicles? *J Orthop Sci* 2015;20:818–22.
 26. Larson AN, Santos ER, Polly DW Jr, et al. Pediatric pedicle screw placement using intraoperative computed tomography 3-dimensional image-guided navigation. *Spine (Phila Pa 1976)* 2012;37:E188–94.
 27. Jin M, Liu Z, Qiu Y, et al. Incidence and risk factors for the misplacement of pedicle screws in scoliosis surgery assisted by O-arm navigation-analysis of a large series of one thousand, one hundred and forty five screws. *Int Orthop* 2017;41:773–80.
 28. Sarwahi V, Wendolowski SF, Lo Y, et al. End vertebra versus apical vertebra: where are we more likely to misplace in spine deformity? *J Pediatr Orthop* 2017; [Epub ahead of print].
 29. Liu Z, Jin M, Qiu Y, et al. The superiority of intraoperative O-arm navigation-assisted surgery in instrumenting extremely small thoracic pedicles of adolescent idiopathic scoliosis: a case-control study. *Medicine* 2016;95:e3581.
 30. Luther N, Iorgulescu JB, Geannette C, et al. Comparison of navigated versus non-navigated pedicle screw placement in 260 patients and 1434 screws: screw accuracy, screw size, and the complexity of surgery. *J Spinal Disord Tech* 2015; 28:E298–303.
 31. Rajasekaran S, Bhushan M, Aiyer S, et al. Accuracy of pedicle screw insertion by Airo intraoperative CT in complex spinal deformity assessed by a new classification based on technical complexity of screw insertion. *Eur Spine J* 2018; [Epub ahead of print].
 32. Rivkin MA, Yocom SS. Thoracolumbar instrumentation with CT-guided navigation (O-arm) in 270 consecutive patients: accuracy rates and lessons learned. *Neurosurg Focus* 2014;36:E7.
 33. Noshchenko A, Cain C, Zaghloul K, et al. Pedicle screw placement assisted by 3D imaging (O-arm system with StealthStation software) versus free-hand technique for multilevel posterior thoracolumbar fusion. *Curr Orthop Pract* 2018;29:151–6.
 34. Laudato PA, Pierzchala K, Schizas C. Pedicle screw insertion accuracy using O-arm, robotic guidance, or freehand technique: a comparative study. *Spine (Phila Pa 1976)* 2018;43:E373–8.
 35. Hecht N, Kampuis M, Czabanka M, et al. Accuracy and workflow of navigated spinal instrumentation with the mobile AiroCT scanner. *Eur Spine J* 2016;25:716–23.
 36. Scheufler KM, Franke J, Eckardt A, et al. Accuracy of image-guided pedicle screw placement using intraoperative computed tomography-based navigation with automated referencing. Part II: thoracolumbar spine. *Neurosurgery* 2011;69:1307–17.
 37. Zindrick MR, Wiltse LL, Doornik A, et al. Analysis of the morphometric characteristics of the thoracic and lumbar pedicles. *Spine (Phila Pa 1976)* 1987;12:160–6.
 38. Kotani T, Akazawa T, Sakuma T, et al. Accuracy of pedicle screw placement in scoliosis surgery: a comparison between conventional computed tomography-based and O-arm based navigation techniques. *Asian Spine J* 2014;8:331–8.
 39. Ryang YM, Villard J, Obermuller T, et al. Learning curve of 3D fluoroscopy image-guided pedicle screw placement in the thoracolumbar spine. *Spine J* 2015;15:467–76.
 40. Zhang J, Weir V, Fajardo L, et al. Dosimetric characterization of a cone-beam O-arm imaging system. *J Xray Sci Technol* 2009; 17:305–17.