

## CASE REPORT

# Efficacy and safety of low-dose imatinib in an elderly patient with mixed phenotype acute leukemia with t(9;22)(q34;q11.2);BCR-ABL1

Yusuke Okayama<sup>1,2</sup> | Teruhito Takakuwa<sup>1,2</sup>  | Ippei Otomaru<sup>1</sup> | Mirei Horiuchi<sup>1</sup> | Akiko Miura<sup>1</sup> | Taku Araki<sup>1</sup> | Yotaro Fujitani<sup>1</sup> | Ryosuke Yamamura<sup>1</sup>

<sup>1</sup>Department of Hematology, Osaka Saiseikai Nakatsu Hospital, Osaka, Japan

<sup>2</sup>Department of Hematology, Graduate School of Medicine, Osaka City University, Osaka, Japan

## Correspondence

Teruhito Takakuwa, Department of Hematology, Osaka Saiseikai Nakatsu Hospital, 2-10-39, Shibata, kita-ku, Osaka, 530-0012, Japan.

Email: t\_takakuwa@med.osaka-cu.ac.jp

## Abstract

Low-dose imatinib with monitoring of drug concentrations in blood may successfully control Philadelphia chromosome-positive mixed phenotype acute leukemia (Ph+MPAL), particularly in elderly patients with comorbidities.

## KEYWORDS

dasatinib, elderly, imatinib, interstitial pneumonitis, Ph+MPAL

## 1 | INTRODUCTION

Optimal treatment for Philadelphia chromosome-positive mixed phenotype acute leukemia (Ph+MPAL), particularly in elderly patients with comorbidities, has not been established. We present the elderly Ph+MPAL case who discontinued initial treatment with dasatinib and whose disease was successfully controlled by low-dose imatinib with monitoring of drug concentrations in blood.

Mixed phenotype acute leukemia (MPAL), a rare type of acute leukemia that exhibits both myeloid and lymphoid features,<sup>1</sup> comprises 2%-4% of all acute leukemias, and approximately 87% of all MPALs are Philadelphia chromosome-negative.<sup>2</sup> According to the 2016 World Health Organization (WHO) classification, Philadelphia chromosome-positive (Ph+) MPAL meets the diagnostic criteria for MPAL based on the presence of blasts harboring the t(9;22)(q34;q11) translocation or BCR-ABL1 rearrangement in the absence of a history of chronic myeloid leukemia (CML).<sup>3</sup>

There are currently no optimal treatments that have been established for Ph+MPAL, which has a poor prognosis with a 2-year overall survival (OS) rate of 14%.<sup>4</sup> Combination of the BCR-ABL inhibitor imatinib with chemotherapy has improved the 5-year OS rate to 54% in patients with Ph+MPAL, which is comparable to that of patients with Ph+acute lymphoblastic leukemia.<sup>5</sup> Recent studies have reported higher efficacy with second-generation tyrosine kinase inhibitors (TKIs) compared to imatinib.<sup>6,7</sup> However, optimal treatment approaches for elderly patients with Ph+MPAL have not been established because of difficulties in managing comorbidities in these patients. In elderly patients who cannot receive second-generation TKI therapy, imatinib can be considered as an alternative treatment option. However, the efficacy and optimal dose of imatinib in elderly patients with Ph+MPAL are unknown.

Herein, we describe the case of an elderly patient with Ph+MPAL who had a history of cardiovascular disease who was intolerant to dasatinib due to complications; however, switching to low-dose imatinib with monitoring of imatinib

This is an open access article under the terms of the Creative Commons Attribution-NonCommercial License, which permits use, distribution and reproduction in any medium, provided the original work is properly cited and is not used for commercial purposes.

© 2021 The Authors. *Clinical Case Reports* published by John Wiley & Sons Ltd.

concentrations in blood achieved disease control and the continued safe use of imatinib.

## 2 | CASE PRESENTATION

An 87-year-old man coincidentally presented with leukoblastosis at a routine visit of cardiology outpatient in December 2017. He was being treated for heart failure and had undergone percutaneous coronary intervention for proximal, middle, and distal branches of right coronary artery and a circumflex branch of left coronary artery (#1-3 and #12-14). Additionally, he had type 2 diabetes mellitus (DM) and chronic kidney disease. Physical examination showed no particular abnormalities. The laboratory findings were as follows: white blood cell count,  $9.9 \times 10^9/L$  with 21.5% blast cells; hemoglobin, 12.5 g/dL; platelet count,  $20.9 \times 10^9/L$ ; and lactate dehydrogenase, 556 IU/L. Bone marrow examination showed hypocellularity with 41.4% medium- and large-sized blasts, which were negative for myeloperoxidase staining by immunohistochemical analysis (Figure 1). Flow cytometric analysis showed that the blast cells were strongly positive for CD10 (87.9%), CD19 (59.8%), CD33 (84.5%), CD34 (94.1%), HLA-DR (98.4%), cytoplasmic CD79a (76.1%), TdT (92.2%), and KORSA (65.1%) and weakly positive for myeloperoxidase (30.7%) (Figure 2). Chromosomal analysis of the bone marrow cells revealed 46, XY, t(9;22)(q34;q11.2) in 17 out of a total of 20 cells in metaphase. The minor *BCR-ABL1* mRNA level in the bone marrow was 460 000 copies/ $\mu\text{g}$  RNA. Additional examination did not reveal splenomegaly, history of CML, or increases in peripheral white blood cell or absolute basophil count. Based on these results, the patient was diagnosed with Ph+MPAL according to the 2016 WHO classification.

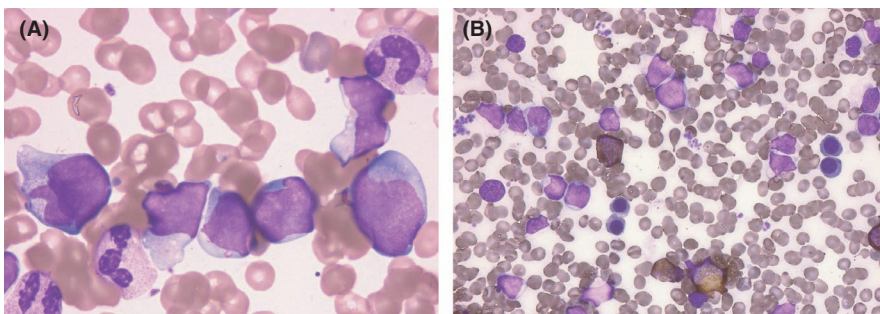
He was started on 60 mg ( $40 \text{ mg/m}^2$ ) prednisolone as pretherapy from January 2018. Based on the medical history including type 2 DM and cardiovascular comorbidity, he was initiated on 50mg/day dasatinib one week after the initiation of prednisolone. However, dasatinib was discontinued after the patient exhibited grade 2 QT prolongation and interstitial pneumonitis ten days after the initiation of dasatinib (Figure 3). After the improvement of his respiratory

status, dasatinib was replaced with imatinib (300 mg/day) in February 2018. Due to grade 2 acute renal failure and QT prolongation, imatinib was discontinued and tapered. After those adverse events improved, he restarted imatinib at dose of 50 mg daily and the dose was gradually increased. Although temporary interruption was necessary to address renal failure and infectious pneumonia, the patient could receive imatinib up to 200 mg/day. Hematological complete remission (CR) was achieved 40 days after the imatinib initiation. Six months after imatinib starting, the blood concentration of imatinib was 1308 ng/mL ( $>1000 \text{ ng/mL}$ ), and hematological CR was maintained. Drug concentration monitoring of imatinib was continued for one year (Figure 4), and the minor *BCR-ABL1* mRNA level in bone marrow declined from 460 000 to 58 copies/ $\mu\text{g}$  RNA in January 2019. Hematological CR was maintained for over a year without the interruption of imatinib by monitoring of blood imatinib concentrations (Figure 5).

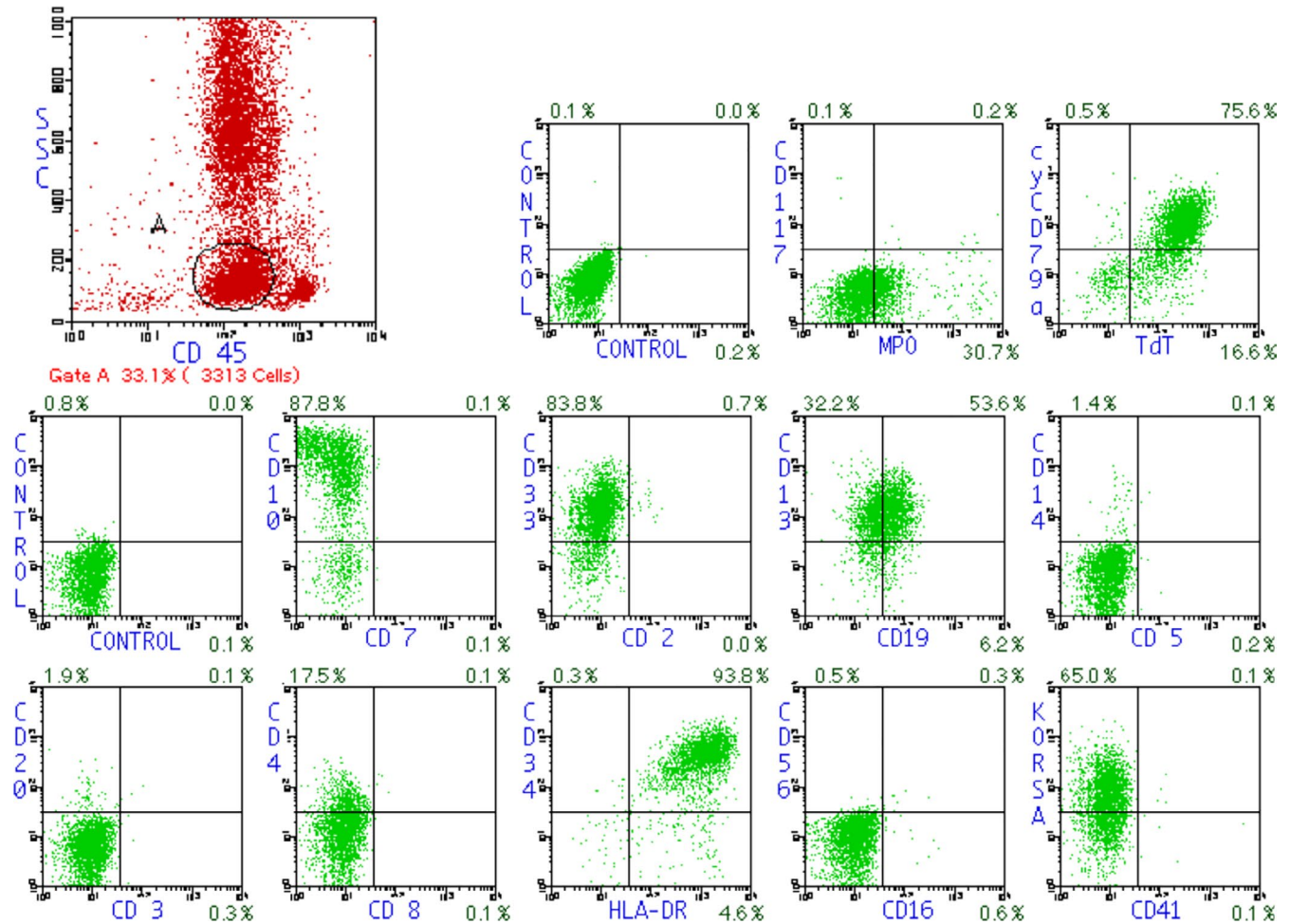
## 3 | DISCUSSION

Although there is no consensus on optimal treatment approaches for Ph+MPAL, TKIs are often used based on their efficacy in CML. In CML, decision-making related to specific TKIs to be used and their doses relies on patient age and comorbidities. Low-dose imatinib may control Ph+MPAL in cases where second-generation TKIs cannot be used due to complications and comorbidities in elderly patients and can be considered as a safe alternative therapy.

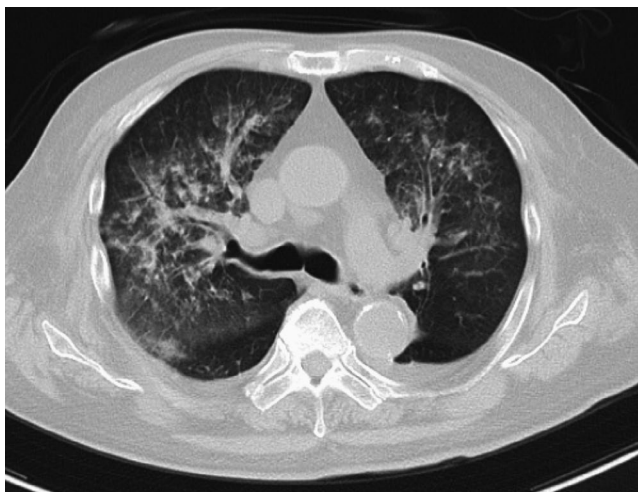
Our review of the literature of relevant cases identified only four reports of elderly patients diagnosed with Ph+MPAL, according to the 2016 WHO classification (Table 1).<sup>7-9</sup> These cases were treated with second-generation TKIs; however, none of the studies involved patients treated with only imatinib. The first of the reported four cases was a 71-year-old woman with hypertension who was initially treated with imatinib (400 mg/day) and later developed edema and fatigue; therefore, the imatinib dose was reduced to 300 mg/day. She maintained cytogenetic CR without serious complications for approximately 20 months; however, reverse transcription-polymerase chain reaction



**FIGURE 1** Blast cells in bone marrow. (A) Bone marrow examination showed hypocellularity with 41.4% medium- or large-sized blasts (May-Giemsa stain,  $\times 1000$  magnification). (B) Blast cells were negative for myeloperoxidase according to histochemical analysis (Myeloperoxidase stain,  $\times 400$  magnification)

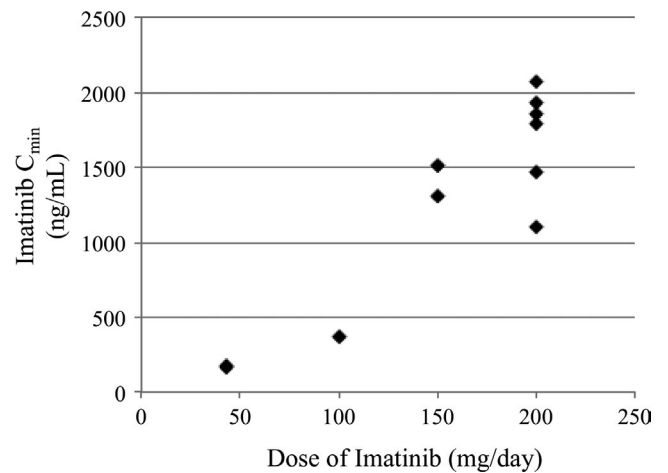


**FIGURE 2** Flow cytometric analysis of bone marrow cells. Blast cells were strongly positive for CD10, CD19, CD33, CD34, HLA-DR, cytoplasmic CD79a, TdT, and KORSA, and weakly positive for MPO



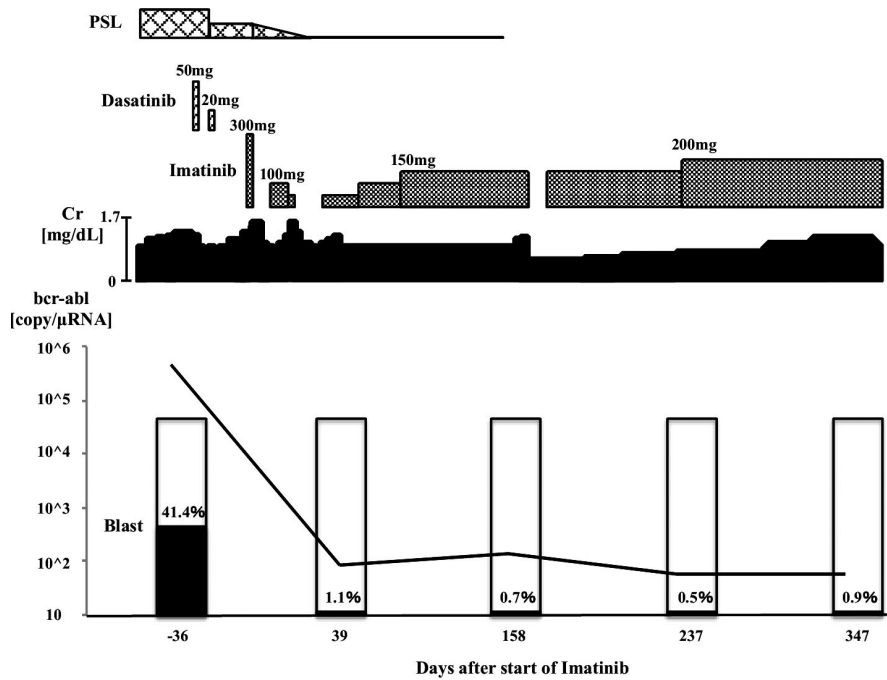
**FIGURE 3** A computed tomography (CT) scan ten days after the initiation of dasatinib. The CT scan showed interstitial pneumonitis

detected the presence of *BCR-ABL1* fusion gene. Her treatment was replaced with nilotinib after the first hematological relapse, and she achieved second cytogenetic CR for seven months. After the second hematological relapse, she



**FIGURE 4** Drug concentration monitoring of imatinib. It showed the distribution of imatinib blood concentration (Imatinib  $C_{min}$ ) and imatinib dose for one year. Imatinib at 150-200 mg/day could maintain Imatinib  $C_{min}$  > 1000 ng/mL

was treated with dasatinib and achieved cytogenetic CR for approximately 2 years.<sup>7</sup> The second case was an 85-year-old man with prostate cancer who was treated with radiation



**FIGURE 5** Clinical course. PSL prednisolone, Cr creatinine

**TABLE 1** Reported Case of Philadelphia Chromosome Positive Mixed Phenotype Acute Leukemia

Case	Age	M/F	Disease(lineage)	Treatment	Efficacy	Reference
1	71	F	Ph+MPAL(Myeloid/B)	IDA+AraC+IM, HDMTX+AraC+IM, VP+IM(1st relapse) →Dasa+DEXA(Skin rash)→Nilo+VP(2nd relapse) →Dasa+VP(CR)	cytogenetic CR	[7]
2	85	M	Ph+MPAL(Myeloid/B)	Decitabine+Dasa+R-mini-HyperCVAD	morphogenic CR	[8]
3	69	F	Ph+MPAL(Myeloid/B)	Dasa+PSL, Dasa only	molecular CR	[9]
4	69	F	Ph+MPAL(Myeloid/B)	Dasa+PSL, Dasa+low dose PSL	molecular CR	
5	87	M	Ph+MPAL(Myeloid/B)	Dasa+PSL(ILD) →IM	cytogenetic CR	Our case

*Note:* Abbreviations: AraC, Cytarabine; CR, Complete remission; CVAD, Cyclophosphamide+Vincristine+Adriamycin+DEXA; Dasa, Dasatinib; DEXA, Dexamethasone; HDMTX, High-dose methotrexate; IDA, Idarubicin; ILD, Interstitial lung disease; IM, Imatinib; Nilo, Nilotinib; Ph+MPAL, Philadelphia chromosome-positive mixed phenotype acute leukemia; PSL, Prednisolone; R, Rituximab; VP, Vincristine+Prednisolone.

and combination chemotherapy with dasatinib. He was successfully treated with dasatinib which controlled the disease without fatal complications.<sup>8</sup> The third case was a 69-year-old woman with a 15-year history of type 2 DM, whereas the fourth case was a 69-year-old woman who was diagnosed with breast cancer 17 years earlier and was treated with surgery, systemic chemotherapy, and hormonal therapy. The last two patients were treated with dasatinib (140 mg/day) and prednisolone and maintained molecular CR for 16 and 7 months, respectively.<sup>9</sup>

The present case (case 5) highlights two important clinical implications. First, low-dose imatinib might provide safe disease control in elderly patients with Ph+MPAL. Second, imatinib can be safely continued without fatal complications by monitoring drug concentrations in blood.

Patients with Ph+MPAL have recently been treated with 600 mg/day imatinib, similar to that used in patients with Ph+B-cell precursor acute lymphoblastic leukemia, which has led to improved 5-year OS and disease-free survival rates that are comparable with those of Ph+B-cell precursor acute lymphoblastic leukemia.<sup>5</sup> However, we should consider the risk of adverse events that can arise in elderly patients with Ph+MPAL who might develop complications such as that occurred in the present case. Therefore, in the present case we monitored the blood concentrations of imatinib, which allowed the delivery of optimal doses without adverse events. Blood imatinib concentrations above 1000 ng/mL are considered effective in CML<sup>10-12</sup>; therefore, we targeted the same cutoff value for controlling the imatinib dose with drug concentration monitoring. As a result, Ph+MPAL could be

controlled with imatinib at a low-dose ranging from 150 to 200 mg/day, indicating that low-dose imatinib could control Ph+MPAL if effective blood concentration is maintained.

The initial treatment with dasatinib had to be discontinued due to interstitial pneumonitis in the present patient, who could safely continue treatment after switching to imatinib. Interstitial pneumonitis, which can develop in 2.9% of patients treated with dasatinib, is grade 3 or higher in half of the affected cases. Conversely, interstitial pneumonitis reportedly occurs in only 1.3% of patients under treatment with imatinib and the symptoms are expected to improve by steroids and other treatments.<sup>13</sup> In contrast, 1.4% of patients treated with nilotinib develop interstitial pneumonitis, which has a mortality rate of 22.2% in these patients.<sup>14</sup> Therefore, switching to imatinib might be considered as an option in patients who develop interstitial pneumonitis during treatment with second-generation TKIs.

Patients treated with TKIs rarely experience cardiac complications, including congestive heart failure (1.7%) and QT prolongation (QT interval >480 ms, 0.7%; QT interval >500 ms, 0.4%), due to imatinib.<sup>15,16</sup> Therefore, imatinib was considered in the present patient with QT prolongation. Conversely, the reported rates of QT prolongation are 10.2%, 1.1%, and 0.5% in nilotinib-treated patients with QT intervals of >450, >480, and >500 ms, respectively, whereas the reported rate of QT interval above 500 ms is 1% in dasatinib-treated patients, which is higher than that reported in nilotinib-treated patients.

The present patient was initially treated with dasatinib instead of nilotinib due to the cardiovascular complications and the preexisting history of DM. However, he was switched to imatinib because of interstitial pneumonitis and QT prolongation. There were no major complications after the switch, and the patient could continue treatment in agreement with previous reports. Therefore, imatinib should be considered as a good option for continued treatment in elderly patients with Ph+MPAL and cardiovascular complications.

Low-dose imatinib was safe and could control disease in an elderly patient with Ph+MPAL. Reports of elderly patients with Ph+MPAL are limited, and accumulation of clinical cases is necessary to elucidate appropriate treatment approaches for elderly individuals with Ph+MPAL.

## ACKNOWLEDGMENTS

Published with written consent of the patient.

## CONFLICT OF INTEREST

None declared.

## AUTHOR CONTRIBUTIONS

Yusuke Okayama wrote the manuscript with support from Teruhito Takakuwa. All authors discussed the case and contributed to the final manuscript.

## ETHICAL STATEMENT

Informed consent was obtained from the patient for publication.

## DATA AVAILABILITY STATEMENT

The data of this case is available from the corresponding author, TT, upon reasonable request.

## ORCID

Teruhito Takakuwa  <https://orcid.org/0000-0001-5259-0450>

## REFERENCES

- Charles NJ, Boyer DF. Mixed-phenotype acute leukemia: diagnostic criteria and pitfalls. *Arch Pathol Lab Med.* 2017;141:1462-1468.
- Yan L, Ping N, Zhu M, et al. Clinical, immunophenotypic, cytogenetic, and molecular genetic features in 117 adult patients with mixed-phenotype acute leukemia defined by who-2008 classification. *Haematologica.* 2012;97:1708-1712.
- Arber DA, Orazi A, Hasserjian R, et al. The 2016 revision to the world health organization classification of myeloid neoplasms and acute leukemia. *Blood.* 2016;127:2391-2405.
- Killick S, Matutes E, Powles RL, et al. Outcome of biphenotypic acute leukemia. *Haematologica.* 1999;84:699-706.
- Shimizu H, Yokohama A, Hatsumi N, et al. Philadelphia chromosome-positive mixed phenotype acute leukemia in the imatinib era. *Eur J Haematol.* 2014;93:297-301.
- Lai B, Mu Q, Zhu H, et al. Durable remission in a patient of mixed phenotype acute leukemia with philadelphia chromosome-positive treated with nilotinib and lenalidomide: a case report. *Medicine (Baltimore).* 2018;97:e0294.
- Kawajiri C, Tanaka H, Hashimoto S, et al. Successful treatment of philadelphia chromosome-positive mixed phenotype acute leukemia by appropriate alternation of second-generation tyrosine kinase inhibitors according to BCR-ABL1 mutation status. *Int J Hematol.* 2014;99:513-518.
- Jain P, Tang G, Huh YO, et al. Philadelphia-positive dimorphic blasts in mixed-phenotype acute leukemia with TET2 mutation. *Am J Hematol.* 2016;91:647-648.
- Takata H, Ikebe T, Sasaki H, et al. Two elderly patients with philadelphia chromosome positive mixed phenotype acute leukemia who were successfully treated with dasatinib and prednisolone. *Intern Med.* 2016;55:1177-1181.
- Takahashi N, Wakita H, Miura M, et al. Correlation between imatinib pharmacokinetics and clinical response in Japanese patients with chronic-phase chronic myeloid leukemia. *Clin Pharmacol Ther.* 2010;88:809-813.
- Blasdel C, Egorin MJ, Lagattuta TF, Druker BJ, Deininger MW. Therapeutic drug monitoring in CML patients on imatinib. *Blood.* 2007;110:1699-1701.
- Bouchet S, Titier K, Moore N, et al. Therapeutic drug monitoring of imatinib in chronic myeloid leukemia: experience from 1216 patients at a centralized laboratory. *Fundam Clin Pharmacol.* 2013;27:690-697.
- Ohnishi K, Sakai F, Ohno R. Twenty-seven cases of drug-induced interstitial lung disease associated with imatinib mesylate. *Leukemia.* 2006;20:1162-1164.

14. Saito Y, Gemma A. Current status of DILD in molecular targeted therapies. *Int J Clin Oncol*. 2012;17:534-541.
15. Atallah E, Durand JB, Kantarjian H, Cortes J. Congestive heart failure is a rare event in patients receiving imatinib therapy. *Blood*. 2007;110:1233-1237.
16. Steegmann JL, Baccarani M, Breccia M, et al. European leukemia net recommendations for the management and avoidance of adverse events of treatment in chronic myeloid leukemia. *Leukemia*. 2016;30:1648-1671.

**How to cite this article:** Okayama Y, Takakuwa T, Otomaru I, et al. Efficacy and safety of low-dose imatinib in an elderly patient with mixed phenotype acute leukemia with t(9;22)(q34;q11.2);BCR-ABL1. *Clin Case Rep*. 2021;9:e04126. <https://doi.org/10.1002/ccr3.4126>