



Case Report

Occipitocervical fixation using Ransford loop for neglected posttraumatic odontoid fracture with atlantoaxial dislocation: A technical note

Robert Sinurat

Department of Surgery, Faculty of Medical, Universitas Kristen Indonesia, Jakarta, Indonesia.

E-mail: *Robert Sinurat - robertsinurat@yahoo.com



***Corresponding author:**

Robert Sinurat,
Jl. Mayjen Sutoyo No. 2,
Kramatjati, Jakarta 13630,
Indonesia.

robertsinurat@yahoo.com

Received : 19 October 19

Accepted : 23 October 19

Published : 15 November 19

DOI

10.25259/SNI_523_2019

Quick Response Code:



ABSTRACT

Background: To relieve the onset of new clinical symptoms, it is important to recognize and treat previously neglected odontoid fractures. However, many hospitals in developing countries do not have the equipment or surgical expertise to adequately manage these lesions.

Case Description: A 31-year-old male presented with paresthesias/quadriparesis attributed to an accident sustained 6 months earlier. The cervical magnetic resonance image revealed atlantoaxial subluxation type 2. Following a laminectomy and occipitocervical fusion with a Ransford loop, the patient's symptoms significantly improved.

Conclusion: Straight forward laminectomy and occipitocervical fusion with a Ransford loop may adequately treat selected cases of neglected atlantoaxial subluxation in a developing country.

Keywords: Atlantoaxial subluxation, Equipment, Stabilization

INTRODUCTION

About 10–20% of cervical fractures involve the odontoid. Type 2 odontoid fractures typically do not heal well without surgery.^[4,2,6] Here, the author presented a 31-year-old male patient with a neglected odontoid fracture accompanied by atlantoaxial dislocation (AAD) successfully treated with delayed decompression and fusion.

CASE REPORT

Six-month duration following a motorbike accident, a 31-year-old male presented with neck pain, paresthesias, quadriparesis, and bilateral ankle clonus. Upper extremity (3/5) and lower extremity strength (4/5) were compromised. The cervical magnetic resonance image showed atlantoaxial subluxation type 2^o, with an increased atlantodens interval (ADI), a decreased posterior ADI, and an increased interspinous distance.^[5] The spinal cord was compressed by the ring of C1 and the upper part of C2 [Figures 1 and 2].

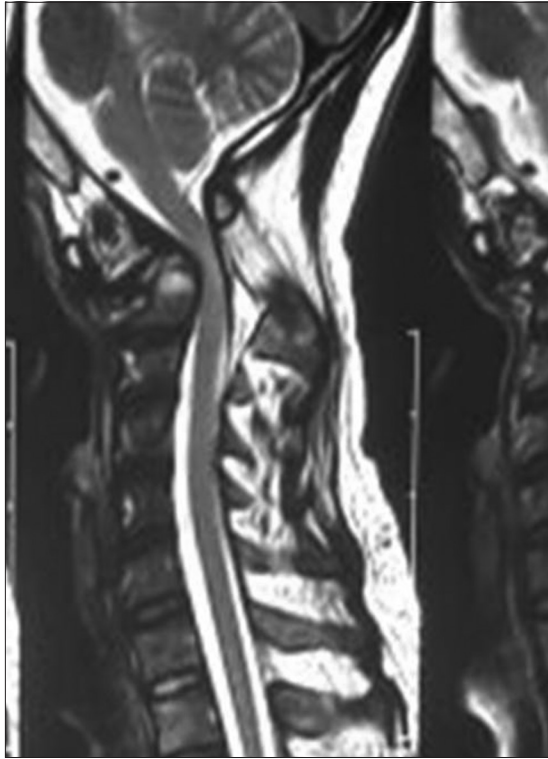


Figure 1: Cervical magnetic resonance imaging (sagittal view).

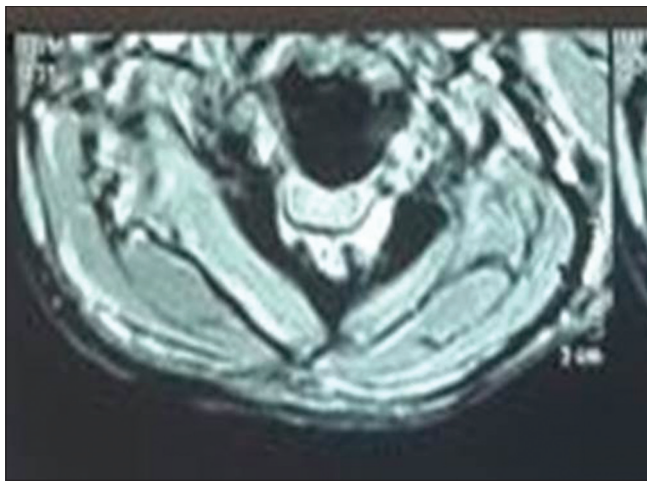


Figure 2: Cervical magnetic resonance imaging (axial view).

Operative procedures

An incision was started from the occiput to C7. The posterior ring of C1 was drilled 1 cm lateral to the midline on both sides; additionally, a laminectomy was performed involving the upper part of the lamina of C2 bilaterally. Two small burr holes were placed in the occipital region; a Ransford loop affixed to the occipital bone using 1.5 mm wires. Similarly, the lamina of C2-C4 was fixed using 1.5 mm sublaminar wires. The patient was discharged on postoperative day 7 without

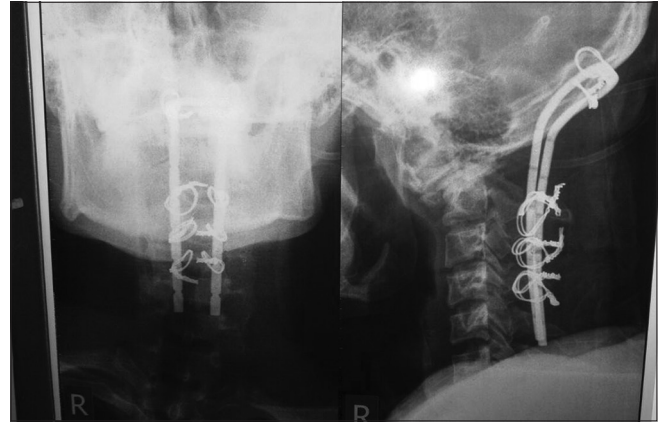


Figure 3: Postoperative cervical X-ray, anteroposterior view (left), and lateral view (right).

any changes in his neurological status. The postoperative X-ray showed that the Ransford loop had remained in good position [Figure 3]. One month later, the strength of his upper extremities improved significantly, and his clonus resolved. Three months postoperatively, he regained full motor function in all four extremities.

DISCUSSION

Poorly managed odontoid fractures are a common problem in underdeveloped countries due to many factors, for example, socioeconomic problems, overlooked diagnoses, and poor access to health care.^[3,1] Specifically, some hospitals do not have a C-arm, an operating table with a headrest, expensive screws, and the surgeon with sufficient skill and experience. Here, we have presented a previously neglected type 2 odontoid fracture with AAD type C managed using an operating table without a headrest, cheap Ransford loop, and wire. The procedure was simple but proved effective for this patient.

CONCLUSION

Selected patients with neglected odontoid type 2 fractures with atlantoaxial dislocation type C can be managed utilizing a simple laminectomy decompression and occipitocervical stabilization using Ransford loops and wire.

Declaration of patient consent

The authors certify that they have obtained all appropriate patient consent forms.

Financial support and sponsorship

Nil.

Conflicts of interest

There are no conflicts of interest.

REFERENCES

1. Aggarwal RA, Rathod AK, Chaudhary KS. Irreducible atlantoaxial dislocation in neglected odontoid fracture treated with single stage anterior release and posterior instrumented fusion. *Asian Spine J* 2016;10:349-54.
2. Evaniew N, Yarascavitch B, Madden K, Ghert M, Drew B, Bhandari M, *et al.* Atlantoaxial instability in acute odontoid fractures is associated with nonunion and mortality. *Spine J* 2015;15:910-7.
3. Sengupta DK. Neglected spinal injuries. *Clin Orthop Relat Res* 2005;431:93-103.
4. Shetty A, Kini AR, Prabhu J. Odontoid fractures: A retrospective analysis of 53 cases. *Indian J Orthop* 2009;43:352-60.
5. Shetty A, Kumar A, Chacko A, Guthe S, Kini AR. Reduction techniques in the management of atlantoaxial subluxation. *Indian J Orthop* 2013;47:333-9.
6. Yang SY, Boniello AJ, Poorman CE, Chang AL, Wang S, Passias PG, *et al.* A review of the diagnosis and treatment of atlantoaxial dislocations. *Global Spine J* 2014;4:197-210.

How to cite this article: Sinurat R. Occipitocervical fixation using Ransford loop for neglected posttraumatic odontoid fracture with atlantoaxial dislocation: A technical note. *Surg Neurol Int* 2019;10:218.