



Presumed immune-mediated haemolytic anaemia associated with pregnancy in a cat

Matthew A Kopke , Sarah Pemberton and Craig G Ruax

Journal of Feline Medicine and Surgery Open Reports
1–5

© The Author(s) 2019

Article reuse guidelines:

sagepub.com/journals-permissions

DOI: 10.1177/2055116919841689

journals.sagepub.com/home/jfmsopenreports

This paper was handled and processed by the European Editorial Office (ISFM) for publication in *JFMS Open Reports*



Abstract

Case summary A 7-year-old female entire Birman presented with acute-onset haemorrhagic vulvar discharge. Moderate, normocytic, normochromic, non-/pre-regenerative anaemia, along with a moderate mature neutrophilia, were seen on haematology. Saline test for agglutination was positive. No haemotropic mycoplasmas were identified. Serum biochemistry revealed severe hyperbilirubinaemia. Retroviral testing was negative. Serology for toxoplasmosis revealed a titre of 1:512. Abdominal ultrasound identified a large uterus, containing at least three advanced-stage fetuses, two of which failed to exhibit independent motion or cardiac activity. Ovariohysterectomy was performed. Histology demonstrated mild, multifocal suppurative placentitis, with Gram staining revealing no evidence of bacteria. Complete resolution of the anaemia was seen within 1.5 months of ovariohysterectomy.

Relevance and novel information Immune-mediated haemolytic anaemia (IMHA) in association with pregnancy has not been previously reported in cats. This case represents a potential novel cause for IMHA in cats, which resolved following ovariohysterectomy.

Keywords: Autoimmune; haemolysis; IMHA; placentitis; pregnancy

Accepted: 11 March 2019

Introduction

Immune-mediated haemolytic anaemia (IMHA) has generally been considered an uncommon to rare cause of anaemia in cats.¹ In a retrospective study of 180 anaemic cats, Korman et al identified immune-mediated haemolysis as an underlying cause in only 6.1% of cases.¹ IMHA secondary to an underlying disease, most often with an infectious cause, is considered more common than primary/idiopathic IMHA in cats.^{1–5}

Infectious causes that have been identified include haemotropic mycoplasma infections (particularly *Mycoplasma haemofelis*), feline leukaemia virus (FeLV), feline infectious peritonitis and *Babesia felis*.^{4,6} Other potential secondary causes, such as hereditary diseases (eg, pyruvate kinase deficiency), drugs (eg, acetaminophen, propylthiouracil, methimazole, famotidine), toxins (eg, onions), severe hypophosphataemia, pancreatitis and neoplasia (eg, lymphoma), have also been described.^{4,6–9} As far as we are aware, IMHA in association with pregnancy has not been reported in cats.

IMHA, or autoimmune haemolytic anaemia, as it is more commonly referred to in humans, has been well documented in pregnant women, with an estimated prevalence of one in 50,000 pregnancies.¹⁰ Clinical presentation can range from gradual, compensated disease to rapid-onset, life-threatening anaemia.¹¹ We describe herein a case of IMHA in association with pregnancy in a cat that presented with the primary complaint of haemorrhagic vulvar discharge, and subsequently went on to show complete resolution of the anaemia within the 1.5 months following ovariohysterectomy (OVH).

School of Veterinary Science, Massey University, Palmerston North, New Zealand

Corresponding author:

Matthew A Kopke BSc, BVSc (Hons), Massey University, Palmerston North, Private Bag 11-222, Palmerston North 4410, New Zealand
Email: m.kopke@massey.ac.nz



Creative Commons Non Commercial CC BY-NC: This article is distributed under the terms of the Creative Commons

Attribution-NonCommercial 4.0 License (<http://www.creativecommons.org/licenses/by-nc/4.0/>) which permits non-commercial use, reproduction and distribution of the work without further permission provided the original work is attributed as specified on the SAGE and Open Access pages (<https://us.sagepub.com/en-us/nam/open-access-at-sage>).

Case description

A 7-year-old female entire Birman was referred for further investigation of acute-onset haemorrhagic vulvar discharge. A survey lateral abdominal radiograph was performed at the referring veterinary clinic, and a markedly enlarged uterus was noted. cursory abdominal ultrasound identified at least three fetuses, with heart rates for each estimated to be in the region of 240 beats per min (bpm). The queen had a history of two prior litters, with no associated complications.

On initial presentation at our veterinary teaching hospital, the cat was bright and alert, with subjectively pale mucous membranes. Apart from the vulvar discharge described above, with associated matting of the coat over the perineum, no further significant findings were appreciated on the rest of the physical examination. Vital parameters were within normal limits. Abdominal palpation revealed at least two palpable fetuses. The body condition score was 3/9. No known toxin exposure (acetaminophen, onions) was reported.

Haematology revealed a moderate, normocytic, normochromic, non-/pre-regenerative anaemia, along with a moderate mature neutrophilia (Table 1; day 1). Saline test for agglutination was positive. No haemotropic mycoplasmas were identified. Serum biochemistry demonstrated severe hyperbilirubinaemia (26 µmol/l;

reference interval [RI] 0–5 µmol/l), moderately increased aspartate aminotransferase (334 IU/l; RI 0–66 IU/l), moderately increased alanine aminotransferase (311 IU/l; RI 0–100 IU/l), mild azotaemia (blood urea nitrogen 16.0 mmol/l; RI 5.7–12.9 mmol/l), mildly increased symmetric dimethylarginine (16 µg/dl; RI 0–14 µg/dl), mild hypokalaemia (3.2 mmol/l; RI 3.5–5.0 mmol/l) and moderate hypoproteinaemia (55 g/l; RI 63–83 g/l), composed of a moderate hypoalbuminaemia (19 g/l; RI 26–40 g/l) and normal globulin concentration (36 g/l; RI 27–49 g/l). The cat was negative on testing for both FeLV and feline immunodeficiency virus. Serology for toxoplasmosis revealed a titre of 1:512, and the cat was feline blood group B.

Focal reproductive tract ultrasonography was performed to assess fetal viability, and better estimate stage of gestation, should any further intervention be required. A large uterus, containing at least three subjectively well-developed fetuses was identified. Two of the fetuses failed to exhibit independent motion or cardiac activity, and the third had a heart rate of 218 bpm, indicating fetal stress.¹² Fetal development was advanced, with visibility of the cerebral choroid plexi, and individual heart chambers consistent with at least 50 days' gestation (Figure 1). Morphology of fetal organs was well defined and similar in all fetuses, indicating that the demise of two fetuses had

Table 1 Serial monitoring of haematological parameters in a cat with immune-mediated haemolytic anaemia associated with pregnancy

	Day 1	Day 4	Day 11	Day 44	RI
RBC ($\times 10^{12}/l$)	2.9	3.2	4.7	7.7	5.0–10.0
Haemoglobin (g/l)	46	51	72	116	80–150
HCT (l/l)	0.15	0.17	0.26	0.37	0.24–0.45
MCV (fl)	50	53	55	49	39–55
MCHC (g/l)	315	297	277	310	290–360
Platelets ($\times 10^9/l$)	Adequate number (estimate)	Adequate number (estimate)	Adequate number (estimate)	Adequate number (estimate)	
Absolute reticulocyte count ($\times 10^9/l$)	95	202	194	72	19–107
Nucleated red blood cell count		2	3		0.0–0.0
WBC ($\times 10^9/l$)	25.7	16.6	16.4	19.8	5.5–19.5
Band (immature) neutrophils ($\times 10^9/l$)		0.3 (2%)			0.0–0.3
Segmented (mature) neutrophils ($\times 10^9/l$)	17.7 (69%)	12.1 (73%)	10.2 (62%)	16.2 (82%)	2.4–12.5
Lymphocytes ($\times 10^9/l$)	6.2 (24%)	3.5 (21%)	5.1 (31%)	2.8 (14%)	1.5–7.0
Monocytes ($\times 10^9/l$)	1.5 (6%)	0.3 (2%)	0.7 (4%)	0.2 (1%)	0.0–0.9
Eosinophils ($\times 10^9/l$)	0.3 (1%)	0.3 (2%)	0.5 (3%)	0.6 (3%)	0.0–1.5
Agglutination	Positive at 1:64 dilution*	Positive	Weak positive	Negative	

*Serial dilutions performed with saline test for agglutination, 1:64 dilution denotes the highest dilution at which agglutination was still seen when evaluated microscopically

RI = reference interval; RBC = red blood cell count; HCT = haematocrit; MCV = mean cell volume; MCHC = mean cell haemoglobin concentration; WBC = white blood cell count

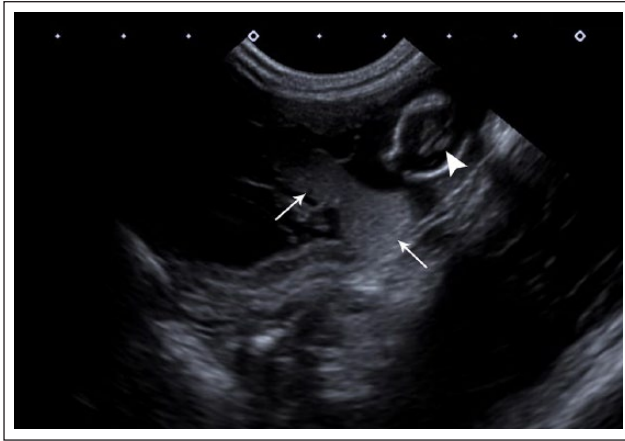

Figure 1 Ultrasonographic image of the gravid uterus including one fetal head. The choroid plexi are visible as two small symmetric hyperechoic structures (arrowhead) within the fetal brain. The falx cerebri is visible as the straight echoic line between these structures. A moderate amount of markedly echogenic intrauterine fluid is present (thin arrows)

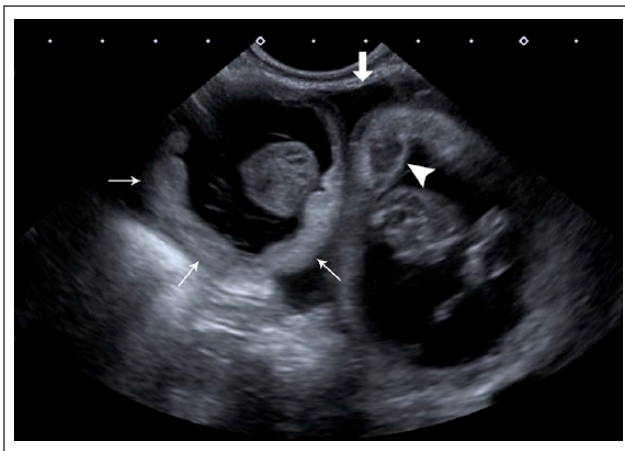


Figure 2 Ultrasonographic image of the uterus, containing two fetuses and zony placenta. One zony placenta is diffusely hyperechoic (thin arrows), and the other is heterogeneously hyperechoic (arrowhead). Anechoic free peritoneal fluid surrounds the uterine horn in this view (thick arrow)

occurred within the preceding 12 h.¹² The zony placenta were varied in appearance, and at least one was subjectively thickened, with an irregular inner margin. This zony placenta had several small areas of heterogeneously increased echogenicity, where the normal hyperechoic inner, hypoechoic middle and hyperechoic outer layers were not visible. Another region of zony placenta was diffusely hyperechoic (Figure 2). In addition, the uterus contained a moderate amount of strongly echogenic fluid contained in multiple pockets. A moderate amount of anechoic free peritoneal fluid was also present, along with subtly hyperechoic fat adjacent to the uterus.

The owner expressed no desire to continue breeding with the queen in the future, and with at least two of the fetuses no longer viable, and the third deemed unlikely to survive to term and/or delivery, OVH was advised. Exploratory laparotomy revealed a moderate amount of straw-coloured fluid in the caudal abdomen. Fluid analysis revealed mild increases in protein (31 g/l; RI 0–28 g/l) and nucleated cell count (2.6×10^9 /l; RI 0– 1.5×10^9 /l), with the latter composed of a small number of reactive mesothelial cells and occasional non-degenerate neutrophils and red blood cells. The gravid uterus appeared grossly congested and contained four fetuses. Recovery from anaesthesia was uneventful, and the cat was maintained on buprenorphine (0.025 mg/kg SC q8–12h) for pain management.

Repeat haematology 3 days later revealed mild improvement in the degree of anaemia, along with evidence of regeneration (Table 1; day 4). The mature neutrophilia had since resolved; however, the cat was still positive on saline test for agglutination (Table 1; day 4). With gradual improvement in terms of both the degree of anaemia and regenerative response following surgery, no further treatment, more specifically immunosuppressive therapy, was instituted and the cat was discharged. Histology later revealed mild, multifocal suppurative placentitis, with Gram staining failing to demonstrate evidence of bacteria within the inflamed areas of placenta. Unfortunately, routine bacterial culture could not be performed to definitively rule out underlying bacterial infection. The IMHA described was deemed most likely to be associated with pregnancy, as is well documented in people.

A revisit at the referring veterinary clinic 1 week later demonstrated further improvement, with a low normal haematocrit and moderate reticulocytosis; however, a weak positive was still noted on saline test for agglutination (Table 1; day 11). Further follow-up 1.5 months after OVH revealed complete resolution of the previously reported anaemia (Table 1; day 44). Repeat serology for toxoplasmosis revealed a titre of 1:1024.

Discussion

Anaemia during pregnancy is considered to be common in humans, with prevalence ranging from 5.4% to >80%, depending on geographical distribution.¹³ Furthermore, IMHA in humans occurs at least four times more frequently during pregnancy than in the non-pregnant population.¹³ Unfortunately, no such reports exist in the veterinary literature, let alone in cats specifically. That being said, manifestations of the disease can be variable, and this may explain why the disease process has not been previously identified in cats. Chaplin et al reported life-threatening anaemia in 40–50% of mothers, and stillbirths or severe post-partum haemolytic anaemia in 35–40% of their infants, yet several years later, Sokol et al

documented only mild clinical signs in 20 patients, with none of these women requiring active treatment.^{10,14} The latter, particularly if it were to occur in cats to a similar degree, would be missed in queens that do not routinely have haematology performed during pregnancy.

Human patients commonly present in the third trimester, and subsequently show improvement with delivery.¹⁵ Diagnosis requires documentation of haemolysis, with the most common features including spherocytosis, reticulocytosis, hyperbilirubinaemia and raised lactate dehydrogenase levels, followed by exclusion of other causes of haemolysis.¹⁵ In addition, pregnancy-associated IMHA in humans should be differentiated from IMHA associated with other lymphoproliferative or connective tissue diseases that simply recur during pregnancy.^{10,16} Following confirmation of the former, first-line therapy is typically corticosteroids.¹⁵ However, cases with only mild clinical signs have been shown to demonstrate improvement following delivery, in the absence of immunosuppressive agents, similar to what was seen in this case following OVH.¹⁰

Unfortunately, despite much investigation into pregnancy-associated IMHA in humans, and as is the case with multiple immune-mediated disorders, the exact mechanism is poorly understood. Feto-maternal microtransfusion, particularly fetal cells possessing paternal antigens, has been proposed as a mechanism but this is speculative.¹⁰ This does, however, seem plausible in this case had the fetuses been of either feline blood group A or AB. Given the known presence of naturally occurring anti-A alloantibodies in a type B queen, exposure to type A blood (fetus) would have led to significant haemolysis and haemagglutination.¹⁷

Toxoplasma gondii is considered a rare cause of abortion, stillbirth or neonatal death in cats.¹⁸ Cats often harbour *T gondii*, and are often asymptomatic.¹⁸ With immunosuppression or dysregulation, however, this may lead to acute systemic toxoplasmosis, through reactivation of latent tissue *T gondii* cysts.^{18–21} We suspect that the immune-mediated disorder in this cat led to reactivation and the subsequent two-fold rise in antibody titres. Although acute toxoplasmosis is typically associated with a four-fold increase in titres, reactivation may also have contributed to fetal death.²²

Limitations of our case included the lack of Coombs testing, lack of PCR for *M haemofelis* and lack of culture and sensitivity testing on both the uterus and fetuses. On the one hand, Coombs testing is more likely to be positive in anaemic cats with IMHA; however, it may also be positive with other forms of anaemia.²³ On the other hand, cases of Coombs-negative IMHA in pregnancy have been reported in humans, and thus failure to represent a positive response would not necessarily have ruled out the possibility of IMHA associated with pregnancy in this cat.¹⁵ In terms of PCR testing for organismal DNA, no

significant difference has been demonstrated between cats with anaemia and a control group of healthy cats, and thus this most likely would not have influenced case management, even if it was found to be present.²⁴

Conclusions

Pregnancy-associated IMHA, although not previously reported in cats, should be considered in a pregnant cat demonstrating signs consistent with haemolysis. This case represents a potential novel cause for IMHA in cats, which resolved following OVH. Further cases may be identified with routine haematology on pregnant queens, particularly in late gestation.

Acknowledgements We are grateful to Dr Malcolm W Jack for having performed the surgery, and Dr Susan P Piripi for performing the histology.

Conflict of interest The authors declared no potential conflicts of interest with respect to the research, authorship, and/or publication of this article.

Funding The authors received no financial support for the research, authorship, and/or publication of this article.

ORCID iD Matthew A Kopke  <https://orcid.org/0000-0002-1712-9615>

References

- 1 Korman RM, Hetzel N, Knowles TG, et al. **A retrospective study of 180 anaemic cats: features, aetiologies and survival data.** *J Feline Med Surg* 2013; 15: 81–90.
- 2 Werner LL and Gorman NT. **Immune-mediated disorders of cats.** *Vet Clin North Am Small Anim Pract* 1984; 14: 1039–1064.
- 3 Swann JW, Szladovits B and Glanemann B. **Demographic characteristics, survival and prognostic factors for mortality in cats with primary immune-mediated hemolytic anemia.** *J Vet Intern Med* 2016; 30: 147–156.
- 4 Paes G, Paepe D, Veldeman J, et al. **Immune-mediated hemolytic anemia (IMHA) in cats – part 1: a review.** *Vlaams Diergeneesk Tijdschr* 2010; 79: 415–423.
- 5 McCullough S. **Immune-mediated hemolytic anemia: understanding the nemesis.** *Vet Clin North Am Small Anim Pract* 2003; 33: 1295–1315.
- 6 Kohn B, Weingart C, Eckmann V, et al. **Primary immune-mediated hemolytic anemia in 19 cats: diagnosis, therapy, and outcome (1998–2004).** *J Vet Intern Med* 2006; 20: 159–166.
- 7 de Brito Galvao JF and Trepanier LA. **Risk of hemolytic anemia with intravenous administration of famotidine to hospitalized cats.** *J Vet Intern Med* 2008; 22: 325–329.
- 8 Peterson ME, Hurvitz AI, Leib MS, et al. **Propylthiouracil-associated hemolytic-anemia, thrombocytopenia, and antinuclear antibodies in cats with hyperthyroidism.** *J Am Vet Med Assoc* 1984; 184: 806–808.
- 9 Zoia A and Drigo M. **Association between pancreatitis and immune-mediated haemolytic anaemia in cats: a cross-sectional study.** *J Comp Pathol* 2017; 156: 384–388.

- 10 Sokol RJ, Hewitt S and Stamps BK. **Erythrocyte autoantibodies, autoimmune haemolysis and pregnancy.** *Vox Sang* 1982; 43: 169–176.
- 11 Piatek CI, El-Hemaidi I, Feinstein DI, et al. **Management of immune-mediated cytopenias in pregnancy.** *Autoimmun Rev* 2015; 14: 806–811.
- 12 Lopate C. **Gestational aging and determination of parturition date in the bitch and queen using ultrasonography and radiography.** *Vet Clin North Am Small Anim Pract* 2018; 48: 617–638.
- 13 Sun D, McLeod A, Gandhi S, et al. **Anemia in pregnancy: a pragmatic approach.** *Obstet Gynecol Surv* 2017; 72: 730–737.
- 14 Chaplin H, Cohen R, Bloomberg G, et al. **Pregnancy and idiopathic autoimmune haemolytic anaemia: a prospective study during 6 months gestation and 3 months postpartum.** *Br J Haematol* 1973; 24: 219–229.
- 15 Saha PK, Kaur J, Bagga R, et al. **A rare case of successfully treated coombs negative immune haemolytic anaemia in pregnancy.** *J Clin Diagn Res* 2017; 11: QD06–QD07.
- 16 Benraad CEM, Scheerder H and Overbeeke MAM. **Autoimmune haemolytic anaemia during pregnancy.** *Eur J Obstet Gynecol Reprod Biol* 1994; 55: 209–211.
- 17 Silvestre-Ferreira AC and Pastor J. **Feline neonatal isoerythrolysis and the importance of feline blood types.** *Vet Med Int* 2010; 2010. DOI: 10.4061/2010/753726.
- 18 Lamm CG and Njaa BL. **Clinical approach to abortion, stillbirth, and neonatal death in dogs and cats.** *Vet Clin North Am Small Anim Pract* 2012; 42: 501–513.
- 19 Lindsay SA, Barrs VR, Child G, et al. **Myelitis due to reactivated spinal toxoplasmosis in a cat.** *J Feline Med Surg* 2010; 12: 818–821.
- 20 Barrs VR, Martin P and Beatty JA. **Antemortem diagnosis and treatment of toxoplasmosis in two cats on cyclosporin therapy.** *Aust Vet J* 2006; 84: 30–35.
- 21 Davidson MG, Rottman JB, English RV, et al. **Feline immunodeficiency virus predisposes cats to acute generalized toxoplasmosis.** *Am J Pathol* 1993; 143: 1486–1497.
- 22 Dubey JP and Thulliez P. **Serologic diagnosis of toxoplasmosis in cats fed *Toxoplasma gondii* tissue cysts.** *J Am Vet Med Assoc* 1989; 194: 1297–1299.
- 23 Tasker S, Murray JK, Knowles TG, et al. **Coombs', haemoplasma and retrovirus testing in feline anaemia.** *J Small Anim Pract* 2010; 51: 192–199.
- 24 Ishak AM, Radecki S and Lappin MR. **Prevalence of *Mycoplasma haemofelis*, 'Candidatus Mycoplasma haemominutum', *Bartonella* species, *Ehrlichia* species, and *Anaplasma phagocytophilum* DNA in the blood of cats with anemia.** *J Feline Med Surg* 2007; 9: 1–7.