

# A new surgical technique “cervical internal os plasty” in cesarean delivery for placenta previa accreta

## A case–control study

Guiqiong Huang, MM, Xiaodong Wang, MD\*, Haiyan Yu, MD, Shu Zhou, MD

### Abstract

Placenta previa accreta is an obstetrical complication that severely affects the health of the fetus and the mother due to massive hemorrhage during pregnancy. This study reported a new suture technique called “cervical internal os plasty” to control obstetrical hemorrhage in cesarean delivery for patients with placenta previa accreta and retrospectively evaluated the safety and effectiveness of the new technique.

From January 2012 to May 2018, we collected 56 patients with this new suture technique, which repaired the damaged weak area with bleeding from the placental attachment site in the lower uterine segment, and restored the damaged anatomic internal os of the cervix. Meanwhile, we compared it with 60 cases with other conservative methods described by other obstetricians with the same qualifications. The perioperative outcomes (blood loss, blood transfusion, operative time, other applied medical technology, and so on) between the 2 groups were recorded in this report.

There were no significant differences between 2 groups among age, gravidity, parity, gestational age, and previous dilatation and curettage techniques ( $P > .05$ ). Of the patients with placenta previa accrete, 77.6% (90/116) had previous dilatation and curettage. The comparison between study group and control group on the rate of postpartum hemorrhage, blood transfusion, and mean operative time, average hospitalization days after cesarean delivery, expenses was not statistically significant ( $P > .05$ ). Compared with the control group, other applied supplementary techniques (including uterine tamponade, pelvic arterial embolization, or emergency hysterectomy) for the bleeding from the the placental attachment site is fewer significantly in the study group. No operative accident and hemorrhage-related complication occurred in the 2 groups.

Cervical internal os plasty is useful in patients with placenta previa accreta due to its simplicity, utility, and effectivity as well as its capacity for preserving fertility.

**Abbreviations:** DIC = disseminated intravascular coagulation, MRI = magnetic resonance imaging.

**Keywords:** caesarean delivery, cervical internal os plasty, conservative methods, obstetric hemorrhage, placenta previa accreta

## 1. Introduction

Placenta previa is one of the leading causes of severe postpartum hemorrhage. When coinciding with placenta accreta, it may be associated with life-threatening maternal hemorrhage after removal of the placenta due to its incomplete separation and massive bleeding from the placental attachment site.<sup>[1]</sup> Placenta accreta occurs when the chorionic villi invade the uterine

myometrium abnormally. It is divided into 3 grades based on histopathology: placenta accreta (where the chorionic villi are in contact with the myometrium), placenta increta (where the chorionic villi invade the myometrium), and placenta percreta (where the chorionic villi penetrate the uterine serosa).<sup>[2,3]</sup>

Currently, there is dramatic increase in the incidence of placenta previa and placenta increta (placenta previa increta) due to the increasing rate of cesarean delivery combined with increasing maternal age.<sup>[4]</sup> With the implementation of the 2-child policy in China, the phenomenon is especially apparent.

Acute torrential bleeding, massive blood transfusion, hysterectomy, and even the death of the woman can occur during cesarean delivery because of placenta previa increta. One of the major reasons is that the bleeding from the placental attachment site in the lower uterine segment is often vast and difficult to stop after removal of the placenta.<sup>[1]</sup> Current clinical hemostatic techniques include uterine tamponade,<sup>[5]</sup> superposition sutures,<sup>[6]</sup> hemostatic multiple square suturing,<sup>[7]</sup> and so on when the bleeding is not so severe. If necessary, obstetricians often attempt to employ B-Lynch sutures,<sup>[8]</sup> pelvic artery ligation,<sup>[9]</sup> or pelvic arterial embolization.<sup>[10]</sup> However, in practice, we have found that these conservative methods sometimes are incapable of stopping the bleeding from the placental attachment site. Moreover, the success of some surgical techniques, such as blood vessel ligation, has been associated with the experience and proficiency of the obstetricians, and in many

Editor: Danyle Wane.

The authors do not have any potential conflicts of interest to disclose.

Supplemental Digital Content is available for this article.

Department of Obstetric and Gynecologic, West China Second University Hospital, Sichuan University, Sichuan, China.

\* Correspondence: Xiaodong Wang, Department of Obstetrics and Gynecology, West China Second University Hospital, Sichuan University, 20 Renmin Road South, Chengdu, 610041, Sichuan, China (e-mail: wangxd\_scu@sina.com).

Copyright © 2019 the Author(s). Published by Wolters Kluwer Health, Inc. This is an open access article distributed under the terms of the Creative Commons Attribution-Non Commercial-No Derivatives License 4.0 (CCBY-NC-ND), where it is permissible to download and share the work provided it is properly cited. The work cannot be changed in any way or used commercially without permission from the journal.

Medicine (2019) 98:9(e14488)

Received: 19 August 2018 / Received in final form: 29 November 2018 /

Accepted: 18 January 2019

<http://dx.doi.org/10.1097/MD.0000000000014488>

hospitals, the conditions do not exist for performing perioperative temporary balloon occlusion of the internal iliac arteries<sup>[11]</sup> and uterine arterial embolization. If these procedures prove invalid, hysterectomy is performed to ensure maternal survival. Therefore, how to improve surgical skills and control bleeding in a timely and effectively manner before it is beyond control has great significance in the decreasing of complications related to massive bleeding. It is essential to have an easy, effective, economical, conservative method to control bleeding during cesarean delivery for placenta previa increta.

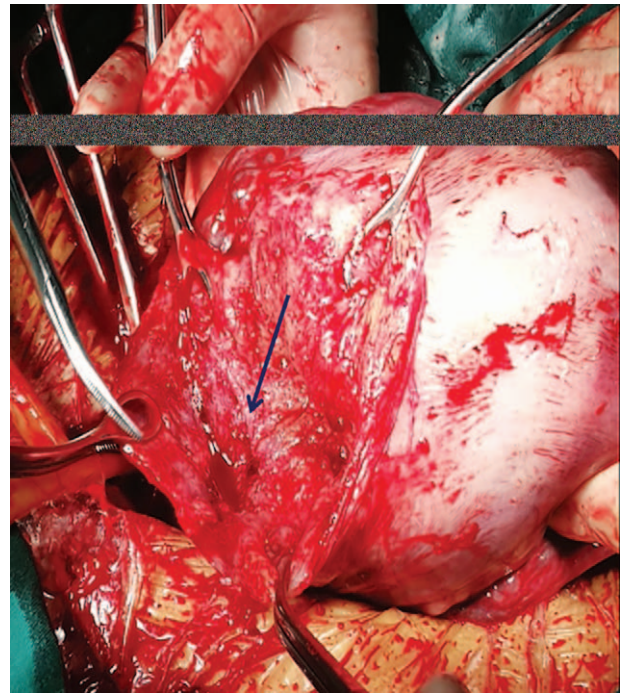
In this article, we report a new surgical hemostatic suture technique, cervical internal os plasty, mainly to treat hemorrhage from the placental attachment site in patients with placenta previa increta.

## 2. Methods

The study group included 56 women who underwent the new method “cervical internal os plasty” by the corresponding author, to stop bleeding from placenta previa increta, and the control group consisted of 60 women who underwent other hemostatic techniques by other obstetricians with the same qualification. All of the participants were diagnosed with placenta previa increta by ultrasound and/or magnetic resonance imaging (MRI) and desired to preserve their fertility. One hundred women received elective cesarean section and 16 received emergency cesarean section because of bleeding in our hospital. They were counseled properly before the operation and were given clear information about the diagnosis, the necessity of the operation, the risk of postpartum hemorrhage, and the methods that could be used to control this massive bleeding, including conservative methods and emergency hysterectomy. The informed consent was obtained from all of the women and the study was approved by the ethics committee of the hospital.

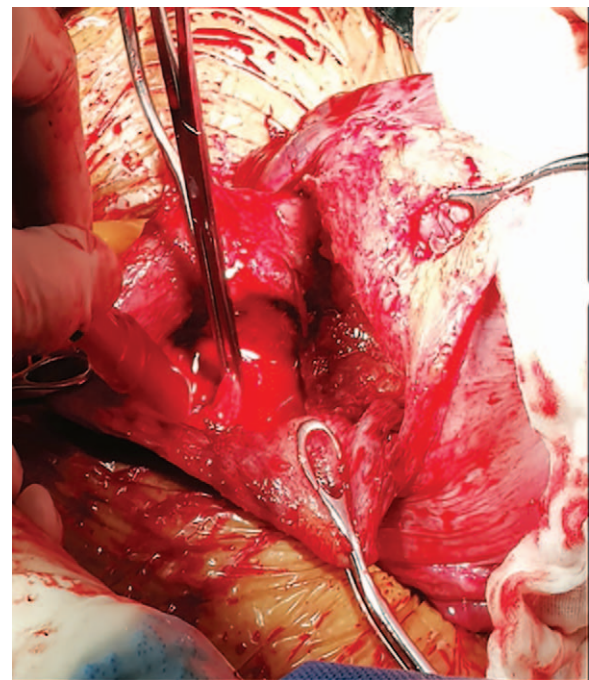
Cesarean section with a transverse incision of lower uterine segment was performed. The remaining portion of the placenta was removed manually after partial placental separation (focal placenta increta) in all cases. If the bleeding was mainly from placental bed of the lower uterine segment, the surgeon of the study group put his palm on the uterine serosa and his thumb into the uterine cavity in the lower uterine segment until it touched “the thin area” (lack of myometrium) (Fig. 1), and then performed the new method. “The thin area” is located between the ends of displaced longitudinal muscle fibers in the corpus and circular muscle fibers in the lower corpus and lower uterine segment, which are covered by the placenta previa increta. The surgical steps were as follows (video, <http://links.lww.com/MD/C853>): a Allis forceps was passed through the uterine incision and used to grasp circular muscle fibers in the lower corpus and lower uterine segment, pulling the tissue upwards the uterine cavity (Fig. 2). And the circular muscle fibers were then sutured to the ends of displaced longitudinal muscle fibers using absorbable sutures stitches (Fig. 3). The method aids to repair the damaged thin area in the lower uterine segment and to restore the anatomy of cervical anatomical internal os and finally to control bleeding from the very thin lower uterine segment seen in such cases. The surgeons of the control group carried out other conservative methods, including 8-finger-suture, B-lynch suture or uterine artery ligation, or together ( $\geq 2$  methods).

We retrospectively recorded the number of previous dilatation and curettage, operative time, perioperative bleeding, number of blood transfusions, other applied techniques (including uterine tamponade, pelvic arterial embolization, or emergency hysterectomy), duration of hospital stay after the operation, and expenses during and after the operation. Analysis of the data was performed with SPSS software, version 19.0 (International Business Machines Corporation, Armonk, NY). Comparisons



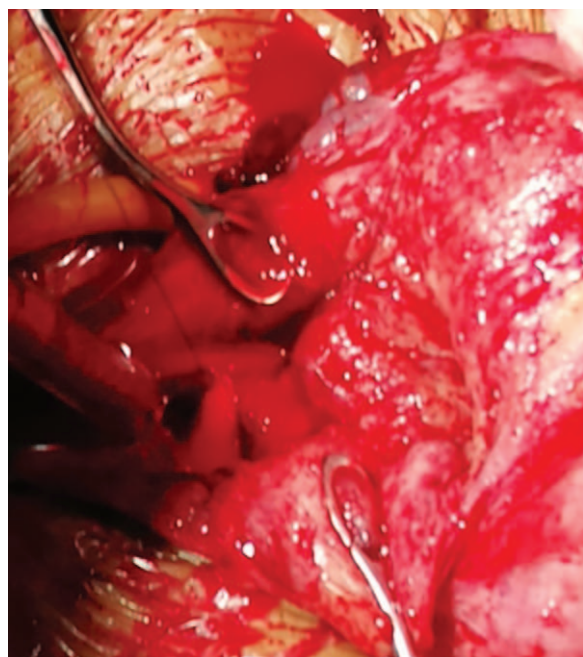
**Figure 1.** “The thin area”. It is located between the ends of displaced longitudinal muscle fibers in the corpus and circular muscle fibers in the lower corpus and lower uterine segment, which are covered by the placenta previa increta.

tom), duration of hospital stay after the operation, and expenses during and after the operation. Analysis of the data was performed with SPSS software, version 19.0 (International Business Machines Corporation, Armonk, NY). Comparisons



**Figure 2.** The diagram of surgical steps. A Allis forceps was passed through the uterine incision and used to grasp circular muscle fibers in the lower corpus and lower uterine segment, pulling the tissue upwards the uterine cavity.





**Figure 3.** Cervical internal os plasty. The tissue below the ends of damaged muscle fibers in the corpus uteri was sutured to the circular muscle fibers in the lower uterine segment using 2 or 3 simple absorbable sutures stitches.

between 2 groups were performed with Student *t* test or chi-squared test. A *P* value <.05 (two-tailed) was considered significant.

### 3. Results

All placenta that completely covered the internal cervical os were adhered to the lower uterine segment (placenta previa) and were embedded into the myometrium (placenta increta). After the removal of the placenta manually, instead of other conservative methods, the authors promptly applied cervical internal os plasty, and the technique proved effective. To analyze more accurately the effectiveness of the new technique, we compared it with other hemostatic techniques.

The mean age of all women was  $33.36 \pm 4.99$  years old and did not differ significantly between the study and control groups. There were no significant differences in age, gravidity, parity, gestational age, and previous dilatation and curettage techniques between the study and control groups. Ninety (77.6%) women in our study underwent one or more previous dilatation and curettage techniques (range, 1–6). Eighteen women had 1 or 2 previous cesarean section in the study group, and 16 women had

previous cesarean section in the control group but we could not find differences between the 2 groups.

As shown in Table 1, postpartum hemorrhage (blood loss  $\geq 1000$  mL) occurred in 23 patients in study group and 26 cases in control group respectively during cesarean section. The transfusion rate in study group is 28.6%, while red cell transfusion and/or autologous blood transfusion were required in 15 cases (25%) in control group. The mean operative time in the study group was 65.79 minutes, and the mean duration of the postoperative hospital stay was 4.59 days with fewer expenses. At the same time, we found no differences in these conditions between the 2 groups. No complications related to operations and hemorrhage including bladder or rectal injury and disseminated intravascular coagulation (DIC) encountered in any of the 2 groups. Histopathological examination of the uterus in all cases showed placenta increta, not percreta.

The new technique described above was successful in stopping the bleeding in 52 out of 56 patients; yielding a success rate of 92.9%. We resorted to hysterectomy in only 1 case and uterine tamponade in 3 patients in the study group. There was 1 hysterectomy and 15 uterine tamponade in the control group. And in the control group, internal iliac arterial embolization was performed in 1 woman after cesarean section due to the hemostatic failure of uterine tamponade. There was statistical significance about other applied supplementary techniques between the 2 groups.

### 4. Discussion

Placenta previa increta is a serious complication during pregnancy, and it has been associated with higher maternal and fetal morbidity and mortality during pregnancy, such as massive blood transfusion and preterm.<sup>[3,12]</sup> Hysterectomy can often occur because it is difficult to stop the bleeding from the placental attachment site, especially in the lower uterine segment. However, hysterectomy results in infertility and other adverse effects. Therefore, many obstetricians have reported some conservative surgical methods with success, such as hemostatic multiple square suturing. However, these procedures do not work in some cases of placenta previa increta. To achieve hemostasis in a more timely manner, we report an easy, effective, and conservative method for women with placenta previa increta.

The basic theory of the sutural hemostatic technique, cervical internal os plasty, relies on the anatomy of the uterus. The distal ends of the muscle fibers in the corpus uteri are terminated to the cervical anatomical internal os. One of the most important risk factors in placenta previa and placenta increta is dilatation and curettage. Previous research has suggested that the risk of placenta previa in pregnancy women with  $\geq 2$  abortions is 2 to 3 times that of women without abortion.<sup>[13]</sup> Multiple miscarriages can lead to the injury of basal lamina of endometrium, dysplasia

**Table 1**

#### Comparison of perioperative outcomes between the 2 groups.

Results	Study group (n=56)	Control group (n=60)	<i>t/x</i> <sup>2</sup>	<i>P</i>
Operative time, s	65.79 ± 22.68	72.75 ± 30.23	0.61	.54
Postpartum hemorrhage ( $\geq 1000$ mL)	23 (41.1%)	26 (43.3%)	0.06	.805
Blood transfusion	16 (28.6%)	15 (25%)	0.19	.66
Other applied supplementary techniques	4 (7.1%)	17 (28.3%)	8.773	.003
Postoperative hospital stay, d	4.59 ± 2.36	4.72 ± 1.98	0.32	.75
Expenses during and after the operation (\$)	3100.76 ± 147.42	3291.21 ± 158.58	0.93	.35

of the decidua development, the implantation abnormality of embryo, and hypoperfusion of the placenta and so on, which ultimately causes placental abnormality. But it has not been reported that whether abortion increases the risk of placenta previa is related to the injury of cervical internal os.

When performing dilatation and curettage, the repeated use of surgical instruments damages muscle fibers around the anatomical internal os. With the increase in the uterine cavity and the progressive stretching of the uterine isthmus during pregnancy, ruptured muscle fibers in the corpus near the anatomical internal os and its distal ends are moved to the uterine body, and ruptured circular muscle fibers in the uterine isthmus near the anatomical internal os are moved reversely. As a result, a thin area appears between the ends of displaced muscle fibers in the corpus and circular muscle fibers in the lower corpus and lower uterine segment, which are covered by the placenta previa increta. After removal of the placenta, the thin area, that is, the placental attachment site in the lower corpus and the lower uterine segment, makes hemostasis difficult due to the poor muscle fiber contraction. In cesarean delivery for placenta previa increta, cervical internal os plasty was performed to repair the damaged thin area and to restore the anatomy of cervical anatomical internal os and finally to control bleeding from the thin area covered by the placenta previa increta.

In our current study, we found that most of the women (90/116) with placenta previa increta had obstetric histories of dilatation and curettage, which damaged the muscle fibers around the anatomical internal os. This finding was consistent with a previous report.<sup>[13]</sup> The results, that the blood loss, blood transfusions, operative time, and hospitalization time after cesarean section in the study group were similar to those in the control group, illustrated that the new technique was safe and effective as other conservative methods. The new technique described in our study was successful in stopping the bleeding in most of the patients. Compared with the control group, other applied supplementary techniques including uterine tamponade, pelvic arterial embolization, or emergency hysterectomy for the bleeding from the the placental attachment site is fewer significantly in the study group. There were no other severe complications, and all of the women recovered very well with short hospital stays after cesarean section. We carefully analyzed all of the sutural hemostatic operations and found that one of the reasons for the failure of hemostasis at the placental attachment site was that the damaged thin area in the lower uterine segment and the damaged anatomical internal os of the cervix were not restored so that the bleeding from the weak area covered by the placenta previa accreta could not be stopped. However, cervical internal os plasty avoids this drawback. The purpose of the new suture technique is to repair the damaged thin area with bleeding in the lower uterine segment and to restore the damaged anatomic internal os of the cervix, and in the long term, it is good for women's future pregnancy. In 4 cases in the study group, blood loss during Caesarean section was >1000 mL due to uterine atony after cervical internal os plasty, rather than the bleeding from the placental attachment site.

Our data also revealed that the new technique had great success in stopping bleeding as other conservative hemostatic techniques. The new suture technique is simple and easy to understand. It requires no advanced medical equipment and is particularly practical for primary-level hospitals. There is no complicated anatomical structure, so it can be implemented by any trained obstetrician who is qualified to perform Caesarean

section. It can prevent more blood transfusion if the technique is used early once the placenta is removed manually. Of course, if the placenta is difficult to be removed from the uterine wall, or the bleeding is not caused by placenta previa accreta, other techniques can be performed.

However, some limitations are also present in this new technique. First, this was a retrospective study and our study was lack of postoperative follow-up. Therefore, a randomized controlled trial is required to evaluate the efficiency of this technique. And a long-term follow-up should be considered in the future. Second, the perioperative outcomes might be influenced by other uncontrollable factors. We enrolled the surgeries by obstetricians with the same qualification and estimate blood loss with the same methods to address potential sources of bias. Third, a small part of patients may fail to stop bleeding and then need further process as other conservative methods do. But we can improve the skill levels of the surgeon by training.

## 5. Conclusion

In summary, according to the results of our study, this study shows cervical internal os plasty is proposed as a simple, effective, safe, and conservative option for the treatment of placenta previa accreta.

## Acknowledgments

The authors thank all the women who participated in the study.

## Author contributions

Guiqiong Huang drafted the manuscript, collected and analyzed the data.

Xiaodong Wang conceived of and designed the study, helped draft the manuscript, revised it critically for important intellectual content, and coordinated data collection.

Haiyan Yu helped with coordination of data collection and helped draft the manuscript. All authors read and approved the final manuscript.

Shou Zhou participated in interpretation of the analyses, and helped with coordination of study design and data collection.

**Conceptualization:** Xiaodong Wang.

**Data curation:** Guiqiong Huang, Haiyan Yu, Shu Zhou.

**Formal analysis:** Xiaodong Wang.

**Methodology:** Xiaodong Wang.

**Supervision:** Xiaodong Wang.

**Writing – original draft:** Guiqiong Huang, Haiyan Yu, Shu Zhou.

**Writing – review & editing:** Xiaodong Wang, Haiyan Yu.

## References

- [1] Matsubara S, Ohkuchi A, Kikkawa M, et al. Blood loss in low-lying placenta: placental edge to cervical internal os distance of less vs. more than 2 cm. *J Perinat Med* 2008;36:507–12.
- [2] Tan CH, Tay KH, Sheah K, et al. Perioperative endovascular internal iliac artery occlusion balloon placement in management of placenta accreta. *AJR Am J Roentgenol* 2007;189:1158–63.
- [3] Garmi G, Salim R. Epidemiology, etiology, diagnosis, and management of placenta accreta. *Obstet Gynecol Int* 2012;2012:873929.
- [4] Klar M, Michels KB. Cesarean section and placental disorders in subsequent pregnancies—a meta-analysis. *J Perinat Med* 2014;42:571–83.
- [5] Ferrazzani S, Guariglia L, Triunfo S, et al. Successful treatment of post-cesarean hemorrhage related to placenta praevia using an intrauterine balloon. Two case reports. *Fetal Diagn Ther* 2006;21:277–80.

- [6] Huang G, Zhou R, Hu Y. A new suture technique for cesarean delivery complicated by hemorrhage in cases of placenta previa accreta. *Int J Gynaecol Obstet* 2014;124:262–3.
- [7] Cho JH, Jun HS, Lee CN. Hemostatic suturing technique for uterine bleeding during cesarean delivery. *Obstet Gynecol* 2000;96:129–31.
- [8] El-Hamamy E, Wright A, B-Lynch C. The B-Lynch suture technique for postpartum haemorrhage: a decade of experience and outcome. *J Obstet Gynaecol* 2009;29:278–83.
- [9] Palacios-Jaraquemada JM. Efficacy of surgical techniques to control obstetric hemorrhage: analysis of 539 cases. *Acta Obstet Gynecol Scand* 2011;90:1036–42.
- [10] Ojala K, Perala J, Kariniemi J, et al. Arterial embolization and prophylactic catheterization for the treatment for severe obstetric hemorrhage\*. *Acta Obstet Gynecol Scand* 2005;84:1075–80.
- [11] Carnevale FC, Kondo MM, de Oliveira Sousa WJr, et al. Perioperative temporary occlusion of the internal iliac arteries as prophylaxis in cesarean section at risk of hemorrhage in placenta accreta. *Cardiovasc Intervent Radiol* 2011;34:758–64.
- [12] Silver RM, Barbour KD. Placenta accreta spectrum: accreta, increta, and percreta. *Obstet Gynecol Clin North Am* 2015;42:381–402.
- [13] Hossain GA, Islam SM, Mahmood S, et al. Placenta previa and its relation with maternal age, gravidity and cesarean section. *Mymensingh Med J* 2004;13:143–8.