

OPEN

Adrenal Pheochromocytoma Incidentally Discovered in a Patient With Parkinsonism

Luigi Petramala, MD, PhD, Antonio Concistrè, MD, Cristiano Marinelli, MD, Laura Zinnamosca, MD, Gino Iannucci, MD, Piernatale Lucia, MD, Giuseppe De Vincentis, MD, and Claudio Letizia, MD

Abstract: To evaluate the diagnostic route of pheochromocytoma (PHEO) in a patient under dopaminergic treatment.

A 70-year-old man with Parkinsonism and under treatment with levodopa and carbidopa came to our observation for evaluation of arterial hypertension and right adrenal mass discovered incidentally.

To evaluate adrenal hormone levels we performed a dexamethasone suppression test, plasma aldosterone levels and 24-hr urinary metanephrine, which revealed elevated levels of catecholamines metabolites. 123-I-metaiodobenzylguanidine SPECT scintiscan revealed raised activity within the right adrenal gland concordant with the mass. The diagnosis of PHEO was posed and an elective laparoscopic adrenalectomy was performed; histopathological examination confirmed the PHEO diagnosis.

Recently the coexistence of PHEO and Parkinsonism is a very rare association of diseases, with only 3 cases reported in literature. In this article, another case is reported and diagnostic procedures are discussed.

(*Medicine* 94(42):e1855)

Abbreviations: PHEO = pheochromocytoma, MRI = magnetic resonance imaging.

INTRODUCTION

Pheochromocytoma (PHEO) and paraganglioma (PGL) are neural-crest derived neoplasms, primarily found in the adrenal gland with a prevalence of 0.1% to 0.6% in patients affected by hypertension.¹ Tumors of adrenal medulla predominantly secrete norepinephrine over epinephrine, instead adrenal medulla normally secretes 80% of epinephrine. Hypertension, either paroxysmal or sustained, is the most consistent finding in neoplasms, and the classical triad of symptoms (headache, palpitations, and diaphoresis) is present in more than 50% of patients.² In severe cases, a patient can present with myocardial infarction, heart failure, pulmonary

oedema, arrhythmias, or intracranial hemorrhage. The coexistence of PHEO and Parkinson's disease or Parkinsonism is very rare, with only 3 cases reported in literature.³⁻⁵

CASE REPORT

A 70-year-old man with history of Parkinsonism and diabetes mellitus presented to the Specialized Center of Secondary Hypertension, University of Rome "La Sapienza," Rome, Italy for an evaluation of hypertension and an adrenal incidentaloma that was detected on abdomen ultrasonography (US) and confirmed by magnetic resonance imaging (MRI) (3 × 2 cm round mass with the presence of necrotic areas; Figure 1A). The patient signed an informed consent to participate in this case report.

At the age of 67 years the patient begun to exhibit gait deficits and bradykinesia of the left lower limb, followed by stiffness of the trunk and amimica facies and limitation in upward gaze. An 123-I-FP-CIT (DAT-SCAN)-SPECT showed a reduction in the physiological concentration in brain presynaptic dopamine transporters with consequent reduction of the striatal structures. The clinical features appeared compatible with the diagnosis of Parkinsonism associated with pseudobulbar syndrome. Levodopa and benserazide therapy was started, subsequently replaced with levodopa and carbidopa at a dose of 750 mg per daily. After starting treatment with levodopa and carbidopa, the patient had a marked improvement in symptoms. He did not report any complaints of episodic headaches, palpitations, sweating, and chest pain. On examination, patient's pulse rate was 67 beats min⁻¹, blood pressure (BP) was 160/100 mm Hg, with postural drop (140/80 mm Hg). His height was 181 cm, and his weight was 75 kg, with a body mass index of 22.8 kg m⁻². No cardiac murmurs or abdominal bruits were revealed. His average 24-hr-ambulatory-BP (ABPM) was 130/90 mm Hg, with "nondipping" profile. The ECG was normal and mild left ventricular concentric remodeling was showed by an echocardiography.

The patient was under treatment with irbesartan, nebivolol, metformin, levodopa, and carbidopa. Routine blood tests were normal except for fasting blood glucose (138 mg dL⁻¹; normal range 70–100 mg dL⁻¹). After replacing nebivolol and irbesartan with nifedipine (60 mg per daily) and doxazosin (8 mg per daily) BP decreased to normal values (135/85 mm Hg), and biochemical tests to determine functional hormone secretion were performed. Investigation for adrenal hormones, including low-dose dexamethasone suppression test, plasma aldosterone levels were normal, while 2 repeated 24-hr-urinary metanephrines measurements were elevated (721 and 782 μg/24 hr; normal range 20–345 μg/24 hr; Table 1).

Considering the probability of adrenal PHEO, a 123-I-metaiodobenzylguanidine (123-I-MIBG) SPECT scintiscan was performed; 185 MBq of 123 I-MIBG was i.v. administered

Editor: Oscar Arias-Carrion.

Received: May 4, 2015; revised: September 3, 2015; accepted: September 27, 2015.

From the Specialized Center of Secondary Hypertension (LP, AC, CM, LZ, CL); Department of Internal Medicine and Medical Specialties (LP, AC, CM, LZ, GI, PL, CL); and Department of Radiology, Section Nuclear Medicine, University of Rome "La Sapienza," Rome, Italy (GDV).

Correspondence: Claudio Letizia, Department of Internal Medicine and Medical Specialties, Policlinico "Umberto I," University "La Sapienza," 00155 Rome, Italy (e-mail: claudio.letizia@uniroma1.it).

The authors have no funding and conflicts of interest to disclose.

Copyright © 2015 Wolters Kluwer Health, Inc. All rights reserved.

This is an open access article distributed under the Creative Commons Attribution-NonCommercial-NoDerivatives License 4.0, where it is permissible to download, share and reproduce the work in any medium, provided it is properly cited. The work cannot be changed in any way or used commercially.

ISSN: 0025-7974

DOI: 10.1097/MD.0000000000001855

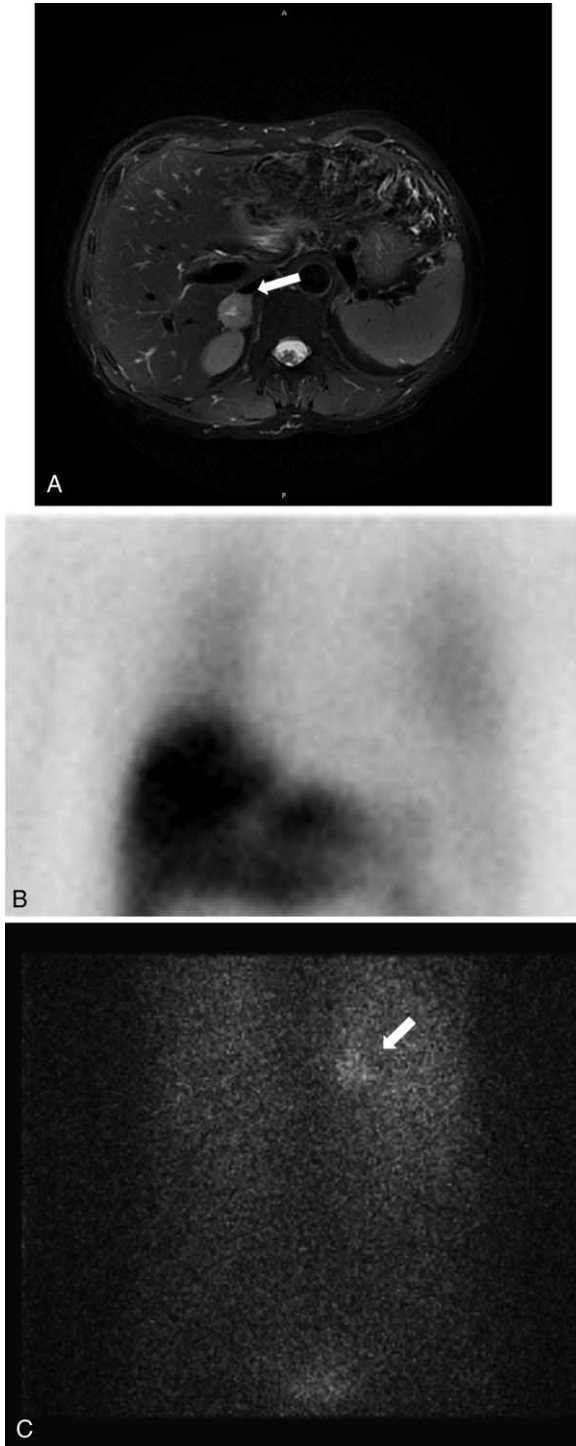


FIGURE 1. (A) Magnetic resonance imaging (MRI): mass in the right adrenal gland (3 × 2 cm) with the presence of necrotic areas. (B) Thorax scintiscan with 123-I metaiodio benzilguanidine (123-I-MIBG) showed a severely reduced MIBG cardiac uptake, with a heart to mediastinum (HM) ratio of 1.38. (C) Scintiscan with 123-I metaiodio benzilguanidine (123-I-MIBG) shows raised activity within the right adrenal gland.

and planar images of thorax were obtained at 20 min and 4 hr, while images of abdomen were obtained at 4 and 24 hr. Thorax scan showed a severely reduced MIBG cardiac uptake, with a heart to mediastinum (HM) ratio of 1.38 (HM cut off: 2), highly suggestive of a Parkinson's disease (Fig. 1B); whereas, abdomen scan revealed raised activity within the right adrenal gland, concordant with the mass (Fig. 1C). A surgical consult was requested, and the patient, now diagnosed with PHEO, was to undergo a surgical resection; however, the surgery was postponed, and the patient was prescribed with 4 mg of doxazosin twice a day, followed by 5 mg of nebivolol daily after testing for the adequacy of the α -blockade in order to prevent paroxysmal increases of BP during surgery. One month later, with a BP of 135/80 mm Hg, the patient underwent a laparoscopic tumor resection. The histopathological examination confirmed the diagnosis of PHEO. The patient has been in regular follow-up for the 12 months, and in treatment with levodopa and carbidopa in addition to doxazosin (4 mg per daily). During the follow-up adrenal hormone tests were run (Table 1). Office and ABPM showed optimal control of BP (average systolic and diastolic BP 125/75 mm Hg), and laboratory analysis showed normal values of fasting glycemia (89 mg dL⁻¹) without metformin treatment.

DISCUSSION

Since the introduction of imaging techniques in medical practice, abnormalities of unknown clinical significance were found more often. One of these abnormalities is the adrenal incidentaloma.⁶ Pathology of adrenal incidentaloma may vary from simple benign cyst or lipoma to adrenal carcinoma. The differential diagnosis of the adrenal mass includes several conditions, such as adenoma, myelolipoma, cyst, lipoma, PHEO, hyperplasia, adrenal cancer, and metastatic cancer.⁷ In order to differentiate the adrenal mass detected on abdominal imaging studies, patients should always be evaluated with hormonal tests.^{8,9} This hormonal evaluation can be difficult with patients with comorbidities, or with patients who are prescribed with interfering medications.

In this article, we discuss the case of PHEO in Parkinsonian patient, in treatment with dopaminergic medications, that presented with an adrenal incidentaloma. Currently only 3 cases have been reported in literature.^{3–5} Our patient represented the fourth case, and the first one in Italy.

The first case reported by Metha et al³ is a 59-year-old American man with a 7-year history of Parkinson's disease, presented episodes of sudden severe headaches with neck pain, tachycardia, sweating, and paleness associated with marked elevation of BP. These symptoms suggested a condition of hypercatecholaminism, and even though further tests revealed normal values of plasma and urinary metanephrines, an 123-I-MIBG-single photon CT (SPECT) was positive for increased uptake in the left adrenal region concordant with the nodule showed in the MRI scan. The histopathological examination, after laparoscopic adrenalectomy, revealed an adrenal medullary hyperplasia.

The second case reported by Collier et al⁴ is about a 63-year-old American man, with a 5-year history of Parkinson's disease and a left adrenal incidentaloma. The urinary metabolites of catecholamines were elevated, and 123-I-MIBG confirmed an increased activity within the left adrenal gland. Histological examination following laparoscopic surgical excision showed the presence of a composite PHEO/PGL/ganglioneuroma.

TABLE 1. Endocrinological data

	At Diagnosis	After Surgery (1 yr)	Range
Serum			
Plasma renin activity (PRA)	0.31	0.5	0.2–2.7 ng mL ⁻¹ hr ⁻¹
Plasma aldosterone (PAC)	14.04	10.45	3.0–16.0 ng dL ⁻¹
Plasma cortisol	13	16.5	4.5–21.0 µg dL ⁻¹
Plasma ACTH	20	23	10–90 pg mL ⁻¹
PAC/PRA ratio	36.4	20.9	<40 ng mL ⁻¹ hr ⁻¹ :ng dL ⁻¹
Urine			
Free cortisol (UFC)	155	143.4	38–200 µg/24 hr
Aldosterone (UAC)	20	22.5	2.84–34.00 µg/24 hr
Metanephrines	721; 782	108	20–345 µg/24 hr
	<i>Dexamethasone suppression test (1 mg) at diagnosis</i>		
	Plasma cortisol	4	<5 µg dL ⁻¹
	ACTH	9	<50% of baseline

ACTH = adrenocorticotropic hormone, UAC = urinary aldosteron concentration, UFC = urinary free cortisol.

The third case reported by Shimodaira et al⁵ is about a 75-year-old Japanese man, affected by Parkinson's disease and paroxysmal hypertension associated with vague abdominal symptoms and right adrenal mass showed during abdominal US. Urine analysis revealed elevated levels of catecholamines and their metabolites, and 123-I-MIBG scintigraphy showed increased uptake in the right adrenal gland concordant with computed tomography (CT). After laparoscopic adrenalectomy, histopathological examination analysis of the mass confirmed the diagnosis of PHEO.

Parkinson's disease is a chronic neurodegenerative disorder characterized by dopaminergic dysfunction and disturbances in neurotransmitter system with motor system disorders including tremor, rigidity, slowness of movement, and impaired balance or coordination. Primary treatment involves oral dopaminergic drugs such as levodopa. Levodopa is converted peripherally to other catecholamines, such as norepinephrine, epinephrine, and their metabolites, and medications containing levodopa may cause false-positive results in endocrine testing for PHEO.¹⁰

The clinical presentation and biohumoral markers of PHEO depend on the capacity of the neoplasm to synthesize, metabolize, and release catecholamines and their metabolites into circulation. Initial biochemical tests for PHEO, recommended by Clinical Guidelines Subcommittee of Endocrine Society,¹¹ should include measurements of plasma-free metanephrines or urinary fractionated metanephrines.

In fact, traditional biochemical tests, including measurements of urine and plasma catecholamines, and urinary vanilmandelic acid, may be unreliable because catecholamine secretion in PHEO is often episodic or even negligible in asymptomatic patients. The higher diagnostic accuracy of metanephrines can be attributed to continuous intratumoral production and secretion of metanephrines into circulatory compartment.¹⁰ Particularly, the measurements of urine metanephrines by mass spectrometry provide excellent sensitivity (97%) and specificity (91%) for diagnosis of PHEO.

Several factors have to be taken into account in order to attain a correct interpretation of biochemical test results. Pre-analytical factors may affect the results, such as exercise, posture, food, stress, and medications; these factors may alter production or disposition of catecholamines and their metabolites. Particularly, some drugs (acetaminophen, labetalol, buspirone, mesalazine, sulfasalazine, tricyclic antidepressants, and

levodopa) can interfere analytically or pharmacodynamically with measurements of plasma and urinary catecholamines and metabolites, which may result in false-positive test results.^{11,12} Particularly, levodopa causes falsely elevated urine normetanephrine, and it can also cause mildly raised values of urine metanephrines.¹² Regarding our patient, the dopaminergic medications (levodopa and carbidopa) may have interfered in the measurement of free urinary metanephrines; as it was impossible to discontinue these medications, we performed determination of urinary metanephrines only.

Another important data showed in these case report (comprised our case) were that in all Parkinsonian patients with suspected diagnosis of PHEO and in treatment with dopaminergic drugs the 123-I-MIBG was performed. The MIBG scintigraphy is based on evidence that norepinephrine and MIBG have the same mechanisms for uptake, storage, and release.¹³

Radiolabeled I-MIBG demonstrate high uptake both in normal sympathetically innervated tissues, such as the heart and salivary glands, and in tumors that express the neurohormone transporters, specifically those of neural crest and neuroendocrine origin.¹⁴ Currently, 123-I-MIBG is considered the gold standard in diagnosing these tumors. Particularly, 123-I-MIBG scintigraphy is used as a diagnostic tool for the detection of PHEO. The sensitivity of 123-I-MIBG scintigraphy in PHEO is reported to be 95%, whereas the specificity is 80% to 90%.¹⁵ However, tumors smaller than 1.5 cm in diameter and with extensive necrosis or hemorrhage may yield false-negative results due to poor uptake of the tracer. Only limited reports of false-positive uptake in other lesions have been published,¹⁶ and 1 major cause of false-positive findings is urinary tract retention, since the reagent is excreted in the urine.¹⁷

Recently, Jacobson et al,¹⁵ in a recent meta-analysis of 123-I-MIBG, concluded that "although results in clinical practice will likely be a few percentages lower, the long history of successful use of this technique and the recent prospective clinical trial support that continued utility of 123-I-MIBG imaging in the diagnosis and management of patients with PHEO."

Another finding observed in our Parkinsonian patient during ¹²³I-MIBG (SPECT) scan was the reduced cardiac uptake of the ligand, which was consistent with the postganglionic sympathetic denervation which is frequent in Parkinson's disease. In fact, in recent years, cardiac scintigraphy with MIBG labeled with iodine (123-I) have been used in Parkinson's disease for evaluating noradrenergic activity of myocardium.

This method provides a functional analysis of the sympathetic postganglionic pathway to evaluate “in vivo” the noradrenergic neurotransmission of the heart.¹⁸

In conclusion, a feature of Parkinson’s disease appears to be an inverse correlation with all types of cancer excluding malignant melanoma. Interestingly, the melanocytes and the cells of the PHEO derived both from the neural crest. Moreover, these 2 types of cells and neurons of the substantia nigra, ascribed to the pathogenesis of Parkinson’s disease, are all pigmented cells.¹⁹ This is the only association in contrast to the finding that neurodegenerative diseases have a lower risk of developing neoplasms.^{20,21}

REFERENCES

- Lenders JW, Eisenhofer G, Mannelli M, et al. Pheochromocytoma. *Lancet*. 2005;366:665–675.
- Cotesta D, Petramala L, Serra V, et al. Clinical experience with pheochromocytoma in a single centre over 16 years. *High Blood Press Cardiovasc Prev*. 2009;16:183–193.
- Mehta SH, Prakash R, Prisant LM, et al. Diagnosis of pheochromocytoma in the setting of Parkinson disease. *Nat Rev Neurol*. 2009;5:343–347.
- Collier A, Ghosh S, Breckenridge A, et al. A pheochromocytoma occurring in a patient with Parkinson’s disease on L-Dopa therapy: a diagnostic challenge. *Clin Endocrinol (Oxf)*. 2012;76:763–764.
- Shimodaira M, Niwa T, Nakajima K, et al. Diagnostic challenge of pheochromocytoma in a patient receiving levodopa for Parkinson’s disease. *Endocr Pract*. 2014;20:e112–e115.
- Bovio S, Cataldi A, Reimondo G, et al. Prevalence of adrenal incidentaloma in a contemporary computerized tomography series. *J Endocrinol Invest*. 2006;29:298–302.
- Mantero F, Terzolo M, Arnaldi G, et al. A survey on adrenal incidentaloma in Italy. Study Group on Adrenal Tumors of the Italian Society of Endocrinology. *J Clin Endocrinol Metab*. 2000;85:637–644.
- Gopan T, Remer E, Hamrahan AH. Evaluating and managing adrenal incidentalomas. *Cleve Clin J Med*. 2006;73:561–568.
- Perry CG, Sawka AM, Singh R, et al. The diagnostic efficacy of urinary fractionated metanephrines measured by tandem mass spectrometry in detection of pheochromocytoma. *Clin Endocrinol (Oxf)*. 2007;66:703–708.
- Eisenhofer G, Brown S, Peitzsch M, et al. Levodopa therapy in Parkinson’s disease: influence on liquid chromatographic tandem mass spectrometric-based measurements of plasma and urinary normetanephrine, metanephrine and methoxytyramine. *Ann Clin Biochem*. 2014;51 (Pt 1):38–46.
- Lenders JW, Duh QY, Eisenhofer G, et al. Pheochromocytoma and paraganglioma: an endocrine society clinical practice guideline. *J Clin Endocrinol Metab*. 2014;99:1915–1942.
- Chandrasekaran S, Ionica N, Streeten EA. Levodopa-carbidopa treatment and falsely high urinary dopamine levels. *Endocr Pract*. 2013;19:377–378.
- Yamashita T, Kodama S, Ohto M, et al. Use of porous anodic alumina membranes as a nanometre-diameter column for high performance liquid chromatography. *Chem Commun (Camb)*. 2007;11:1160–1162.
- Sakakibara R, Tateno F, Kishi M, et al. MIBG myocardial scintigraphy in pre-motor Parkinson’s disease: a review. *Parkinsonism Relat Disord*. 2014;20:267–273.
- Jacobson AF, Deng H, Lombard J, et al. ¹²³I-meta-iodobenzylguanidine scintigraphy for the detection of neuroblastoma and pheochromocytoma: results of a meta-analysis. *J Clin Endocrinol Metab*. 2010;95:2596–5606.
- Sone H, Okuda Y, Nakamura Y, et al. Radioiodinated metaiodobenzylguanidine scintigraphy for pheochromocytoma. A false-positive case of adrenocortical adenoma and literature review. *Horm Res*. 1996;46:138–142.
- Rainis T, Ben-Haim S, Dickstein G. False positive metaiodobenzylguanidine scan in a patient with a huge adrenocortical carcinoma. *J Clin Endocrinol Metab*. 2000;85:5–7.
- Sawada H, Oeda T, Yamamoto K, et al. Diagnostic accuracy of cardiac metaiodobenzylguanidine scintigraphy in Parkinson disease. *Eur J Neurol*. 2009;16:174–182.
- Driver JA. Inverse association between cancer and neurodegenerative disease: review of the epidemiologic and biological evidence. *Biogerontology*. 2014;15:547–557.
- Benito-León J, Romero JP, Louis ED, et al. Faster cognitive decline in elders without dementia and decreased risk of cancer mortality: NEDICES study. *Neurology*. 2014;82:1441–1448.
- Romero JP, Benito-León J, Louis ED, et al. Alzheimer’s disease is associated with decreased risk of cancer-specific mortality: a prospective study (NEDICES). *J Alzheimers Dis*. 2014;40:465–473.