

Diaphragmatic Hernia after Transhiatal Esophagectomy for Esophageal Cancer

Dohun Kim, M.D., Si-Wook Kim, M.D., Jong-Myeon Hong, M.D.

Department of Thoracic and Cardiovascular Surgery, Chungbuk National University College of Medicine

Diaphragmatic hernia was found in a patient who had undergone transhiatal esophagectomy for early esophageal cancer. Chest X-ray was not helpful, but abdominal or chest computed tomography was useful for accurate diagnosis. Primary repair through thoracotomy was performed and was found to be feasible and effective. However, long-term follow-up is required because hernia recurrence is common.

Key words: 1. Diaphragmatic hernia
2. Transhiatal esophagectomy
3. Esophageal neoplasms

Case report

Transhiatal esophagectomy with cervical esophago-gastrostomy was performed for early distal esophageal cancer because of severe adhesion in the right thoracic cavity due to the tuberculous destruction of the right upper parenchymal area. The hiatal opening was four finger widths, and crus division was performed only on the left side. The pathology of the lesion indicated T2N0M0 squamous cell carcinoma, and no adjuvant treatment was applied. The patient showed relatively good recovery with temporary hoarseness. The findings of regular follow-ups performed every two months were normal until left upper quadrant abdominal pain developed suddenly 6 months after surgery. The patient visited a local clinic and underwent abdominal computed tomography (CT) and chest X-ray. The chest X-ray (Fig. 1A) showed no significant problems, but the CT revealed a prominent diaphragmatic hernia (Fig. 1B, C). The patient did not visit our outpatient clinic at that time because the symptoms subsided quickly.

The patient visited the outpatient clinic two months after the hernia was detected on the abdominal CT, and curative hernia surgery was planned. A double-lumen endotracheal tube was inserted, and left posterolateral thoracotomy was performed through the 7th intercostal space. A large diaphragmatic defect 10.16–12.7 cm in length was detected along the left side of the hiatal opening (Fig. 2). Reduction of the small and large bowel into the abdominal cavity was performed successfully, and the hernia opening was primarily closed with pledged 3-0 Prolene sutures. A regular diet was started on postoperative day 2, and the patient was discharged on postoperative day 5. No complications were observed during the recovery phase, and the patient was found to be in good condition upon visiting the outpatient clinic on postoperative day 35.

Discussion

Post-esophagectomy diaphragmatic hernia (PDH) has been reported as a rare complication [1,2]. However,

Received: November 11, 2015, Revised: February 5, 2016, Accepted: February 12, 2016, Published online: August 5, 2016

Corresponding author: Jong-Myeon Hong, Department of Thoracic and Cardiovascular Surgery, Chungbuk National University College of Medicine, 1 Chungdae-ro, Seowon-gu, Cheongju 28644, Korea
(Tel) 82-43-269-6062 (Fax) 82-43-269-6969 (E-mail) hongjm1@gmail.com

© The Korean Society for Thoracic and Cardiovascular Surgery. 2016. All right reserved.

© This is an open access article distributed under the terms of the Creative Commons Attribution Non-Commercial License (<http://creativecommons.org/licenses/by-nc/4.0>) which permits unrestricted non-commercial use, distribution, and reproduction in any medium, provided the original work is properly cited.

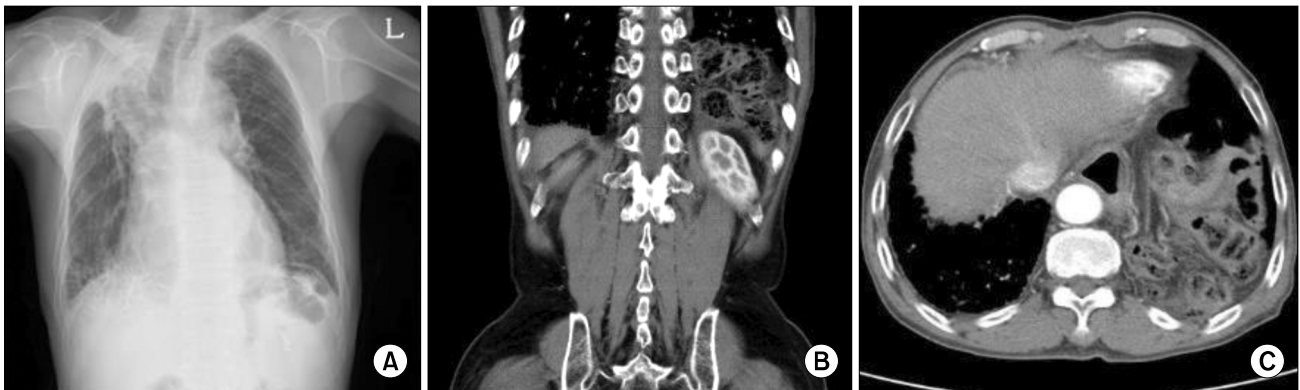


Fig. 1. Abdominal computed tomography revealed a prominent transhiatal hernia. (A) Chest X-ray was not helpful for the diagnosis. (B, C) However, portions of the small and large bowel were seen in the left thoracic cavity on abdominal computed tomography.

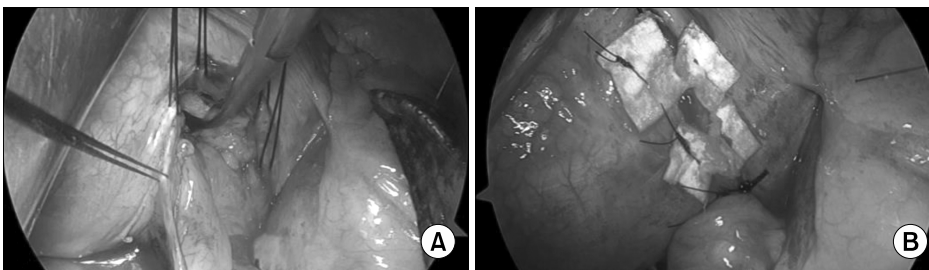


Fig. 2. Post-esophagectomy diaphragmatic hernia repair with pledgetted Prolene sutures. (A) A large diaphragmatic defect was seen upon left thoracotomy. (B) Reduction of the small and large bowel into the abdominal cavity was successful, and primary closure of the defect was performed with pledgetted 3-0 Prolene sutures.

it can be a common event with or without hernia-related symptoms [3]. Moreover, a higher incidence of PDH has been reported in cases of transhiatal esophagectomy (24%) than in those of the Ivor-Lewis procedure (12%) and in cases of minimally invasive surgery (4.5%) than in those of open esophagectomy (2.5%) [3,4]. Most instances of PDH occur in the left chest (44 of 67 [3], 11 of 15 [1], and 9 of 9 [2]), possibly because if an opening occurs in the left upper abdomen after gastric preparation, the bowels can move into this space. Moreover, the less-damaged plain serosal surface is located at a greater curvature of the conduit; therefore, less adhesion develops on the left side, making herniation more likely in the left chest [2]. In this case, the chief complaint was persistent left upper quadrant abdominal pain. CT was useful for detecting PDH, and its early application is thus recommended when persistent abdominal symptoms develop, particularly on the left side.

The causes of PDH vary widely and include the following: (1) lack of anchoring of the stomach to the diaphragm after transhiatal esophagectomy [3], (2) over-extension of the hiatus in laparoscopic proce-

dures [1], (3) respiratory problems aggravating negative intrathoracic pressure [5], and (4) steroid use [5]. In this case, the stomach was not anchored after transhiatal esophagectomy, and laparoscopic gastric preparation was performed. Some authors insist that PDH is potentially preventable by minimizing hiatal enlargement, repairing excessively large hiatuses [3], closing the open mediastinal pleura, or anchoring the stomach [5]. To prevent similar events, particular caution around the hiatus is recommended in laparoscopic procedures. This should be particularly emphasized in transhiatal esophagectomy because stomach anchoring or hiatus repair can be performed only in the abdominal phase.

While not all hernias require surgical repair, large or progressive hernias [3] with prominent symptoms should be repaired surgically. The median time interval from esophagectomy to hernia varies from 8 months to 2 years [2,3], and most hernia repairs have thus far been performed via an abdominal approach (9 of 9 [3], 14 of 15 [1], and 7 of 7 [2]). In this case, bowel herniation did not develop for 6 months, and a transthoracic approach was selected for hernia repair.

This approach was selected in anticipation of pleural adhesion, but no adhesions were observed. Some authors use a mesh for hernia repair in most of their cases, while the others use it in a more limited capacity [1-3]. We repaired the hernia directly without the use of a mesh material. The patient exhibited good postoperative status until postoperative day 35, but further long-term follow-up is required because recurrence is common after hernia repair [1,3].

In conclusion, PDH is not a rare complication but can be difficult to detect with routine chest X-ray. CT is useful for accurate diagnosis, and primary repair through thoracotomy is feasible and effective. However, long-term follow-up is required because hernia recurrence is common.

Conflict of interest

No potential conflict of interest relevant to this article was reported.

Acknowledgments

This work was supported by the research grant of Chungbuk National University in 2014.

References

1. Price TN, Allen MS, Nichols FC 3rd, et al. *Hiatal hernia after esophagectomy: analysis of 2,182 esophagectomies from a single institution*. Ann Thorac Surg 2011;92:2041-5.
2. Vallbohmer D, Holscher AH, Herbold T, Gutschow C, Schroder W. *Diaphragmatic hernia after conventional or laparoscopic-assisted transthoracic esophagectomy*. Ann Thorac Surg 2007;84:1847-52.
3. Ganeshan DM, Correa AM, Bhosale P, et al. *Diaphragmatic hernia after esophagectomy in 440 patients with long-term follow-up*. Ann Thorac Surg 2013;96:1138-45.
4. Benjamin G, Ashfaq A, Chang YH, Harold K, Jaroszewski D. *Diaphragmatic hernia post-minimally invasive esophagectomy: a discussion and review of literature*. Hernia 2015;19:635-43.
5. Jang HJ, Lee HS, Zo JI. *Pleural incarceration of the transverse colon after transthoracic esophagectomy: a case report*. Korean J Thorac Cardiovasc Surg 2009;42:115-8.