



ELSEVIER

Contents lists available at [ScienceDirect](https://www.sciencedirect.com)

Trauma Case Reports

journal homepage: www.elsevier.com/locate/tcr

Management of femoral non-union with post-traumatic bone defect using second-generation PRECICE® nail - A case report

Victor Lu^{a,*}, James Zhang^a, Matija Krkovic^b

^a School of Clinical Medicine, University of Cambridge, CB2 0SP, United Kingdom

^b Department of Trauma and Orthopaedics, Addenbrooke's Hospital, CB2 0QQ, United Kingdom

ARTICLE INFO

Keywords:

Trauma
Fracture
Limb lengthening
Osteogenesis

ABSTRACT

The management of post-traumatic bone defects with non-union remains a surgical challenge. Current techniques are often fraught with complications, posing a functional, economical, and psychological challenge for the patient. A 57 year-old gentleman suffered an open femoral fracture after a motorcycle accident. Having previously undergone open reduction internal fixation, he presented to us with atrophic non-union and bone defects, which were simultaneously treated with a second-generation PRECICE nail. Our treatment protocol was based on the strain theory, and involved initial distraction by ~5 mm at the non-union site, compression of the non-union site, followed by distraction osteogenesis at the non-union site. The patient achieved union and the initially planned limb lengthening regime was achieved with minimal complications. Self-lengthening, magnetically-driven PRECICE nails can successfully restore union and manage limb length discrepancies with reasonable patient satisfaction and minimal complications.

Introduction

The treatment of post-traumatic femoral diaphyseal non-union with bone defect is a surgical challenge. Common limb length discrepancy (LLD) procedures involve the Masquelet technique, vascularised bone grafts, and distraction osteogenesis using external fixators, yet they pose a functional and economical challenge for the patient, given the high complication rate and the frequent need for revision surgery [1].

Magnetically-driven PRECICE nails are self-lengthening internal devices activated via an external controller. We present one patient with post-traumatic femoral diaphyseal non-union with concomitant bone defect, treated using the second-generation PRECICE® nail (NuVasive Inc., San Diego, California). We based our management on Perren's strain theory [2], whereby callus formation is promoted if strain on bone cells can be reduced to tolerable limits.

This report gained ethical approval (PRN9742) and consent for publication was received from the patient.

Case report

A 57 year-old man was involved in a motorbike accident, and sustained a Gustilo-Anderson 3B right femoral open fracture. The following day, he underwent temporary external fixation, and open reduction internal fixation (ORIF). He was then placed on a strict

* Corresponding author at: Christ's College, St. Andrew's Street, Cambridge CB2 3BU, United Kingdom.

E-mail addresses: victorluwawa@yahoo.com.hk (V. Lu), zz357@cam.ac.uk (J. Zhang), matija.krkovic@addenbrookes.nhs.uk (M. Krkovic).

<https://doi.org/10.1016/j.tcr.2021.100585>

Accepted 18 December 2021

Available online 23 December 2021

2352-6440/© 2021 Published by Elsevier Ltd. This is an open access article under the CC BY-NC-ND license

(<http://creativecommons.org/licenses/by-nc-nd/4.0/>).

non weight-bearing regimen involving bed rest and elevation of affected limb to reduce oedema. He was discharged four weeks thereafter without complications, and began partial weight bearing (PWB).

After 105 weeks of PWB on crutches, he felt increasingly weak on his right leg, and presented to our clinic with a BMI of 21.9. Radiographs showed broken distal locking screws with limited callus formation (Figs. 1, 1b), a 30 mm bone defect (shorter on the right), and the patient was diagnosed with atrophic non-union (fig. 1c).

Ten weeks thereafter (119 weeks after his injury), he was admitted for simultaneous management of non-union and LLD. The existing intramedullary nail was removed, and the non-union was resected until the Paprika sign was seen, i.e. punctate cortical or cancellous bleeding [3]. This yielded an overall bone defect of 81 mm. Prophylactic intravenous flucloxacillin and gentamicin were given, and 5 samples were taken from around the fracture site for microbiology culture, each using a separate sterile instrument. Prophylactic antibiotic therapy was stopped the following day when microbiology cultures failed to detect any organism growth.

After debridement of the non-union, a 305 × 12.5 mm retrograde PRECICE nail was inserted, and distally locked. Bone fragments were then compressed together at the non-union, and when the bone ends were ~ 5 mm apart, the nail was proximally locked. The gap at the non-union was filled with autologous bone graft harvested from the ipsilateral proximal tibia, and was selected due to its ability

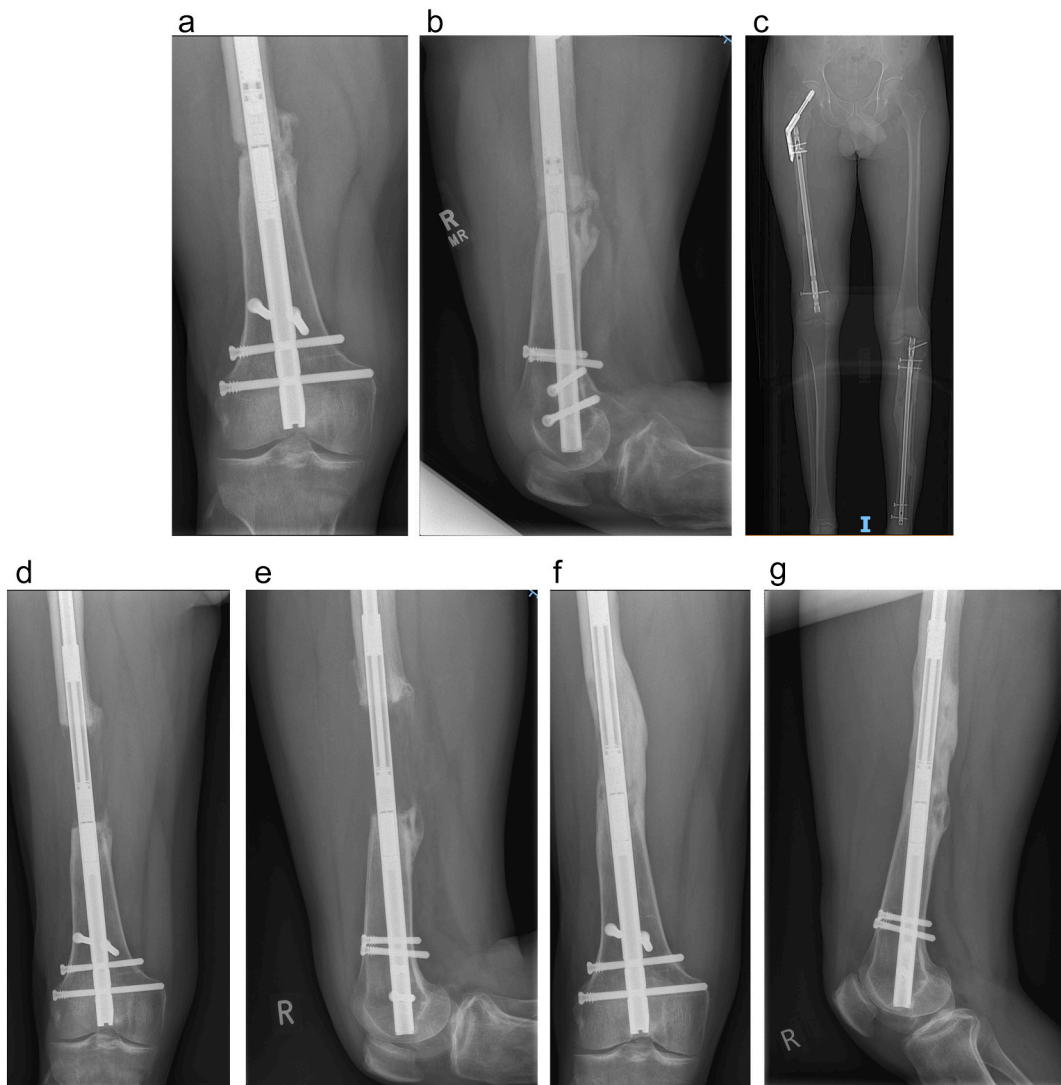

Fig. 1. a: AP X-ray of broken distal locking screws, non-union with limited callus formation.
 b: Lateral X-ray of broken distal locking screws, non-union with limited callus formation.
 c: AP X-ray showing the leg length discrepancy before PRECICE nail insertion.
 d: AP X-ray of distraction osteogenesis but no consolidation yet.
 e: Lateral X-ray of distraction osteogenesis but no consolidation yet.
 f: AP X-ray of consolidation and union.
 g: Lateral X-ray of consolidation and union.

to induce osseous repair, especially at non-union sites. Before closure, antibiotic-loaded calcium sulphate beads were added in the gap. Post-operative management involved non-weight bearing, active and passive physiotherapy using continuous passive motion machine.

Two weeks after the PRECICE nail insertion, the gap was distracted for ~5 mm, at a rate of 1 mm per day, to decrease strain on bone graft cells and promote callus formation. One week later, the non-union site was compressed to close the gap completely, producing preloaded continuous contact, allowing Haversian osteons to cross the fracture at the compressed surfaces, stimulating bone formation [2]. After another four weeks, distraction using the PRECICE nail started, in increments of 0.25 mm, four times a day, until the desired length was achieved (figs. 1d, 1e). The patient was followed up at two-week intervals. The regenerate were deemed weak, and lengthening was slowed to 0.75 mm per day three weeks later. We expected the regenerate to be weak on the anterolateral side, but of good quality on the posteromedial side.

Leg length was equalised 155 days after distraction osteogenesis began. Full weight bearing was achieved 259 days after distraction osteogenesis commenced, with X-rays showing good regeneration on three cortices. Nineteen weeks thereafter, he was able to walk unaided without any noticeable limp. He continued hydrotherapy up to 19 months post-operatively, but stopped due to the COVID-19 lockdowns, after which he started to experience increasing pain in his proximal hip, radiating to his knees.

The patient reported minimal neuromuscular deficits, and he credits the use of magnetically-driven self-lengthening nails, instead of external fixators, which he felt would have lowered his quality-of-life. However, his mental wellbeing has deteriorated to a degree out of proportion to his symptoms, due to COVID-19 lockdowns. Furthermore, his physiotherapy ceased due to COVID-19, which slowed the rate of physical recovery. Final X-ray showed consolidation at the distraction osteogenesis site and docking site union (figs. 1f, 1g), but scarring at the trochanteric bursa and fascia; he was recommended to continue with physiotherapy after lockdown and use NSAIDs. He was discharged after 230 weeks of follow-up. Fig. 2 shows a timeline depicting major clinical events.

Table 1 summarises the outcome measures and Table 2 presents patient reported outcome measures (PROMs) after recovery.

Discussion

To our knowledge, this is the first report of the simultaneous treatment of post-traumatic femoral bone loss and non-union, with a second-generation PRECICE nail, managed using the strain theory suggested by Perren et al. [2].

Limb-lengthening utilising distraction osteogenesis with external fixators began with the Ilizarov technique, and evolved to include limb lengthening over an intramedullary nail [4]. However external fixators are inherently cumbersome, and are associated with complications like pin site infections, knee stiffness, and docking site non-union [5]. Other approaches like the Masquelet technique are unreliable in the lower limb [6].

Mechanical intramedullary nails, e.g. Intramedullary Skeletal Kinetic Distractor, Guichet nails yielded satisfactory outcomes, however complications of runaway rails and premature consolidation were reported [7]. Motorised systems, e.g. Fitbone used a remote controller for lengthening, however spontaneous shortening and infection around subcutaneous receivers were reported [8]. We chose the second-generation magnetically-driven PRECICE nail, since this decreased internal corrosion and actuator pin fracture compared to first generation PRECICE nails. Also, the lack of welds and crowns prevents nail breakages, or crown failures [9].

Simultaneous reconstruction of femoral non-union with bone defect is difficult; underlying infection, comorbidities, joint stiffness complicate treatment and recovery. Utilising the strain theory [2], our distraction-compression-distraction regime proved successful. The femoral defect filled by autologous bone graft cells was initially distracted for ~5 mm, which decreased strain across bone graft cells, which is a precondition for mechanical induction of callus formation. Halvachizadeh et al. stated that bone healing is 'defined by the interplay of rigidity and elasticity of fracture fixation' [10]. According to the strain theory, the elasticity of fracture fixation is compatible with the indirect healing nature of biological internal fixation, provided that small unstable gaps of high strain are avoided [2]. Strain must be kept between the minimum needed to induce callus formation, and the maximum that still permits bony bridging. This can be achieved via osteoclastic resorption or by distraction, as was done in this case. This gap was then compressed after a month, to allow Haversian osteons to cross fracture plane, stabilised by neighbouring compressed areas of contact [2]. Only after a further

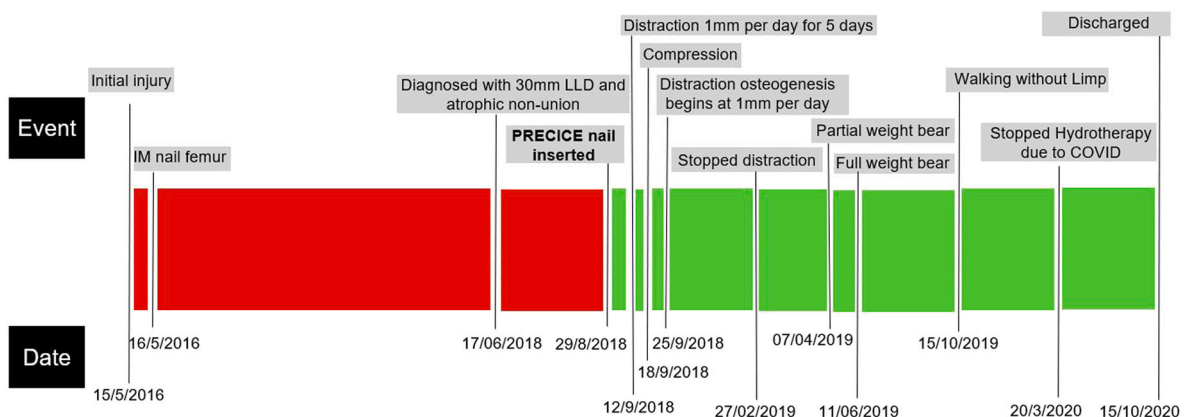


Fig. 2. Timeline of events.

Table 1
Demographical and clinical outcome measures.

Age at injury	58
Sex	Male
BMI	21.9
Initial LLD	81 mm
Final LLD	0 mm
Injury cause	Motorcycle accident
Type of initial surgery	ORIF
Complications in initial surgery	Non-union, distal screws broken
Time from injury to PRECICE nail insertion	119.4 weeks
Time from distraction osteogenesis to PWB	27.7 weeks
Time from distraction osteogenesis to FWB	37 weeks
Time from distraction osteogenesis to bone union	44.7 weeks
Number of days spent lengthening	155 days
^a Consolidation index	0.63 months/cm
Smoking status	Ex-smoker
^b Follow-up time	232 weeks
^c Total cost	£27,601

^a Consolidation index is defined as time from the start of distraction osteogenesis to the appearance of consolidation in at least three cortices on lateral and anteroposterior radiographs, divided by total lengthening.

^b Follow-up is 232 weeks as of December 6th 2021.

^c Calculated by the sum of all expenditures made to the hospital by the payer.

Table 2
Patient-reported outcome measures.

Euroqol	
Health Index (0–1.000)	0.767
VAS Score (0–100)	65
SF-36 (0–100)	
Physical functioning	75
Role limitation: physical	0
Bodily pain	67.5
General health	25
Vitality	40
Social functioning	37.5
Role limitation: emotional	0
Mental health	44
Oxford hip score (0–48)	37
Oxford knee score (0–48)	35
Oxford knee score activity participation questionnaire (0–100)	56

four weeks did limb lengthening begin. Bone graft was used since it acts both as an osteoconductive matrix and contains osteoinductive mitogens, which provide a favourable environment for new bone growth and directly stimulate the mitogenesis of precursor cells. The iliac crest is a common location for bone graft harvesting, however the proximal tibia (PT) is a popular alternative. The authors chose the latter since evidence suggests that there is no significant difference in the volume of cancellous bone available for harvest between the PT and iliac crest [11]. Furthermore, utilising the PT as a harvest site causes fewer complications such as pain, primary haemorrhage, and surgical site infection [12,13].

The patient managed to fully weight bear 259 days after distraction osteogenesis began. This was slightly longer than expected, perhaps due to an increase in his smoking and drinking habits and an overall unhealthier lifestyle. Smoking and alcohol are known to affect the dynamics of bone and wound healing, with nicotine decreasing the strength of fracture repair in distraction osteogenesis [14] and alcohol having a dose-dependent toxic effect on osteoblast activity [15]. Nutritional and metabolic requirements increase during fracture healing, and a poor diet can stymie callus formation and fracture healing [16].

Successful usage of the PRECICE nail with low complication rates have been reported in the literature. Laubscher et al. compared complication rates between the monorail external fixator and PRECICE intramedullary nails, and found that PRECICE nails had fewer complications and patient-reported scarring [17]. Bakarar et al. also reported a lower percentage and severity of complications with PRECICE nails compared to older nail generations and external fixators [18]. Shabtaï et al. reported on the successful treatment of congenital limb deficiency with PRECICE nails with minimal complications [19]. Nevertheless, some retrospective studies have reported complications such as non-union necessitating revision surgery [20], mechanical failure [21], and nail breakage [22], one of which occurred 15 months after implantation [23]. Tiefenböck et al. reported a complication rate of 70%, nevertheless, 30% of complications were reported in patients with a congenital deformity [24]. Complications associated with patients that have congenital malformations may have been a confounding factor, especially if lengthening is attempted in the tibia with an open growth plate [19].

Simultaneous management of post-traumatic femoral non-union with bone defects is challenging, but was well received by patients

using the second-generation self-lengthening, magnetically-driven PRECICE nail. By initially distracting the bone defect by ~5 mm, then compressing the gap, before distraction started, strain on bone graft cells was minimised, allowing robust callus and regenerate growth. From our experience, the PRECICE nail is a viable alternative for limb lengthening. Since the literature only contains small-scale retrospective observational studies on this topic with varying complication rates, future studies could focus on large-scale clinical trials with long follow-up times, to identify late complications related to the hardware itself and investigate the long-term effects on patient recovery and rehabilitation.

Funding

This research did not receive any specific grant from funding agencies in the public, commercial, or not-for-profit sectors.

Ethics approval

This study was approved by the clinical ethics department (PRN9742).

Consent to participate

All included patients consented to participate in this study.

Consent to publication

All authors have reviewed the final version and have consented to publication.

Availability of data and material

The authors confirm that the data supporting the findings of this study are available within the article and/or upon request.

Declaration of competing interest

The authors have no conflicts of interest to declare that are relevant to the content of this article.

Acknowledgements

No services of an external publishing agency were used.

References

- [1] R.W. Hood, E.J. Riseborough, Lengthening of the lower extremity by the Wagner method. A review of the Boston Children's Hospital experience, *J. Bone Joint Surg. Am.* 63 (7) (1981 Sep) 1122–1131.
- [2] S.M. Perren, Evolution of the internal fixation of long bone fractures. The scientific basis of biological internal fixation: choosing a new balance between stability and biology, *J. Bone Joint Surg. Br.* 84 (8) (2002 Nov) 1093–1110, <https://doi.org/10.1302/0301-620x.84b8.13752>.
- [3] A. Barakat, W.H.K. Schilling, S. Sharma, E. Guryel, R. Freeman, Chronic osteomyelitis: a review on current concepts and trends in treatment, *Orthop. Trauma* 33 (3) (2019 April) 181–187, <https://doi.org/10.1016/j.mporth.2019.03.005>.
- [4] V. Lu, J. Zhang, A. Zhou, M. Krkovic, Management of post-traumatic femoral defects with a monorail external fixator over an intramedullary nail [published online ahead of print, 2021 Aug 6], *Eur J Orthop Surg Traumatol.* (2021) 1–8, <https://doi.org/10.1007/s00590-021-03082-1>.
- [5] C. Iacobellis, A. Berizzi, R. Aldegheri, Bone transport using the ilizarov method: a review of complications in 100 consecutive cases, *Strateg. Trauma Limb Reconstr.* 5 (1) (2010 Apr) 17–22, <https://doi.org/10.1007/s11751-010-0085-9>.
- [6] D. Giotikas, N. Tarazi, L. Spalding, M. Nabergoj, M. Krkovic, Results of the induced membrane technique in the Management of Traumatic Bone Loss in the lower limb: a cohort study, *J. Orthop. Trauma* 33 (3) (2019 Mar) 131–136, <https://doi.org/10.1097/BOT.0000000000001384>.
- [7] P. Wagner, R.D. Burghardt, S.A. Green, S.C. Specht, S.C. Standard, J.E. Herzenberg, PRECICE® magnetically-driven, telescopic, intramedullary lengthening nail: pre-clinical testing and first 30 patients, *SICOT J.* 3 (2017) 19, <https://doi.org/10.1051/sicotj/2016048>.
- [8] A.I. Hammouda, V.L. Szymczuk, M.G. Gesheff, N.S. Mohamed, J.D. Conway, S.C. Standard, P.K. McClure, J.E. Herzenberg, Acute deformity correction and lengthening using the PRECICE magnetic intramedullary lengthening nail, *J. Limb Lengthen Reconstr.* 6 (2020) 20–27.
- [9] V.C. Panagiotopoulou, K. Davda, H.S. Hothi, J. Henckel, A. Cerquiglini, W.D. Goodier, J. Skinner, A. Hart, P.R. Calder, A retrieval analysis of the precise intramedullary limb lengthening system, *Bone Joint Res.* 7 (7) (2018 Aug 4) 476–484, <https://doi.org/10.1302/2046-3758.77.BJR-2017-0359.R1>.
- [10] S. Halvachizadeh, H.C. Pape, Perren's strain theory and fracture healing, in: B. Crist, J. Borrelli Jr., E. Harvey (Eds.), *Essential Biomechanics for Orthopedic Trauma*, Springer, Cham, 2020, https://doi.org/10.1007/978-3-030-36990-3_2.
- [11] C. Mauffrey, M. Madsen, R.J. Bowles, D. Seligson, Bone graft harvest site options in orthopaedic trauma: a prospective in vivo quantification study, *Injury* 43 (3) (2012) 323–326, <https://doi.org/10.1016/j.injury.2011.08.029>.
- [12] O.N. Salawu, O.M. Babalola, B.A. Ahmed, G.H. Ibraheem, D.M. Kadir, Comparative study of proximal tibia and iliac crest bone graft donor sites in treatment of orthopaedic pathologies, *Malays Orthop. J.* 11 (2) (2017) 15–19, <https://doi.org/10.5704/MOJ.1707.011>.
- [13] Y.C. Huang, C.Y. Chen, K.C. Lin, et al., Comparing morbidities of bone graft harvesting from the anterior iliac crest and proximal tibia: a retrospective study, *J. Orthop. Surg. Res.* 13 (1) (2018) 115, <https://doi.org/10.1186/s13018-018-0820-3>. Published 2018 May 16.
- [14] S.M. Raikin, J.C. Landsman, V.A. Alexander, M.I. Froimson, N.A. Plaxton, Effect of nicotine on the rate and strength of long bone fracture healing, *Clin. Orthop. Relat. Res.* 353 (1998) 231–237, <https://doi.org/10.1097/00003086-199808000-00027>.
- [15] D.A. Chakkalakal, Alcohol-induced bone loss and deficient bone repair, *Alcohol. Clin. Exp. Res.* 29 (12) (2005) 2077–2090, <https://doi.org/10.1097/01.alc.0000192039.21305.55>.

- [16] A. Karpouzou, E. Diamantis, P. Farmaki, S. Savvanis, T. Troupis, Nutritional aspects of bone health and fracture healing, *J. Osteoporos.* 2017 (2017) 4218472, <https://doi.org/10.1155/2017/4218472>.
- [17] M. Laubscher, C. Mitchell, A. Timms, D. Goodier, P. Calder, Outcomes following femoral lengthening: An initial comparison of the Precice intramedullary lengthening nail and the LRS external fixator monorail system, *The Bone & Joint Journal* 98-B (10) (2016) 1382–1388, <https://doi.org/10.1302/0301-620x.98b10.36643>. Oct.
- [18] A.H. Barakat, J. Sayani, C. O'Dowd-Booth, E. Guryel, Lengthening nails for distraction osteogenesis: a review of current practice and presentation of extended indications, *Strateg. Trauma Limb Reconstr.* 15 (1) (2020) 54–61, <https://doi.org/10.5005/jp-journals-10080-1451>. Jan-Apr.
- [19] L. Shabtai, S.C. Specht, S.C. Standard, J.E. Herzenberg, Internal lengthening device for congenital femoral deficiency and fibular hemimelia, *Clin. Orthop. Relat. Res.* 472 (12) (2014) 3860–3868, <https://doi.org/10.1007/s11999-014-3572-3>.
- [20] T. Haider, G.E. Wozasek, Repeated intramedullary stabilization following failed telescopic nail lengthening - an appropriate treatment strategy, *Injury* 50 (11) (2019) 2060–2064, <https://doi.org/10.1016/j.injury.2019.09.017>.
- [21] W. Wu, K.M. Kuhn, Mechanical failure of a femoral lengthening nail: a case report, *Patient Saf Surg.* 12 (2018) 7, <https://doi.org/10.1186/s13037-018-0154-4>. Published 2018 May 3.
- [22] C. Rentenberger, T. Haider, L. Zak, G.E. Wozasek, Implant failure after externally magnetic-controlled nail lengthening, *Injury* 52 (11) (2021) 3350–3354, <https://doi.org/10.1016/j.injury.2021.09.006>.
- [23] T.M. Tiefenböck, G.E. Wozasek, Unusual complication with an intramedullary lengthening device 15 months after implantation, *Injury* 46 (10) (2015) 2069–2072, <https://doi.org/10.1016/j.injury.2015.07.033>.
- [24] T.M. Tiefenboeck, L. Zak, A. Bukaty, G.E. Wozasek, Pitfalls in automatic limb lengthening - first results with an intramedullary lengthening device, *Orthop. Traumatol. Surg. Res.* 102 (7) (2016) 851–855, <https://doi.org/10.1016/j.otsr.2016.07.004>.