

Incidence, cumulative mortality and factors affecting the outcome of COVID-19-associated mucormycosis from Western India

Archana Ajay Vare, Snehalata Yellambkar, Asma Farheen, Varsha Nandedkar, Swati S Bhombe, Rachana Shah

Purpose: To report the incidence, cumulative mortality, and factors influencing the outcomes from a large series of COVID-19-associated mucormycosis (CAM) from western India. **Methods:** Consecutive patients with CAM between March 1 and May 10, 2021, with a minimum follow-up of 1 month were included. We recorded the presence of diabetes, use of steroids, and need for non-invasive ventilation (NIV) from the case files. The features of orbital involvement, treatment administered, and outcomes, i.e., death, orbital exenteration, or recovery were noted. Cumulative probability of adverse outcomes, defined as either death or exenteration, was reported using survival analysis. **Results:** We treated 67 cases of CAM and found an incidence of 13.6 cases per 1,000 patients post-moderate to severe COVID-19. Uncontrolled diabetes (90%) with ketoacidosis (40%) and prior systemic steroids (84%) were the strongest predispositions. The onset of CAM was 15.1 ± 9.5 days (range: 6–42 days) after recovery from COVID-19. The cumulative probability of an adverse outcome was 38% (95% confidence intervals [CI] = 23.7–56.9%) on day 20. The patients who required NIV during COVID-19 were at seven times higher risk of experiencing an adverse outcome (hazard ratios [HR] = 6.92, 95% CI = 2.9–16.2) while those who received amphotericin-B had a 61% lower risk (HR = 0.39, 95% CI = 0.16–0.97). **Conclusion:** The current outbreak of CAM was seen predominantly in uncontrolled diabetics, especially with ketoacidosis and steroid intake. The cumulative probability of death or orbital exenteration was 38% at day 20 of the infection and those who required NIV and did not receive amphotericin-B were at a high risk of these outcomes.

Key words: COVID-19-associated mucormycosis (CAM), diabetes mellitus, steroids

The COVID-19 pandemic has led to devastation across the world with multiple waves of infections over the past year. In addition to the viral infection itself, there has been an increase in the number of opportunistic infections in patients with COVID-19, fungal infections being common among these, involving different parts of the body.^[1-7] Recently, we have seen a sudden increase in the number of COVID-19-associated rhino-orbitocerebral mucormycosis (CAM) cases,^[8,9] with more than 2,500 cases reported in the literature over the past few months alone.^[1,8-19] The largest series reported recently consisted of 2,826 cases from India,^[19] indicating that it is a huge public health problem already.

Since mucormycosis is known to occur predominantly in diabetics with poor glycemic control, the sudden increase in its incidence has been attributed to the indiscriminate use of systemic steroids, especially in diabetic patients. The recently published study by Sen *et al.*^[19] clearly showed this to be true. However, with the rising numbers, there is fear that mucor may infect even those without these risk factors during the post-COVID-19 recovery phase. Though some recently published studies report outcomes in CAM,^[20,21] none of them used survival analysis to report mortality or morbidity. To the best of our knowledge, there are no studies addressing the cumulative mortality rates and factors predicting mortality in this cohort

Department of Ophthalmology, Government Medical College, Aurangabad, Maharashtra, India

Correspondence to: Dr. Archana Vare, Associate Professor, Department of Ophthalmology, Government Medical College, Aurangabad, Maharashtra, India. E-mail: archana_vare@rediffmail.com

Received: 01-Jul-2021

Revision: 21-Aug-2021

Accepted: 08-Sep-2021

Published: 26-Nov-2021

using appropriate statistical tools. Additionally, despite the large collaborative series recently published by pooling cases from across India,^[19] we believe that the outcomes from a single multidisciplinary center still carry merit in terms of more thorough documentation of the disease stage and uniformity of the treatment protocols followed.

Ours is a tertiary care multispecialty government hospital in the western state of Maharashtra which is the hardest-hit state in India with more than 6 million cases so far. Our hospital has catered to >50,000 patients with moderate to severe COVID-19 infections over the past year. We have observed an outbreak of CAM over the past 2 months and report the underlying predispositions and morbidity and mortality outcomes from a cohort of 67 patients with CAM from western India.

Methods

This was a retrospective study and was approved by the local institutional ethics committee of a large government hospital in western India. Informed consent was taken from all patients at the time of admission and the study followed the tenets of the

This is an open access journal, and articles are distributed under the terms of the Creative Commons Attribution-NonCommercial-ShareAlike 4.0 License, which allows others to remix, tweak, and build upon the work non-commercially, as long as appropriate credit is given and the new creations are licensed under the identical terms.

For reprints contact: WKHLRPMedknow_reprints@wolterskluwer.com

Cite this article as: Vare AA, Yellambkar S, Farheen A, Nandedkar V, Bhombe SS, Shah R. Incidence, cumulative mortality and factors affecting the outcome of COVID-19-associated mucormycosis from Western India. Indian J Ophthalmol 2021;69:3678-83.

Access this article online

Website:

www.ijo.in

DOI:

10.4103/ijo.IJO_1767_21

Quick Response Code:



Declaration of Helsinki. Case records of all the patients with a diagnosis of COVID-19 in the past and having a diagnosis of CAM between March 1 and May 10, 2021, were identified from the medical records department of our hospital and those with a minimum follow-up of 30 days were included in this study. The patients were classified into proven CAM, probable CAM, and possible CAM based on standardized criteria published before.^[22] In summary, all the patients with suspected CAM based on typical clinical features [Fig. 1] of orbital cellulitis and/or black eschar on the hard palate, face or nose, underwent a deep nasal swab that was used to prepare a Potassium Hydroxide (KOH) mount to identify the fungus.

Additionally, material from the swab or specimen obtained during nasal endoscopy was used to culture the fungus using Sabouraud's dextrose agar. A computerized tomography (CT) scan or magnetic resonance imaging (MRI) scan was also ordered for all the patients to confirm pansinusitis, orbital and cranial involvement. Additionally, all the patients underwent routine blood workup including fasting blood sugar levels, complete blood counts, C-reactive protein levels, and serum ferritin levels at the time of admission for CAM.

In addition to the basic demographics such as age and gender, we recorded the following information from the case files: the presence of diabetes, the duration of diabetes, the treatment being taken for diabetes (insulin vs. no insulin), and the patient's fasting blood sugar at the time of admission for CAM. In those with a fasting sugar of ≥ 150 mg/dL without a previous history of diabetes, a diagnosis of diabetes was recorded. Similarly, a diagnosis of diabetic ketoacidosis was entered when ketones were found in the blood or urine.

The time interval (in days) between COVID-19 recovery (defined as discharge from hospital or at least 14 days after having a Polymerase Chain Reaction [PCR] confirmed diagnosis of COVID-19) and the onset of CAM was recorded in days. A history of the treatment received for the past COVID-19 infection was retrieved from the case records including a history of steroid usage, the route of administration, and the type of steroid used. The history of requiring supplemental oxygen as well as non-invasive ventilation (NIV) and ventilatory support and history of use of remdesivir were all recorded.

The ophthalmic manifestations at the time of admission of CAM were recorded including presenting visual acuity, i.e., whether perceiving light or not, presence of complete ptosis, total ophthalmoplegia, proptosis, presence of a relative afferent pupillary defect (RAPD), and presence of a black eschar on the face, nostrils, palate, or lids. All the patients were advised endoscopic sinus debridement with lavage using liposomal amphotericin-B. The patients were administered intravenous lyophilized amphotericin-B when it was available in the wards. Orbital exenteration was planned for patients with advanced orbital disease characterized by no perception of light, complete ptosis, and total ophthalmoplegia but was subject to anesthetic fitness for general anesthesia.^[22] The outcome was recorded as follows: death, exenteration, or recovery, either completely recovered (i.e., no disease clinically or on imaging), or recovering and under follow-up.

Statistical analysis

All continuous variables were presented as mean with standard deviation or median with interquartile range (IQR) and group differences were analyzed using the Student's *t*-test or the Wilcoxon rank-sum test for non-parametric distributions. Similarly, categorical variables were presented as proportions (*n*, %) and group differences were analyzed using the Chi-square or Fisher's exact tests.

In view of the relatively small number of events, we combined death and orbital exenteration into one adverse outcome for this analysis. The survival analysis was performed using adverse outcome as the censoring variable and Kaplan-Meier (K-M) curves were plotted to depict the cumulative probability of survival at various time points. The time for adverse outcome was defined as the interval between the time of admission for CAM and either death or orbital exenteration. The survival probability for an adverse outcome was assessed using the Cox Proportional Hazards Models and displayed using HR with 95% CI. The potential covariates used for adjusting HR were those with a *P* < 0.05 in univariate models and those that have been shown to influence failure rates in the previous studies. A best-fit multivariable model was identified using the sensitivity analysis and Akaike's information criteria

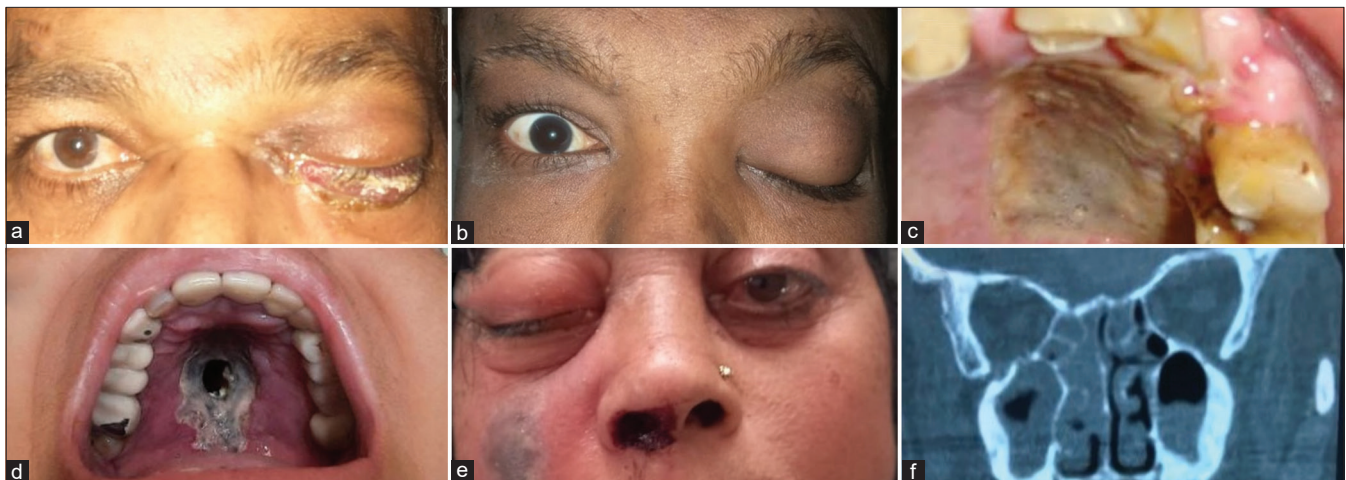

Figure 1: Clinical features of patients with mucormycosis showing orbital cellulitis with a total ophthalmoplegia (a) and complete ptosis (b), black eschar on the hard palate (c and d), nasal eschar (e), and pansinusitis on CT scan (f)

(AIC) after eliminating variance inflation and significant interaction between covariates.

All data were entered in Microsoft Excel and analyzed using STATA 12.1 I/c (Stata Corp, Fort Worth, TX, USA) and all *P*-values <0.05 were considered statistically significant.

Results

Our hospital admitted 4,910 patients with moderate to severe COVID-19 during the study period and saw 67 patients with CAM, leading to an incidence of 13.6 cases per 1,000 patients with moderate to severe COVID-19. Of these, 28 (42%) were proven cases of CAM, 5 (7%) were probable CAM, and the remaining 34 (51%) were possible CAM.

The mean age of the patients with CAM was 54.8 ± 9.4 years and 40 (60%) were men. Only one patient had bilateral disease. Table 1 shows a summary of all baseline characteristics, underlying predisposing factors, details of prior COVID-19 treatment, and characteristics of their ophthalmic presentation. A majority of the patients were diabetic ($n = 60$, 90%) with nine among these being diagnosed with diabetes at the time of presentation with CAM. The fasting blood sugar was markedly elevated and more than a third of the patients had coexistent diabetic ketoacidosis. The CAM developed approximately 15 days after COVID-19 recovery (median

= 14 days, Inter Quartile Range (IQR) = 8–20 days, range = 6–42 days), though eight patients continued to be admitted for severe COVID-19 management at the time of the onset of CAM. A large majority of the patients had received steroids for COVID-19 management ($n = 56$, 84%) in some form with a majority having received intravenous methylprednisolone ($n = 41$, 61%) followed by intravenous dexamethasone ($n = 12$, 18%). Prolonged oxygen supplementation was needed by 52 (78%) patients during COVID-19 management of which 18 (27%) needed NIV or mechanical ventilatory support. All patients, except one (1.5%), had some underlying predisposition in the form of uncontrolled diabetes with or without ketoacidosis or steroid administration and prolonged oxygen administration. The one exception was a 63-year-old gentleman who was not diabetic, did not have any underlying predispositions, and had not even received any oxygen, but developed CAM 40 days after recovery from COVID-19.

All patients had orbital involvement and three patients (5%) had an intracranial extension at the time of presentation to the Ophthalmology Department. Pansinusitis was the commonest involvement ($n = 60$, 90%) followed by maxillary ($n = 4$, 6%) and ethmoidal ($n = 3$, 4%) involvement. Of the 67 patients with CAM, 26 (39%) experienced an adverse outcome, with 23 (34%) having died and 3 (4%) underwent orbital exenteration. None of those who had exenteration died. Of those with

Table 1: Comparison of demographics and clinical characteristics between patients who had an adverse outcome (either death or exenteration) vs. those who did not

Variable	Overall (<i>n</i> = 67)	No adverse outcome (<i>n</i> = 41)	Adverse outcome (<i>n</i> = 26)	<i>P</i>
Age	54.8 ± 9.4	54.1 ± 9.4	55.8 ± 9.7	0.48
Gender (% Men)	40 (60%)	27 (66%)	13 (50%)	0.19
Diabetes	60 (90%)	35 (85%)	25 (96%)	0.16
% on Insulin	30 (45%)	15 (37%)	15 (58%)	0.06
DM duration (months)	33.8 ± 44	32 ± 45.9*	36 ± 43	0.79
Ketoacidosis with CAM	27 (40%)	14 (32%)	14 (54%)	0.03
FBS at the time of CAM	279 ± 123	257 ± 132	312 ± 101	0.04
Time since COVID-19**	15.1 ± 9.5	17.5 ± 9.0	11.2 ± 9.2	0.004
Proven CAM	27 (40%)	19 (46%)	8 (31%)	0.43
Antifungal administered	30 (45%)	22 (54%)	8 (31%)	0.06
Blood workup				
Neutrophil count (%)	76 ± 9	75 ± 9	78 ± 10	0.39
C-reactive protein	88 ± 49	84 ± 52	93 ± 46	0.63
Serum ferritin	683 ± 522	636 ± 538	735 ± 526	0.57
COVID-19 Treatment				
Steroids	56 (84%)	32 (81%)	23 (89%)	0.18
Remdesivir	27 (40%)	16 (39%)	11 (42%)	0.78
Assisted ventilation [#]	18 (27%)	3 (7%)	15 (58%)	<0.001
Ophthalmic presentation				
Vision (% with no PL)	24 (36%)	11 (27%)	13 (50%)	0.05
Complete ptosis	40 (60%)	21 (51%)	19 (73%)	0.07
Proptosis	48 (72%)	25 (61%)	23 (88%)	0.02
RAPD	30 (45%)	15 (37%)	15 (58%)	0.09
Total Ophthalmoplegia	38 (57%)	19 (46%)	19 (73%)	0.03

* Excludes nine freshly diagnosed diabetics, **Calculated for those ($n = 59$) who did develop CAM post-COVID-19 recovery, [#]Includes NIV (Non-invasive ventilation and ventilator support), CAM= COVID-19-associated mucormycosis, PL= Perception of light, RAPD= Relative afferent pupillary defect

exenteration, two had an intracranial extension at presentation. Of the remaining 41 patients, 37 had completely recovered while 2 were recovering and still under follow-up with a mean follow-up time of 35 ± 2.7 days. Using survival estimates, the cumulative probability of an adverse outcome [Fig. 2] occurring was 9% (95% CI = 4.1–19%) at day 2 and increased to 24% on day 8 (95% CI = 15.7–36.8%) and 38% on day 20 (95% CI = 27.3–51.6%). A majority of those with adverse outcomes ($n = 16/26, 62\%$) occurred on or before day 8 of presentation [Fig. 3].

The patients who had adverse outcomes were all diabetic and nearly two-thirds had coexistent ketoacidosis. Also, a significantly higher proportion of those in this group received assisted ventilation in the form of NIV or ventilator support during their previous COVID-19 management. Lastly, this group with adverse outcomes presented with much worse disease [Table 1] in the form of worse vision, i.e., higher proportion with no perception of light, complete ptosis, proptosis, and total ophthalmoplegia. A multivariable Cox’s proportional hazards analysis [Table 2] with a best-fit model showed that a history of receiving assisted ventilation led to a nearly seven-fold increased risk of having an adverse outcome ($P = 0.009$). In the same model, the patients who received amphotericin-B had a 61% reduced risk ($P = 0.043$) of an adverse outcome.

Discussion

In this retrospective study involving 67 patients with CAM over a short period, we found that almost all patients had an underlying predisposing factor for opportunistic infections. Uncontrolled diabetes was the most consistent with an alarmingly high rate of ketoacidosis (40%) among those infected. The prior use of systemic steroids and the need for supplemental oxygen were the other strong predispositions seen. We also found that, though CAM predominantly affects patients recovering from COVID-19, it can also infect those with an active viral infection, albeit with comorbidities such as uncontrolled diabetes. On average, the onset of CAM was about 15 days after recovery from the COVID-19 infection, though it could start as late as 40–42 days after recovery. The cumulative probability of mortality or exenteration was 24%

at 8 days after CAM onset and increased to 38% at day 20. The patients who had required non-invasive oxygen support or ventilator support during their COVID-19 illness were at a significantly higher risk of death or orbital exenteration while those with less severe orbital involvement, evidenced by the presence of light perception had a lower risk of mortality. Systemic antifungals also appeared to reduce mortality significantly.

We found an incidence of 13.6 cases per 1,000 patients with moderate to severe COVID-19 infection in our setting. Given that India has seen 10+ million fresh cases of COVID-19 over the past few months (the second wave) of which about 15–20% may have moderate to a severe disease requiring oxygen supplementation and steroid use and given that the prevalence of diabetes in India ranges from 15 to 20% of the population, there is a likelihood of a very large number of mucormycosis cases occurring making this a public health emergency. Though it has been postulated before,^[19] we now have clear evidence of uncontrolled diabetes, especially with ketoacidosis being at a higher risk of CAM. Since steroid use is life-saving, and hence, inevitable during COVID-19 management itself. It is imperative that the blood sugar is closely monitored in diabetics and be controlled with all possible measures and steroids be tapered as early as possible in this high-risk group.

The use of prolonged oxygen has been postulated to be a risk factor for CAM, however, 22% of the cases did not receive any supplemental oxygen suggesting that uncontrolled diabetes and the hyperglycemic influence of steroids may be more important risk factors of CAM than contaminated oxygen supplies. Similar results were reported by Sen *et al.*^[19] who also did not implicate contaminated oxygen as a causative factor. However, the previous need for NIV and ventilatory support was the strongest mortality indicator. We suspect that this is an indication of the more severe nature of the prior COVID-19 infection with poor systemic status and higher levels of immune compromise in this subgroup. Yet oxygen contamination cannot be ruled out, especially in times of acute shortage and procurement from unreliable sources, therefore, protocols must be in place to supply clean oxygen to all patients with COVID-19.

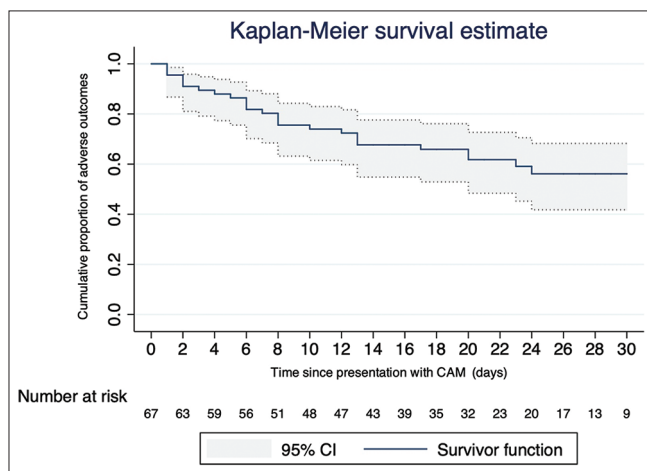


Figure 2: Kaplan–Meier survival estimates of cumulative probability of adverse outcomes at various time points during the first 20 days are the onset of COVID-19-associated mucormycosis

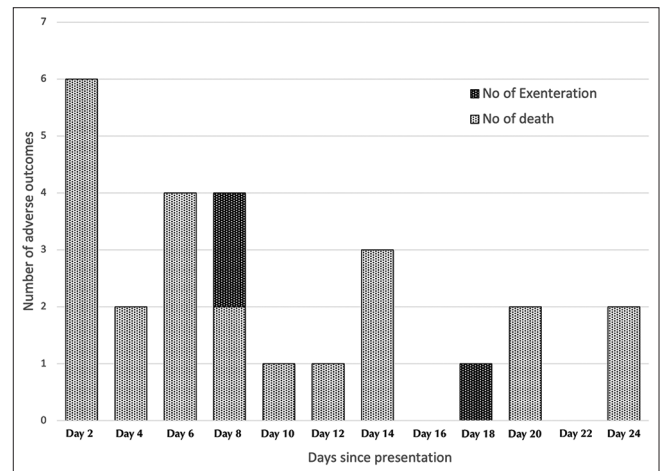


Figure 3: Distribution of cases with mortality and orbital exenteration at various time points after admission for COVID-19-associated mucormycosis

Table 2: Factors associated with adverse outcome of either death or exenteration

Variable	Interval	Univariate analysis		Multivariable analysis	
		HR	95% CI	HR	95% CI
Age	1 year increment	0.99	0.94-1.1	--	--
Gender	vs. Men	0.78	0.29-2.1	--	--
Diabetes duration	1 month increment	1.0	0.9-1.1	--	--
Ketoacidosis	vs. no ketoacidosis	2.54	0.98-6.5	--	--
Time since COVID-19 recovery	1 day increment	0.96	0.91-1.1	--	--
Need for O ₂ as NIV	vs. no NIV	4.64**	1.79-12.1	6.92**	2.9-16.2
Steroid use	vs. no steroid use	1.14	0.67-1.94	--	--
Antifungal use	vs. not used	0.31*	0.09-0.83	0.39*	0.16-0.97
Vision: No PL status	vs. PL status	0.16*	0.05-0.51	0.62	0.28-1.37
RAPD [#]	vs. no RAPD	2.75*	1.2-9.6	--	--
Proptosis	vs. no proptosis	8.68*	1.2-65.1	--	--
Total ophthalmoplegia [#]	vs. partial plegia	6.55**	1.4-27.5	--	--
Complete ptosis [#]	vs. incomplete ptosis	6.46**	1.5-28.1	--	--

** $P < 0.001$, * $P < 0.05$, NIV (Non-invasive ventilation and ventilator support), PL= Perception of light, RAPD= Relative afferent pupillary defect, [#]Not taken to multivariable models in view of variance inflation and high interaction with vision

We report a relatively low incidence of orbital exenteration and this may be due to very poor systemic status in most cases, including ketoacidosis and post-COVID-19 poor health making them unfit for general anesthesia. However, Ravani *et al.*,^[9] in a recent study of 31 cases of CAM, also reported low rates of orbital exenteration, done in only 4 eyes out of 31 with CAM in their series while Sen *et al.*,^[19] from the largest series, report 17% exenterations. Dave *et al.*^[20] report higher exenteration in 38% of the cases, however, the severity of CAM appears to be worse in their series with 33% having CNS involvement as opposed to only 5% in our series. We also report one case of bilateral and sequential CAM as part of this series, a rare occurrence, and this patient died on day 4 of admission. Surprisingly, we found one (1.5%) patient without any identifiable predispositions for CAM, and this occurred 40 days after uneventful COVID-19 recovery. Though the cause is as yet undefined, it may be very important to observe closely for more such occurrences, which may indicate as yet unexplained virus–host interactions leading to tissue necrosis in the nose and paranasal sinuses. Our rate of adverse outcome was also very similar to that reported by Dave *et al.*,^[20] who report an unfavorable outcome in a third of their cases, and Sen *et al.*,^[19] where 31% of the patients underwent either exenteration or died. However, our proportions of deaths are higher, likely due to the worse systemic condition at the presentation of our patients. Lastly, a majority of those who died did so by the 8th day of admission with CAM, making this an important window of opportunity to intervene, especially with systemic lyophilized amphotericin-B which appears to reduce mortality by 61%. The government must do all it can to make this life-saving drug available to all who need it at affordable costs.

The drawbacks of our study are its retrospective nature and the lack of documentation of the duration of steroid use during COVID-19 treatment, though we doubt whether this information would have altered the major findings of this study. The advantages of our study are the relatively large number of cases of this very rare disease, occurring in the form of an outbreak, and allowing us to understand the disease behavior, mortality, and morbidity rates. To the best of our knowledge, this is the first study providing a survival analysis,

cumulative mortality, and hazards ratios for factors predicting death or exenteration in CAM. The mortality indicators we found, i.e., the need for assisted ventilation in the past and the presence of severe orbital manifestations can help physicians triage patients for emergency procedures and administer systemic antifungals when in limited supply.

Conclusion

In conclusion, we report the underlying risk factors, mortality, and significant morbidity outcomes from an outbreak of CAM infections from a multispecialty hospital in India. This is the first study reporting on the cumulative survival rates at 1 month in CAM and should be helpful to a wide variety of physicians who are part of multidisciplinary teams managing this life-threatening fungal infection post-COVID-19 recovery.

Financial support and sponsorship

Nil.

Conflicts of interest

There are no conflicts of interest.

References

- Ahmadikia K, Hashemi SJ, Khodavaisy S, Getso MI, Alijani N, Badali H, *et al.* The double-edged sword of systemic corticosteroid therapy in viral pneumonia: A case report and comparative review of influenza-associated mucormycosis versus COVID-19 associated mucormycosis. *Mycoses* 2021;64:798-808.
- Johnson AK, Ghazarian Z, Cendrowski KD, Persichino JG. Pulmonary aspergillosis and mucormycosis in a patient with COVID-19. *Med Mycol Case Rep* 2021;32:64-7.
- Monte Junior ESD, Santos MELD, Ribeiro IB, Luz GO, Baba ER, Hirsch BS, *et al.* Rare and Fatal Gastrointestinal Mucormycosis (Zygomycosis) in a COVID-19 Patient: A Case Report. *Clin Endosc.* 2020;53:746-9. doi: 10.5946/ce.2020.180. Epub 2020 Nov 19. PMID: 33207116; PMCID: PMC7719411.
- Pasero D, Sanna S, Liperi C, Piredda D, Branca GP, Casadio L, *et al.* A challenging complication following SARS-CoV-2 infection: A case of pulmonary mucormycosis. *Infection* 2020;1-6. doi: 10.1007/s15010-020-01561-x.

5. Bhagali R, Prabhudesai NP, Prabhudesai MN. Post-COVID-19 opportunistic candida retinitis: A case report. *Indian J Ophthalmol* 2021;69:987-9.
6. Shah KK, Venkatramani D, Majumder PD. A case series of presumed fungal endogenous endophthalmitis in post-COVID-19 patients. *Indian J Ophthalmol* 2021;69:1322-5.
7. Song G, Liang G, Liu W. Fungal co-infections associated with global COVID-19 pandemic: A clinical and diagnostic perspective from China. *Mycopathologia* 2020;185:599-606.
8. Sen M, Lahane S, Lahane TP, Parekh R, Honavar SG. Mucor in a viral land: A tale of two pathogens. *Indian J Ophthalmol* 2021;69:244-52.
9. Ravani SA, Agrawal GA, Leuva PA, Modi PH, Amin KD. Rise of the phoenix: Mucormycosis in COVID-19 times. *Indian J Ophthalmol* 2021;69:1563-8.
10. Alekseyev K, Didenko L, Chaudhry B. Rhinocerebral mucormycosis and COVID-19 pneumonia. *J Med Cases* 2021;12:85-9.
11. Garg D, Muthu V, Sehgal IS, Ramachandran R, Kaur H, Bhalla A, *et al.* Coronavirus disease (COVID-19) associated mucormycosis (CAM): Case report and systematic review of literature. *Mycopathologia* 2021;186:289-98.
12. Maini A, Tomar G, Khanna D, Kini Y, Mehta H, Bhagyasree V. Sino-orbital mucormycosis in a COVID-19 patient: A case report. *Int J Surg Case Rep* 2021;82:105957.
13. Mehta S, Pandey A. Rhino-orbital mucormycosis associated with COVID-19. *Cureus* 2020;12:e10726.
14. Mekonnen ZK, Ashraf DC, Jankowski T, Grob SR, Vagefi MR, Kersten RC, *et al.* Acute invasive rhino-orbital mucormycosis in a patient with COVID-19-associated acute respiratory distress syndrome. *Ophthalmic Plast Reconstr Surg* 2021;37:e40-80.
15. Revannavar SM, PS Supriya, Samaga L, VK Vineeth. COVID-19 triggering mucormycosis in a susceptible patient: a new phenomenon in the developing world? *BMJ Case Rep* 2021;14:e241663. doi: 10.1136/bcr-2021-241663. PMID: 33906877; PMCID: PMC8088249.
16. Verma DK, Bali RK. COVID-19 and mucormycosis of the craniofacial skeleton: Causal, contributory or coincidental? *J Maxillofac Oral Surg* 2021;20:1-2.
17. Waizel-Haiat S, Guerrero-Paz JA, Sanchez-Hurtado L, Calleja-Alarcon S, Romero-Gutierrez L. A Case of fatal rhino-orbital mucormycosis associated with new onset diabetic ketoacidosis and COVID-19. *Cureus* 2021;13:e13163.
18. Werthman-Ehrenreich A. Mucormycosis with orbital compartment syndrome in a patient with COVID-19. *Am J Emerg Med* 2021;42:264.e5-8.
19. Sen M, Honavar SG, Bansal R, Sengupta S, Rao R, Kim U, *et al.* Epidemiology, clinical profile, management, and outcome of COVID-19-associated rhino-orbital-cerebral mucormycosis in 2826 patients in India - Collaborative OPAI-IJO study on mucormycosis in COVID-19 (COSMIC), report 1. *Indian J Ophthalmol* 2021;69:1670-92.
20. Dave TV, Gopinathan Nair A, Hegde R, Vithalani N, Desai S, Adulkar N, *et al.* Clinical presentations, management and outcomes of rhino-orbital-cerebral mucormycosis (ROCM) following COVID-19: A multi-centric study. *Ophthalmic Plastic Reconstr Surg* 2021;37:488-95.
21. Nair AG, Adulkar NG, D'Cunha L, Rao PR, Bradoo RA, Bapaye MM, *et al.* Rhino-orbital mucormycosis following COVID-19 in previously non-diabetic, immunocompetent patients. *Orbit* 2021;1-6. doi: 10.1080/01676830.2021.1960382.
22. Honavar SG. Code mucor: Guidelines for the diagnosis, staging and management of rhino-orbito-cerebral mucormycosis in the setting of COVID-19. *Indian J Ophthalmol* 2021;69:1361-5.