

Myiasis (maggots) around nephrostomy tube

Prashant Motiram Mulawkar, Sumit Gopal Agrawal, Utpala Prashant Mulawkar¹,
Girdhar Shivnarayan Panpaliya²

Departments of Urology, ¹Plastic Surgery and ²Anesthesiology, Tirthankar Superspeciality Hospital, Akola, Maharashtra, India

Abstract

Myiasis is caused by the presence of dipterous larvae in humans and animals. It is usually associated with poor hygienic conditions. A urologist rarely comes across myiasis. We report a case of myiasis around a recently placed nephrostomy tube. A 55-year-old male farmer from a rural area underwent right percutaneous nephrolithotomy. The procedure was terminated because of bradycardia and arrhythmia. There were residual calculi. A nephrostomy was kept. His relook nephroscopy was planned, but he was not willing. Hence, he was discharged with an indwelling nephrostomy tube. Two weeks later, he presented with severe pain around the right nephrostomy tube with surrounding pruritus. The wound hygiene was poor. He was found to have maggots around the nephrostomy tube. These were treated by local instillation of turpentine oil and oral and topical ivermectin, followed by manual removal of the maggots.

Keywords: Maggots, myiasis, nephrostomy, percutaneous nephrolithotomy

Address for correspondence: Dr. Prashant Motiram Mulawkar, Department of Urology, Tirthankar Superspeciality Hospital, Gaddam Plots, Akola - 444 005, Maharashtra, India.

E-mail: pmulawkar@hotmail.com

Received: 11.12.2020, **Accepted:** 15.03.2021, **Published:** 02.09.2021

INTRODUCTION

Myiasis is a parasitic disease caused by the presence of dipterous larvae in humans and other vertebrate animals.^[1] It is usually associated with poor socioeconomic status, poor hygienic conditions, rural background, diabetes, psychiatric illness, and homelessness and close contact with cattle. Rarely, a urologist comes across myiasis of the penis, urethra, scrotum, vulva, or vagina.^[1,2] We report a case of myiasis around a recently placed nephrostomy tube. To our best knowledge, this is the first case of myiasis around the nephrostomy tube.

CASE REPORT

A 55-year-old male underwent the first-stage right percutaneous nephrolithotomy (PCNL) for a stag-horn calculus elsewhere. He had large residual calculi. Double-J (DJ) stent and nephrostomy were kept. He was not willing for second-stage PCNL and was discharged after removing the nephrostomy tube with instructions to undergo surgery or get DJ removed. Two months later, he consulted us with a urine leak from the nephrostomy site and a DJ stent *in situ*. There was no renal or perirenal abscess. Urine culture was sterile. He was not willing for re-do PCNL; hence, the DJ stent was removed on request. Six months later, he presented with right abdominal pain. Urine culture was sterile. His plain computed tomography of the kidneys,

Video Available on: www.urologyannals.com

Access this article online

Quick Response Code:



Website:

www.urologyannals.com

DOI:

10.4103/UA.UA_185_20

This is an open access journal, and articles are distributed under the terms of the Creative Commons Attribution-NonCommercial-ShareAlike 4.0 License, which allows others to remix, tweak, and build upon the work non-commercially, as long as appropriate credit is given and the new creations are licensed under the identical terms.

For reprints contact: WKHLRPMedknow_reprints@wolterskluwer.com

How to cite this article: Mulawkar PM, Agrawal SG, Mulawkar UP, Panpaliya GS. Myiasis (maggots) around nephrostomy tube. *Urol Ann* 2021;13:438-41.

ureters, and bladder [Figure 1] showed large calculi in the upper and mid calyces. PCNL was performed under general anesthesia. Multiple tract PCNL was planned. Large upper calyx calculus was targeted first through a supra 12 access through 22 French Amplatz sheath. Majority of the upper calyx stone burden was cleared with pneumatic lithotrite. There were two large residual calyces in the middle and lower calyces. During the procedure, the patient had bradyarrhythmias; hence, the surgery was stopped. A Foley catheter was kept as a nephrostomy [Figure 2]. He was reassessed by a cardiologist and was scheduled for the second sitting of PCNL. However, he was not willing for surgery. He was discharged with the nephrostomy tube *in situ* with the intention of doing a repeat PCNL. Two weeks later, he presented with severe pain and pruritus around the right nephrostomy tube and sensation of something crawling inside the nephrostomy tract. He did not have a fever. He had not taken bath for these days. The nephrostomy site was soiled. There were maggots [Figures 3 and video 1] around the nephrostomy site. The nephrostomy site was irrigated with turpentine oil. Maggots were manually removed. The expertise for genus identification was not available (personal communication, Prof G K Lande, Entomologist). Oral and topical ivermectin was also used. All maggots were cleared in 2 days, nephrostomy was removed. He was instructed about hygienic habits and PCNL was postponed for the time being. Antibiotics were not given.

DISCUSSION

Infestation of human or animal by dipterous larvae (maggots) is known as myiasis. It is a zoonotic disease. Goats and sheep are the definitive hosts. Humans are the accidental hosts.^[3] Among livestock animals, myiasis is the most common parasitic infestation. Myiasis occurs occasionally in humans. Close proximity to domestic animals is an important risk factor.^[2] This patient had a wound myiasis which is usually a facultative or obligatory parasite. It starts with oviposition of the flies in necrotic,

hemorrhaging, or pus-filled lesions.^[4] Myiasis is usually divided into various types according to the organs infested as subdermal, oral, nasal, aural, ocular, enteric, anorectal, and genitourinary.^[2]

Myiasis is common in tropical countries more in regions with poor sanitation and unhygienic conditions are prevalent. The real importance and exact incidence of myiasis in humans is not known. Registration and notification of cases is unnecessary.^[4] Many cases of myiasis do not reach medical attention. Most of the literature consists of individual case reports or short case series. Singh and Singh^[5] have published an extensive review of various reports of myiasis in humans. In this report, the authors have identified 37 fly species belonging to ten families responsible for human myiasis.

Predisposing factors for myiasis are poor hygiene, density of fly population, living standards, poor sanitation, psychiatric, physically, or immunocompromised conditions. Exposed lesion is another important risk factor.^[4] Genital myiasis is usually treated by dermatologists, venereologists and gynecologists. Oviposition to the genital area by flies is uncommon as the genitals are usually covered. Promiscuous sexual behavior, multiple sex partners, intravaginal foreign bodies for sexual gratification, and genital malignancies are the few risk factors for the genital myiasis.^[5] Most of the urological procedures are not contaminated procedures. Except for a rare case of myiasis around the suprapubic catheter,^[6] myiasis around urological drain tubes is rare. Nephrostomy wounds, operative wounds, are usually clean. It is rare for a urologist to come across myiasis.

Our patient had not taken bath with the fear of infection or accidental removal of nephrostomy. He is a farmer and has domestic animals. He did not have any immunocompromising risk factors. Diagnosis of myiasis is usually clinical. Laboratory and imaging studies are unwarranted unless internal myiasis is suspected. Entomologist experts in dipteran classification are rarely

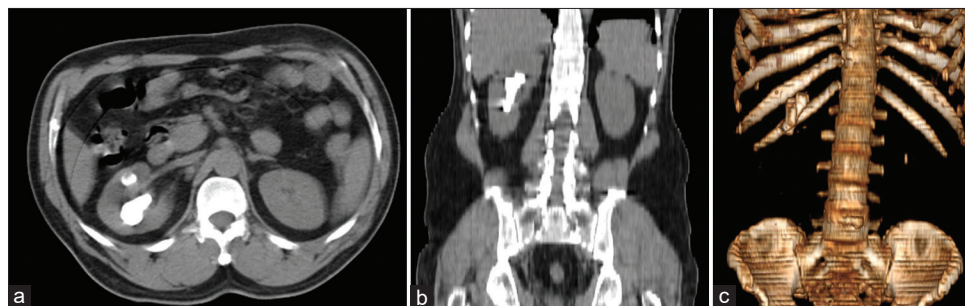


Figure 1: Preoperative computed tomography of the kidneys, ureters, and bladder: (a) Axial, (b) Coronal, and (c) Three-dimensional reconstruction image, showing right renal calculi. There is a small calculus in the left kidney also

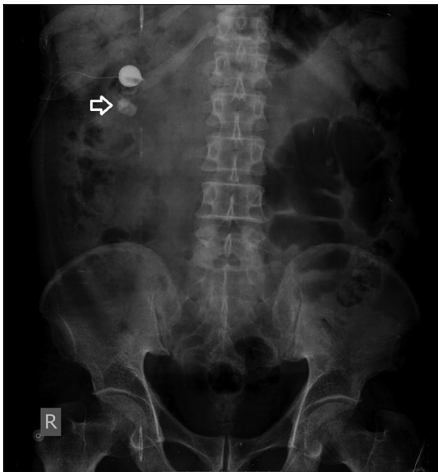

Figure 2: Postpercutaneous nephrolithotomy of the kidneys, ureters, and bladder X-ray showing residual calculi (arrow). There is a contrast in the Foley catheter balloon used as nephrostomy

available.^[4] Prevention involves suppressing or eradicating flies, hygienic practices, regular wound inspection, and fly nets.^[2]

The general principles of treatment comprise three techniques.^[4] First is the application of toxic substance like turpentine oil or hypertonic saline to kill the larvae.^[3] Repeated application is usually required. Lignocaine in 1% concentration is known to paralyze the larva.^[4] Second is to produce local hypoxia. Petroleum jelly is applied locally and the wound is sealed. This blocks the breathing holes. The maggots emerge out to avoid asphyxiation. Third is removal of the maggots. Forceful removal should be avoided. Maggots dig their hook-like structures in the wound and resist removal.^[3] Forceful removal leads to an incomplete removal. Retention of larval fragments may lead to allergic complications,^[2] granulomatous inflammation, and calcification.^[3] Immature maggots usually do not come out easily.^[4] It is advisable to kill the larvae and then remove them. In our patient, all maggots disappeared after three applications.

Ivermectin has been used successfully in myiasis. It causes hyperpolarization of neurons and myocytes of invertebrates leading to inhibition of neurotransmission. It is given orally as well as topically.^[3] Our patient received a single dose of 12 mg of ivermectin. In addition, a 0.24% topical ivermectin was applied as a single application. Singh *et al.*^[7] reported a retrospective study of maggots at various sites. Twenty-seven patients were treated with topical turpentine oil and 80 patients were treated with oral and topical ivermectin. Patients in the ivermectin group had faster recovery and shorter hospital stay. Maggots themselves have antibacterial activity.

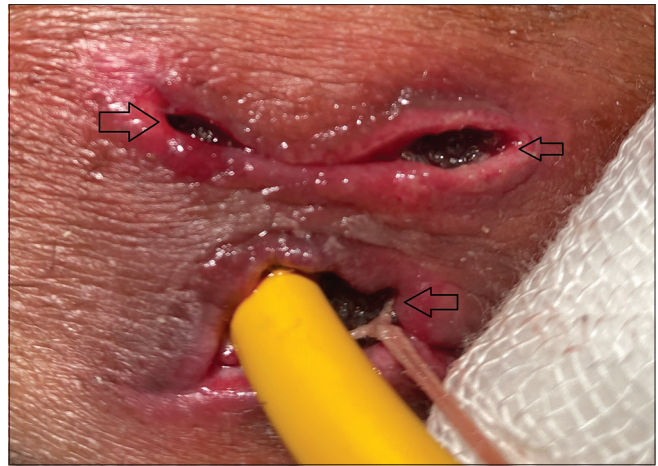


Figure 3: Maggots around the nephrostomy site marked by arrows

Complications of wound myiasis are destruction of local tissues, invasion of deeper tissues, and secondary infection. This is more so with obligatory parasites. Facultative maggots prevent secondary bacterial infections.^[3,4] Hence, systemic antibiotics are usually not required. The use of facultative maggots to treat infection by cleaning the necrotic tissues is known. The maggots themselves have bactericidal action and stimulate granulation.^[4]

Long-term drainage tubes like nephrostomies are common in urological practice. Patients usually avoid taking bath because of fear of contamination of the wound because of water or fear of accidental removal of the drain tube. Sometimes, the dressing may get soiled and may attract flies. Pruritus around tubes is common and can be neglected to be a “normal.” Apprehension about accidental removal of the drain tubes in patient’s mind can be removed with proper patient education about retention methods of the drain tubes. Myiasis should be kept as one of the possible diagnoses in patients with long-term drain tubes and pain, pruritus, or sensation of crawling in the wound.

CONCLUSION

Myiasis is an indicator of poor personal hygiene and poor wound care. We report a rare case of myiasis (maggots) around the nephrostomy tube. Myiasis should be kept as one of the possible diagnoses in patients with long-term drain tubes and sensation of itching or crawling in the wound. The diagnosis is usually evident on inspection. Treatment by local application of turpentine oil and oral and topical ivermectin is usually successful.

Declaration of patient consent

The authors certify that they have obtained all appropriate patient consent forms. In the form the patient (s) has/have

given his/her/their consent for his/her/their images and other clinical information to be reported in the journal. The patients understand that their names and initials will not be published and due efforts will be made to conceal their identity, but anonymity cannot be guaranteed.

Financial support and sponsorship

Nil.

Conflicts of interest

There are no conflicts of interest.

REFERENCES

1. Faridnia R, Soosaraei M, Kalani H, Fakhar M, Jokelainen P, Zolfaghari Emameh R, *et al.* Human urogenital myiasis: A systematic review of reported cases from 1975 to 2017. *Eur J Obstet Gynecol Reprod Biol* 2019;235:57-61.
2. Singh A, Kaur J. Occurrence of human urogenital myiasis due to neglected personal hygiene: A review. *Trans R Soc Trop Med Hyg* 2019;113:4-10.
3. Puthran N, Hegde V, Anupama B, Andrew S. Ivermectin treatment for massive orbital myiasis in an empty socket with concomitant scalp pediculosis. *Indian J Ophthalmol* 2012;60:225-7.
4. Francesconi F, Lupi O. Myiasis. *Clin Microbiol Rev* 2012;25:79-105.
5. Singh A, Singh Z. Incidence of myiasis among humans-A review. *Parasitol Res* 2015;114:3183-99.
6. Aggarwal A, Pandey S, Sharma A, Aeron R. Apprehension in patient's mind: Leading to myiasis. *BMJ Case Rep* 2018;2018:225848.
7. Singh S, Athar M, Chaudhary A, Vyas A, Tiwari S. Effect of ivermectin on wound myiasis-A hospital based study. *Ann Clin Lab Res* 2017;5:200.