



Since January 2020 Elsevier has created a COVID-19 resource centre with free information in English and Mandarin on the novel coronavirus COVID-19. The COVID-19 resource centre is hosted on Elsevier Connect, the company's public news and information website.

Elsevier hereby grants permission to make all its COVID-19-related research that is available on the COVID-19 resource centre - including this research content - immediately available in PubMed Central and other publicly funded repositories, such as the WHO COVID database with rights for unrestricted research re-use and analyses in any form or by any means with acknowledgement of the original source. These permissions are granted for free by Elsevier for as long as the COVID-19 resource centre remains active.



Thrombosis of pulmonary vasculature despite anticoagulation and thrombolysis: The findings from seven autopsies



O. Porembskaya^{a,b,*}, K. Lobastov^{c,d}, O. Pashovkina^e, S. Tsaplin^{c,e}, I. Schastlivtsev^{c,e}, S. Zhuravlev^e, L. Laberko^{c,d}, G. Rodoman^{c,d}, V. Kravchuk^a, A. Skvortsov^a, S. Saiganov^a

^a Mechnikov North-Western State Medical University, Saint Petersburg, Russia

^b Institute of Experimental Medicine, Saint Petersburg, Russia

^c Pirogov Russian National Research Medical University, Moscow, Russia

^d Moscow City Hospital No.24, Moscow, Russia

^e Clinical Hospital No.1 of the President's Administration of Russian Federation, Moscow, Russia

ARTICLE INFO

Keywords:

Autopsy
COVID-19
Deep vein thrombosis
Pulmonary embolism
Pulmonary artery thrombosis
Vascular endothelium

ABSTRACT

Background: Venous thromboembolism (VTE) with the prevalence of pulmonary microcirculatory thrombosis is considered a common complication of novel coronavirus disease (COVID-19) that develops despite anticoagulation.

Methods: The clinical course of the disease and the autopsy findings of seven deceased patients with verified COVID-19 were analyzed. The chest computed tomography (CT) scan was routinely performed while CT pulmonary angiography and a duplex ultrasound scan (DUS) of the lower limbs were used in cases of suspected VTE. The VTE prophylaxis was administered to all patients with intermediate or therapeutic doses of low-molecular-weight heparin. The histological examination of the lung tissue and other organs was performed with particular attention paid to the pulmonary vasculature.

Results: Venous thromboembolism, including deep vein thrombosis in one patient and pulmonary artery thrombosis in two patients, was confirmed by imaging tests despite anticoagulation. Systemic thrombolysis was performed in two patients with putative and confirmed pulmonary embolism. An autopsy revealed the signs of acute respiratory distress syndrome in all seven patients. Abnormalities of lung vessels were found in all cases and were represented by dystrophy and necrosis in the endothelium and muscle fibers, and by infiltration by plasmatic cells, neutrophils, and lymphocytes. Multiple clots of variable maturity were observed. All those changes developed despite anticoagulation and were preserved after systemic thrombolysis.

Conclusion: Inflammatory and prothrombotic changes in the arterial wall in parallel with the lack of lung perfusion may cause diffuse arterial thrombosis in the lungs. This background may be responsible for the low response to systemic anticoagulation and thrombolysis in severe forms of COVID-19.

1. Background

Over six months have passed since the start of the worldwide pandemic with the spread of the SARS-CoV-2 virus, but several questions about the pathogenesis and treatment of the disease remain unresolved. A large amount of data on the thrombotic complications of coronavirus disease (COVID-19) has been collected over time. A specific feature of these data is a high prevalence of thrombosis in the vasculature of the pulmonary artery (PA) prevailing over a deep vein thrombosis (DVT) in lower limbs [1–3]. Such findings were regarded as thromboembolic until

detailed histological findings became available. The results of morphological studies showed that thrombus formation in the branches of the pulmonary artery has the underlying inflammatory abnormalities in the vessel wall caused by the cytotoxic effect of both the virus itself and the activated immune cells [4–6]. Increased D-dimer and other coagulation disturbances that are characteristic of patients with severe COVID-19 allow considering disseminated intravascular coagulation (DIC) as one of the possible causes of thrombosis in the lung vessels and other organs (liver, kidney, pelvic veins)[6–9].

The appearance of venous thromboembolism (VTE) in patients with

* Corresponding author. Cardio-vascular department of the Mechnikov's North-Western State Medical University, 191015, Kirochnaya street, 41, St.Petersburg, Russia.

E-mail address: olgaporembskaya@gmail.com (O. Porembskaya).

<https://doi.org/10.1016/j.tru.2020.100017>

Received 29 August 2020; Received in revised form 1 October 2020; Accepted 15 October 2020

2666-5727/© 2020 The Author(s). Published by Elsevier Ltd. This is an open access article under the CC BY-NC-ND license (<http://creativecommons.org/licenses/by-nc-nd/4.0/>).

COVID-19 is associated with unfavorable outcomes [10]. However, there is no single approach to the prevention of VTE in COVID-19, and the guidelines regarding anticoagulant prophylaxis and therapy vary across societies [11–13]. Thrombotic complications are registered despite the administration of both prophylactic and therapeutic anticoagulation [2, 3]. However, individual studies suggest reduced mortality with therapeutic anticoagulation in patients on mechanical ventilation, although its rates remain high [14].

Considering the fact that thrombosis of lung vessels can deteriorate the respiratory function and general status of the patient, systemic thrombolysis has been suggested to improve treatment outcomes. However, the published data indicate only temporary benefits in blood oxygenation, with no reported long-term results [15,16].

This study aimed to assess histological abnormalities in the pulmonary vasculature in the setting of anticoagulant, thrombolytic, and anti-cytokine therapy in deceased patients with COVID-19.

2. Methods

We analyzed the clinical course of the disease and the autopsy findings of seven patients with COVID-19 who passed away at the Clinical Hospital no.1 of the President's Administration of the Russian Federation and the Moscow City Hospital no.24 (Moscow, Russia). Both clinical centers were reprofiled into an infection hospital during the pandemic. Clinical Hospital no.1 took persons with COVID-19 from April 30 to May 30, 2020; six deceased patients underwent dissection within this period. The routine autopsy was not performed at the Moscow City Hospital no.24, which has been used as an infection hospital from April 20 to August 10, 2020, though one selective dissection was done. The results were included in this analysis.

The patients with increased body temperature and acute respiratory symptoms were admitted to the clinical centers. At admission, all of them underwent a reverse transcription-polymerase chain reaction (PCR) test for the detection of SARS-CoV-2 and chest computed tomography (CT). The chest CT was repeated with the patient's deterioration, and CT pulmonary angiography (CTPA) was used in the case of suspicion of pulmonary embolism (PE). A duplex ultrasound scan (DUS) of the lower limbs was used to exclude deep vein thrombosis (DVT) in case of clinical suspicion or identification of the source of PE.

In accordance with the national guidelines for the management of COVID-19, patients received the following therapy: specific drugs (hydroxychloroquine in combination with azithromycin, lopinavir/ritonavir), antibiotics (vancomycin, meropenem, ceftriaxone), respiratory support, and symptomatic treatment. The VTE prophylaxis was performed with intermediate doses of low-molecular-weight heparin (LMWH, enoxaparin of 40–60 mg twice daily) that were escalated to therapeutic doses (1 mg/kg twice daily) due to putative or confirmed VTE. Systemic thrombolysis for the alleged or confirmed PE was performed by a recombinant tissue plasminogen activator (tPA) dose of 100 mg intravenously over 2 h in two cases.

One deceased patient was selected for a non-routine autopsy. He had been admitted to the intensive care unit with a critical disease and received mechanical ventilation three weeks after the onset of the symptoms when he had not received specific treatment. Despite this, he died 15 h after admission. The reason for this dissection was to specify histological changes in the absence of pharmacological influence.

Dissection was performed using the standard methodology, with the use of protective measures similar to those utilized when caring for patients with COVID-19. The search for potential sources of PE in deep veins of both legs was carried out. Autopsy samples were fixed in formalin. The tissues of the lungs, trachea, bronchi, brain, heart, liver, kidneys, and spleen were examined. The specimens were stained with hematoxylin and eosin. Immunohistological analysis was not performed. The primary objective of the examination was the evaluation of abnormalities and thrombotic processes in the lung vasculature.

No informed consent was necessary from the families. All performed

procedures and investigations were performed in accordance with the ethical standards of the Institutional Reviewal Boards. The study was conducted without any financial support or funding.

3. Findings

3.1. Clinical characteristics of patients

The general demographic data of deceased patients are represented in Table 1. The PCR test confirmed the diagnosis of SARS-CoV-2 infection in five cases. The patients no. 2 and 3 were PCR-negative but had a typical pattern of disease (ground-glass opacities) on the chest CT scan, which allowed confirmation of the diagnosis according to the national guidelines.

The first chest CT scan at admission detected multisegmental viral pneumonia in all patients, with the involvement of at least 70–75% of the lung tissue. A multifold increase in ferritin and lactate dehydrogenase (LDH) levels was typical for the patients (Table 2). The D-dimer increased moderately with higher levels (4.2–21.3 mg/L) in critically ill patients. The other changes in hemostasis could be interpreted as a hypo-coagulation state (Table 3). None of the patients with available parameters of coagulation fulfilled the criteria of DIC by the International Society of Thrombosis and Hemostasis [17]. Thrombocytopenia, with a decrease in platelet count $<150 \times 10^9/L$, was observed in only two out of seven patients. Increased prothrombin time and fibrinogen level were not typical for analyzed patients (Table 3).

The dramatic deterioration of three patients was suggested as PE and required CTPA, which was done in two cases and revealed thrombosis of minor branches of PA (Table 1). The clinical signs of patient no.3 were interpreted as putative PE due to the inability to perform CTPA. The DUS did not confirm any source of pulmonary embolism.

Systemic thrombolysis with tPA was performed in two cases of putative and confirmed PE (patients no.3 and no.6) without any hemorrhagic consequences. The therapy resulted in the time-limited improvement of blood oxygenation and the clinical course of the disease. Patient no.3 increased saturation from 70% to 97% in parallel with the improvement of other blood gases (Table 4) and was excommunicated from a ventilator. However, he returned to non-invasive and invasive ventilation at six days after lysis and died a short time later. Patient no.6 did not show pronounced improvement after thrombolysis. His saturation fluctuated between 77 and 82% (up to 93% with FiO_2 86%) prior to lysis and 86–89% (up to 96% with FiO_2 60%) after it, with a further progressive decrease that required invasive ventilation at day 4 and resulted in death at day 12 after treatment.

3.2. Pathological characteristics of the disease

3.2.1. General characteristics of the morphological abnormalities

A histological examination of the lungs showed a typical COVID-19 pattern with the development of acute respiratory distress syndrome (ARDS) changes in all patients. Accumulation of fluid with an admixture of surfactant, desquamated epithelium, alveolar macrophages, and neutrophils was discovered in the alveolar lumina. Focal epithelial proliferation with the formation of syncytia was registered in parallel with desquamation. Giant epithelial cells with viral particles and signs of pyroptosis were detected in the epithelium of some alveoli and their lumina. Typical changes included the formation of fibrin and hyaline membranes in the alveolar space (Fig. 1). Emphysematous dilation of some alveoli with the establishment of large cavities was registered. The irregular thickness of the alveolar septa was typical in such cases. Some of these septa were thickened with proliferating septal cells while other single septa were sclerotic. These findings reflect the presence of both exudative and proliferative phases of the disease in different parts of the lungs. Alveolar septa adjacent to the bronchi and blood vessels were infiltrated by lymphoid and plasmatic cells as well as histiocytes.

Hypertrophy of muscle fibers was found in the bronchi and

Table 1
Clinical characteristics and venous thromboembolism in analyzed patients.

Patient no.	Sex	Age, years old	Results of PCR test	Duration of inpatient treatment, days	Body weight, kg	BMI, kg/m ²	VTE	
							DVT ^a	PE
1	female	83	positive	16	72	26.5	Calf muscle veins by DUS	No clinical signs
2	male	79	negative	15	85	29.4	No clinical signs	Minor branches of PA by CTPA
3	male	59	negative	14	80	27.4	Excluded by DUS	Putative by clinical signs
4	male	86	positive	1	73	24.4	No clinical signs	No clinical signs
5	male	72	positive	10	106	35.8	Excluded by DUS	No clinical signs
6	female	63	positive	23	105	40.0	Excluded by DUS	Minor branches of PA by CTPA
7 ^b	male	60	positive	<1 (15 h)	100	39.0	No clinical signs	No clinical signs

BMI – body mass index; CTPA – computed tomography pulmonary angiography; DUS – duplex ultrasound scan; DVT – deep vein thrombosis; PE – pulmonary embolism; PCR – reverse transcription-polymerase chain reaction; VTE – venous thromboembolism.

^a No additional signs of DVT were obtained at autopsy.

^b the patient with no specific treatment.

Table 2
Blood test findings at the day of death in analyzed patients.

Patient no.	AST U/L	ALT U/L	Creatinine μmol/L	GFR mL/min	LDH U/L	Ferritin ng/mL
1	48	38	160	25	565	693
2	104	33	45	104	496	465
3	41	29	64	121	821	2595
4	34	14	160	33	362	333
5	63	35	202	27	852	3092
6	50	33	261	16	933	1709
7	68	64	229	NA	NA	NA
Reference ranges						
Women	<32	<33	53–97	80–110	135–214	28–365
Men	<40	<41	80–115	80–125	135–225	10–150

AST – aspartate aminotransferase; ALT – alanine aminotransferase; GFR – glomerular filtration rate; LDH – lactate dehydrogenase; NA – not applicable.

bronchioles. Desquamated epithelium, mucus, and macrophages were detected in the bronchial lumina of all calibers.

No signs of hemorrhagic lesions were found in the lungs, and other examined organs in six patients.

The typical abnormalities of big and small vessels were represented by swelling of the vessel wall, intima and media loosening, dystrophy and necrobiosis in the endothelium and muscle fibers, fibrinoid necrosis, fragmentation of the collagen and elastic fibers, and infiltration by inflammatory cells (Fig. 2). Advanced inflammatory infiltration with plasmatic cells, neutrophils, and lymphocytes was detected in the

Table 3
Blood coagulation parameters in analyzed patients.

Patient no.	Day	D-dimer, mg/L	FG, g/L	PT, sec	PLT, count x10 ⁹ /L	DIC ISTH, scores	INR	APTT, sec	TT, sec
1	1	2.21	2.16	12.7	155	3	1.14	30.8	22.9
	16	1.44	2.23	14.6	350	2	1.3	45.8	40.2
2	1	0.65	4.27	11.2	193	2	1.01	37.9	19.8
	15	0.23	2.55	11.6	363	0	1.04	30.1	22.4
3	1	1.44	5.7	11.4	146	2	1.03	37.9	21.0
	14 (m)	1.57	1.92	11.4	292	2	1.03	33.0	26.1
	14 (e)	6.53	2.08	12.8	222	3	1.15	45.6	NA
4	1	1.62	1.35	17.3	106	2	1.54	54.1	20.0
	2	1.63	1.19	20.0	109	2	1.77	53.3	24.7
5	1	1.75	6.20	10.4	145	2	0.94	35.5	21.5
	10	21.3	3.02	14.6	94	4	1.3	116.6	NA
6	1	0.62	4.52	11.9	164	2	1.07	30.7	22.1
	23	4.17	3.32	11.9	71	4	1.07	25.8	17.1
7	1	NA	NA	NA	168	NA	2.9	38.0	NA
Reference ranges									
Women		<0.5	2–4	11–14	150–400	≥5: overt DIC	0.8–1.2	21.1–36.5	14–21
Men					180–320				

FG – fibrinogen; PT – prothrombin time; PLT – platelets; DIC ISTH – assessment of DIC by ISTH criteria (≥5 scores indicate DIC); INR – international normalized ratio; APTT – activated partial thromboplastin time; TT – thrombin time; (m) – morning; (e) – evening; NA – not applicable.

vascular wall and perivascular space. Multiple clots of variable maturity and degree of the organization were discovered inside the arteries with the abnormal wall. In the small arteries, the thrombi predominantly had a fibrin structure, while in mid-sized vessels, there was a mixed content (Figs. 3 and 4).

Similar signs of angiopathy were detected in the individual vessels of the kidney, liver, and spleen (Fig. 5). They were represented by dystrophic endothelial abnormalities, fibrinoid necrosis of the vascular wall, inflammatory infiltration of the vessel wall, and a perivascular zone. No clots were discovered in these organs at the background of angiopathy.

The described abnormalities were typical for all six patients and were registered regardless of the type of antiviral therapy, anti-cytokine, or interferon treatment.

3.2.2. Thrombotic angiopathy in the hypocoagulation setting

Structural changes similar to those described above in the other six patients were detected by the histological examination of patient no.7, who had no exposure to any specific treatment before death. Typical patterns of ARDS with severe edema of the lung tissue, casts of fibrin, hyaline membranes, desquamated and proliferating epithelium, surfactant networks, macrophages, and neutrophils in the alveoli were found. Giant alveolocytes with the phenomena of pyroptosis were discovered. The interstitial space was characterized by hyperemia and infiltration with lymphocytes and leukocytes.

The walls of the segmental and subsegmental branches of the pulmonary artery appeared to be infiltrated by neutrophils and lymphocytes

Table 4
Blood gases in patients who underwent systemic thrombolysis.

Patient no.	Day after lysis	pCO ₂ , mmHg	pO ₂ , mmHg	sO ₂ , %	O ₂ Hb, %	Clinical data
3	Before	42.3	48.6	70.0	78.9	NIV
		27.6	86.7	97.1	95.5	Nasal cannula
	2	26.4	69.4	95.8	94.1	NIV
6	Before	49.8	50.8	81.1	79.5	MV
		43.3	42.5	77.4	76.5	NIV
	0	34.6	77.5	89.3	88.2	NIV
Reference ranges	3	49.3	37.0	65.6	63.7	MV
		35–45	80–100	93–98	96–98	

NIV – non-invasive ventilation; MV – mechanical ventilation; pCO₂ – partial pressure of carbon dioxide; pO₂ – partial pressure of oxygen; sO₂ – oxygen saturation; O₂Hb – oxyhemoglobin.

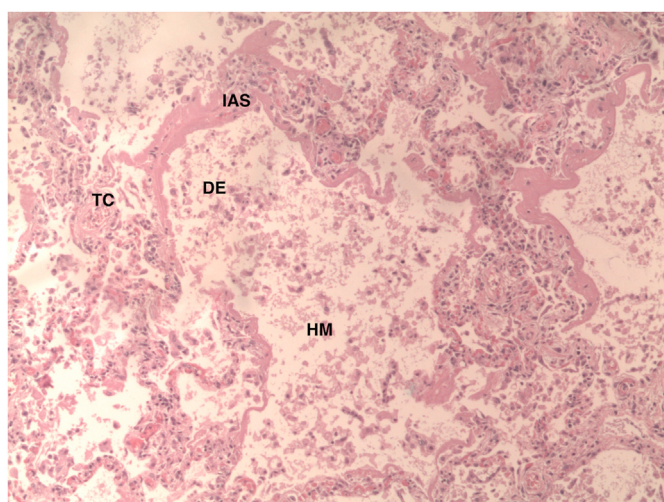


Fig. 1. Hyaline membranes (HM) in the alveolar lumen, desquamated epithelium (DE), thickened and infiltrated alveolar septa (IAS), thrombi in capillaries (TC) (H&E stain; original magnification, ×100).

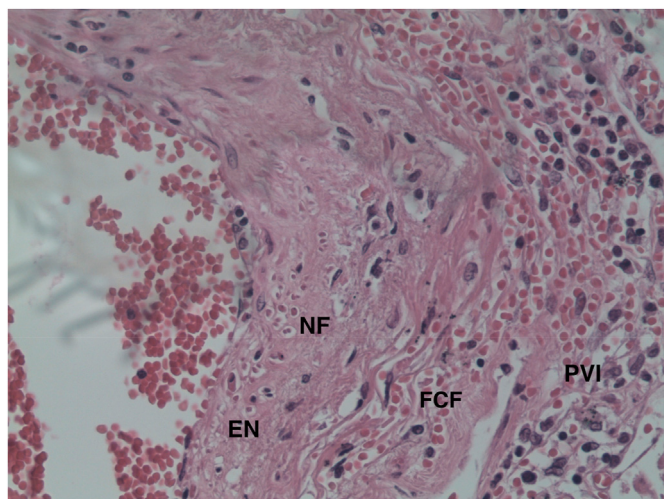


Fig. 2. Artery wall with dystrophic endothelial changes, endothelial necrosis (EN) with nucleus fragmentation (NF), fragmentation of collagen fibers (FCF), and infiltration of the arterial wall and perivascular space by leukocytes and lymphocytes (PVI) (H&E stain; original magnification, ×400).

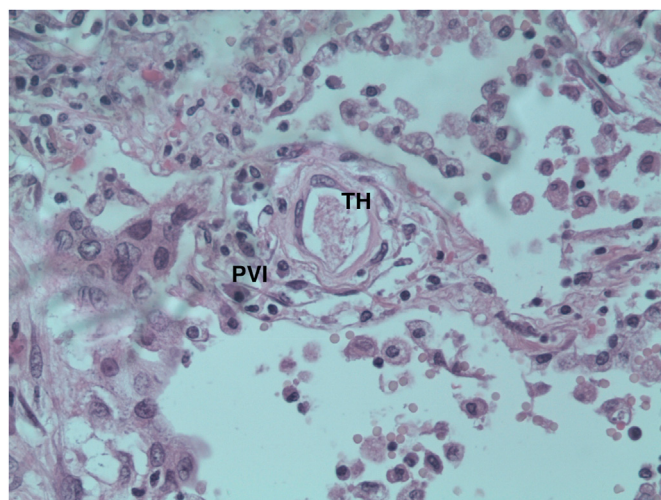


Fig. 3. Fibrin capillary thrombus (TH), perivascular leukocyte, and lymphocyte infiltration (PVI) (H&E stain; original magnification, ×400).

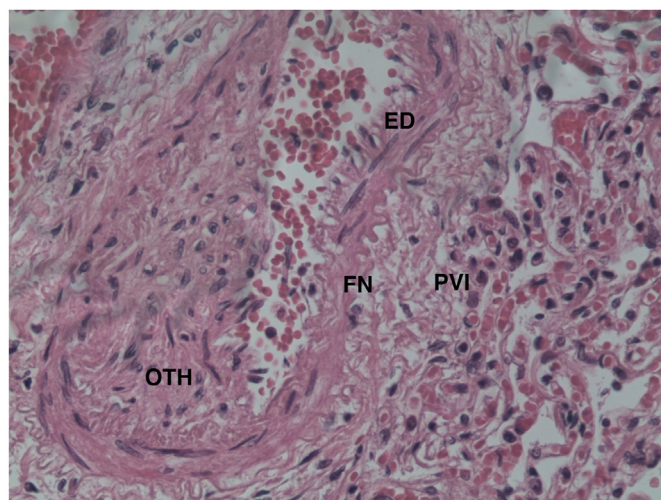


Fig. 4. Organizing thrombus (OTH) in the arterial lumen. Endothelial edema, endotheliocyte desquamation (ED) and necrosis, fibrinoid wall necrosis (FN), infiltration of the vessel wall, and perivascular tissues by leukocytes and lymphocytes (PVI) (H&E stain; original magnification, ×400).

in parallel with perivascular infiltration. Ongoing thrombosis was registered in the subsegmental branches of the PA despite the hypo-coagulative state (Fig. 6). No additional clots were discovered in the liver, kidney, and spleen.

In contrast with the previously described patients, diapedetic hemorrhages were found in the cerebral cortex, white matter of the hemispheres, and cerebellum. Similar focal hemorrhages were discovered in the lungs, mucous membranes of the stomach, colon, urinary bladder, and the renal calyces.

No other histopathological differences except hemorrhagic lesions were observed in the patient no.7 when compared with the previous six ones.

3.2.3. Abnormalities in the pulmonary artery branches after systemic thrombolysis

Patients no.3 and no.6 represented multiple thrombi in the major and minor pulmonary artery branches despite systemic thrombolysis. Some clots, mostly in the major vessels, were lysed (Fig. 7). Thrombi in the small-caliber arteries represented a different maturity and degree of organization with no signs of lysis (Fig. 8).

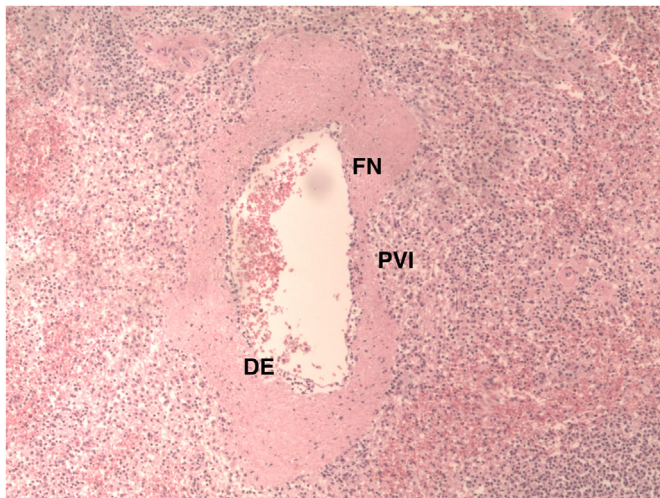


Fig. 5. Artery of the spleen: dystrophic endothelial (DE) changes; fibrinoid wall necrosis (FN). Leukocyte and lymphocyte infiltration (PVI) of the wall and perivascular spaces (H&E stain; original magnification, $\times 100$).

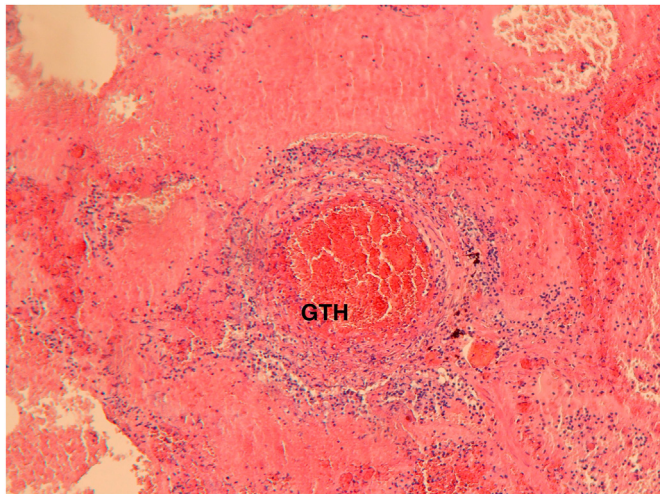


Fig. 6. Parietal growing thrombus (GTH) in the subsegmental pulmonary artery branch with prominent vascular wall and perivascular inflammatory infiltration (H&E stain; original magnification, $\times 400$).

4. Discussion

Morphological studies testify that angiopathy is the crucial pathogenic mechanism of thrombotic complications in COVID-19 [4,6]. Ultrastructural analysis reveals the destruction of the pulmonary vascular endotheliocytes [4]. Immunohistochemical tests demonstrate the presence of CD45 lymphocytes, CD68 macrophages, CD61 megakaryocytes, CD3⁺, CD4⁺, and CD8 T-cells, and CD15 neutrophils in the inflammatory infiltration of the vascular wall and perivascular space [4,18]. Advanced abnormalities of the lung vasculature are observed with varying frequencies among vessels of different calibers. Clots in the major arteries may be found in a limited number of patients and require differential diagnosis between thrombosis in situ and thromboembolism. By contrast, thrombi in pulmonary microvasculature may be revealed in most of the patients with COVID-19 pneumonia. The cumulative evidence shows that microcirculatory thrombosis could be found in 87% of all deceased patients, while thrombosis of large PA branches was found in only 13% of autopsies (Table 5). Moreover, the capillary destruction with advanced fibrinoid necrosis occurs regardless of the severity of viral pneumonia and may be registered in patients without ARDS [19].

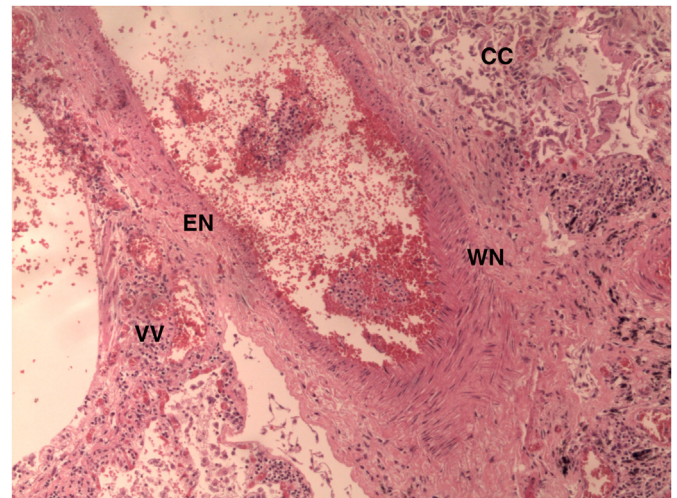


Fig. 7. Partial lysis of thrombus in a large branch of the pulmonary artery. Dystrophic and necrotic changes in the artery wall (EN – endothelial necrosis, WN – wall necrosis). Typical destructive changes of lung tissue. Vasa vasorum (VV) and lung capillary congestion (CC).

In the current study, typical structural changes without significant heterogeneity were discovered in all seven patients both in the wall of small PA branches and in the alveolar capillaries. Dystrophy reaching the grade of cell necrosis in the intima and media was combined with inflammatory infiltration of the vascular wall and perivascular space. Described abnormalities were registered both in thrombosed vessels and in the patent arteries. Similar angiopathy in the absence of thrombosis was found in the liver, kidney, and spleen.

Structural changes in the arterial wall can precede and provoke thrombosis and indicate the formation of a prothrombotic phenotype that could be initiated by several mechanisms in COVID-19. One of them is a direct endothelial injury by the virus that provokes massive cellular apoptosis, leading to the loss of cellular anticoagulation function [5,20]. The activation of immune cells and endotheliocytes by circulating cytotoxins may represent another trigger for endothelial damage [20]. The high level of ferritin associated with the systemic inflammation, cytokine storm, tissue infiltration by monocytes and macrophages, and poor prognosis of the disease testify to the role of the upregulated immune response in cell injury. The activation of the complement system directly

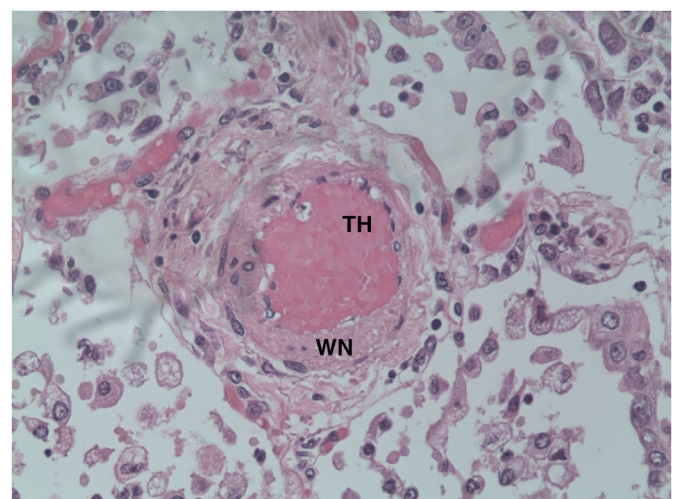


Fig. 8. Early-stage (fresh) thrombus (TH), artery wall dystrophic and necrotic endothelial changes (WN), perivascular inflammatory infiltration (after systemic thrombolysis).

Table 5

The frequency of venous thromboembolism and lung vasculature thrombosis in deceased patients with COVID-19 (a pooled analysis).

Publication	Number of patients	Type of autopsy	Major branches of PA, no./no. of total (%)	Small branches of PA and microvasculature, no./no. of total (%)	Extrapulmonary thrombosis, no./no. of total (%)
Menter T. et al. [9]	21	Full	4/21 (19%)	5/11 (45%)	Kidney: 3/18 (17%)
Carsana L. et al. [18]	38	Lungs	0/38 (0%)	33/38 (87%)	n/a
Lax S.F. et al. [6]	11	Full	1/11 (9%)	11/11 (100%)	Liver: 1/11 (9%)
Fox S.E. et al. [26]	10	Full	0/10 (0%)	10/10 (100%)	0/10 (0%)
Ackermann M. et al. [4]	7	Lungs	0/7 (0%)	Arterioles: 4/7 (57%); Capillaries: 7/7 (100%)	n/a
Elder C. et al. [27]	80	Full	17/80 (21%)	n/a	DVT: 32/80 (40%) Prostatic venous plexus thrombosis: 15/46 (33%)
The current study	7	Full	0/7 (0%)	7/7 (100%)	DVT (lower extremities): 1/7 (14%)
Total	174		22/174 (13%)	73/84 (87%)	37/126 (29%)

PA – pulmonary artery; DVT – deep vein thrombosis; n/a – data non-available.

by the virus or in a traditional way is another potential mechanism for endothelial damage [19].

The role of systemic coagulation disturbance in the pathogenesis of COVID-19 thrombosis is less evident than the contribution of the local mechanisms mentioned above. Thus, prophylactic anticoagulation may be enough to prevent systemic hypercoagulation and avoid DIC. It has been shown that without pharmacological prophylaxis, DIC developed in 71.4% of deceased patients with COVID-19 [7]. At the same time, no evidence of DIC was reported in patients who received prophylactic doses of LMWH in the previous reports as well as in the current study [2,21]. Moreover, prophylactic anticoagulation reduced mortality in patients with the signs of sepsis-induced coagulopathy and critically increased D-dimer [22]. On the other hand, even if DIC could be prevented, there is another potential underlying mechanism of COVID-19 associated thrombosis. It has been shown that impaired fibrinolysis related to the increased level of plasminogen activator inhibitor-1 (PAI-1) and thrombin activatable fibrinolysis inhibitor (TAFI) may lead to the thrombotic complications in severe COVID-19 [23]. The hypofibrinolysis can develop either as a systemic or local effect due to PAI-1 release from endothelial cells [23].

However, no reliable data support the efficacy of prophylactic or therapeutic anticoagulation in preventing the pulmonary vasculature thrombosis in COVID-19. Venous thromboembolism with a predominantly thrombotic lesion of PA and arterial thrombotic events were detected despite anticoagulation in previous reports [2,3,24]. The post-mortem examination of patients who received anticoagulants identified disseminated clots in the lung vasculature [6,8,9].

In the current analysis, intermediate or therapeutic doses of LMWH were administered to all patients. Despite this fact, one subject developed thrombosis of the calf muscle veins, two subjects had a confirmed PE, one had a putative PE, and all seven subjects experienced extensive thrombosis of the PA branches as detected by dissection. At the same time, no thrombi in other organs were found, despite the angiopathy. All abnormalities were accompanied by extremely high ferritin and LDH levels.

We can assume that the lack of anticoagulant activity in the pulmonary vasculature may be related to the decreased perfusion. The reason for this is a blood flow shunt in the dead spaces, vascular constriction, and blood stasis caused by lung tissue destruction and pulmonary edema [19,20]. At the same time, microcirculation in other organs is preserved, and anticoagulant therapy with maintained blood flow prevents thrombus formation at the background of angiopathy. According to the previously published data, microcirculatory thrombosis outside the lung is rarely observed (Table 5). However, the ongoing destructive processes in the arterial wall can lead to necrotic injury, resulting in the failure of organ function [9,19]. Impaired levels of AST, ALT, creatinine, and GRF, observed in some patients, can be considered as the signs of such dysfunction.

Lack of pulmonary perfusion can limit the efficacy of systemic thrombolysis. In our patients, it resulted in the persistence of clots in

subsegmental branches of PA. They appeared to be less sensitive to systemic lysis when compared to thrombi in major PA branches. Ongoing thrombi formation can be responsible for the limited time efficacy of systemic thrombolysis and a lack of significant clinical and respiratory improvement. At the same time, diapedetic hemorrhages that were observed by histological examination can become a substrate for major bleeding. Likely, dose, volume, and duration adjustments can improve the results of thrombolysis. Several different regimens have been suggested for tPA administration [15,16,25]. Lower doses and longer duration may be preferred.

5. Conclusion

Coronavirus disease caused by the SARS-CoV-2 virus is associated with a high incidence of thrombotic complications. The most important among these is thrombosis of the lung vasculature. Clots in the small PA branches may aggravate the severity of the disease, affect blood oxygenation, increase the dead space in the lungs, and reduce the bioavailability of anticoagulants. The immune processes triggered in the lungs have a systemic nature, inducing the development of angiopathy in other organs. Progressive dystrophy and necrosis in the arterial wall contribute to organ failure. Anticoagulant and thrombolytic therapies have limited opportunities for the prevention and treatment of thrombotic complications in COVID-19. The search for optimal therapeutic regimens and possible combinations with other drugs aimed at the improvement of pulmonary perfusion is essential.

Funding

The study was performed without any financial support or funding.

Authors contribution

O Porembskaya, K Lobastov, S Tsaplin, O Pashovkina, L Laberko - concept and design.

O Porembskaya, K Lobastov, S Tsaplin, O Pashovkina, L Laberko, I Schastlitsvsev, A Skvortsov - analysis and interpretation of data.

O Porembskaya, K Lobastov - writing the manuscript.

S Zhuravlev, L Laberko, V Kravchuk - critical revising the intellectual content.

O Porembskaya, K Lobastov, L Laberko, G Rodoman, S Saiganov - final approval of the version to be published.

Declaration of competing interest

The authors declare that they have no known competing financial interests or personal relationships that could have appeared to influence the work reported in this paper.

References

- [1] J. Poissy, J. Goutay, E. Caplan, M. Parmentier, T. Duburcq, F. Lassalle, E. Jeanpierre, A. Rauch, J. Labreuche, S. Susen, Lille ICU haemostasis COVID-19 group. Pulmonary embolism in COVID-19 patients: awareness of an increased prevalence, *Circulation* (2020), <https://doi.org/10.1161/CIRCULATIONAHA.120.047430>.
- [2] J. Helms, C. Tacquard, F. Severac, I. Leonard-Lorant, M. Ohana, X. Delabranche, H. Merdji, R. Clere-Jehl, M. Schenck, F. Fagot Gandet, S. Fafi-Kremer, V. Castelain, F. Schneider, L. Grunebaum, E. Anglés-Cano, L. Sattler, P.M. Mertes, F. Meziani, CRICS TRIGGERSEP Group, Clinical research in intensive care and sepsis trial group for global evaluation and research in sepsis). High risk of thrombosis in patients with severe SARS-CoV-2 infection: a multicenter prospective cohort study, *Intensive Care Med.* 46 (2020) 1089–1098, <https://doi.org/10.1007/s00134-020-06062-x>.
- [3] F.A. Klok, M.J.H.A. Kruip, N.J.M. van der Meer, M.S. Arbous, D.A.M.P.J. Gommers, K.M. Kant, F.H.J. Kaptein, J. van Paassen, M.A.M. Stals, M.V. Huisman, H. Endeman, Incidence of thrombotic complications in critically ill ICU patients with COVID-19, *Thromb. Res.* 191 (2020) 145–147, <https://doi.org/10.1016/j.thromres.2020.04.013>.
- [4] M. Ackermann, S.E. Verleden, M. Kuehnel, A. Haverich, T. Welte, F. Laenger, A. Vanstapel, C. Werlein, H. Stark, A. Tzankov, W.W. Li, V.W. Li, S.J. Mentzer, D. Jonigk, Pulmonary vascular endothelialitis, thrombosis, and angiogenesis in covid-19, *N. Engl. J. Med.* (2020), <https://doi.org/10.1056/NEJMoa2015432>.
- [5] Z. Varga, A. Flammer, P. Steiger, M. Haberecker, R. Andermatt, A.S. Zinkernagel, M.R. Mehra, R.A. Schuepbach, F. Ruschitzka, H. Moch, Endothelial cell infection and endothelialitis in COVID-19, *Lancet* 395 (10234) (2020) 1417–1418, [https://doi.org/10.1016/S0140-6736\(20\)30937-5](https://doi.org/10.1016/S0140-6736(20)30937-5).
- [6] S.F. Lax, K. Skok, P. Zechner, H.H. Kessler, N. Kaufmann, C. Koelblinger, K. Vander, U. Bargfrieder, M. Trauner, Pulmonary arterial thrombosis in COVID-19 with fatal outcome: results from a prospective, single-center, clinicopathologic case series. Prospective, single-center, clinicopathologic case series, *Ann. Intern. Med.* (2020), <https://doi.org/10.7326/M20-2566>.
- [7] N. Tang, D. Li, X. Wang, Z. Sun, Abnormal coagulation parameters are associated with poor prognosis in patients with novel coronavirus pneumonia, *J. Thromb. Haemostasis* 18 (4) (2020) 844–847, <https://doi.org/10.1111/jth.14817>.
- [8] D. Wichmann, J.-P. Sperhake, M. Lütgehetmann, S. Steurer, C. Edler, A. Heinemann, F. Heinrich, H. Mushumba, I. Kniep, A.S. Schröder, C. Burdelski, G. de Heer, A. Nierhaus, D. Frings, S. Pfefferle, H. Becker, H. Brederke-Wiedling, A. de Weerth, H.R. Paschen, S. Sheikhzadeh-Eggers, A. Stang, S. Schmiedel, C. Bokemeyer, M.M. Addo, M. Aepfelbacher, K. Püschel, S. Kluge, Autopsy findings and venous thromboembolism in patients with COVID-19, *Ann. Intern. Med.* (2020), <https://doi.org/10.7326/M20-2003>.
- [9] T. Menter, J.D. Haslbauer, R. Nienhold, S. Savic, H. Deigendesch, S. Frank, D. Turek, N. Willi, H. Pargger, S. Bassetti, J.D. Leuppi, G. Cathomas, M. Tolnay, K.D. Mertz, A. Tzankov, Post-mortem examination of COVID19 patients reveals diffuse alveolar damage with severe capillary congestion and variegated findings of lungs and other organs suggesting vascular dysfunction, *Histopathology* (2020), <https://doi.org/10.1111/his.14134>.
- [10] S. Cui, S. Chen, X. Li, S. Liu, F. Wang, Prevalence of venous thromboembolism in patients with severe novel coronavirus pneumonia, *J. Thromb. Haemostasis* 18 (6) (2020) 1421–1424, <https://doi.org/10.1111/jth.14830>.
- [11] B. Bikkeli, M.V. Madhavan, D. Jimenez, T. Chuich, I. Dreyfus, E. Driggin, C. Nigoghossian, W. Ageno, M. Madjid, Y. Guo, L.V. Tang, Y. Hu, J. Giri, M. Cushman, I. Quéré, E.P. Dimakakos, C.M. Gibson, G. Lippi, E.J. Favaloro, J. Fareed, J.A. Caprini, et al., COVID-19 and thrombotic or thromboembolic disease: implications for prevention, antithrombotic therapy, and follow-up, *J. Am. Coll. Cardiol.* 75 (23) (2020) 2950–2973, <https://doi.org/10.1016/j.jacc.2020.04.031>.
- [12] A.C. Spyropoulos, J.H. Levy, W. Ageno, J.M. Connors, B.J. Hunt, T. Iba, M. Levi, C.M. Samama, J. Thachil, D. Giannis, J.D. Douketis, Subcommittee on perioperative, critical care thrombosis, haemostasis of the scientific, standardization committee of the international society on thrombosis, Haemostasis +. Scientific and standardization committee communication: clinical guidance on the diagnosis, prevention and treatment of venous thromboembolism in hospitalized patients with COVID-19, *J. Thromb. Haemostasis* (2020). <https://doi.org/10.1111/jth.14929>.
- [13] L.K. Moores, T. Tritschler, S. Brosnahan, M. Carrier, J.F. Collen, K. Doerschug, A.B. Holley, D. Jimenez, G. LeGal, P. Rali, P. Wells, Prevention, diagnosis and treatment of venous thromboembolism in patients with COVID-19: CHEST Guideline and Expert Panel Report, *Chest* S0012–3692 (20) (2020), 31625–1, <https://doi.org/10.1016/j.chest.2020.05.559>.
- [14] I. Paranjpe, V. Fuster, A. Lala, A.J. Russak, B.S. Glicksberg, M.A. Levin, A.W. Charney, J. Narula, Z.A. Fayad, E. Bagiella, S. Zhao, G.N. Nadkarni, Association of treatment dose anticoagulation with in-hospital survival among hospitalized patients with COVID-19, *J. Am. Coll. Cardiol.* (2020), <https://doi.org/10.1016/j.jacc.2020.05.001>.
- [15] H.D. Poor, C.E. Ventetulo, T. Tolbert, G. Chun, G. Serrao, A. Zeidman, N.S. Dangayach, J. Olin, R. Kohli-Seth, C.A. Powell, COVID-19 critical illness pathophysiology driven by diffuse pulmonary thrombi and pulmonary endothelial dysfunction responsive to thrombolysis, *Clin. Transl. Med.* (2020). <https://doi.org/10.1002/ctm2.44>.
- [16] S.D. Qanadli, L. Gudmundsson, D.C. Rotzinger, Catheter-directed thrombolysis in COVID-19 pneumonia with acute PE: thinking beyond the guidelines, *Thromb. Res.* 192 (2020) 9–11.
- [17] M. Levi, C.H. Toh, J. Thachil, H.G. Watson, Guidelines for the diagnosis and management of disseminated intravascular coagulation, *Br. J. Haematol.* 145 (1) (2009) 24–33.
- [18] L. Carsana, A. Sonzogni, A. Nasr, R.S. Rossi, A. Pellegrinelli, P. Zerbi, R. Rech, R. Colombo, S. Antinori, M. Corbellino, M. Galli, E. Catena, A. Tosoni, A. Gianatti, M. Nebuloni, Pulmonary postmortem findings in a series of COVID-19 cases from northern Italy: a two-centre descriptive study, *Lancet Infect. Dis.* (2020), [https://doi.org/10.1016/S1473-3099\(20\)30434-5](https://doi.org/10.1016/S1473-3099(20)30434-5).
- [19] C. Magro, J.J. Mulvey, D. Berlin, G. Nuovo, S. Salvatore, J. Harp, A. Baxter-Stoltzfus, J. Laurence, Complement associated microvascular injury and thrombosis in the pathogenesis of severe COVID-19 infection: a report of five cases, *Transl. Res.* (2020), <https://doi.org/10.1016/j.trsl.2020.04.007>.
- [20] T. Iba, J.H. Levy, M. Levi, J.M. Connors, J. Thachil, Coagulopathy of coronavirus disease 2019, *Crit. Care Med.* (2020). <https://doi.org/10.1097/CCM.0000000000004458>.
- [21] H. Fogarty, L. Townsend, C. Ni Cheallaigh, H. Fogarty, L. Townsend, C. Ni Cheallaigh, C. Bergin, I. Martin-Loeches, P. Browne, C.L. Bacon, R. Gaule, A. Gillett, M. Byrne, K. Ryan, N. O'Connell, J.M. O'Sullivan, N. Conlon, J.S. O'Donnell, COVID-19 coagulopathy in Caucasian patients, *Br. J. Haematol.* 189 (6) (2020) 1044–1049, <https://doi.org/10.1111/bjh.16749>.
- [22] N. Tang, H. Bai, X. Chen, J. Gong, D. Li, Z. Sun, Anticoagulant treatment is associated with decreased mortality in severe coronavirus disease 2019 patients with coagulopathy, *J. Thromb. Haemostasis* 18 (5) (2020) 1094–1099, <https://doi.org/10.1111/jth.14817>.
- [23] C. Nougier, R. Benoit, M. Simon, H. Desmurs-Clavel, G. Marcotte, L. Argaud, J.S. David, A. Bonnet, C. Negrier, Y. Dargaud, Hypofibrinolytic state and high thrombin generation may play a major role in SARS-CoV2 associated thrombosis, *J. Thromb. Haemostasis* (2020), <https://doi.org/10.1111/jth.15016>. <http://doi.org/10.1111/jth.15016>.
- [24] C. Lodigiani, G. Iapichino, L. Carenzo, M. Cecconi, P. Ferrazzi, T. Sebastian, N. Kucher, J.D. Studt, C. Sacco, B. Alexia, M.T. Sandri, S. Barco, Humanitas COVID-19 Task Force. Venous and arterial thromboembolic complications in COVID-19 patients admitted to an academic hospital in Milan, Italy, *Thromb. Res.* 191 (2020) 9–14. <https://doi.org/10.1016/j.thromres.2020.04.024>.
- [25] J. Wang, N. Hajizadeh, E.E. Moore, R.C. McIntyre, P.K. Moore, L.A. Veress, M.B. Yaffe, H.B. Moore, C.D. Barrett, Tissue plasminogen activator (tPA) treatment for COVID-19 associated acute respiratory distress syndrome (ARDS): a case series, *J. Thromb. Haemostasis* (2020). <https://doi.org/10.1111/jth.14828>.
- [26] S.E. Fox, A. Akmatbekov, J.L. Harbert, G. Li, J. Quincy Brown, R.S. Vander Heide, Pulmonary and cardiac pathology in African American patients with COVID-19: an autopsy series from New Orleans, *Lancet Respir Med* (2020), [https://doi.org/10.1016/s2213-2600\(20\)30243-5](https://doi.org/10.1016/s2213-2600(20)30243-5).
- [27] C. Edler, A.S. Schröder, M. Aepfelbacher, A. Fitzek, A. Heinemann, F. Heinrich, A. Klein, F. Langenwalder, M. Lütgehetmann, K. Meißner, K. Püschel, J. Schädler, S. Steurer, H. Mushumba, J.P. Sperhake, Dying with SARS-CoV-2 infection—an autopsy study of the first consecutive 80 cases in Hamburg, Germany, *Int. J. Leg. Med.* 134 (4) (2020) 1275–1284. <https://doi.org/10.1007/s00414-020-02317-w>.