

# A novel mutation in GP1BA gene in a family with autosomal dominant Bernard Soulier syndrome variant: A case report

JINGYAO MA, ZHENPING CHEN, GANG LI, HAO GU and RUNHUI WU

Hematology Oncology Center, Beijing Children's Hospital, Capital Medical University,  
National Center for Children's Health, Beijing 100045, P.R. China

Received September 25, 2020; Accepted January 8, 2021

DOI: 10.3892/etm.2021.9791

**Abstract.** Classic Bernard-Soulier syndrome (BSS) is a rare form of autosomal recessive disorder that is caused by mutations in the GP1BA gene that encode the GPIb-V-IX complex, a receptor of von Willebrand factor. BSS characterized by macrothrombocytopenia and excessive bleeding. The present study reports a single case (18-month Chinese girl) diagnosed with BSS. The patient suffered mild thrombocytopenia, giant platelets and normal platelet aggregation. In addition, mild bleeding and thrombocytopenia were also indicated in thirteen family members, including the proband and her father. Gene sequence analysis identified a monoallelic missense mutation in GP1BA (c.97T>A), which encodes a p.C33R substitution in the N-terminal domain of glycoprotein (GP)Ib $\alpha$  that may disrupt the protein structure. To the best of our knowledge, this dominant variant has not been reported previously. BSS's autosomal dominant inheritance mode is rarely identified and can be easily misdiagnosed as immune thrombocytopenia. For patients with giant platelets, thrombocytopenia and positive family history, next-generation sequencing for inherited thrombocytopenia, especially disorders that are caused by mutations in glycoprotein Ib-IX-V complex, is required.

## Introduction

The Bernard-Soulier syndrome (BSS) is an extremely rare congenital disease that is characterized by macrothrombocytopenia and defective binding of platelets to the von Willebrand factor (vWF), which participates in the adherence of platelets to the vascular subendothelial layer (1). BSS disease pathogenesis lies in the expression of vWF receptor

via the glycoprotein Ib-IX-V (GPIb-IX-V) complex (2). The GPIb-IX-V complex consists of four subunits, glycoprotein (GP)Ib $\alpha$ , GPIb $\beta$ , GPIX and GPV, which are encoded by glycoprotein Ib platelet subunit alpha (GP1BA), glycoprotein Ib platelet subunit beta (GP1BB), GP9 and GP5 (3). Mutations that occur in GP1BA, GP1BB and GP9 may lead to BSS (4). The major subunit, GPIb $\alpha$ , holds an essential ligand-binding site for vWF within its N-terminal domain, and this features the leucine-rich repeat (LRR) (5,6). Pathogenic mutations in its GP1BA gene are classically inherited as a biallelic, autosomal recessive trait (4). A milder phenotype caused by monoallelic autosomal dominant inheritance that shares characters with BSS, including macrothrombocytopenia, has been previously reported (6-12). However, this aforementioned phenotype does not lead to severe bleeding or serious surgical or obstetric hemorrhage that is commonly seen in BSS. Therefore, the autosomal dominant variant of BSS can be easily misdiagnosed as immune thrombocytopenia (ITP) and managed with intravenous immunoglobulin and glucocorticoids, which are used as a first-line treatment for ITP (13,14).

In the present case report, sequence analysis performed on an 18-month-old girl identified an NM\_000173 c.97T>A (p.Cys33Arg) (p.C33R) heterozygous missense mutation in GP1BA. This specific mutation has not been previously reported and may further expand the information regarding mutations in BSS.

## Case report

An 18-month-old girl with thrombocytopenia consulted the Hematology Oncology Center, Beijing Children's Hospital, Capital Medical University (Beijing, China). A period of six months prior to admission to the department, the patient underwent a physical examination, which revealed a baseline platelet count of  $31 \times 10^9/l$ . Since this examination, the patient had no bleeding symptoms, including easy bruising, epistaxis, gingival bleeding and other symptoms as a result of internal bleeding. A peripheral blood smear indicated giant platelets and a reduction in platelet count. vWF antigen (vWF Ag) levels was 94.6% (42.0-140.8%), aggregation response of platelets after adenosine diphosphate (ADP) was 55% (55-90%), collagen was 62.1% (55-90%), arachidonic acid was 82.6% (55-90%) and ristocetin was including low concentration and [76.1% (55-90%); low concentration] and

---

*Correspondence to:* Dr Runhui Wu, Hematology Oncology Center, Beijing Children's Hospital, Capital Medical University, National Center for Children's Health, 56 Nanlishi Road, West, Beijing 100045, P.R. China  
E-mail: runhuiwu@hotmail.com

**Key words:** Bernard-Soulier syndrome, glycoprotein Ib platelet subunit alpha gene, autosomal dominant variant, next-generation sequencing

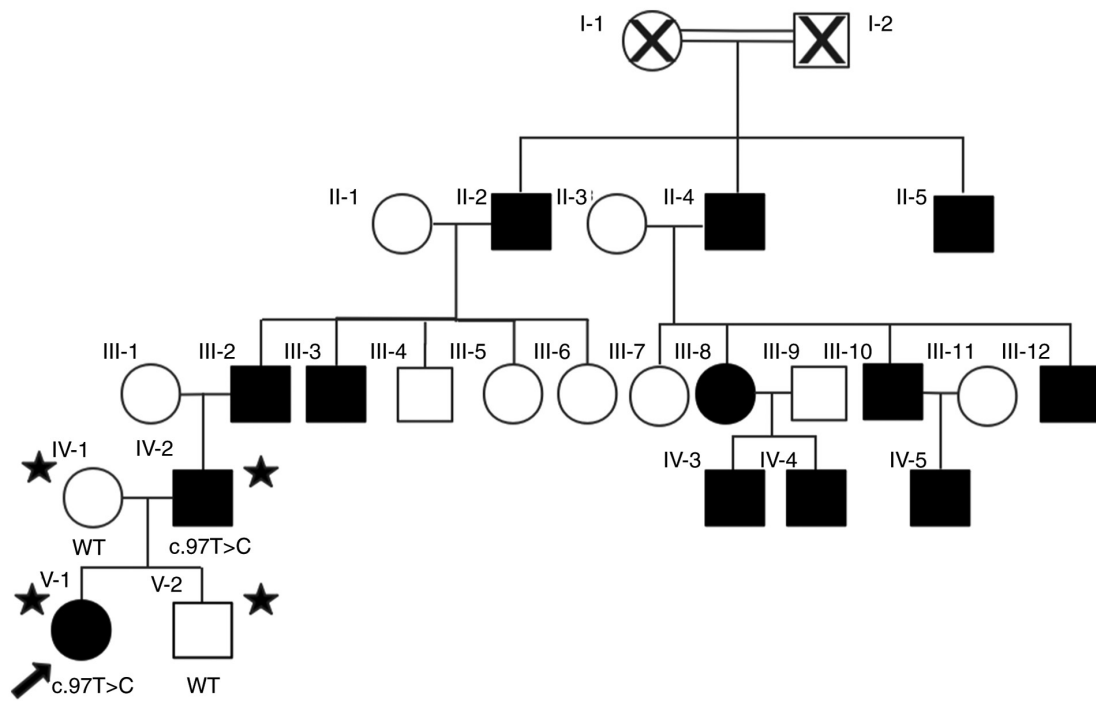


Figure 1. Proband's (V-1) family pedigree indicates mild bleeding and thrombocytopenia. Black star indicates the analysis of family members by next-generation sequencing.

[2.6% (<3%); standard concentration], all of which were within the normal range. CBC, peripheral blood smear and platelet aggregation were performed on the patients parents, and the patients father shared a similar phenotype, including enlarged platelet size and normal aggregation rate of platelet as follows: Aggregation response of platelets after adenosine diphosphate (ADP) was 56.4% (55-90%), collagen was 72.3% (55-90%), arachidonic acid was 85.7% (55-90%) and ristocetin, including low concentration and standard concentration, was 66.7% (55-90%) and 1.3% (<3%) respectively. Considering the probability of inherited thrombocytopenia and abnormal morphology of platelets, DNA samples for genetic analysis were collected from her parents. Written consent from the patient's parents was obtained at the time of sample collection. The present study was performed with approval from the Ethics Committee of Beijing Children's Hospital (Beijing, China; reference no. 2020-Z-113).

Approximately 2 ml peripheral blood of the patient, parents and one sibling were collected in new EDTA containing tubes (as anticoagulant) for genetic analysis. Exome sequencing of germline DNA samples was performed using a QIAamp DNA Mini kit (Qiagen, China Co., Ltd.), according to the manufacturer's protocol. Selected targeted genes that were associated with thrombocytopenia were analyzed using a gene capture strategy with a GenCap custom enrichment kit (MyGenostics, Inc.), following the manufacturer's protocol. The final enriched sequencing libraries were sequenced for paired-end reads of 150 bp using Illumina NovaSeq 6000 platform (Illumina, Inc.). The identified variants were annotated using ANNOtate VARIation (ANNOVAR; <http://annovar.openbioinformatics.org/en/latest/>).

The sequencing analysis identified a heterozygous nucleotide substitution in the GPIBA gene (NM\_000173:

exon2:c.97T>G). An amino acid of cysteine 33 was substituted with arginine in the N-terminal domain of GPIb $\alpha$  protein on the platelet membrane. A validation of GPIBA sequencing was performed on the patient's parents and one sibling. The pedigree analysis (Fig. 1) indicated an autosomal-dominant mode of inheritance. The individuals father carried a similar heterozygous p.C33R variant, while her mother carried a wild-type sequence (Fig. 2). The structural effect of the sequence variant was predicted to be deleterious via in-silico analysis (Fig. 3), using the following software with default parameters: Mutation Taster (<http://www.mutationtaster.org/>), Sorting Intolerant From Tolerant (<http://sift.jcvi.org/>), PolyPhen-2 (<http://genetics.bwh.harvard.edu/pph2/>) and Genomic Evolutionary Rate Profiling (<http://mendel.stanford.edu/SidowLab/downloads/gerp/index.html>). According to the ACMG guidelines (15), the variant was classified as 'likely pathogenic', which confirmed BSS.

## Discussion

In the current case report, a novel heterozygous c.97T>A substitution was reported in the GPIBA gene, which causes a Cys33Arg amino acid substitution. The mutation was annotated with ANNOVAR and the results demonstrated that it has not been recorded in the GnomAD (<https://gnomad.broadinstitute.org/>), 1000 Genomes (<http://www.1000genomes.org/>), ExAC database (16), the human gene mutation database (<http://www.biobase-international.com/product/hgmd>; <http://www.hgmd.cf.ac.uk/ac>), OMIM (<https://www.omim.org/>) or ClinVar databases (<https://www.ncbi.nlm.nih.gov/clinvar/>). To date, ~60 variants of GPIBA encoding GPIb $\alpha$  protein have been identified, and the majority of these are homozygous and contribute to symptoms of BSS (6,17). However, the symptoms

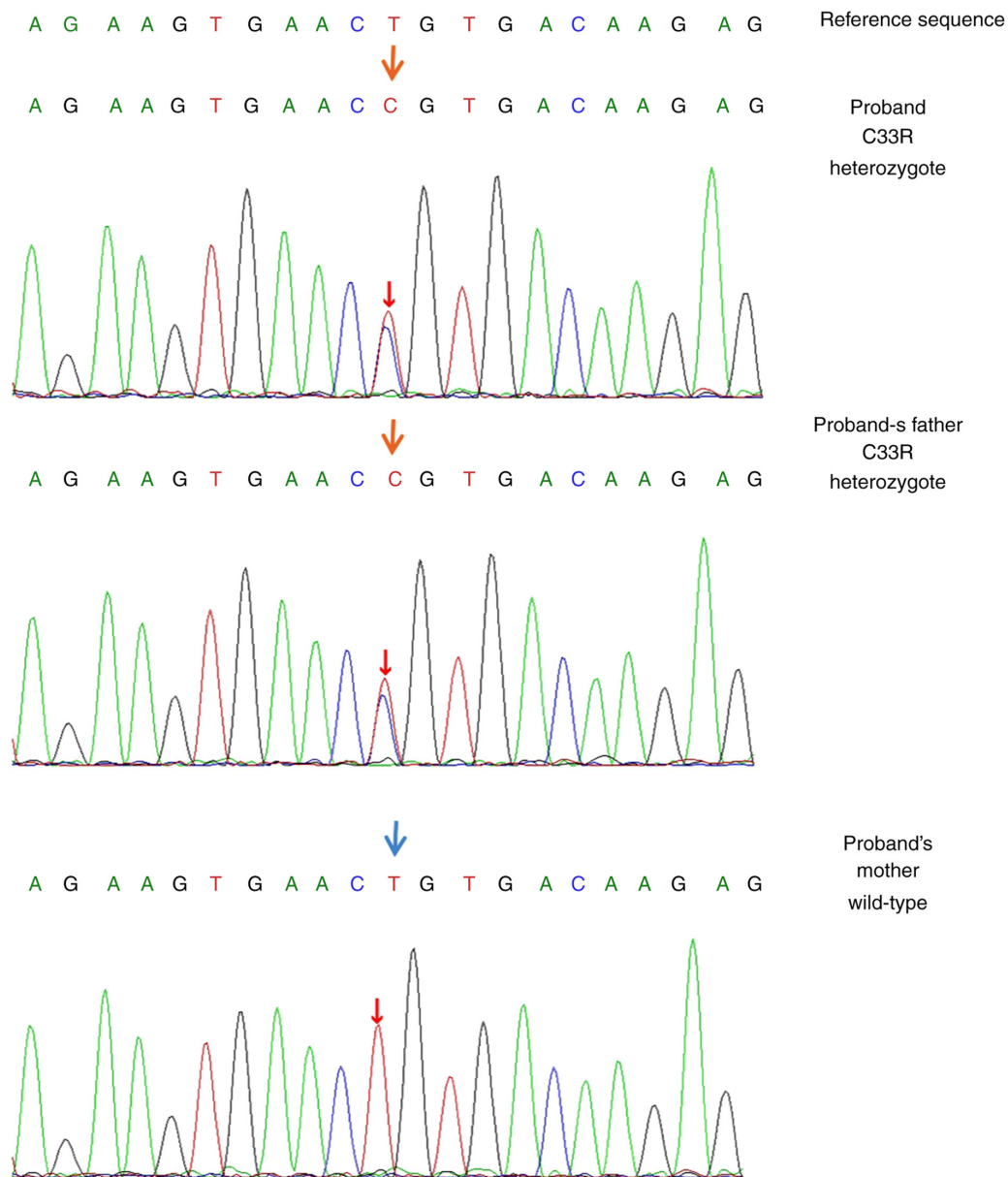


Figure 2. Sanger sequencing showing the nucleotide of GPIBA at position 97 in the reference sequence as T. The proband and her father were heterozygous for the variant C, and her mother was wild-type. The red arrows indicate the site of the new mutation, and the blue arrow indicates the wild-type sequence. GPIBA, glycoprotein Ib platelet subunit alpha.

of individuals in the pedigree of the current study seemed milder than the symptoms of individuals with classic homozygous BSS. Platelet aggregation of the present patients with heterozygous BSS (including the response to the low concentration of ristocetin) appeared normal despite giant platelets being identified in the results of the peripheral blood smear.

Mutations in BSS may be missense, nonsense, frameshift, insertions or deletions, and these mutations can cause abnormality in GPIB $\alpha$  protein expression (18,19). The dominant inheritance of BSS remains relatively rare as only six variants have been previously identified, including the Bolzano variant (p. Ala172Val), which is the most frequent type in Italy (12). The remaining four heterozygous mutations were described in single families (6-12).

The phenotype of monoallelic BSS, which is the same as that of the biallelic BSS in the degree of symptom presentation,

may vary based on different genotypes and relevant changes in the expression and function of GPIB $\alpha$  (2). Mutations in the patient outlined in the current case report and her father were located in the conserved N-terminal flanking domain. The domain lies ahead of the LRR region of GP Ib $\alpha$ , which serves a role in the orientation of charged residues (6). All previously reported variants (p. Ala172Val, p. Asn57His, p. Tyr70Asp, p. Leu73Phe, p. Asn150Ser and p. Leu59Arg), which are located in the LRR region (amino acids 35-200), may lead to macrothrombocytopenia. This is due to the abnormal interaction of the cytoplasmic end of GPIB $\alpha$  protein with the actin-binding protein, which controls the normal process of megakaryocyte maturation, demarcation membrane system production and the size of the platelets (20,21). While the conserved N-terminal flanking region of GPIB $\alpha$ , where the novel mutation was discovered in the pedigree outlined the present study, may

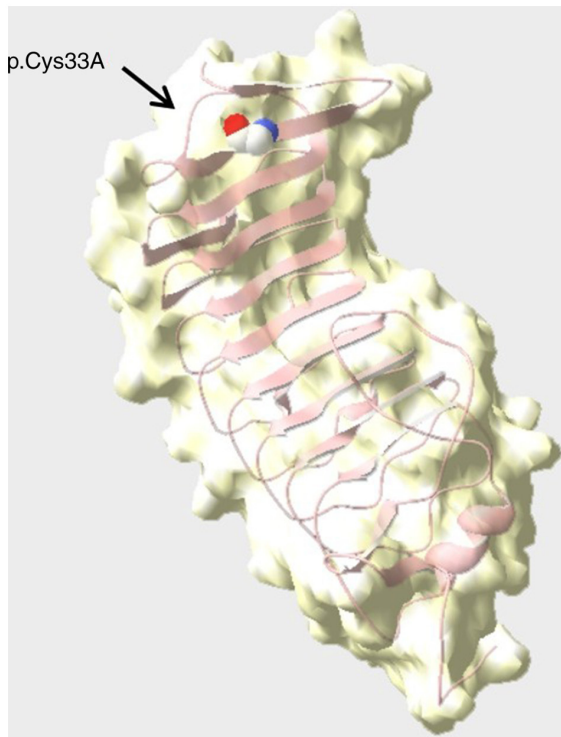


Figure 3. Crystal structure of the human N-terminal domain (~300 aa) of GPIb $\alpha$ . Cys33 of our patient was presented by colored spheres in the conserved N-terminal flank (amino acid 1-35), which had a role in binding to von Willebrand factor. GP, glycoprotein.

interact with C-terminal flanking (amino acid 201-268) and exhibit a weak influence on the binding of GPIb $\alpha$  to vWF that is induced by ristocetin or botrocetin, the mutations within the LRR caused a more significant change in the formation of GPIb $\alpha$  as well as a pronounced disturbance in ligand binding (22).

BSS is commonly misdiagnosed with ITP and is subsequently treated with futile therapies, including glucocorticoids and immunoglobulins (14). BSS is a rare bleeding disorder that is accompanied by thrombocytopenia, and symptoms are less pronounced in the monoallelic phenotype of the disease (6,8). BSS shares similar clinical characteristics with ITP, such as mucocutaneous bleeding, negative family history and normal platelet aggregation (14). However, the identification of giant platelets in a peripheral blood smear may help clinicians make an accurate diagnosis. In the current case report, the patient and her father shared the same mutation and similar mild manifestation. Her mother carried a wild-type genotype and did not exhibit macrothrombocytopenia and bleeding. For those suspected of having BSS, gene sequencing should be performed, and symptoms such as abnormal levels of bleeding should be investigated throughout the family to encourage early diagnosis and subsequently, the establishment of effective treatment.

In the present study, platelet immunophenotype and vWF-cofactor activity analysis (binding of vWF to recombinant mutated GPIb) could not be performed. Therefore, whether this novel dominant variant contributes to the reduced expression of GPIb-V-IX and whether the inactive interaction between platelets and vWF was indicated, which is commonly

identified in classic BSS, was not confirmed. Identification of the effect of specific mutations on the structure and function of GPIb $\alpha$  protein and the pathogenesis to a milder phenotype is required in future studies.

A novel autosomal dominant inheritance mutation in GPIBA was identified in a family with mild bleeding symptoms and macrothrombocytopenia. This monoallelic mutation that occurs in the N-terminal flanking domain has, to the best of our knowledge, not been previously reported. Due to common misdiagnosis, gene sequencing is considered essential and urgent for diagnosing suspected patients who exhibit a blood smear showing giant platelets, with BSS.

### Acknowledgements

The authors would like to thank Dr Lulu Mao and Mr. Xinwen Fu from MyGenostics, Inc. for technical support in NGS work and drawing the crystal structure.

### Funding

The present study was supported by the National Natural Science Foundation of China (grant no. 81970111), the Beijing Natural Science Foundation of China (grant no. 7192064), the Pediatric Medical Coordinated Development Center of Beijing Municipal Administration of Hospitals (grant no. XTZD20180205) and the National Science and Technology Key Projects (grant no. 2017ZX09304029004).

### Availability of data and material

The datasets used and/or analyzed during the current study are available from the corresponding author on reasonable request.

### Authors' contributions

JM was involved in the collection and critical analysis of clinical data and wrote the manuscript. RW contributed to the designing the study, supervision and critical review of the manuscript. ZC contributed to the supervision and critical analysis of laboratory data, including the interpretation of NGS results. GL performed the platelet aggregation. HG was involved in the collection and sorting of the clinical data. RW and ZC confirmed the authenticity of all the raw data. All authors read and approved the final manuscript.

### Ethics approval and consent to participate

The present study was approved by the Ethics Committee of Beijing Children's Hospital (Beijing, China; reference no. 2020-Z-113) and written consent from the patient's parents was obtained.

### Patient consent for publication

The patient's parents have provided consent for publication.

### Competing interests

The authors declare that they have no competing interests.

## References

- López JA, Andrews RK, Afshar-Kharghan V and Berndt MC: Bernard-Soulier syndrome. *Blood* 91: 4397-4418, 1998.
- Savoia A, Pastore A, De Rocco D, Civaschi E, Di Stazio M, Bottega R, Melazzini F, Bozzi V, Pecci A, Magrin S, *et al*: Clinical and genetic aspects of Bernard-Soulier syndrome: Searching for genotype/phenotype correlations. *Haematologica* 96: 417-423, 2011.
- Andrews RK, Gardiner EE, Shen Y, Whisstock JC and Berndt MC: Glycoprotein Ib-IX-V. *Int J Biochem Cell Biol* 35: 1170-1174, 2003.
- Savoia A, Kunishima S, De Rocco D, Zieger B, Rand ML, Pujol-Moix N, Caliskan U, Tokgoz H, Pecci A, Noris P, *et al*: Spectrum of the mutations in Bernard-Soulier syndrome. *Hum Mutat* 35: 1033-1045, 2014.
- Othman M and Emsley J: Gene of the issue: GPIBA gene mutations associated with bleeding. *Platelets* 28: 832-836, 2017.
- Trizuljak J, Kozubík KS, Radová L, Pešová M, Pál K, Réblová K, Stehlíková O, Smejkal P, Závřelová J, Pacejka M, *et al*: A novel germline mutation in GPIBA gene N-terminal domain in monoallelic Bernard-Soulier syndrome. *Platelets* 29: 827-833, 2018.
- Ghalloussi D, Saut N, Bernot D, Pillois X, Rameau P, Sébahoun G, Alessi MC, Raslova H and Baccini V: A new heterozygous mutation in GPIBA gene responsible for macrothrombocytopenia. *Br J Haematol* 183: 503-506, 2018.
- Noris P, Perrotta S, Bottega R, Pecci A, Melazzini F, Civaschi E, Russo S, Magrin S, Loffredo G, Di Salvo V, *et al*: Clinical and laboratory features of 103 patients from 42 Italian families with inherited thrombocytopenia derived from the monoallelic Ala156Val mutation of GPIb $\alpha$  (Bolzano mutation). *Haematologica* 97: 82-88, 2012.
- Vettore S, Scandellari R, Moro S, Lombardi AM, Scapin M, Randi ML and Fabris F: Novel point mutation in a leucine-rich repeat of the GPIB $\alpha$  chain of the platelet von Willebrand factor receptor, GPIb/IX/V, resulting in an inherited dominant form of Bernard-Soulier syndrome affecting two unrelated families: The N41H variant. *Haematologica* 93: 1743-1747, 2008.
- Kunishima S, Imai T, Hamaguchi M and Saito H: Novel heterozygous missense mutation in the second leucine rich repeat of GPIB $\alpha$  affects GPIb/IX/V expression and results in macrothrombocytopenia in a patient initially misdiagnosed with idiopathic thrombocytopenic purpura. *Eur J Haematol* 76: 348-355, 2006.
- Miller JL, Lyle VA and Cunningham D: Mutation of leucine-57 to phenylalanine in a platelet glycoprotein Ib alpha leucine tandem repeat occurring in patients with an autosomal dominant variant of Bernard-Soulier disease. *Blood* 79: 439-446, 1992.
- Savoia A, Balduini CL, Savino M, Noris P, Del Vecchio M, Perrotta S, Belletti S, Poggi and Iolascon A: Autosomal dominant macrothrombocytopenia in Italy is most frequently a type of heterozygous Bernard-Soulier syndrome. *Blood* 97: 1330-1335, 2001.
- Balduini CL, Savoia A and Seri M: Inherited thrombocytopenias frequently diagnosed in adults. *J Thromb Haemost* 11: 1006-1019, 2013.
- Reisi N: Bernard-Soulier syndrome or idiopathic thrombocytopenic purpura: A case series. *Caspian J Intern Med* 11: 105-109, 2020.
- Richards S, Aziz N, Bale S, Bick D, Das S, Gastier-Foster J, Grody WW, Hegde M, Lyon E, Spector E, *et al*: Standards and guidelines for the interpretation of sequence variants: A joint consensus recommendation of the American College of Medical Genetics and Genomics and the Association for Molecular Pathology. *Genet Med* 17: 405-424, 2015.
- Wang K, Li M and Hakonarson H: ANNOVAR: Functional annotation of genetic variants from high-throughput sequencing data. *Nucleic Acids Res* 38: e164, 2010.
- Proulle V, Strassel C, Perrault C, Baas MJ, Moog S, Mangin P, Nurden P, Nurden A, Adam F, Bryckaert M, *et al*: A novel missense mutation in a leucine-rich repeat of GPIb $\alpha$  in a Bernard-Soulier variant reduces shear-dependent adherence on von Willebrand factor. *Br J Haematol* 186: e184-e187, 2019.
- Li R and Emsley J: The organizing principle of the platelet glycoprotein Ib-IX-V complex. *J Thromb Haemost* 11: 605-614, 2013.
- Simon D, Kunicki T and Nugent D: Platelet function defects. *Haemophilia* 14: 1240-1249, 2010.
- López JA: The platelet glycoprotein Ib-IX complex. *Blood Coagul Fibrinolysis* 5: 97-119, 1994.
- Mhaweck P and Saleem A: Inherited giant platelet disorders. Classification and literature review. *Am J Clin Pathol* 113: 176-190, 2000.
- Cauwenberghs N, Vanhoorelbeke K, Vauterin S and Deckmyn H: Structural determinants within platelet glycoprotein Ib $\alpha$  involved in its binding to von Willebrand factor. *Platelets* 11: 373-378, 2000.



This work is licensed under a Creative Commons Attribution-NonCommercial-NoDerivatives 4.0 International (CC BY-NC-ND 4.0) License.