


**CASE REPORT**

# An inappropriate shock after reprogramming tachycardia zones

Rita Marinheiro MD<sup>1</sup>  | Leonor Parreira MD<sup>1</sup> | Pedro Amador MD<sup>1</sup> |  
 Dinis Mesquita MD<sup>1</sup> | Lurdes Almeida MD<sup>2</sup> | Ana Lousinha MD<sup>3</sup> | José Farinha MD<sup>1</sup> |  
 Marta Fonseca MD<sup>1</sup> | Ana Fátima Esteves MD<sup>1</sup> | Rui Caria MD<sup>1</sup>

<sup>1</sup>Centro Hospitalar de Setubal EPE, Setubal, Portugal

<sup>2</sup>Centro Hospitalar Barreiro-Montijo EPE, Barreiro, Portugal

<sup>3</sup>Centro Hospitalar Lisboa Central EPE, Lisboa, Portugal

**Correspondence**

Rita Marinheiro, Centro Hospitalar de Setubal EPE, Rua Camilo Castelo Branco 2910 - 446 Setubal, Portugal.  
 Email: Ritamarinheiro@gmail.com

**Abstract**

A patient with an implantable cardioverter-defibrillator (ICD) (Abbott®) had episodes of slow monomorphic ventricular tachycardia (VT) and his ICD was programmed with three tachycardia zones. During the follow-up, he received an inappropriate shock. Upon interrogation (of the device), trigeminal pattern binned as ventricular sensing (VS)–VS–ventricular fibrillation (VF) was detected. VF was assumed according to binning system. When VF is present, discrimination algorithms are not available and five consecutive sinus beats are necessary to reset binning system. Catheter ablation was performed to treat VT in order to reprogram tachycardia zones.

**KEYWORDS**

implantable cardioverter-defibrillator zones, inappropriate shock, slow ventricular tachycardia, trigeminy

## 1 | INTRODUCTION

Inappropriate shocks are deleterious and should be avoided whenever possible. Since slow ventricular tachycardia (VT) can occur, especially in patients taking anti-arrhythmic drugs, reprogramming tachycardia zones is not uncommon nowadays and one must be aware of the higher risk of inappropriate shocks when tachycardia zones are programmed in slower thresholds.

## 2 | CASE REPORT

A 72-year-old man with previous myocardial infarction and impaired left ventricular (LV) function underwent implantation of an implantable cardioverter-defibrillator (ICD) device (AnalyST Accel™ CD1219-36, Abbott®) for primary prevention of sudden cardiac death in 2006.

During the follow-up period, he received an appropriate shock for a monomorphic VT at a rate of 200 beats per minute (bpm). He

initiated therapy with amiodarone 200 mg once a day. In May 2018, he was observed for symptoms of heart failure (HF) and a slow VT at a rate of 145 beats per minute (bpm) was detected and converted to sinus rhythm with burst of anti-tachycardia pacing (ATP). The patient was proposed for VT ablation and the ICD was reprogrammed with three tachycardia zones (Table 1).

In July 2018, the patient was admitted to the hospital for acute HF. He described the sensation of a shock two weeks before. The tracing of the device interrogation of the episode (Figure 1) showed a trigeminal pattern binned as ventricular sensing (VS)–VS–VF that continued for 14 seconds and VF was detected (denoted by the "Trigger" annotation). Device assumes VF as cycle length was 316 ms; and after 12 intervals, a 36 joule (J) shock therapy was delivered ("HV" annotation) with conversion to ventricular pacing.

He underwent catheter ablation guided by substrate mapping (EnSite NavX, Abbott). Radiofrequency applications were performed at the borders of the posterior scar, in the channels within the scar and at sites with local electrograms showing diastolic potentials. The patient was discharged with amiodarone 200 mg once a day

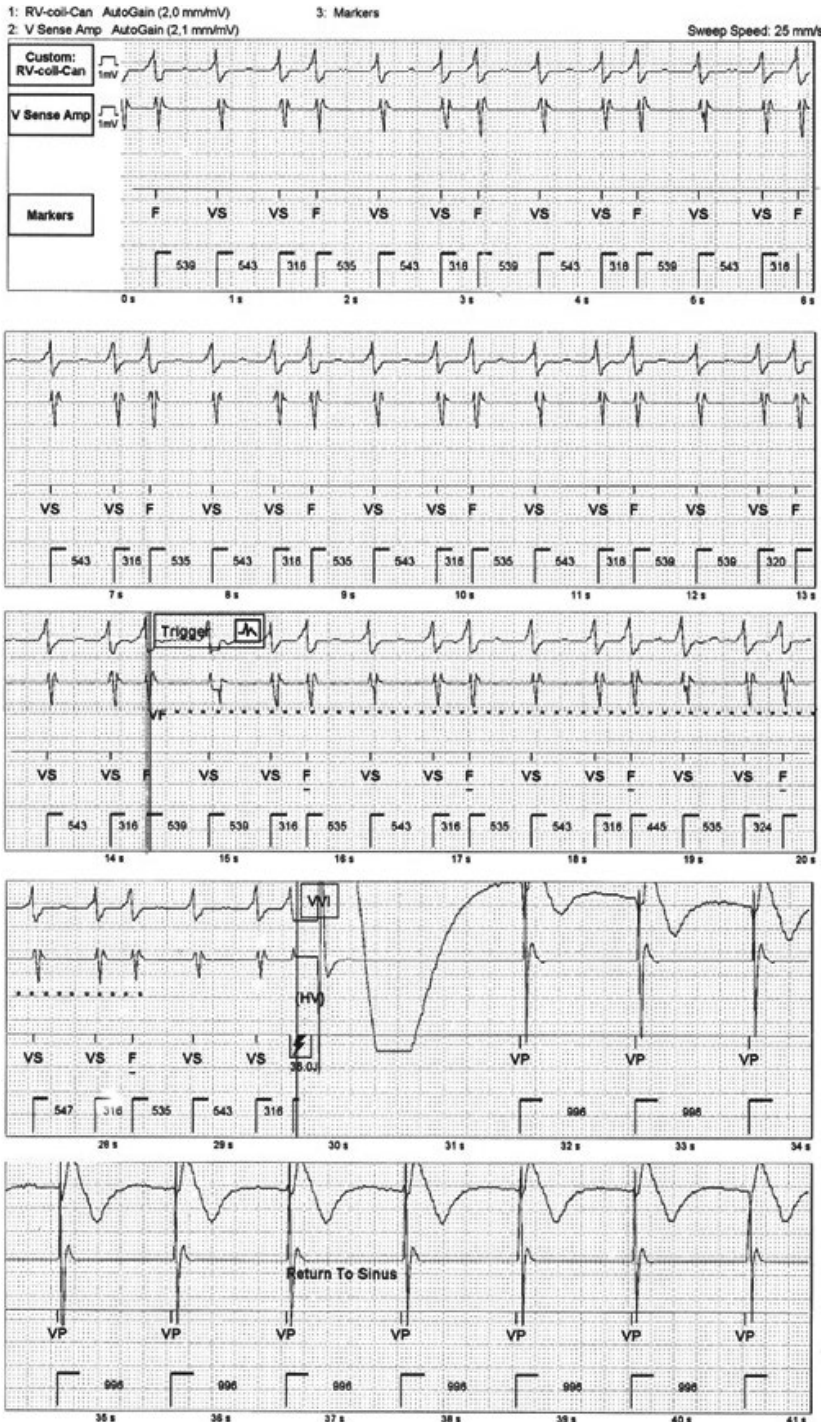
This is an open access article under the terms of the Creative Commons Attribution-NonCommercial License, which permits use, distribution and reproduction in any medium, provided the original work is properly cited and is not used for commercial purposes.

© 2019 The Authors. *Journal of Arrhythmia* published by John Wiley & Sons Australia, Ltd on behalf of the Japanese Heart Rhythm Society.

	VT-1	VT-2	VF
Detection criteria	HR 139-160 bpm (CL 430-375 ms)	HR 160-180 bpm (CL 375-330 ms)	HR ≥ 181 (CL < 330ms)
Number of recorder intervals	20	20	12
Therapy	ATP + shock	ATP + shock	Shock (36J)
SVT discriminators were programmed "ON" using the nominal settings: sudden onset and stability criterion (variability < 80 ms); morphology criterion was "OFF."			

Abbreviations: ATP, anti-tachycardia pacing; bpm, beats per minute; CL, cycle length; HR, heart rate; SVT, supra-ventricular tachycardia; VF, ventricular fibrillation; VT, ventricular tachycardia.

**TABLE 1** Tachycardia ICD parameters programmed after the detection of a slow ventricular tachycardia



**FIGURE 1** In each of five panels are shown the bipolar electrograms (EGMs) from the lead tip, the far field unipolar EGM from the lead tip to can, the marker channels and timing in seconds (s) (from top to bottom). The upper three and the beginning of the fourth panel show stored EGMs from the device preceding ventricular fibrillation (VF) detection. At 14 s (point marked by "Trigger"), VF is detected and charging begins. The fourth panel shows a 36 J shock therapy following which ventricular pacing begins. In the marker channel, VS, VF and VP correspond to ventricular sensing, ventricular fibrillation and ventricular pacing, respectively

and bisoprolol 5 mg once a day and tachycardia zones were reprogrammed: VF at a HR  $\geq$  206 bpm (CL 290 ms), VT-2 at HR between 160 and 206 bpm (CL 375–290 ms) and a slow VT-1 zone as a monitoring zone between 148 and 160 bpm (CL 405–375 ms). Tachycardia was diagnosed once 16, 12 and 20 recorded intervals were within VF, VT-2 and VT-1, respectively. After 6 months of follow-up, the patient remains in NHYA class II and no VT/VF were detected or ICD therapies were performed.

### 3 | DISCUSSION

We present a case of an inappropriate shock due to trigeminy. The real-time intracardiac EGM demonstrate that trigeminy (a sequence repetitiously of two normal beats and one premature beat) was interpreted as VF due to Abbott binning system<sup>1</sup>. Morphology of the premature beat in the RV-Coil-Can was similar to the sinus rhythm and compensatory pause is not complete, suggesting that it was probably a premature atrial contraction. Binning system essentially considers two features, namely: the current interval and an interval average. The current interval measures the time in milliseconds between any two sensed events. The interval average is defined as the mean of the current and the three prior intervals (ie, four most recent intervals). When current and average intervals are the same, the interval is binned in the corresponding zone. When they are classified differently, the interval is binned in the faster zone. Once a sufficient number of intervals are binned, detection is satisfied. Counters can be reset if sinus rhythm is redetected, but nominally, five sinus intervals must be binned for redetection (although this is a programmable feature that can range from three to seven). It is important to note that to satisfy tachycardia criteria, binned intervals need not be consecutive, so long as a sinus rhythm is not re-established.<sup>1,2</sup> In this case, a premature beat was classified as VF since CL was 316 ms (current interval). The running average of the previous four CL was 428 ms (interval average) classified as VT-1 so, according to the binning system, the interval was binned in the faster zone: VF. As the trigeminal rhythm was sustained, the patient did not have five consecutive sinus beats to reset the counter and after binned 12 intervals, the ICD assumed the episode as VF and a shock was delivered. Abbott's ICDs have a "Bigeminal Avoidance" counter that prevents bigeminal rhythms from being classified as tachycardia and also includes SVT discriminators.<sup>3</sup> However, this feature is only applied in the slowest detection zone (VT-1), so it did not come into play in this situation.

Strategies to prevent inappropriate shocks include programming the tachycardia detection zones to a higher threshold<sup>4</sup> or using only

two tachycardia zones with a higher cutoff of VF zone. In a previous reported case with an inappropriate shock due to trigeminy, the authors removed VT detection zones.<sup>5</sup> In fact, we are aware that the cutoff rate for VF detection was very low and hence the premature beat was classified in the VF zone. However, since our patient had slow VT with hemodynamic compromise, a slow VT zone (VT-1) was programmed to detect these episodes. Removing VT-1 detection zone could not have been enough to avoid inappropriate shock since premature beat was in FV zone. Even if the cutoff of VF detection was higher, the premature beat would have been classified as VT-2 and inappropriate therapy would probably have been delivered as well since SVT discriminators are only applies in VT-1 zone. By ablating the slow VT, we were able to remove the VT-1 zone and to redefine a higher threshold for VF zone, allowing the bigeminal avoidance algorithm to apply in the VT zone. Although within only 6 months of follow-up, there have been no inappropriate detections or therapies.

### CONFLICT OF INTEREST

Authors declare no conflict of interests for this article.

### ORCID

Rita Marinheiro  <https://orcid.org/0000-0003-1576-812X>

### REFERENCES

1. Al-Ahmad A, Ellenbogen K, Natale A, Wang P. Pacemakers and Implantable Cardioverter Defibrillators: An Expert's Manual. Cardiotext. Minneapolis, Minnesota, 2010. Canada.
2. Mansour F, Khairy P. ICD monitoring zones: intricacies, pitfalls, and programming tips. *J Cardiovasc Electrophysiol*. 2008;19(5):568–74.
3. Reference Manual for Model CD1219-36q Software for AnalySTAccel™ VR. St Jude Medical, Cardiac Rhythm Management Division. 2006;4–5.
4. Mansour F, Thibault B, Dubuc M, Guerra Pg, Macle L, Brugada R, et al. Shocking truths about implantable cardioverter defibrillator monitoring zones. *Pacing Clin Electrophysiol*. 2007;30(9):1146–8.
5. Nair K, Selvaraj R, Chauhan V. Defibrillator shock due to ventricular trigeminy. *Europace*. 2009;11(3):374–5.

**How to cite this article:** Marinheiro R, Parreira L, Amador P, et al. An inappropriate shock after reprogramming tachycardia zones. *J Arrhythmia*. 2019;35:679–681. <https://doi.org/10.1002/joa3.12212>