

ORIGINAL RESEARCH ARTICLE

Needlescopic versus conventional laparoscopic surgery for colorectal cancer ~a comparative study~

Masashi Tsuruta¹⁾, Hirotooshi Hasegawa¹⁾, Koji Okabayashi¹⁾, Kohei Shigeta¹⁾,
Takashi Ishida¹⁾, Masashi Yahagi²⁾, Yoshiyuki Ishii²⁾³⁾ and Yuko Kitagawa¹⁾

1) Department of Surgery, Keio University School of Medicine

2) Department of Surgery, Kitasato University Kitasato Institute Hospital

3) Department of Surgery, Kitasato University School of Medicine

Abstract:

Objectives: This study set out to determine whether Needlescopic surgery (NS) produces comparable surgical outcomes for patients with colorectal cancer (CRC) compared to conventional multi-port laparoscopic surgery (MPS). **Methods:** We used the five-port method with a 3.5 cm umbilical incision for extraction and reconstruction during MPS for CRC. One or two 5 mm ports were exchanged for needle forceps and all surgical procedures were as for previous MPS since July 2012. We investigated the short-term outcomes of 138 consecutive patients who underwent curative resection of CRC by NS (July 2012-August 2014) and 130 consecutive patients with CRC treated with MPS during a previous period (January 2010-June 2012). **Results:** Operative time in the NS group was comparable to that of MPS ($p=0.467$); the NS group had significantly less estimated blood loss ($p=0.002$) and a shorter postoperative hospital stay ($p<0.001$). The mean number of dissected lymph nodes was 27 in both groups ($p=0.730$). No mortality occurred in either group, and similar morbidity rates were observed ($p=0.454$). **Conclusions:** NS using Endo Relief needle forceps is a safe and feasible option compared to conventional MPS for CRC.

Keywords:

needlescopic surgery, colorectal cancer, laparoscopic surgery

J Anus Rectum Colon 2017; 1(2): 45-49

Introduction

Laparoscopic surgery (LS) has been established as a feasible strategy for colorectal cancer (CRC) because it preserves oncological outcome, is less invasive, and allows a better quality of life for patients compared to open surgery¹⁻⁴⁾. Moreover, reduced port surgery (RPS) and single port laparoscopic surgery (SILS) are less invasive and give better cosmetic results⁵⁻⁷⁾. Natural orifice transluminal endoscopic surgery is considered even less invasive and satisfactory results were reported in colorectal surgery^{8,9)}. However, technical, ethical, and oncological problems limit its clinical adoption.

The short-term outcomes of RPS and SILS for CRC are comparable to that of conventional multi-port LS (MPS)¹⁰⁻¹³⁾; however, one study suggested there is no advantage beyond

MPS¹⁴⁾. In addition, quite a few studies have reported the long-term oncological outcomes in SILS^{15,16)}. Furthermore, RPS or SILS is normally performed by a single surgeon with no requirement for an assistant, except a laparoscopist; so they are often not part of the education of novice surgeons. Their dichotomous nature makes them unpopular and they not used as alternatives to conventional MPS for CRC.

Needlescopic surgery (NS) was first reported in 1998¹⁷⁾ for a cholecystectomy, and was defined as LS using at least one port <3 mm diameter, which is included RPS by reduction of port size. Since then, NS has been utilized for several procedures¹⁸⁻²¹⁾. However, few studies have reported use of NS for CRC^{22,23)}. In our institution, Endo Relief needle forceps (Hope Denshi, Chiba, Japan) were introduced for MPS in July 2012 because they are less invasive and maintain surgical quality. The Endo Relief needle forceps have a

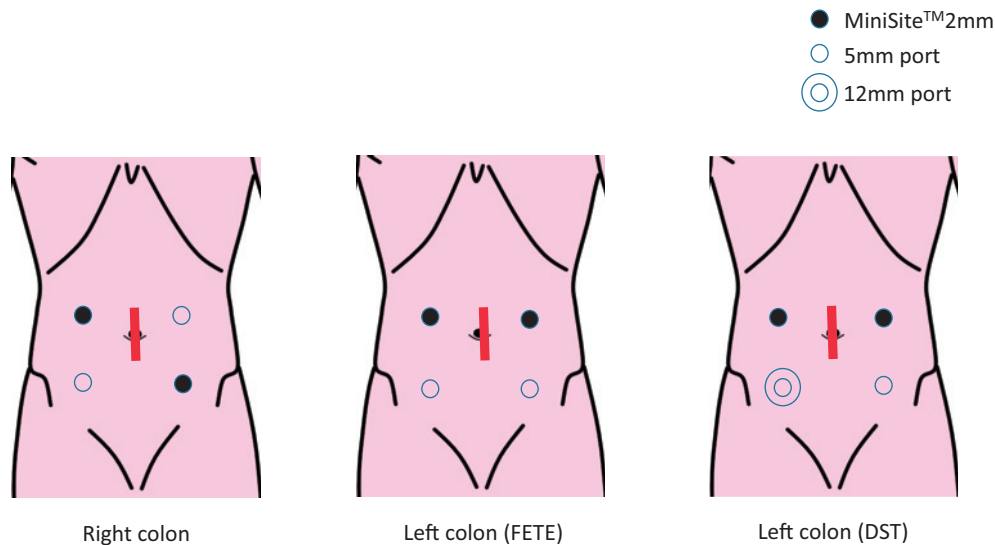


Figure 1. Port site placement for the five-port method

A 5 mm port near the surgeon's left hand was replaced by mini ports for the Endo Relief needle forceps. If possible, the assistant used one pair of Endo Relief forceps.

FETE: Functional end-to-end anastomosis

DST: Double stapling technique

2.4-mm-diameter shaft with the same shape, size, and tip as conventional 5 mm forceps. The handling and maneuverability of the Endo Relief needle forceps are similar to those of conventional 5 mm forceps. This study assessed the feasibility of NS using Endo Relief needle forceps for CRC in terms of short-term outcomes.

Methods

Patients

Since the introduction of the Endo Relief needle forceps in July 2012, 138 patients have undergone curative resection of CRC by NS (NS group). We excluded patients with double cancers, ulcerative colitis-related cancer, and those requiring other concomitant surgeries, including those related to the stoma, from this study. Consecutive patients with CRC who underwent conventional LS before NS was introduced served as a historical control group (MPS group), and the clinicopathological findings and short-term outcomes of both groups were compared retrospectively. This study was approved by the Ethics Review Board (No. 20140457) at our institute.

Endo Relief needle forceps

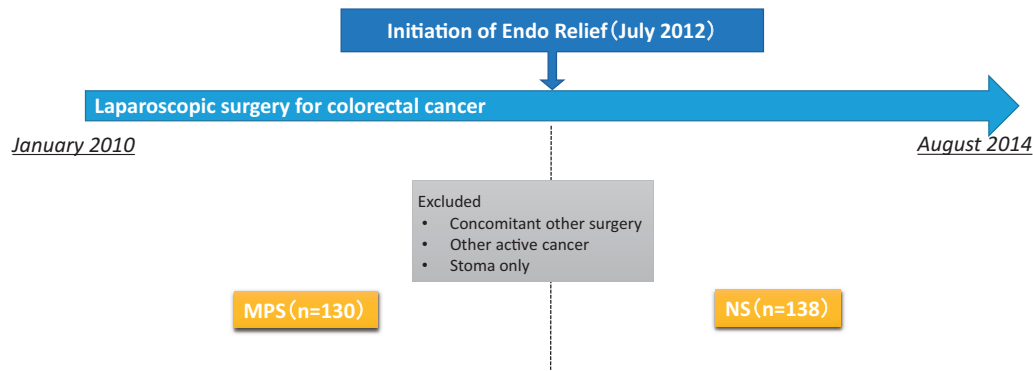
We initiated NS using the Endo Relief needle forceps to improve cosmetic outcomes and be less invasive. The Endo Relief needle forceps have a 2.4-mm-diameter shaft of identical shape, size, and tip as conventional 5 mm forceps. The benefits of these features include an atraumatic tip and powerful grasping of tissue, which are shared by conventional 5 mm forceps.

We usually used the MiniSite™ 2 mm (Covidien Group

Japan, Tokyo, Japan) as a trocar for the Endo Relief needle forceps. Since the tip (5 mm) was unable to pass through the trocar, the handle was connected to the shaft and tip, which was inserted from the other 5 mm port or a 12 mm port, as exchanging forceps during the procedure is difficult.

Surgical procedure

A five-port technique was used (Figure 1). The Endo Relief forceps were used with the surgeon's left hand or either hand of the assistant, if possible, because they did not need to be exchanged. A 3.5 mm sagittal transumbilical incision was made initially with E·Z Access and the LAP PROTECTOR™ (FF0504; Hakko, Nagano, Japan), and pneumoperitoneum was established through the camera port. After the appropriate bowel segment was mobilized fully, the vascular supply was divided intracorporeally at its origin, and a radical lymphadenectomy was performed. The bowel was delivered through the umbilical incision, which was extended if necessary, and divided extracorporeally. A functional end-to-end anastomosis was fashioned using a linear stapler for all cases, except those with rectosigmoid tumors. In these cases, the distal rectum was divided intracorporeally using a laparoscopic linear stapler following intracorporeal division of the inferior mesenteric vessels, and the proximal end of the bowel was delivered through the umbilical incision. The bowel was resected extracorporeally, after which an anvil was placed in the proximal colon, and an anastomosis was performed intracorporeally using the double-stapling technique. All surgeries were performed or assisted by one of four fully experienced laparoscopic colorectal surgeons certified by the Japanese Society for Endoscopic Surgery.

**Figure 2.** Consort diagram

MPS: multiport laparoscopic surgery

NS: needlescopic surgery

Table 1. Patient Background

	MPS (n=130)	NS (n=138)	P value
Age	68 (31-93)	70 (37-96)	0.222
Sex (M:F)	78:52	59:79	<0.001
BMI	22.7 (14.8-37.9)	22.4 (15.1-32.7)	0.185
PS (0:1:2:3)	70:49:10:1	80:48:9:1	0.709
ASA (1:2:3)	53:76:13	46:80:12	0.510
Past-laparotomy	45 (34.6%)	41 (29.7%)	0.171
Tumor location (colon:rectum)	105:25	109:29	0.408
T1:T2-4	33:97	46:92	0.047
Tumor size (cm)	3.5 (0.7-8.0)	3.1 (0.4-9.0)	0.922

BMI: body mass index

PS: performance status

ASA: American Society of Anesthesiologists

MPS: multiport laparoscopic surgery

NS: needlescopic surgery

Table 2. Surgical Outcomes

	MPS (n=130)	NS (n=138)	P value
Operative time (min)	270 (142-460)	265 (147-560)	0.467
Estimated blood loss (g)	10 (10-820)	10 (5-440)	0.002
Postoperative stay (day)	9 (5-67)	8 (5-47)	<0.001
Conversion	8 (6.2%)	0 (0%)	-
Harvested lymph nodes	27 (2-84)	27 (5-47)	0.730
Complication	13 (10.0%)	15 (10.8%)	0.454
Wound infection	2	3	
Small bowel obstruction	7	2	
Anastomotic leakage	2	1	
Lymphorrhea	0	2	
Abscess	2	1	
Others	0	6	

MPS: multiport laparoscopic surgery

NS: needlescopic surgery

Data collection

Patient data were collected from medical records retrospectively; these included sex, body mass index (BMI), Performance Status, American Society of Anesthesiologists score, tumor location, International Union against Cancer T stage, history of laparotomy, operation time, estimated blood loss, number of harvested lymph nodes, postoperative complications, mortality, and length of postoperative hospital stay. All parameters are described as medians (range) without annotation. Quantitative data was compared using the Wilcoxon test and qualitative variables the chi-square test. A p-value <0.05 was considered to indicate significance. The statistical analysis was performed using R ver. 2.15.2.

Results

There were 138 patients in the NS group, and 130 patients in the MPS group (Figure 2). Table 1 shows their preoperative clinicopathological characteristics. The NS group included more female patients and advanced tumors ($\geq T2$), whereas no significant difference was observed in the other

parameters. Operative time was comparable in both groups (MPS vs. NS: 270 vs. 65 min, $p=0.467$). Significantly less estimated blood loss (10 vs. 10, $p=0.002$) and shorter postoperative stays ($p<0.001$) were observed in the NS group (Table 2). There was no mortality in either group. No patients underwent conversion in the NS group, whereas eight patients (6.2%) in the MPS group underwent conversion. The median number of harvested lymph nodes was 27 in both groups. Complications were observed in approximately 10% of the patients in each group. One patient in the MPS group with anastomotic leakage required reoperation due to a stoma; otherwise, no other patient had severe complications.

Discussion

Compared to open surgery, LS, which uses an incision less than one-fourth the size, achieved adequate lymphadenectomy, as well as mobilization, excision, and reconstruction of the colon, and conferred a dramatic change in the history of surgery for CRC. Moreover, RPS is expected to be less invasive and produce better cosmetic outcomes

than LS due to the smaller incision in the abdominal wall. However, having fewer ports interferes with mobilizing the forceps, leading to less effective counter traction and visualization. The better cosmetic outcomes and reduced invasiveness could come at the cost of reduced quality of surgery and poorer oncological outcome. For this reason, considerable attention should be paid to the indications.

Needlescopic surgery, which is also included in RPS, is defined as using at least one needle-sized port (<3 mm) during LS¹⁷. The needle forceps produced by Karl Storz are used worldwide, although their small tip size results in a higher risk of injury to other internal organs²⁴. The Endo Relief needle forceps have a tip of the same size as conventional 5 mm forceps and can be used comfortably by any surgeon. However, there are some disadvantages; i.e., shaft rigidity and the inability to exchange instruments. Although the low shaft stiffness is expected to be overcome by innovation and new technology, we suggest that “cross-traction” could mitigate this fault instead of using conventional counter traction (Supplemental Figure 1). Visualizing deeper areas in the pelvis in cases of obesity or a narrow pelvis can be problematic. Since the edge of the inlet of the pelvis bends the shaft, the tip should be uncontrolled and traction is insufficient, which cause worse visualization consequently. However, the rigidity of the shaft should be minimally affected if the power is applied in the longitudinal direction of the shaft, by which effective traction could make surgical field open. We also anticipate that Endo Relief needle forceps will be used in the surgeon’s left hand, causing minimal inconvenience because the forceps are often exchanged to energy devices in the right hand.

Our findings revealed that NS with the Endo Relief needle forceps had comparable short-term surgical outcomes to those of conventional MPS for CRC. Although detecting a large difference may be difficult due to the reduced size of ports (from 5 to 2.4 mm), it is not necessary to suture the skin with needle forceps. Suturing a wound, even with a 5 mm port, occasionally causes chronic pain, wound infection, and keloid. Moreover, the small additional effort required to provide better cosmetic outcomes and reduced invasiveness could lead to widespread adoption of NS.

In this series, the MPS group contained more patients with advanced CRC, which may have resulted in the worse estimated blood loss, postoperative stay, and conversion rate. However, no difference was observed in tumor size or the rectal cancer ratio, so these factors may not have had an impact. Historical factors, in which LS was attempting to use for patients with advanced CRC in this objective period, may be the reason for the high conversion rate during MPS.

Better visualization during LS initiated another era in colorectal surgery, particularly regarding the pelvic anatomy. In addition, all staff members involved can see the same operative field, and all surgical procedures are easily recorded. Consequently, education should improve and the learning curve should become less steep. Although RPS may have benefits, such as using fewer ports, and faults, such as tech-

nical difficulty, our method is basically identical to conventional LS for all surgical procedures. Thus, NS shows promise for the future.

Some limitations of our study should be discussed. First, this was a retrospective study with a small sample size. More robust evidence from a well-planned prospective study, which is well designed by statistical power analysis, is required. The second limitation was selection bias. The low rigidity of the Endo Relief shaft decreases its longevity and it is not indicated for severely obese patients (BMI \geq 30). A more durable shaft is desired. Third, the impact in terms of improved cosmetic outcomes and reduced invasiveness of the needle forceps on the long-term results is unknown. Forth, this study evaluated only short-term outcome. The oncological outcome is more important than less-invasiveness or better cosmetics. Less size of port might contribute to reduction of port site recurrence, however further study is needed for evaluating long-term outcome.

Collectively, Needlescopic surgery with Endo Relief needle forceps may be feasible for CRC, as the quality of the LS surgery was preserved, it was less invasive, and produced a better cosmetic result. Further prospective randomized studies are required to confirm the long-term oncological outcomes and patient satisfaction.

Acknowledgement: The English in this document has been checked by at least two professional editors, both native speakers of English. For a certificate, please see: <http://www.textcheck.com/certificate/RCNT2b>

Conflicts of Interest

There are no conflicts of interest.

References

1. Biondi A, Grosso G, Mistretta A, et al. (2013) Laparoscopic-assisted versus open surgery for colorectal cancer: Short- and long-term outcomes comparison. *Laparoendosc Adv Surg Tech A*. 2013 Jan; 23(1): 1-7.
2. Braga M, Vignali A, Gianotti L, et al. Laparoscopic versus open colorectal surgery: A randomized trial on short-term outcome. *Ann Surg*. 2002 Dec; 236(6): 759-66.
3. Guillou PJ, Quirke P, Thorpe H, et al. Short-term endpoints of conventional versus laparoscopic-assisted surgery in patients with colorectal cancer (MRC CLASICC trial): multicentre, randomised controlled trial. *Lancet*. 2005 May; 14-20; 365(9472): 1718-26.
4. Weeks JC, Nelson H, Gelber S, et al. Short-term quality-of-life outcomes following laparoscopic-assisted colectomy vs open colectomy for colon cancer: a randomized trial. *JAMA*. 2002 Jan 16; 287 (3): 321-8.
5. Baig MN, Mofteh M, Deasy J, et al. Implementation and usefulness of single-access laparoscopic segmental and total colectomy. *Colorectal Dis*. 2012 Oct; 14(10): 1267-75.
6. Chambers WM, Bicsak M, Lamparelli M, et al. Single-incision laparoscopic surgery (SILS) in complex colorectal surgery: a technique offering potential and not just cosmesis. *Colorectal Dis*. 2011 Apr; 13(4): 393-8.
7. Poon JT, Cheung CW, Fan JK, et al. Single-incision versus conventional laparoscopic colectomy for colonic neoplasm: A random-

- ized, controlled trial. *Surg Endosc.* 2012 Oct; 26(10): 2729-34.
8. Leung AL, Cheung HY, Li MK. Advances in laparoscopic colorectal surgery: A review on NOTES and transanal extraction of specimen. *Asian J Endosc Surg.* 2014 Jan; 7(1): 11-6.
 9. Emhoff IA, Lee GC, Sylla P. Transanal colorectal resection using natural orifice transluminal endoscopic surgery (NOTES). *Dig Endosc.* 2014 Jan; 26 Suppl 1: 29-42.
 10. Mufty H, Hillewaere S, Appeltans B, et al. Single-incision right hemicolectomy for malignancy: A feasible technique with standard laparoscopic instrumentation. *Colorectal Dis.* 2012 Nov; 14(11): e764-70.
 11. Makino T, Milsom JW, Lee SW. Feasibility and safety of single-incision laparoscopic colectomy: A systematic review. *Ann Surg.* 2012 Apr; 255(4): 667-76.
 12. Fujii S, Watanabe K, Ota M, et al. Single-incision laparoscopic surgery using colon-lifting technique for colorectal cancer: A matched case-control comparison with standard multiport laparoscopic surgery in terms of short-term results and access instrument cost. *Surg Endosc.* 2012 May; 26(5): 1403-11.
 13. Hasegawa F, Kawamura YJ, Sasaki J, et al. Oncological 3-port laparoscopic colectomy by 1 surgeon and 1 camera operator: A preliminary report. *Surg Laparosc Endosc Percutan Tech.* 2013 Apr; 23(2): 176-9.
 14. Curro G, Cogliandolo A, Lazzara S, et al. Single-incision versus three-port conventional laparoscopic right hemicolectomy: Is there any real need to go single? *J Laparoendosc Adv Surg Tech A.* 2012 Sep; 22(7): 621-4.
 15. Wang Y, Liu R, Zhang Z, et al. A safety study of transumbilical single incision versus conventional laparoscopic surgery for colorectal cancer: Study protocol for a randomized controlled trial. *Trials.* 2015 Nov; 16: 539.
 16. Marks JH, Montenegro GA, Shields MV, et al. Single-port laparoscopic colorectal surgery shows equivalent or better outcomes to standard laparoscopic surgery: Results of a 190-patient, 7-criterion case-match study. *Surg Endosc.* 2015 Jun; 29(6): 1492-9.
 17. Gagner M, Garcia-Ruiz A. Technical aspects of minimally invasive abdominal surgery performed with needlescopic instruments. *Surg Laparosc Endosc.* 1998 Jun; 8(3): 171-9.
 18. Soble JJ, Gill IS. Needlescopic urology: Incorporating 2-mm instruments in laparoscopic surgery. *Urology* 1998 Aug; 52(2): 187-94.
 19. Ferzli G, Sayad P, Nabagiez J. Needlescopic extraperitoneal repair of inguinal hernias. *Surg Endosc.* 1999 Aug; 13(8): 822-3.
 20. Yim AP, Liu HP, Lee TW, et al. 'Needlescopic' video-assisted thoracic surgery for palmar hyperhidrosis. *Eur J Cardiothorac Surg.* 2000 Jun; 17(6): 697-701.
 21. Chock A, Seslar S, Stoopan E, et al. Needlescopic appendectomy. *Surg Endosc.* 2003 Sep; 17: 1451-1453.
 22. Chiasson PM, Pace DE, Mustard RA, et al. "Needlescopic" sigmoid resection. *Surg Endosc.* 2002 Apr; 16(4): 715.
 23. Mamazza J, Schlachta CM, Seshadri PA, et al. Needlescopic surgery. A logical evolution from conventional laparoscopic surgery. *Surg Endosc.* 2001 Oct; 15(10): 1208-12.
 24. Mukai T, Fukunaga Y, Ueno M, et al. Needlescopic surgery for left-sided colorectal cancer. *Int J Colorectal Dis.* 2014 Dec; 29(12): 1501-5.

Journal of the Anus, Rectum and Colon is an Open Access article distributed under the Creative Commons Attribution-NonCommercial-NoDerivatives 4.0 International License. To view the details of this license, please visit (<https://creativecommons.org/licenses/by-nc-nd/4.0/>).