



Acquired factor V inhibitor with erythema and eosinophilia in a patient with end-stage renal disease

Eisuke Katsuren¹ · Kentaro Kohagura² · Takanori Kinjyo¹ · Ryo Zamami^{1,2} · Takuto Nakamura^{1,2} · Nanako Oshiro¹ · Yoshitsugu Sunagawa¹ · Kumiko Omine¹ · Yuki Kudo¹ · Yuki Shinzato¹ · Tsukasa Osaki^{3,4,5} · Masayoshi Souri^{3,4,5} · Akitada Ichinose^{3,4} · Masanobu Yamazato¹ · Akio Ishida¹ · Yusuke Ohya¹

Received: 12 May 2022 / Accepted: 24 July 2022
© The Author(s) under exclusive licence to The Japan Society of Nephrology 2022

Abstract

Autoimmune factor V deficiency (AiFVD) is a rare bleeding disorder caused by factor V inhibitors. In this report, we present the case of an 89-year-old man who developed bleeding tendency during surgery to create arteriovenous fistula for hemodialysis. The bleeding tendency developed with prolongation of activated partial thromboplastin and prothrombin time, following drug-induced eruption and eosinophilia. Significant reduction in coagulation factor activity and inhibitory pattern in cross-mixing tests suggested the presence of inhibitors to coagulation factors. Subsequently, we detected a factor V inhibitor and anti-factor V autoantibodies was confirmed using enzyme-linked immunosorbent assay with purified human plasma factor V. Thus, the patient was ‘definitely diagnosed’ with AiFVD in accordance with the diagnostic criteria enacted by the Japanese Ministry of Health, Labor, and Welfare. The bleeding tendency improved after initiating oral prednisolone 50 mg (1 mg/kg) followed by normalization of activated partial thromboplastin time and prothrombin time at the 34th day. After improving the coagulation system prolongation, the inhibitor and autoantibodies has been eradicated. Since it is suggested that drug-induced immune response can cause AiFVD, AiFVD should be considered in patients who undergo hemodialysis and develop failure of hemostasis and drug-induced eruption.

Keywords Autoimmune factor V deficiency · Hemostasis failure · Factor V inhibitor · Eosinophilia · End-stage renal disease

Introduction

Acquired coagulation factor deficiency is common; however, it rarely causes bleeding. Autoimmune coagulation factor deficiency is the cause of bleeding in some patients with bleeding symptoms. Coagulation factor antibodies reduce the activity of clotting factors and cause bleeding tendency. Most autoantibodies are against factor VIII; anti-factor VIII autoantibodies are found in acquired hemophilia A, which affects one in 1.5 million persons per year [1]. Autoimmune factor V deficiency (AiFVD) is a rare bleeding disorder caused by factor V inhibitors and loss of the coagulation factor due to rapid removal of the immune complex with each coagulation factor. In Japan, the reported incidence of AiFVD is 0.04 [2], and due to its low incidence, its diagnosis is challenging, compared to the diagnosis of acquired hemophilia A.

✉ Kentaro Kohagura
kohagura@med.u-ryukyuu.ac.jp

¹ Cardiovascular Medicine, Nephrology and Neurology, Graduate School of Medicine, University of the Ryukyus, Okinawa, Japan

² Dialysis Unit, University Hospital of the Ryukyus, Okinawa, Japan

³ Department of Molecular Patho-Biochemistry and Patho-Biology, Yamagata University School of Medicine, Yamagata 990-9585, Japan

⁴ The Japanese Collaborative Research Group (JCRG) On Autoimmune Acquired Coagulation Factor Deficiencies Supported By the Japanese Ministry of Health, Labor and Welfare (MHLW), Tokyo, Japan

⁵ Department of Public Health and Hygiene, Yamagata University Graduate School of Medical Science, 2-2-2, Iida-Nishi, Yamagata 990-9585, Japan

Case report

Presentation

The patient was an 89-year-old man with end-stage renal disease due to nephrosclerosis. He was admitted to the emergency department with dyspnea and wet cough and was diagnosed with congestive heart failure (CHF) complicated with pneumonia. Treatment with ceftriaxone sodium hydrate and 30 mg/day of prednisolone (PSL) was initiated for pneumonia and exacerbation of chronic obstructive pulmonary disease, and intravenous furosemide was administered for CHF. Since *Enterobacter cloacae* was detected in sputum culture, the antimicrobial agent was changed to ceftazidime (CAZ) on day 3 after admission, and treatment of pneumonia was completed on day 14 after admission. Erythema appeared on the trunk on day 18 after admission, with eosinophilia (maximum eosinophil count: 790/ μ L) on day 6 after starting oral tolvaptan for fluid volume control. Since drug-induced erythema was suspected, CAZ and tolvaptan were discontinued. Three days after discontinuing these drugs, the erythema and eosinophilia improved. Since renal dysfunction was at an advanced stage, arteriovenous fistula was created for initiating hemodialysis. During the arteriovenous fistula creation procedure, bleeding tendency from the arteriovenous fistula ligature was observed, but mucosal or subcutaneous hemorrhage was not observed. Table 1 shows the postoperative blood and biochemical tests on day 32. Postoperative blood test revealed an activated partial thromboplastin time

(APTT) of 86.1 s and a prothrombin ratio (PT-INR) of 7.31 (Table 2). Further, coagulation test performed on the day of admission showed an APTT of 29.2 s and a PT-INR of 1.01 (Table 2). These results suggest that the patient developed de novo coagulation abnormalities after admission. In addition, blood tests revealed considerable decline in the activities of multiple coagulation factors (Table 3). Liver failure and vitamin K deficiency were initially suspected, but changes in the coagulation system were not observed after administration of vitamin K, and abdominal ultrasonography did not reveal liver cirrhosis. Since cross-mixing studies showed an upward convex inhibitor pattern (Fig. 1), which suggests the presence of a coagulation factor inhibitor. The results of a 1:1 mixture test of healthy samples and subjects (data was not shown) showed a decrease in coagulation factor activity of FV, but no decrease in coagulation activity of FVIII,

Table 1 Laboratory data (32nd day after admission)

	Laboratory data	Normal range
White blood cell	3700/ μ L	(3300–8600/ μ L)
(Neutrophil)	45.80%	
(Eosinophil)	7.30%	
(Lymphocyte)	35.30%	
(Monocyte)	11.60%	
Red blood cell	2.85×10^6 / μ L	(4.35–5.55)
Hemoglobin	8.3 g/dL	(13.7–16.8)
Platelets	11.7×10^4 / μ L	(15.8–34.8)
Albumin	2.9 g/dL	(4.1–5.1 g/dL)
Urea nitrogen	65 mg/dL	(8.0–20.0 mg/dL)
Creatinine	3.99 mg/dL	(0.65–1.07 mg/dL)
eGFR	11.8 mL/min/1.73 m ²	
Calcium	7.6 mg/dL	(8.8–10.1 mg/dL)
Ionic phosphate	3.3 mg/dl	(2.7–4.6 mg/dL)
AST	33 U/L	(13–30 U/L)
ALT	16 U/L	(10–42 U/L)

eGFR estimated glomerular filtration rate, AST aspartate aminotransferase, ALT alanine aminotransferase

Table 2 Coagulation test

	On admission (day 1)	32nd day after admission	Normal range
APTT, s	29.2	86.1	(23.5–35.0 s)
PT, s	12.3	76.6	(10.0–15.0 s)
PT, %	97.9%	8.8	(70.0–130.0%)
PT RATIO	1.01	6.08	(0.85–1.15)
PT-INR	1.01	7.31	(0.85–1.30)
Fib	535	393	(180–350 mg/dL)
FDP	7	5	(0.0–4.0 μ g/mL)
D-dimer	2.7	1.9	(0.0–1.0 μ g/mL)

APTT activated partial thromboplastin time, PT prothrombin time, PT RATIO Specimen coagulation time/control coagulation time, PT-INR prothrombin time-international normalized ratio, Fib fibrinogen, FDP fibrinogen degradation products

Table 3 Coagulation factor activity test (32nd day after admission)

Coagulation factor assay		Reference values
II	5%	(70–120%)
V	< 1%	(70–140%)
VII	1%	(70–120%)
VIII	12%	(70–130%)
IX	3%	(70–120%)
X	8%	(70–120%)
XI	3%	(70–120%)
XII	6%	(70–130%)
XIII	93%	(70–130%)
Protein C	104%	(70–140%)
LA(SCT ratio)	2.35	(< 1.16)
HPT	127%	(70–130%)
FVIII inhibitor	None	None
VWF:RCo	176%	(50–155%)
FXIII antigen	45%	(> 70%)

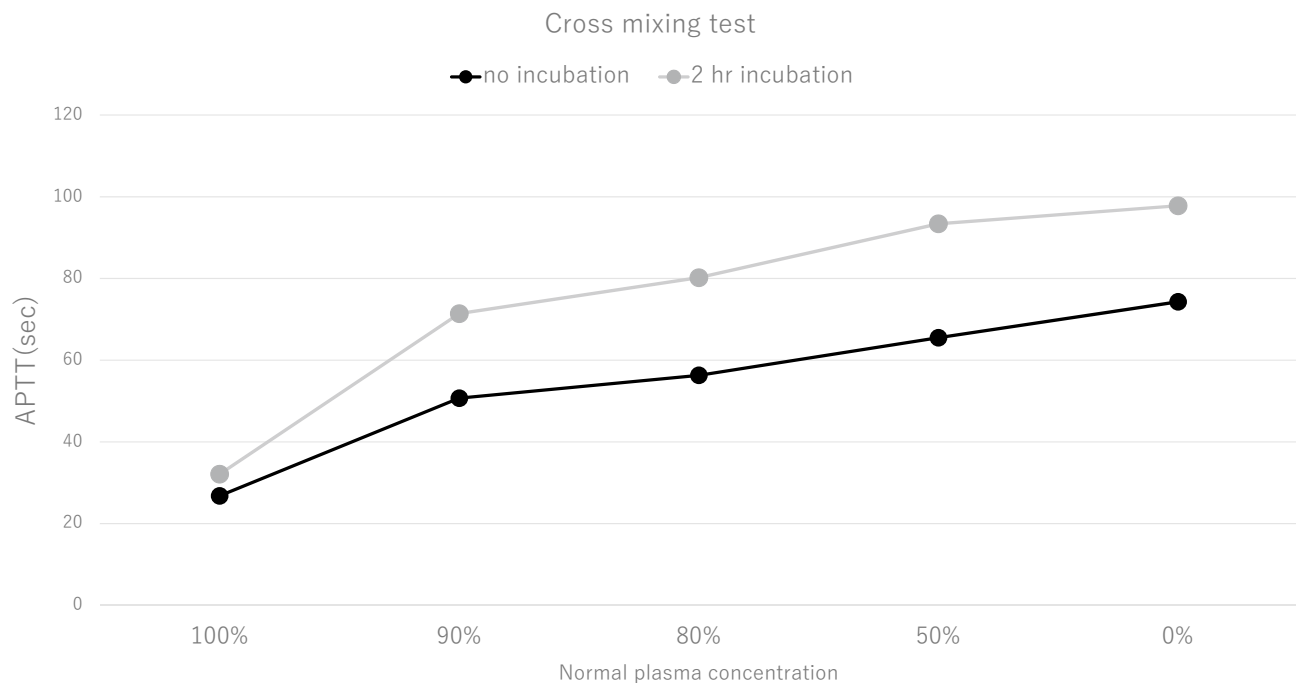


Fig. 1 APTT cross-mixing test. APTT cross-mixing test the immediate reaction (no incubation) and the reaction after 2 h of incubation (2 h incubation) showed an upward convex graph pattern, suggesting the presence of inhibitors

FXIII, or vWF, indicating that there were no inhibitors for FVIII, FXIII, and vWF. After initiating PSL, coagulation gradually improved. Since the presence of coagulation factor V inhibitor and anti-factor V autoantibody was later confirmed, we confirmed the diagnosis of AiFVD. Blood cultures on admission and on day 18 of illness were negative, and there was no subsequent fever suggestive of sepsis. Contrast-enhanced CT of the chest and abdomen and CT of the head were performed to search for malignancy, but no obvious abnormalities were found. On day 34 after initiating PSL (68 days from admission), the coagulation system normalized (Fig. 2). The patient was referred to the clinic for hemodialysis therapy maintenance after 7 months of PSL therapy and 3 months of no relapse. Due to a positive stool hemoglobin test, we recommended lower gastrointestinal endoscopy to the patient, but he refused it.

Results

Detailed experimental analyses were performed by the Japanese Collaborative Research Group for the definitive diagnosis of multiple coagulation factor deficiencies. A factor V-specific cross-mixing test of plasma samples from the patient and a healthy control clearly showed an inhibitor pattern (Fig. 3a), indicating the presence of a factor V inhibitor, rather than factor V deficiency. Furthermore, using the Bethesda method, we detected a factor V inhibitor with

a titer value of 145 BU/mL (Fig. 3b), and the presence of anti-factor V autoantibody was confirmed using enzyme-linked immunosorbent assay (ELISA) with purified human plasma factor V as described in a previous study (Fig. 3c) [3]. Thus, the patient was ‘definitely diagnosed’ with AiFVD in accordance with the diagnostic criteria enacted by the Japanese Ministry of Health, Labor, and Welfare [2, 4]. Factor V inhibitor and anti-factor V autoantibodies were not detected on day 73 and 94, likely because of antibody eradication treatment using PSL alone (Fig. 3b, c).

Discussion

In this report, we present the case of a patient who had just started hemodialysis therapy with bleeding tendency due to AiFVD, a rare disease with an estimated incidence of 0.04 per million persons per year in Japan [5]. Infectious diseases (viral and bacterial), antimicrobial agents (especially β -lactams), blood transfusion, cancer, and autoimmune diseases are the most common triggers of AiFVD. In a recent study, AiFVD was reported after Coronavirus Disease 2019 infection [6]. However, many cases of AiFVD are idiopathic, and the disease mechanism is not clear [7]. In a previous study, hematuria, gastrointestinal bleeding, hematoma, intracranial hemorrhage, and pulmonary hemorrhage were reported as bleeding symptoms, and 23% of patients were asymptomatic [8].

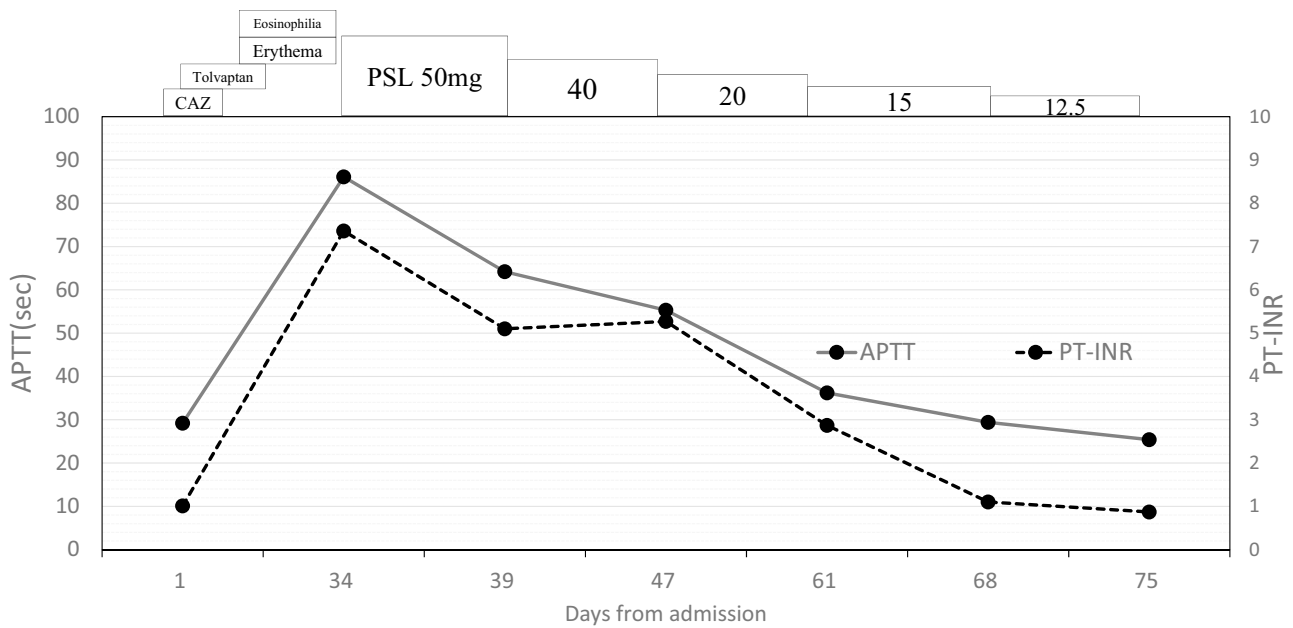


Fig. 2 Clinical course. Horizontal axis: number of hospital days *APTT* activated partial thromboplastin time (in seconds), *PT-INR* international normalized ratio of prothrombin time, *PSL* prednisolone (in mg/day), *CAZ* ceftazidime

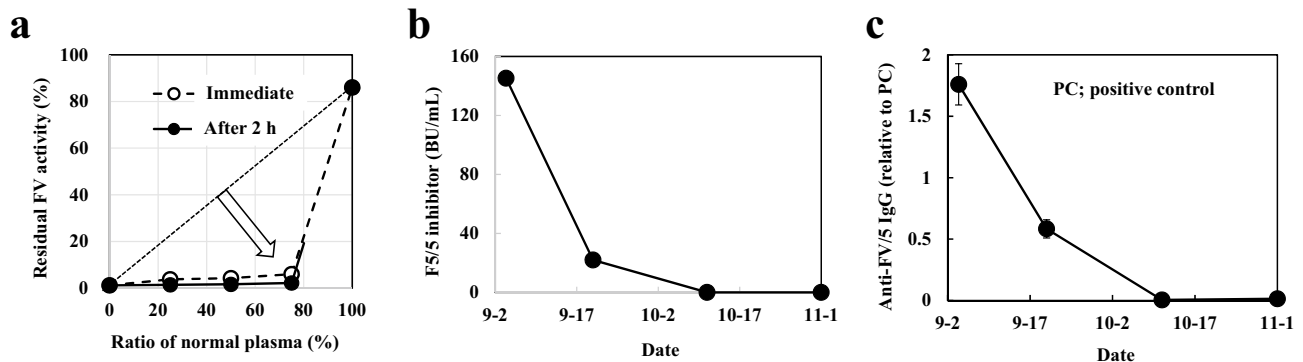


Fig. 3 a Five-step dilution cross-mixing test. Residual factor V activity was measured using one-stage clotting assay of the patient’s plasma at ratios of 0:1 (0%), 1:3 (25%), 1:1 (50%), 3:1 (75%), and 1:0 (100%) with normal plasma (white circles and broken line). Mixed samples were also incubated at 37 °C for 2 h (black circles and solid line) before the assay. The patient’s sample showed a downward concave ‘inhibitor’ pattern (white arrow). A straight dotted line depicts a theoretical ‘deficient’ pattern. **b** Change in factor V inhibitor titer value (Bethesda method). Factor V inhibitor titer value was determined using Bethesda method after heating the sample for 30 min at

56 °C. One Bethesda unit (BU/mL) is defined as the reciprocal of the inhibitor’s dilution concentration that results in 50% residual activity in the mixture. The initial titer value of factor V inhibitor was as high as 145 BU/mL, and it decreased in parallel with levels of anti-factor V autoantibodies. **c** Change in anti-factor V IgG level. Anti-factor V IgG level (black circle) was clearly detected using enzyme-linked immunosorbent assay of the patient’s sample on days 32 and 50 when factor V activity and antigen level are extremely low. The anti-factor V autoantibodies rapidly disappeared after the initiation of autoantibody eradication therapy using PSL on days 73 and 94

There are nine reported cases of AiFVD in patients undergoing hemodialysis, and seven of these patients were from Japan. Hemostatic defect in arteriovenous fistula, which presents as persistent oozing and is a common complication in patients undergoing hemodialysis, was the first symptom in several of these reported cases. In four of the above-mentioned patients, hemostatic defect in arteriovenous fistula may be related to antimicrobial therapy (Table 4) [3,

9–16]. Furthermore, AiFVD and eosinophilia were reported in four other patients with renal disease beside our patient [12, 17–19]. The above findings suggest that drug-induced immune response can cause AiFVD. In our patient, infection and drugs (e.g., CAZ, tolvaptan) may have induced this acquired abnormality. Given that hemostatic defect in arteriovenous fistula developed after eruption with eosinophilia, drug-induced immune response was considered responsible

Table 4 Reported cases of AiFV/5D in hemodialysis patients

Age	Sex	Cause of renal failure	Symptom	Cause	Treatment	Outcome
84 [9]	M	Unknown	Subcutaneous bleeding	Antibacterial drug (CFPM)	Oral PSL	Death
87 [3]	M	Diabetic nephropathy	Hemostatic defect in arteriovenous fistula	Bronchopneumonia, antibacterial agents (CTRX, LVFX)	Oral PSL	Normalized in 4 months
72 [10]	F	Nephrosclerosis	Subcapsular renal hematoma	Urinary tract infection, antibacterial drug (CTRX)	Oral PSL + CPA + plasma exchange	Normalized in 4 months
47 [11]	M	Unknown	Hemorrhagic pleural effusion, cardiac fluid	Unknown	FFP administration	Normalize in 1 month
72 [12]	M	Nephrosclerosis	Small intestinal bleeding	Eosinophilia	Oral PSL	Normalize in 1 month
68 [13]	M	Unknown	Hemostatic defect in arteriovenous fistula	Introduced antibacterial drug, introduction of dialysis	PSL	Normalized in 1.5 months
82 [14]	M	Diabetic nephropathy, Postoperative bladder cancer	Intermittent hematuria	Unknown	Oral PSL	Normalized in 2 months
75 [15]	M	Unknown	Thrombosis on the hemodialysis puncture site	Urinary tract infection, antibacterial drug (CTX)	Nothing	Normalized in 1 week
55 [16]	M	Chronic glomerulonephritis	Hemostatic defect in arteriovenous fistula, gingival bleeding, intramuscular bleeding	Unknown	Oral PSL + plasma exchange	Sudden death (unknown cause)

CFPM cefepime, CTRX ceftriaxone, LVFX levofloxacin, CTX cefotaxime, PSL prednisolone

for the AiFVD. Similarly, in a previous study, it was reported that drug-induced hypersensitivity syndrome/drug reaction with eosinophilia and systemic symptoms is associated with the development of autoimmune disease with detection of autoantibodies [20]. Although the mechanisms of drug-induced antibody production remain unclear, reactive autoantibodies may underlie the development of AiFVD in our patient. Acquiring factor V inhibitor after administration of warfarin and dabigatran as well as antimicrobial agents were also reported [21, 22].

In this case, not only factor V but also various other factors were decreased, but no inhibitors other than inhibitors for factor V were observed. These findings suggest a pseudo-multifactorial deficiency due to high titer factor V inhibitor. The presence of extremely high titers of coagulation factor inhibitors in the plasma results in complete inhibition of factor V. This leads to pseudo-multifactorial deficiency because the prolonged clotting time is not corrected, despite the normal activity of other factors [10]. Treatment is aimed at control of bleeding (using fresh frozen plasma [FFP], platelet transfusion, and prothrombin complex concentrate) and eradication of inhibitors using immunosuppressive agents. It was reported that platelet transfusion is superior to FFP for hemostatic control in patients with reduced factor V activity, whether congenital or acquired [23]. This may be because 20% of factor V is stored in platelets and factor V

has properties that allow it to escape inhibitors [8]. According to a previous study, immunosuppressive therapy with corticosteroids and/or cyclophosphamide and other immunosuppressive agents are used to eradicate inhibitors [7]. Remission was achieved in 37 of 49 patients (76%), with a median time to remission of 6 weeks [7]. In cases of steroid resistance, rituximab therapy, plasma exchange, and intravenous immunoglobulin therapy are considered alternative treatments [7, 24, 25]. In our patient, oozing was observed following compression hemostatic therapy, but since there was no active bleeding, platelets were not administered. The oozing improved within a few days after starting the patient on PSL. The coagulation system normalized on day 34 after PSL initiation without relapse.

In other words, 34 days after PSL initiation (i.e., on day 66), the patient achieved complete remission, evidenced by normal values of PT and APTT (Fig. 1). Further, immunological remission was confirmed on days 73 by the absence of anti-factor V autoantibodies on ELISA and factor V inhibitor. We previously reported that 73% of Japanese patients with AiFVD initially received PSL for antibody eradication, while 13.5% patients received a pulse PSL regimen, with success rates of 74.7% and 70.8%, respectively [2]. The success rate of PSL alone (85.1%) is higher than that of overall PSL (74.7%). Moreover, the success rate of pulse PSL alone (90%) was lower than that of pulse

PSL combined with PSL (100%). Therefore, physicians are advised to choose either the pulse-PSL-alone regimen or the combined regimen as first-line antibody eradication therapy whenever possible, at least in Japan where rituximab is not approved by the Japanese public health insurance system for the treatment of AiFVD. Acquired coagulation factor inhibitors can cause life-threatening bleeding. Moreover, recurrence has been reported in 20% of patients [1]; thus, it is important to follow patients closely over time.

Conclusion

Although rare, acquired AiFVD should be considered in cases of new hemostatic defect in arteriovenous fistula, especially when accompanied by drug-induced eruption and eosinophilia.

Acknowledgements This study has been supported by a research aid to A.I. from Japanese MHLW (21FC1008). The authors are indebted to all members of JCRG on AiCFDs. This case was presented at the 65th Annual Meeting of the Japanese Society for Dialysis Therapy (2020).

Declarations

Conflict of interest All the authors have declared no competing interest.

Ethical approval This article does not contain any studies with human participants or animals performed by any of the authors.

Informed consent Informed consent was obtained from the patient and his family for publication of this case report.

References

- Collins PW, Hirsch S, Baglin TP, Dolan G, Hanley J, Makris M, et al. Acquired haemophilia A in the United Kingdom: a 2-year national surveillance study by the United Kingdom Haemophilia Centre Doctors' Organisation. *Blood*. 2007;109:1870–7.
- Ichinose A, Osaki T, Souri M. A review of coagulation abnormalities of autoimmune acquired factor V deficiency with a focus on Japan. *Semin Thromb Hemost*. 2022;48:206–18.
- Ogawa H, Souri M, Kanouchi K, Osaki T, Ohkubo R, Kawanishi T, et al. A high titer of acquired factor V inhibitor in a hemodialysis patient who developed arterial thrombosis. *Int J Hematol*. 2019;109:214–20.
- Ichinose A. Immune-mediated acquired coagulation factor deficiencies: state-of-the-art in diagnosis and management. *Rinsho Ketsueki*. 2019;60:667–79 (**In Japanese**).
- Ichinose A, Hideo W, Hidesaku A. Guidance for diagnosis and management of patients with Japan's designated disease 288–4 autoimmune acquired coagulation factor V/5 deficiency (AiF5D). *Ketsueki Naika*. 2022;84:129–42 (**In Japanese**).
- Chiurazzi F, Tufano A, Esposito M, D'Agostino F, Casoria A, Capasso F, et al. Acquired factor V inhibitor after Coronavirus Disease 2019 (COVID-19). *Semin Thromb Hemost*. 2022;48:124–6.
- Franchini M, Lippi G. Acquired factor V inhibitors: a systematic review. *J Thromb Thrombolysis*. 2011;31:449–57.
- Boland F, Shreenivas AV. Acquired factor V inhibitors: a review of the literature. *Ann Hematol Oncol*. 2017;4:1168.
- Yamanishi M, Nishimi Y, Usui M, Miki K, Imashuku S. Acquired factor V deficiency associated with CFPD administration. *Clin Lab*. 2019;65(10). <https://doi.org/10.7754/Clin.Lab.2019.190240>.
- Nakata K, Ueda S, Matsunaga H, Mima F, Ueda H, Yoshioka A, et al. High titer of acquired factor V inhibitor presenting with a pseudo-deficiency of multiple coagulation factors. *Intern Med*. 2018;57:393–7.
- Zhao WB, Chen YR, Luo D, Lin HC, Long B, Wu ZY, et al. Severe serous cavity bleeding caused by acquired factor V deficiency associated with lymphatic leakage in a hemodialysis patient: a case report. *World J Clin Cases*. 2019;7:2556–61.
- Kitazawa A, Misawa H, Nagahori K, Koda R, Yoshino A, Kawamoto S, et al. Acquired factor V inhibitors in a patient with end-stage renal disease. *Intern Med*. 2016;55:3505–9.
- Matsumoto A, Ogawa Y, Osaki T, Souri M, Yanagisawa K, Ishizaki T, et al. Successful management of acquired factor V deficiency developing shortly after induction of hemodialysis. *Rinsho Ketsueki*. 2020;61:445–50 (**In Japanese**).
- Niwa N, Yoshida T, Mizuno R, Oya M, Hayashi M. Renal hemorrhage caused by acquired inhibitors to coagulation factors VIII and V in a hemodialysis patient. *CEN Case Rep*. 2016;5:223–6.
- Ghachem I, El Borgi W, Fekih Salem S, Ben Lakhel F, Chelbi A, Ghiriani I, et al. Haemodialysis Tunisian patient with acquired factor V inhibitor associated to arteriovenous shunt thrombosis. *Ann Biol Clin (Paris)*. 2020;78:206–9.
- Ishizu M, Kuroiwa M, Tanaka K, Hasegawa Y. Severe hemorrhagic tendency due to factor V inhibitor in a hemodialysis patient: a case report. *Nihon Toseki Igakkai Zasshi*. 2003;36:1285–8 (**In Japanese, Abstract in English**).
- Iino N, Maruyama H, Gejyo F. Acquired coagulation abnormality due to factor V inhibitor. *Nippon Naika Gakkai Zasshi*. 2002;91:3295–7 (**In Japanese**).
- Kitamura S, Misawa M, Namba S, Tsuji K, Torigoe R, Shima M, et al. Membranous nephropathy with acquired factor V inhibitor: a case report. *BMC Res Notes*. 2013;6:553.
- Takahashi H, Fuse I, Abe T, Yoshino N, Aizawa Y. Acquired factor V inhibitor complicated by Hashimoto's thyroiditis, primary biliary cirrhosis and membranous nephropathy. *Blood Coagul Fibrinolysis*. 2003;14:87–93.
- Mizukawa Y, Aoyama Y, Takahashi H, Takahashi R, Shiohara T. Risk of progression to autoimmune disease in severe drug eruption: risk factors and the factor-guided stratification. *J Investig Dermatol*. 2022;142:960–8.e9.
- Sekiguchi Y, Yoshikawa H, Shimada A, et al. Acquired factor v inhibitor developing after treatment with dabigatran etexilate methanesulfonate: a case report and review of the literature. *Indian J Hematol Blood Transfus*. 2014;30(Suppl 1):275–9.
- Khalafallah A, Grabek J, Hayes R, Mohamed M. Bleeding associated with acquired factor V inhibitor in a patient on warfarin treated successfully with prednisolone. *BMJ Case Rep*. 2013. <https://doi.org/10.1136/bcr-2013-010018>.
- Chediak J, Ashenhurst JB, Garlick I, Desser RK. Successful management of bleeding in a patient with factor V inhibitor by platelet transfusions. *Blood*. 1980;56:835–41.
- Patel MD, Hajdenberg J. Successful treatment of chronic recurrent life-threatening bleeding due to an acquired factor V inhibitor with rituximab and steroids. *Haemophilia*. 2016;22:e231–2.

25. Navarrete MA, van der Meer FJ, Damiani G, Diaz A, Eikenboom J. The use of rituximab therapy in patients with acquired factor V inhibitors. *Am J Hematol.* 2012;87:826–7.

Publisher's Note Springer Nature remains neutral with regard to jurisdictional claims in published maps and institutional affiliations.

Springer Nature or its licensor holds exclusive rights to this article under a publishing agreement with the author(s) or other rightsholder(s); author self-archiving of the accepted manuscript version of this article is solely governed by the terms of such publishing agreement and applicable law.