



B. Narayan • C. Harris • S. Nayagam

## Treatment of high-energy tibial plateau fractures

Received: 18 August 2006 / Accepted: 6 October 2006 / Published online: 14 December 2006

**Abstract** Treatment of high-energy fractures of the tibial plateau requires an inordinate degree of surgical effort in order to avoid complications. Fracture reduction can be a challenge to experienced hands and the soft tissue conditions are intolerant of careless dissection. In general, it is an oversimplification to use one technique of stabilisation for such a heterogenous group (even within one classification tier). This article describes the specific attributes of Schatzker type 6 injuries (AO 41C) that enable decision-making algorithms to be generated and balances the merits for plate stabilisation and external fixation against injury characteristics. A detailed description is given for circular fixation in these injuries to assist those unfamiliar with the technique.

**Key words** External fixation • Fracture • Tibia • Ilizarov • Plateau • Internal fixation • Minimally invasive

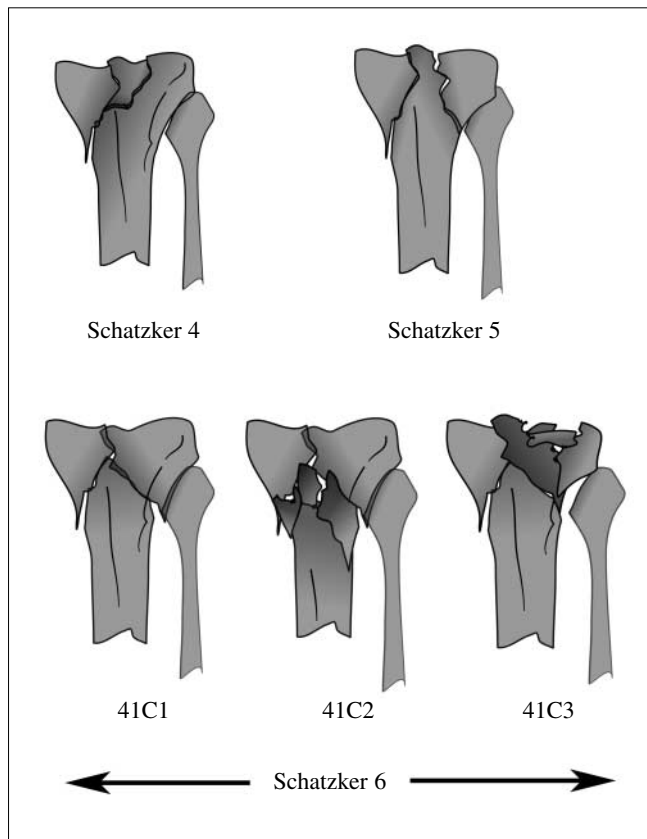
### Introduction

High-energy fractures of the tibial plateau are characterised by severe damage; there is fracture comminution, significant soft tissue damage with implications for healing, and an association with neurological injuries (common peroneal nerve) and compartment syndrome [1]. Although these injuries are a small fraction of general fracture workload, they require an inordinate degree of surgical effort in order to avoid complications. Fracture reduction can be a challenge to experienced hands and the soft tissue conditions are intolerant of careless dissection.

Two main classifications in common use for proximal tibial fractures are that of Schatzker et al. [2] and the AO/OTA comprehensive [3]. Both are based on the fracture pattern with the degree of injury, and correspondingly challenge of management, rising with increasing type. In the AO/OTA comprehensive classification, proximal tibial injuries are assigned the number 41 (4 for tibia, 1 for proximal). Complete articular injuries, where the articular surface is dissociated from the diaphysis of the bone, are classified 41-C. These are subdivided into 3 groups, according to the complexity of the articular and metaphyseal fracture components (Fig. 1). The Schatzker system divides proximal tibial fractures into 6 types; although types 4–6 are regarded as high-energy injuries in young adults, it is the Schatzker types 5 and 6 that are the focus of this article. Both classification systems are comparable and overlap but the grades of severity are not always interchangeable: Schatzker 6 injuries are characterised by the separation of the metaphysis from the diaphysis – these are all 41C injuries in the AO/OTA system; Schatzker 5 is a complete articular injury (involving both medial and lateral sides of the plateau) but without the metaphyseo-diaphyseal dissociation (MDD) – there is no interchangeable AO/OTA grade.

These classifications do not describe the amount of fracture displacement, associated soft tissue injuries or the state of local vascularity – the very features that are preva-

B. Narayan • C. Harris • S. Nayagam (✉)  
Limb Reconstruction Unit, Department of Orthopaedic Surgery  
Royal Liverpool and Broadgreen University Hospital NHS Trust  
Liverpool, L7 8XP, UK  
e-mail: durai.nayagam@rlbuht.nhs.uk



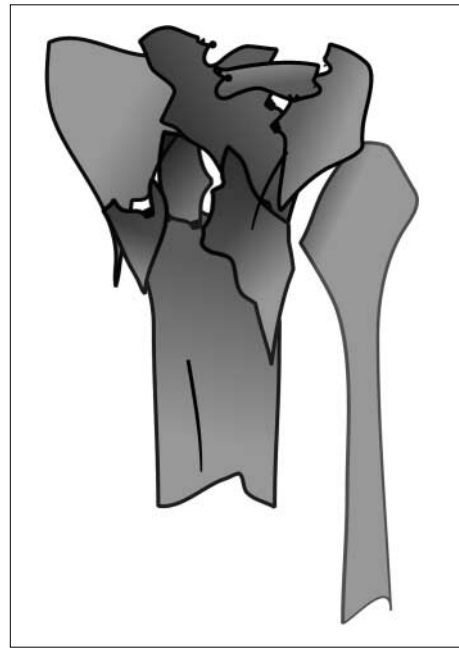**Fig. 1** A comparison of the Schatzker and AO comprehensive classifications for high-energy proximal tibial fractures

lent in these high-energy injuries. Our experience has clearly revealed heterogeneity within each class – a multi-fragmentary articular *and* metaphyseal group (combination of 41C2 and 41C3) is not uncommon and often the most difficult to treat (Fig. 2).

Attention to three main areas is needed in managing these injuries – the articular surface, the metaphyseo-diaphyseal region and the soft tissue stabilisers (ligaments and menisci).

### Treatment objectives

The aims here are in common with articular injuries elsewhere: restoring anatomy, stability and function, with the hope that doing so preserves joint survival against post-traumatic arthritis. However the objectives can be difficult to meet with this particular group of injuries; a simple extrapolation of fracture stabilisation techniques, successful elsewhere in the body, may induce complications not seen in other regions – an understanding of the pathoanatomy of this group of fractures is a prerequisite to successful decision-making.



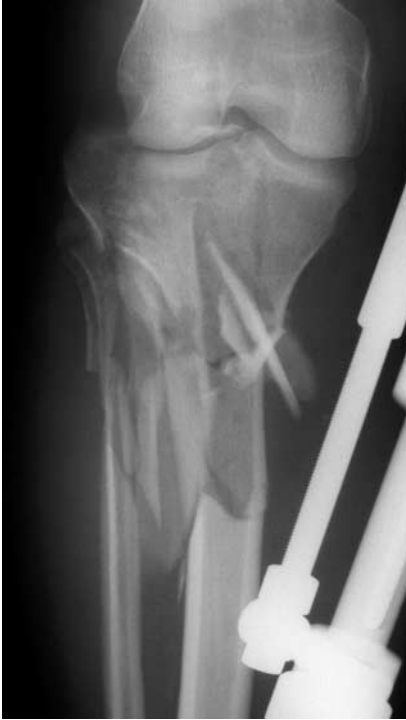**Fig. 2** A variant of the 41C pattern that is comminuted in both articular and metaphyseal components

### Damage control and preoperative planning

Soft tissue management is of great importance and is integral to the period during which pre-op planning is carried out. It is a form of damage control.

#### Damage control

The concept of ‘damage control’ has become popular, and refers to the use of monolateral external fixation to achieve temporary stability in patients with multiple long-bone fractures. The same approach is translated for the severely injured limb; early extensive surgery through a tenuous soft tissue envelope invites risk of complications and the strategy of a period of temporary stabilisation by spanning external fixation – ‘local damage control’ – has evolved. Spanning external fixation helps bring the fracture into approximate axial alignment [4, 5] and maintains soft tissues at appropriate length (Fig. 3). Radiographs and CT scans performed after application of external fixation are easier to interpret, and allow for better surgical planning – this being the practice of ‘span and scan’. Spanning fixation permits repeated, unobstructed and comfortable inspection of the soft tissue status prior to definitive surgery. It also facilitates compartment pressure monitoring and comfortable inter-hospital transfer of the patient to institutions that are able to provide definitive care.



**Fig. 3** Variant of 41C patterns realigned by spanning fixation

#### Spanning fixator configuration

Monolateral fixation applied across the knee, with half pins in the femur and the tibia, is simplest. However the label ‘temporary stabilisation’ is no excuse for fixator assemblies that are applied in a hurry and are unstable – stable configurations are needed for the benefits of damage control to be realised.

The stiffness and stability of a monolateral construct depends on the diameter of the pins, the numbers of pins in each segment of fixation, the use of pins in different planes, the diameter of the sidebar and the placement of the sidebar [6–8]. A guide to a stable configuration would include:

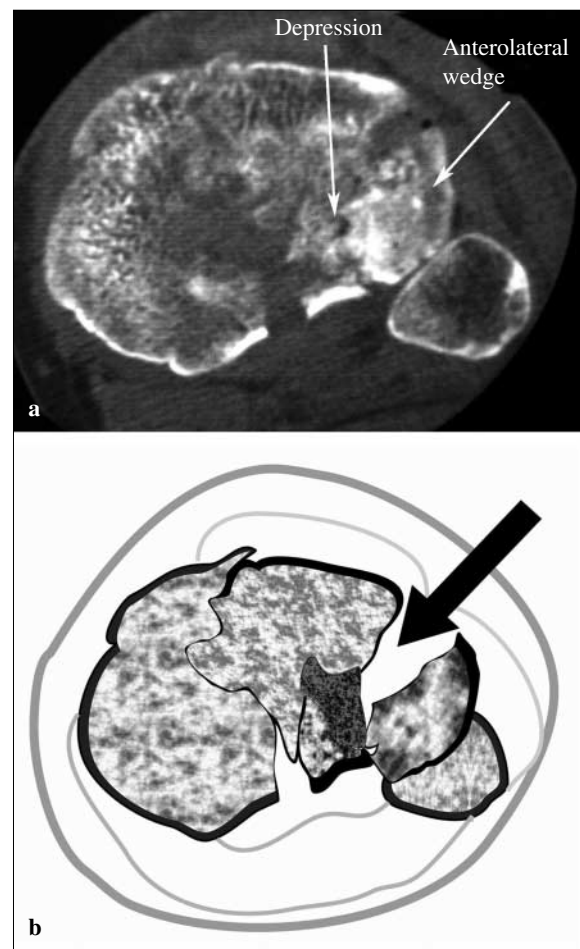
- 5-mm or 6-mm pins in the femur and tibia;
- two, but preferably three pins in each segment (femur and tibia):
  - two femoral pins in the sagittal plane (proximal to the suprapatellar pouch) and a third in a different plane;
  - two or three tibial pins (well distal to any planned internal fixation device) through the anteromedial (subcutaneous) surface, preferably in different planes;
- large-diameter interconnecting sidebars (rods), or stacked rods if diameters are narrow;
- bringing the sidebars close to the skin, but leaving just enough room for pin site care.

In the femur anteroposterior pins permit easy assembly of the external fixator construct, and when used for temporary fixation are not associated with quadriceps tethering or long-term limitation of knee movement [9]. In the tibia,

the safe corridor for insertion of monolateral pins is from anteromedial to posterolateral, or from anterior to posterior. Anteroposterior pins are placed just medial to the palpable crest of the tibia and beyond the limit of the zone of injury. Placement with due consideration of future skin incisions is wise.

#### CT scans

CT scanning is best performed after the application of spanning external fixation. Whilst finely separated axial cuts (3 mm) and sagittal and coronal reformats help in surgical planning, they do not substantially add to the classification of the injury. The axial cuts accurately locate depressed articular fragments and allow planning for access [10, 11] (Fig. 4). Coronal and sagittal reformats map the extent of articular depression and estimate the degree of depression more clearly than plain X-ray films. Sagittal reformats are also useful in showing involvement of the tibial tubercle and the presence of posterolateral or posteromedial fragments [12].



**Fig. 4** CT scan of 41C injury indicating plane of cleavage for access to middle of lateral plateau

## Compartment pressure monitoring

Compartment syndrome is known to occur in about 12% of closed and an equal proportion of open high-energy proximal tibial fractures [9]. A high index of suspicion is necessary and regular clinical monitoring mandatory; continuous pressure monitoring is indicated in those who cannot provide reliable responses to clinical examination for whatever reason.

---

## Decision-making

Separation of the diaphysis from the metaphysis of the proximal tibia – metaphyseal-diaphyseal dissociation (MDD) – is an important characteristic of the AO/OTA 41C proximal tibial fractures. Multifragmentary dissociation below the tibial tuberosity is typical of high-energy fractures, and problems with non-union or malunion often arise here.

Choosing the appropriate treatment consists in the balance struck between fracture characteristics, individual patient factors, research evidence and the skills of the treating surgeon. It would be ideal to competently offer different surgical strategies based on the balance of the first three factors but this would necessitate the surgeon having a wide breadth and depth of surgical skills.

Treatment strategies are broadly non-operative or surgical. Non-operative management of high-energy plateau fractures with MDD is fraught with problems – malunion and non-union being notable. Stiffness is not necessarily a foregone outcome with non-operative strategies; joint motion can be preserved provided the fracture is treated with traction and early motion, but this technique is becoming obsolete in the West owing to the expense of protracted hospitalisation.

Anatomical reduction and fixation by plates and screws were popular in the 1980s, but met with significant trouble from wound breakdown and deep infection. The type of stabilisation was not at fault but the manner of implementation. Much local tissue vascularity was sacrificed to produce the immaculately reduced fracture – the sorry sight of a leaking wound being invisible on plain radiographs! Even with the advent of newer methods of plating such as minimally invasive techniques coupled to the use of angle-stable implants, problems unique to high-energy MDD have not been solved in all cases.

Circular external fixation offers a non-invasive method of restoring the continuity of the metaphysis to the diaphysis without additional violation of the soft-tissue envelope. In addition it is the only method of treatment that allows fine-tuning of reduction post-operatively. This is particularly useful in complex fracture patterns when intra-operative restoration of the mechanical axis of the tibia is difficult, especially when the fracture extends very distal into the tibial shaft, because assessment of tibial alignment

through C-arm imaging is limited by the restricted field of view. Furthermore, the technique of closed gradual reduction in the circular external fixator preserves the soft tissue envelope around the most damaged part of the limb.

In the authors' experience, circular external fixation is ideal to restore the continuity of the metaphysis to the diaphysis in cases where the dissociation is comminuted, distal to the tibial tuberosity, or has diaphyseal extensions. Whilst angle-stable implants (plates with locking screws) are also useful, the technique is limited by a prerequisite reduction at the MDD – if this can only be accomplished through extensive dissection and fragment handling at surgery, then much of the intended benefits of percutaneous plating are lost. In recognition of this caveat, we may choose to use an angle-stable implant for minimally comminuted and displaced AO/OTA 41C fractures and opt for fine wire circular external fixation for the more complex and displaced varieties.

---

## Operative technique

### Three stages

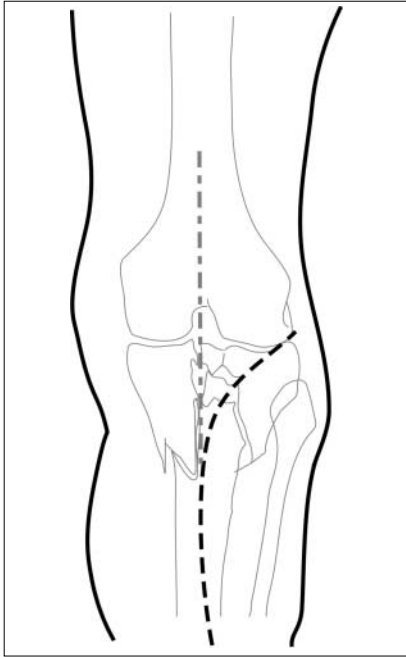
A staged approach facilitates breaking up a difficult problem into manageable parts. The main stages are:

- articular reduction and fixation;
- meniscal repair (either as a consequence of injury or surgical approach);
- MDD reduction and stabilisation.

### Articular reduction and fixation

#### *Surgical exposure*

A midline incision is standard and serves to protect the need for future surgery, in particular for arthroplasty. However access to the lateral plateau is more commonly needed as the split and depressed fracture segments are often on this side. A midline incision may induce extensive stripping in order to reach the farthest aspects of the lateral plateau and when access to both sides of the tibial plateau was required, this set the scene for wound problems. The midline incision for access to both sides of the tibial plateau, particularly when plate osteosynthesis is contemplated, is now superseded by separate anterolateral and posteromedial incisions. An anterolateral incision curved proximally provides good reach of the key fracture parts and does not compromise future access for knee arthroplasty if due attention is given to the curve characteristics (Fig. 5); a projected midline incision should subtend an angle of at least 60° with the main direction of the curve. Direct access to the medial plateau is safely achieved through a posteromedial incision and developing the plane between popliteus muscle and bone.



**Fig. 5** Common anterior incisions for access to the tibial plateau

#### Meniscal elevation

As the surgical exposure is developed deep to the fascia lata at the joint line of the lateral tibial plateau, it becomes clear the meniscus, capsule and fascia lata become closely entwined. A plane of cleavage is surgically created by sharp dissection (the tip of a No. 15 blade is ideal) between the outer periphery of the meniscus and capsule – in effect, creating a red-on-red ‘tear’ of the meniscus. As the dissection proceeds from anterior to lateral, two features may be revealed:

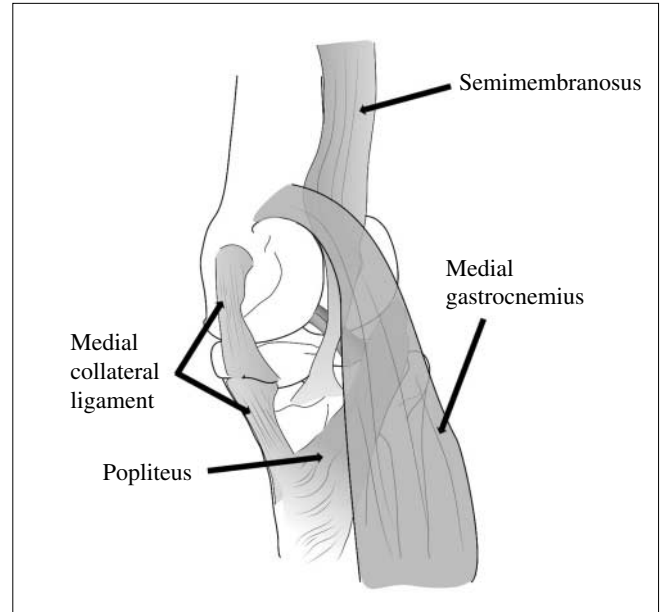
- the anterior fissure of the anterolateral wedge split of the tibial plateau;
- a torn lateral meniscus, if present.

Usually it is not necessary for this dissection to proceed further than the midaxis of the tibia in the sagittal plane. The submeniscal plane can be identified using a fine hypodermic needle as a probe along the edge of tibial plateau; without using this technique it is easy to make a mistake and enter the knee joint above the meniscus rather than below it.

#### Articular reduction

The precise order of reduction will depend on the fracture pattern. The CT scan provides location of:

- the anterolateral split, which gives access to the depressed portions of the lateral tibial condyle;
- other major fracture lines which dictate the direction of interfragmentary screws;



**Fig. 6** Plane for access to posteromedial aspect of proximal tibia

- a significant posteromedial segment which may need a separate posteromedial incision to allow direct elevation and fixation (Fig. 6).

The anterior fissure of the anterolateral wedge fragment is developed by inserting a blunt instrument to prise open the plane, and thereby gain access into the centre of the lateral joint space. If the subperiosteal elevation does not extend beyond the mid-sagittal plane, the posterior parts of this anterolateral split wedge will keep its soft tissue attachments posteriorly. This plane of access can be maintained using a simple Weitlander retractor.

Evacuation of the joint haemarthrosis and of soft clot will enable the surgeon to identify the fracture fragments. The depressed segment should be elevated en masse from beneath and not by picking out individual articular fragments. The latter can render the assembly of tiny pieces of the joint surface utterly futile. The elevation of the depressed segment leaves a void in the subchondral metaphysis. There is some individual preference and debate about the choice of appropriate substitute to fill this defect. Autogenous corticancellous graft is still the benchmark although tricalcium phosphate and similar type bone substitutes have their appeal. Direct visualisation of accuracy of reduction is possible through the submeniscal exposure of the joint surface. The anterolateral split wedge fragment is then folded over like closing a book.

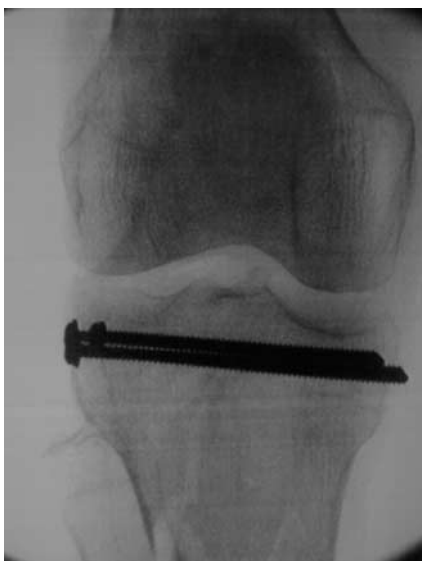Should a posterolateral fragment of lateral tibial plateau exist, reduction can often be accomplished through the same exposure above, with access achieved through the middle of the joint and the fragment then held by percutaneously directed screws. In some scenarios it may be preferable to make a small separate posterolateral oblique incision just above the tendon of biceps femoris in order to

reach the posterolateral corner of the plateau and insert a fixation screw to hold the said fragment [12].

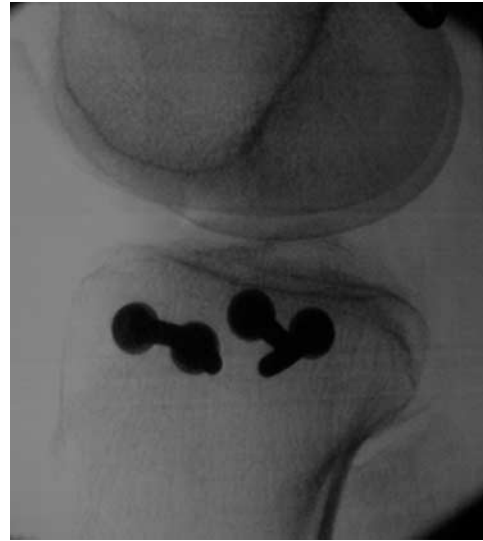The medial plateau often consists of coronal plane splits if multifragmented. Traction often achieves reduction in relation to the lateral plateau but there are occasions when the posteromedial fragment poses a problem and remains depressed with respect to the remainder of the tibial plateau. Access to the fragment is relatively straightforward; a posteromedial longitudinal incision is made [12]. The medial head of gastrocnemius is retracted posteriorly; the tendons of the pes anserinus are retracted anteriorly and this is helped if the knee is kept flexed. A subperiosteal plane is developed, and occasionally this requires elevation of the popliteus muscle with the periosteum. The fracture line becomes visible and reduction can be performed directly or with the aid of lateral X-ray projections.

**Fixation**

Provisional fixation of the reduced fracture fragments is easily accomplished with K-wires, with some forethought given to prospective placement of screws so as to minimise retraction of the K-wires and re-insertion. The direction of screw fixation in order to achieve interfragmentary compression of the main fragments will have been obtained from axial CT scans; ideally the direction should be orthogonal to the relevant fracture line. Traditionally cannulated screws were favoured, of 6.5-mm calibre. There is evidence [13, 14] suggesting multiple 3.5-mm cortical threaded screws, inserted parallel in the subchondral zone in the manner of a ‘raft’, have advantages; these screws better maintain the reduction of depressed segments and provide greater space for insertion of tension wires in circular external fixation (Figs. 7 and 8). This is the favoured technique in our unit.



**Fig. 7** Raft-type screws for articular fixation (AP view)

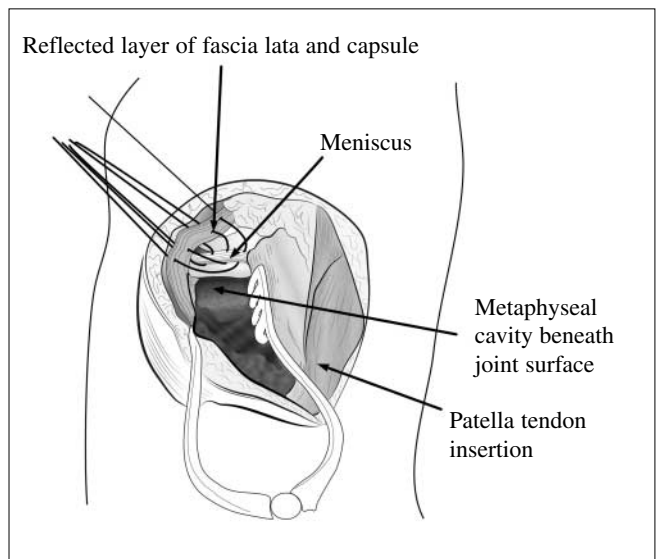


**Fig. 8** Raft-type screws for articular fixation (LAT view)

**Reattachment of the meniscus**

Access to the joint surface requires the meniscus be separated from the combined capsule and fascia lata in a reflection of the latter as a single layer from the periphery of the meniscus. This surgically created red-on-red tear permits identification of the menisco-tibial junction and a submeniscal route to the joint surface. Repair of the meniscus is therefore mandatory. If a tear of the meniscus is encountered as part of the injury, then a repair is performed if the tear is similarly at a red-on-red junction. More central tears are excised.

The technique of reattachment is shown in Figure 9. A new plane is created superficial to the fascia lata but deep to subcutaneous fat. Some restraint is needed when creating



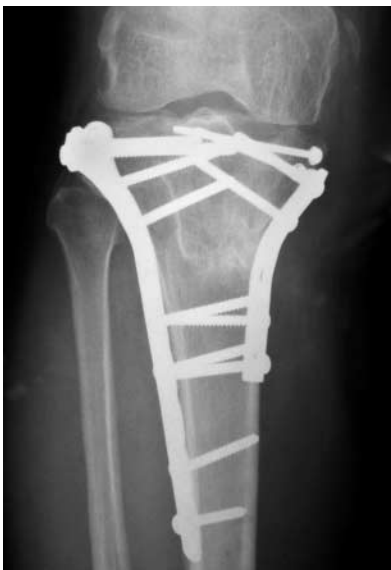**Fig. 9** Repairing the lateral meniscus to the fascia lata/capsule conjoined layer

this new plane as the overlying skin receives a significant blood supply through fascia-perforating vessels which are inevitably divided. It is necessary only to elevate this as far lateral as the extent of meniscal detachment. When this is done, the fascia and capsule exists as a separate conjoined layer and it is to this the meniscus is reattached with multiple interrupted sutures. A tapered point narrow diameter or a J-shaped needle is useful; braided non-absorbable sutures of size 0 are optimum. The suture is passed from out to in; the needle is fed through the fascia lata/capsule layer, through the outer rim of the meniscus and back out through the first layer. This suture is cut and clipped for tying later. Multiple sutures are passed in the same manner, starting at the most lateral and posterior aspect and working anteriorly, with an interval of 5–7 mm between sutures.

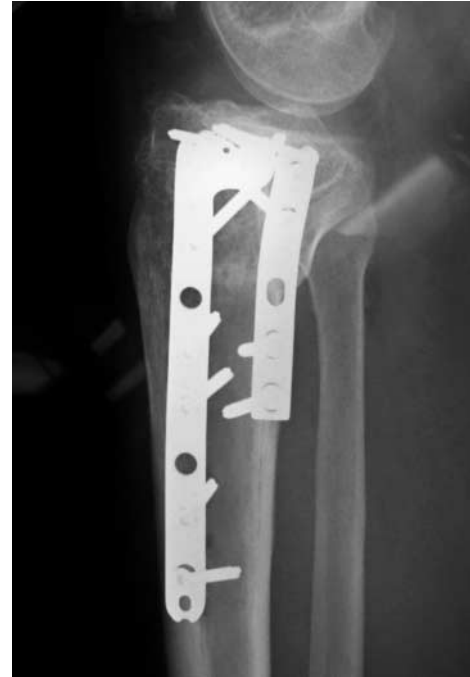The sutures are then tied in sequence, approximating the cleaved edge (red-on-red tear) of the lateral meniscus back to the capsule and fascia lata.

### Dealing with metaphyseal-diaphyseal dissociation

This important characteristic of high-energy plateau fracture patterns can be the most challenging. In examples where the dissociation is through the tibial tubercle or proximal to it, stabilisation using angle-stable plates contoured for lateral tibial application may be more appropriate than external fixation. Access for plate insertion is through the same anterolateral approach and a distal incision may be needed for lower screw insertion. The medial plateau is held by a second plate applied posteromedially; this is either a third tubular or narrow 3.5-mm DCP applied in the manner of an antiglide plate (Figs. 10 and 11). This



**Fig. 10** Anterolateral and posteromedial plate fixation of proximal tibial plateau fracture (AP view)



**Fig. 11** Anterolateral and posteromedial plate fixation of proximal tibial plateau fracture (LAT view)

approach to double plating suffices in holding this particular variety of MDD without recourse to the more risky extended anterior midline incision.

In scenarios where there is displacement, comminution or diaphyseal extension in an infratubercle MDD, our preference is to stabilise the fracture with circular external fixation. The rationale for choosing such a fixator for this variety of high-energy tibial plateau fractures is optimisation of the biological and biomechanical environment to healing. The MDD is often the area that poses problems with delayed or non-union, and an alteration of surgical strategy befits the purpose of avoiding the problem. External fixation permits minimal disruption of the precarious biology remaining in this area, and circular external fixation not only permits post-operative alterations in alignment and contact between fracture fragments (a commonly quoted advantage of external fixation in general) but more importantly controls the biomechanical environment. Several studies have shown control of this environment through choice of fixation devices can facilitate the speed and manner of callus formation across fractures [15–18]. Our choice of circular external fixation is particular; there are several designs on the market but the characteristics of a circular fixator under load are important. We have found all-wire circular external fixators (Ilizarov classic system) and specialised hybrid types (Orthofix Sheffield Ring System) offer beam loading characteristics and isotropic behaviour. Our experience with both devices has shown similar characteristics of callus formation and union times when used in comparable fracture types [19, 20].

### Application of the ring fixator

There are several techniques; applying a circular fixator, especially if tensioned fine wires are used, is more difficult and time-consuming than a monolateral half-pin fixator, but the two devices are completely different with respect to bio-mechanical characteristics. The technique described here is for the Sheffield Ring Fixator System (Orthofix Srl, Verona) but the principles are applicable to other similar fixators.

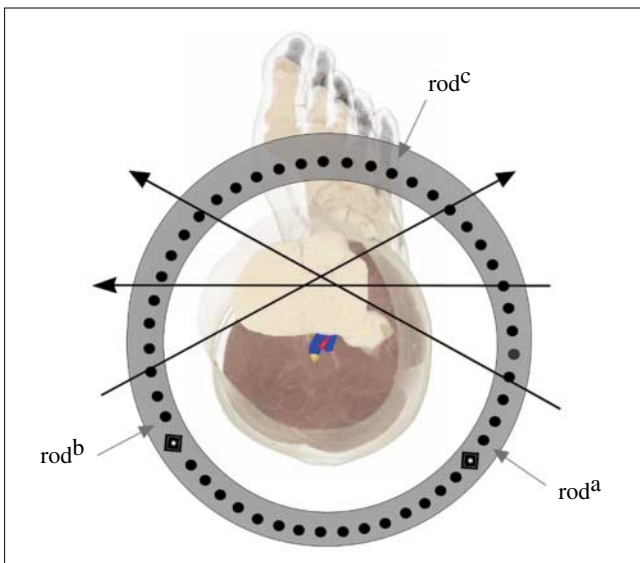
With any external fixator system application is simplified by provisional reduction of the fracture. Many fixator systems purport ease of application through ‘click and fix’ components or ball-joints, but often this freedom of use can result in the assembly of devices that are overly fussy, poorly aligned to the limb and unstable. The application technique here requires the surgeon to achieve a provisional reduction of the MDD: it is often easiest if the limb is under traction (that will achieve a significant proportion of the fracture reduction anyway) through a traction table or similar device. Fine adjustment of the reduction can be accomplished through the use of tenaculum forceps or provisional use of 2-mm or 3.2-mm K-wires that will hold the MDD reduced until ring fixator application is complete.

Some preoperative planning is necessary:

- The ring diameter needed (it will be necessary to have soft tissue clearance of approximately 2–3 finger breadths above the tibial crest and similarly around the posterior calf muscles). A common diameter for such fractures is 150–175 mm. Using the smallest feasible ring diameter ensures stability.
- The threaded rod length. This varies with the size of the leg and the level of the MDD. As a guide, the MDD should be at least 2 cm proximal to the first half pin of the distal ring assembly, thereby reducing the risk of a half pin infection extending into fracture haematoma. A common rod length is 150–200 mm. Using the shortest rod feasible ensures greater stability.

The fixator is preassembled using the ring diameter and rod length as appropriate. Although it is possible to leave the proximal ring as two-thirds of a full circumference, it is the authors’ preference to use a complete ring here. Two threaded rods (rods a and b) are inserted initially as shown in Figure 12, the third (rod c) is inserted after the Sheffield clamp has been positioned optimally.

With the fracture provisionally reduced as described earlier, a wire is then passed in the coronal plane in line with the mid-sagittal axis, just distal to the ‘raft’ screws. Note the mid-sagittal axis in the proximal fourth of the tibia is the junction of the anterior fourth and posterior three-fourths – especially if the wire is inserted about 2 cm from the joint line (Fig. 14 A). Either a smooth 2-mm K-wire or a 2-mm central olive wire is used – to ensure this wire is at right angles to the axis of the tibia proximal to the MDD, the wire is inserted at the lateral cortex 20 mm



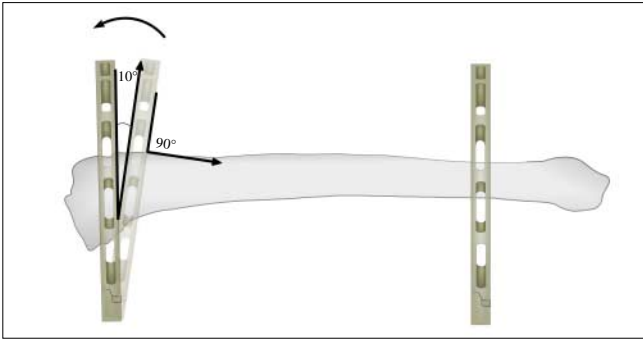
**Fig. 12** Direction of proximal tibial wires and threaded rod location for the Sheffield Ring System (Orthofix Srl, Verona)

from the lateral joint line and guided so as to emerge from the medial cortex 9 mm from the joint line on this side (see Table 1). This wire is *not* parallel to the joint line as the joint line is not orthogonal to the axis of the tibia; when inserted in this manner it is at right angles to the axis of the tibia. The preassembled fixator is then brought up to the wire so that this wire lies on the proximal surface of the proximal ring. Two sliding clamp units are attached to the ends of the wire and onto the ring. The ring should be positioned so that the clearance over the anterior surface of the tibia is approximately 25 mm and a similar space is available from the posterior surface of the calf. With the wire tensioned to at least 1200 N, the proximal ring is still able to rotate around this wire as its axis. Before the second fixation point is secured (a half pin on the distal ring – *vide infra*), the ring is held in position so as to be orthogonal to the axis of the tibia in the lateral view – whilst an X-ray image may help here, it is often not necessary and an estimate of the position of the fixator with respect to the limb

**Table 1** Estimated entry and exit points for the coronal plane reference wire in relation to tibial plateau joint line – based on an 85° medial proximal tibial angle

Tibial plateau width, mm	Lateral entry point, mm	Medial exit point, mm
60	15	5
70	15	6
80	15	7
90	15	8
60	20	7
70	20	8
80	20	9
90	20	10



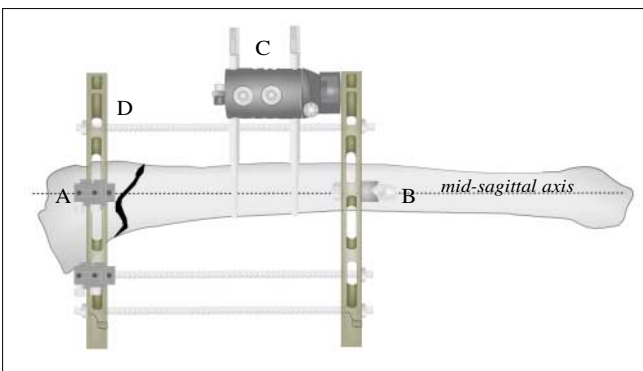


**Fig. 13** Tilting the proximal ring so as to obtain orthogonal positioning to the longitudinal axis of tibia

suffices and with practice is as good as X-ray guidance. A rule of thumb is to tilt the ring  $10^{\circ}$ – $15^{\circ}$  posteriorly from the anterior slope of the tibial tuberosity (Fig. 13).

Attention is now directed to the distal ring. A single screw clamp is positioned on the distal surface of the distal ring on the medial side: this clamp is attached to the corresponding hole to that of the medial sliding clamp unit of the proximal ring. This ensures the half pin and wire lie in line along the mid-sagittal axis and reduces the amount of sagittal plane translation that may arise from indiscriminate reference wire and half pin placement (these corresponding holes are easily identified as the Orthofix ring surface is marked). The half pin is inserted in the coronal plane, orthogonal to the axis of the tibia. When accomplished, both attachments of the proximal and distal ring to the tibia are orthogonal to the axis of the tibia and help in ensuring that any residual angulation in the coronal plane at the MDD is also minimised. Once this screw is attached, the remainder of fixator application is relatively simple:

- The Sheffield clamp is positioned on the proximal surface of the distal ring with the screws targeted just medial to the tibial crest and in the sagittal plane (Fig. 14 C). Two screws are used in slots 1 and 5 of the clamp (Fig. 14 B). At this point the third threaded rod can be added between the two rings, usually in an anterior position. Leaving this rod to the end allows the Sheffield clamp to be optimally positioned first (Fig. 14 D).



**Fig. 14** Final two-ring assembly for proximal tibial fractures

- A further two wires are inserted in the proximal ring; one through the centre of the ring and the other on the distal surface. This ensures a wide separation of the wires about the proximal ring and the crossing angle of the wires can be maximised by following the order and direction shown in Figure 12. The second and third wires can be of the peripheral olive type and affixed to the ring using a combination of a wire securing pin and sliding clamp unit.

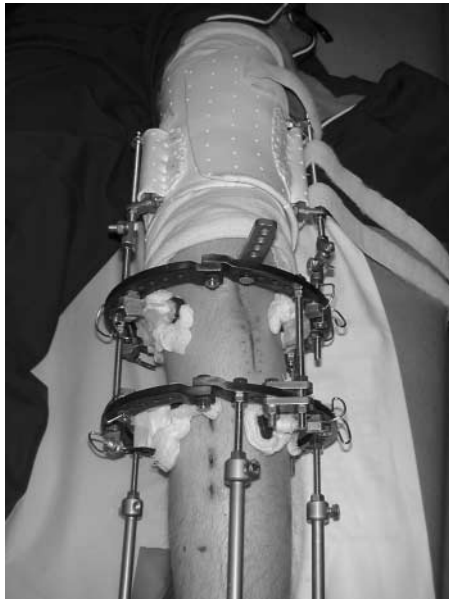
Three wires in the proximal ring and three half pins in the distal is sufficient fixation for stability; an additional wire in the proximal ring and another half pin in the distal may be used in exceptionally heavy patients. At completion of fixator application, any distraction at the MDD must be eliminated. This can be done by reducing the distance between the two rings through adjusting the length of the threaded rods. Should there be a significant malreduction at the end of application of the fixator, the threaded rods should be substituted for reduction units; these facilitate some reduction of angulation, translation, rotation and length without the need for altering the wire or half pin position.

### Post-operative care/rehabilitation

Immediate post-operative issues relate to analgesia and control of swelling. The leg is elevated (using pillows or by raising the end of the bed) and arterio-venous impulse foot pumps can be used. Opioid analgesics are preferred over non-steroidal anti-inflammatory agents (NSAIDs) because of concerns that NSAIDs adversely affect bone healing. Thromboprophylaxis is also advocated.

The circular fixator should be viewed as a component of the total care of these fractures and not the sole constituent. Achieving fracture reduction and stabilisation is only the initial step; good post-operative rehabilitation is essential. Joint positioning and splintage prevent contractures, which may otherwise develop rapidly. Early joint exercises are encouraged, and depending on the adequacy of articular fixation and on associated ligament injuries, weight bearing may be permitted to a limited degree (about 30%) in the first 6 weeks and then encouraged to the 'as tolerated' maxim. In cases with significant ligament instability or a very proximal MDD, the support may bridge the knee by using a femoral brace affixed to the fixator or simply extending the fixator itself (Fig. 15).

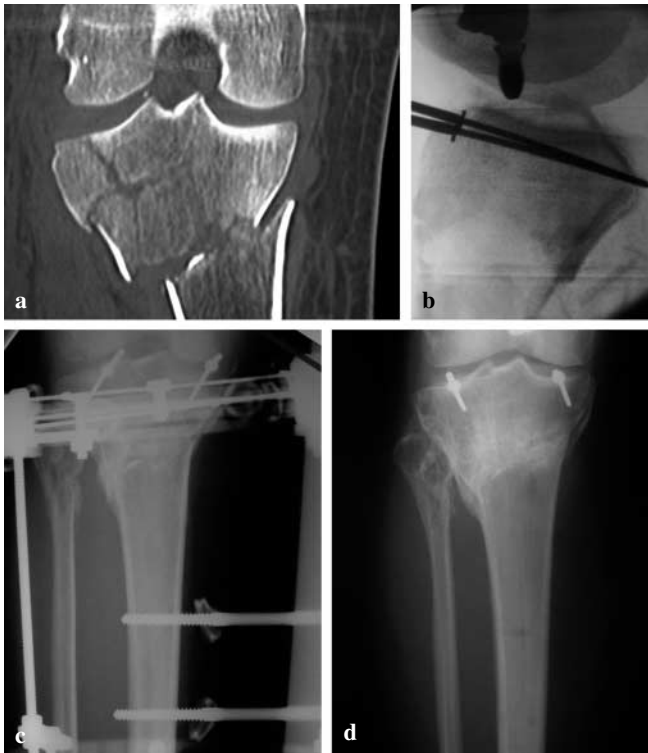Physiotherapy for rehabilitating both joint ROM and muscle control is needed. A pin site care regime will help minimise problems; many different protocols exist but scientific evidence is sparse [21]. The potential for wires to catch synovial reflections at the tibial plateau should caution against very proximal wire placement; perforation of the synovium should be suspected if any wire site persistently drains serous fluid, and arrangements should be made to relocate the wire.



**Fig. 15** Brace extension for an unstable knee as attached to an Ilizarov fixator

#### Fixator removal

It is not uncommon for these high-energy injuries to unite without recourse to additional procedures (e.g., bone grafting) if the following details were adhered to:



**Fig. 16** 41C tibial plateau fracture treated percutaneously using fracture fixation pins and a circular external fixator

- attention is paid to minimising surgical trauma during exposure, dissection and fracture reduction;
- fragment contact is achieved after reduction;
- the patient encouraged to bear weight and use the limb in a functional manner in rehabilitation.

Depending on the degree of comminution and soft tissue damage, many of these fractures will unite in 14–20 weeks. Callus formation is inversely proportional to the remaining gaps between the fragments; well reduced fractures exhibit a ‘blurring of fracture line’ phenomenon on X-ray rather than the usual florid callus (Fig. 16). Clues as to clinical union can be sought from the manner the patient walks – at union, the patient walks without much discomfort (if any) and often suggests to the surgeon the fracture is united! Cast protection after fixator removal is not mandatory; much will depend on the quality of radiological union and the ability of the patient to comply with a limited period of partial weight-bearing for 2–4 weeks should a cast or brace not be used.

**Summary** *Circular external fixation for high-energy tibial plateau fractures is a tool for the surgeon who has to manage these injuries. If used in the manner above, with appropriate attention to the detail described, it elevates surgical strategy from a ‘one technique fits all’ approach to a considered and balanced outlook on a group of very heterogeneous injuries.*

#### References

1. McQueen MM, Gaston P, Court-Brown CM (2000) Acute compartment syndrome: who is at risk? *J Bone Joint Surg Br* 82:200–203
2. Schatzker J, McBroom R, Bruce D (1979) The tibial plateau fracture: the Toronto experience 1968–1975. *Clin Orthop Relat Res* 138:94–104
3. Orthopaedic Trauma Association (1996) Fracture and dislocation compendium: introduction. *J Orthop Trauma* 10[Suppl 1]:5–9
4. Anglen JO, Aletto T (1998) Temporary transarticular external fixation of the knee and ankle. *J Orthop Trauma* 12:431–434
5. Haidukewych GJ (2002) Temporary external fixation for the management of complex intra- and periarticular fractures of the lower extremity. *J Orthop Trauma* 16:678–685
6. Kowalski M, Schemitsch EH, Harrington RM et al (1996) Comparative biomechanical evaluation of different external fixation sidebars: stainless-steel tubes versus carbon fiber rods. *J Orthop Trauma* 10:470–475
7. Tencer AF, Claudi B, Pearce S et al (1983) Development of a variable stiffness external fixation system for stabilisation of segmental defects of the tibia. *J Orthop Res* 1:395–404
8. Huiskes R, Chao EYS (1986) Guidelines for external fixation frame rigidity and stresses. *J Orthop Res* 4:68–75

9. Egol KA, Tejwani NC, Capla EL et al (2005) Staged management of high-energy proximal tibia fractures (OTA types 41): the results of a prospective, standardized protocol. *J Orthop Trauma* 19:448–455; discussion 456
10. Humphrey C, Dirschl D, Ellis T (2005) Interobserver reliability of a CT-based fracture classification system. *J Orthop Trauma* 19:616–622
11. Chan PS, Klimkiewicz JJ, Lucchetti WT et al (1997) Impact of CT scan on treatment plan and fracture classification of tibial plateau fractures. *J Orthop Trauma* 11:484–489
12. Carlson DuWayne A (2005) Posterior bicondylar tibial plateau fractures. *J Orthop Trauma* 19:73–78
13. Westmoreland GL, McLaurin TM, Hutton WC (2002) Screw pullout strength: a biomechanical comparison of large-fragment and small-fragment fixation in the tibial plateau. *J Orthop Trauma* 16:178–181
14. Karunakar MA, Egol KA, Peindl R et al (2002) Split depression tibial plateau fractures: a biomechanical study. *J Orthop Trauma* 16:172–177
15. Claes L, Augat P, Suger G et al (1997) Influence of size and stability of the osteotomy gap on the success of fracture healing. *J Orthop Res* 15:577–584
16. Claes L, Heitemeyer U, Krischak G et al (1999) Fixation technique influences osteogenesis of comminuted fractures. *Clin Orthop* 365:221–229
17. Claes L, Eckert-Hubner K, Augat P et al (2002) The effect of mechanical stability on local vascularization and tissue differentiation in callus healing. *J Orthop Res* 20:1099–1105
18. Claes, Laule J, Wegner K et al (2000) The influence of stiffness of the fixator on maturation of callus after segmental transport. *J Bone Joint Surg Br* 82:142–148
19. Yang L, Nayagam S, Saleh M (2003) Stiffness characteristics and inter-fragmentary displacements with different hybrid external fixators. *Clin Biomech* 18:166–172
20. Yang L, Nayagam S, Saleh M (2000) The effect of different wire and screw combinations on the stiffness of a hybrid external fixator. *Proc Inst Mech Eng* 214:669–676
21. Davies R, Holt N, Nayagam S (2005) The care of pin sites with external fixation. *J Bone Joint Surg Br* 87:716–719