

This article is licensed under the Creative Commons Attribution-NonCommercial 4.0 International License (CC BY-NC) (<http://www.karger.com/Services/OpenAccessLicense>). Usage and distribution for commercial purposes requires written permission.

Single Case

Clostridium septicum: An Unusual Link to a Lower Gastrointestinal Bleed

Kegan Jessamy^a Fidelis O. Ojevwe^a Ezinnaya Ubagharaji^a
Anuj Sharma^a Obiajulu Anozie^a Christy Ann Gilman^a Sekou Rawlins^b

^aDepartment of Medicine, SUNY Upstate Medical University, Syracuse, N.Y., USA;

^bGastroenterology Division, Department of Medicine, SUNY Upstate Medical University, Syracuse, N.Y., USA

Keywords

Clostridium septicum · Colon cancer · Lower gastrointestinal bleeding

Abstract

Clostridium septicum is a highly virulent pathogen which is associated with colorectal malignancy, hematological malignancy, immunosuppression, diabetes mellitus and cyclical neutropenia. Presentation may include disseminated clostridial infection in the form of septicemia, gas gangrene, and mycotic aortic aneurysms. We report the case of a 62-year-old female presenting with necrotizing fasciitis of her left thigh and subsequently developing rectal bleeding. While she was being treated with empiric antibiotics, her blood culture was found to be positive for *C. septicum*. We would like to highlight the importance of early colorectal cancer screening in minimizing the occurrence of undetected tumors which provide an optimal growth environment for *C. septicum*, leading to localized and/or remote infection.

© 2016 The Author(s)
Published by S. Karger AG, Basel

Introduction

Clostridium septicum is a highly virulent pathogen which has been known to be associated with colorectal malignancy, hematological malignancy (acute myeloid leukemia, myelodysplastic syndrome), immunosuppression, diabetes mellitus, and cyclical neutropenia [1–4]. It has a wide range of presentations which are inclusive of but not limited to septicemia, gas gangrene, and mycotic aortic aneurysms. *C. septicum* is responsible for 1.3% of all clostridial infections, with reported mortality rates close to 60%, which demonstrates the virulent nature of this pathogen [2, 5, 6]. The reported rates of underlying malignancy as a result of *C. septicum* infection range from 50 to 85% [7]. Here we discuss the case of a 62-year-old female who developed a lower gastrointestinal bleed as a result of *C. septicum* infection, and the importance of understanding the link between *C. septicum* and malignancy.

Case Presentation

A 62-year-old female presented with necrotizing fasciitis of her left thigh and groin. She had noticed a carbuncle 2 weeks prior that gradually grew in size and was associated with chills without pyrexia. Her past medical history was significant only for diet-controlled type 2 diabetes mellitus (most recent hemoglobin A1c level 5.7%). Medications prior to admission included ascorbic acid 1,000 mg orally daily, and she denied using any non-steroidal anti-inflammatory drugs. She also denied any history of smoking or illicit drug use. She drank alcohol (1–2 bottles of beer) on occasions, two to three times per year. On examination, she was hypotensive with a blood pressure of 87/63 mm Hg and had a pulse of 92 bpm with a corresponding temperature of 36.6°C. She was noted to have severe tenderness to her entire left thigh with posterior crepitus. She received intravenous fluid resuscitation and was sent for urgent imaging. Laboratory investigations were significant for a hemoglobin of 7.8 g/dl, a mean corpuscular volume of 71.9 fl, a white blood cell count of $11.9 \times 10^3 \mu\text{l}$, a platelet count of $151 \times 10^3 \mu\text{l}$, a reticulocyte count of 3.39%, an immature reticulocyte fraction of 35.80%, a serum iron level of 7.0 $\mu\text{g/dl}$, a serum transferrin level of 123 mg/dl, and a total iron-binding capacity of 7.0 $\mu\text{g/dl}$. Direct Coombs test and fecal occult blood testing were negative. A CT scan of the left lower extremity was significant for air in the posterior thigh muscles, extending superiorly to the gluteus maximus and distally to the knee, indicative of necrotizing fasciitis (fig. 1).

The patient was started on intravenous vancomycin, clindamycin, and piperacillin/tazobactam. After aggressive fluid resuscitation for septic shock she was taken to the operating room for fasciotomy and debridement. Intraoperatively, she was found to have extensive devitalized tissue and necrosis within her left thigh. The surgical team consisting of general, vascular, and orthopedic surgeons collectively made the decision to perform disarticulation of the left lower extremity to minimize spread of tissue infection. Intraoperative wound culture grew *C. septicum*. Postoperatively, she was managed in the intensive care unit with the intention to perform screening colonoscopy in 2 months at the patient's request. Given her wound culture sensitivities, her antibiotic regimen was subsequently changed to clindamycin and piperacillin/tazobactam.

On postoperative day 12 she was noted to have frank blood in her fecal management tube which had previously been placed to minimize contamination of her hip wound. Emergent colonoscopy was performed and revealed a fungating polypoid, sessile and ulcerated partially obstructing large mass in her cecum (fig. 2) which on histopathology was consistent

with well-differentiated invasive adenocarcinoma. She underwent a laparoscopic right hemicolectomy 9 days later. CT imaging of the abdomen, pelvis, and thorax was negative for metastatic spread. One year after surgery, the patient continues to be followed up in the outpatient setting without any signs or symptoms of recurrence of colon cancer.

Discussion

C. septicum is a motile, Gram-positive, spore-forming bacillus. Its motility and production of α -, β -, γ -, and δ -exotoxins confer significant virulence to this organism in the manifestation of disease. The α -toxin is responsible for tissue necrosis and hemolysis [6]. *C. septicum* can produce spontaneous or remote myonecrosis in the absence of prior trauma [6]. The hypoxia and acidity of the tumor environment is favorable toward spore germination and subsequent active infection [1]. Bowel inflammation leads to bacterial translocation and infection of distant tissues. This organism is more aerotolerant compared to *C. perfringens*, allowing it to infect healthy tissues [3].

At times, there may be no clinical manifestations of colon cancer, and the diagnosis could be missed as some physicians may not be aware of the association of *C. septicum* with colonic malignancy. If colorectal cancer is diagnosed in the context of *C. septicum* infection, other malignancies associated with *C. septicum* are less likely to be present.

Once a diagnosis has been made, prompt surgical therapy is necessary for debridement of devitalized tissue. Disarticulation and muscle resection are done to prevent further spread if muscle necrosis has spread across a joint. Data from previous studies have shown that *C. septicum* is susceptible to a wide range of antibiotics such as clindamycin, penicillin, and metronidazole [8]. Other studies comparing treatment before and after the use of hyperbaric oxygen show a decrease in mortality from 70 to 25% [9], hence hyperbaric oxygen therapy is worthwhile despite the aerotolerance of *C. septicum*.

Current colon cancer screening guidelines suggest colon cancer screening from the age of 50 years or at age 40 years or 10 years before the youngest case in the immediate family for those at increased risk [10]. It is unfortunate that this patient was not screened for colon cancer prior to presentation and that her endoscopic finding was only encountered as a result of her rectal bleeding. This highlights the importance of screening, which could have potentially prevented her from developing a colon cancer tumor which likely served as a nidus for her *C. septicum* overgrowth which led to necrotizing fasciitis and subsequent limb amputation.

Conclusion

C. septicum is a highly virulent organism with mortality rates as high as 60% [2, 6] and a clear association with various malignancies. The tumor environment provides an adequate environment encouraging the growth and spore formation of *C. septicum*, which then leads to localized or remote infection [6]. In order to minimize the development of these infections which occur in the context of colon cancer, early colorectal cancer screening is prudent. Physicians should always be aware and vigilant of the association of *C. septicum* and colon cancer.

Statement of Ethics

Written informed consent was obtained from the patient for publication of this case report and the accompanying figures.

Disclosure Statement

The authors declare that they have no competing interests.

References

- 1 Khan AA, Davenport K: A reminder of the association between *Clostridium septicum* and colonic adenocarcinoma. *Int Semin Surg Oncol* 2006;3:12.
- 2 Mirza NN, McCloud JM, Cheetham MJ: *Clostridium septicum* sepsis and colorectal cancer – a reminder. *World J Surg Oncol* 2009;7:73.
- 3 Chew SS, Lubowski DZ: *Clostridium septicum* and malignancy. *ANZ J Surg* 2001;71:647–649.
- 4 Panikkath R, Konala V, Panikkath D, Umyarova E, Hardwicke F: Fatal *Clostridium septicum* infection in a patient with a hematological malignancy. *Proc (Bayl Univ Med Cent)* 2014;27:111–112.
- 5 Seder C, Kramer M, Long G, Uzieblo M, Shanley C, Bove P: *Clostridium septicum* aortitis: Report of two cases and review of the literature. *J Vasc Surg* 2009;49:1304–1309.
- 6 Larson CM, Bubrick MP, Jacobs DM, West MA: Malignancy, mortality and medicosurgical management of *Clostridium septicum* infection. *Surgery* 1995;118:592–598.
- 7 Kennedy CL, Krejany EO, Young LF, O'Connor JR, Awad MM, Boyd RL, Emmins JJ, Lyras D, Rood JI: The α -toxin of *Clostridium septicum* is essential for virulence. *Mol Microbiol* 2005;57:1357–1366.
- 8 Ramkissoon Y, Ghoorahoo H, Haydock S, O'Shaughnessy K: An unusual complication of carcinoma of the caecum. *Postgrad Med J* 2000;76:438, 451–452.
- 9 Hart GB, Lamb RC, Strauss MB: Gas gangrene. *J Trauma* 1983;23:991–1000.
- 10 Levin B, Lieberman DA, McFarland B, Andrews KS, Brooks D, Bond J, Dash C, Giardiello FM, Glick S, Johnson D, Johnson CD, Levin TR, Pickhardt PJ, Rex DK, Smith RA, Thorson A, Winawer SJ; American Cancer Society Colorectal Cancer Advisory Group; US Multi-Society Task Force; American College of Radiology Colon Cancer Committee: Screening and surveillance for the early detection of colorectal cancer and adenomatous polyps, 2008: a joint guideline from the American Cancer Society, the US Multi-Society Task Force on Colorectal Cancer, and the American College of Radiology. *Gastroenterology* 2008;134:1570–1595.

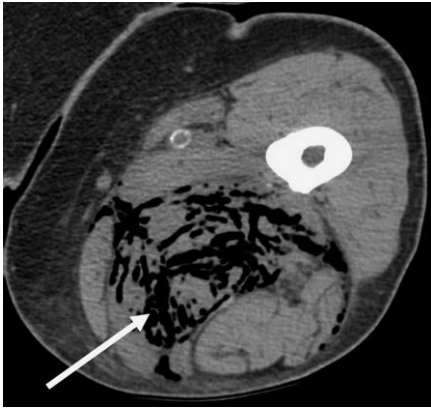


Fig. 1. CT scan of the left lower extremity. The arrow illustrates extensive gas within the soft tissues of the left lower extremity.

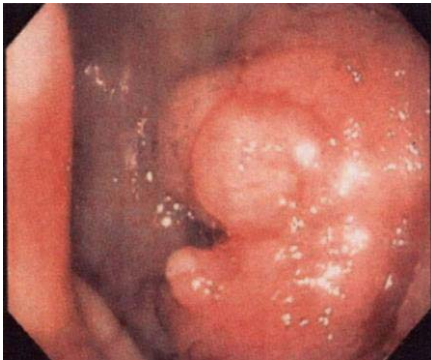


Fig. 2. Colonoscopy showing a large obstructing mass in the cecum.