


## Case report

# COVID-19 presenting as severe, persistent abdominal pain and causing late respiratory compromise in a 33-year-old man

Sarah Catherine Walpole <sup>1,2</sup>, Rebecca McHugh,<sup>1</sup> Julie Samuel,<sup>3</sup> Matthias Ludwig Schmid<sup>1</sup>

<sup>1</sup>Department of Infection & Tropical Medicine, Newcastle Upon Tyne Hospitals NHS Foundation Trust, Newcastle Upon Tyne, UK

<sup>2</sup>Faculty of Medical Sciences, Newcastle University, Newcastle, United Kingdom

<sup>3</sup>Department of Microbiology, Newcastle Upon Tyne Hospitals NHS Foundation Trust, Newcastle Upon Tyne, UK

## Correspondence to

Dr Sarah Catherine Walpole; sarah.walpole@doctors.org.uk

Accepted 22 May 2020

## SUMMARY

A 33-year-old man presented repeatedly with severe abdominal pain and diarrhoea. Renal colic was suspected, and he was admitted for pain management. Questioning elicited an additional history of sore throat and mild, dry cough. Inflammatory markers were mildly raised (C reactive protein (CRP) 40 mg/L). Initial nasopharyngeal swabs were negative for severe acute respiratory syndrome coronavirus-2 (SARS-CoV-2) by PCR. CT of the kidneys, ureters and bladder (CT KUB) was normal; however, CT of the thorax showed multifocal bilateral peripheral areas of consolidation consistent with COVID-19 infection. He developed respiratory compromise and was transferred to the intensive care unit (ICU). Sputum was positive for SARS-CoV-2 by PCR, and culture grew *Yersinia enterocolitica*. He recovered following supportive management and treatment with piperacillin–tazobactam.

## BACKGROUND

Of 136 COVID-19 positive patients in Wuhan, only 5 (3.6%) presented with vomiting and 3 (2.2%) presented with abdominal pain,<sup>1</sup> and of 651 COVID-19 patients in Zhejiang, 74 had abdominal symptoms.<sup>2</sup> This report details an uncommon but important presentation of COVID-19 in a young, normally fit and well 33-year-old man. COVID-19 infection would have been missed, had he not represented twice with ongoing symptoms.

The case highlights the importance of having a high suspicion of COVID-19 in patients with an unexplained fever, even where respiratory symptoms are not elicited and nasopharyngeal swab is negative for severe acute respiratory syndrome coronavirus-2 (SARS-CoV-2). In this case, CT of the thorax was key to the diagnosis and deep respiratory tract samples provided virological confirmation.

## CASE PRESENTATION

A 33-year-old man with no medical history presented to the accident and emergency department three times in 24 hours with severe abdominal pain. He reported fever for 3 days, abdominal pain for 1 day and one episode of vomiting. He is a non-smoker, usually fit and well. His wife and children were asymptomatic.

On the first presentation, he was diagnosed with probable gastroenteritis and advised about symptom control and self-isolation. On the second attendance, he was advised that his symptoms were in keeping with a viral infection, and discharged with analgesia and safety-netting advice. Bloods showed normal white cell count, mild lymphopaenia ( $0.95 \times 10^9/L$ ), mild thrombocytopenia ( $10^4$  g/L), normal renal function, normal liver function and C reactive protein (CRP) 40 mg/L (table 1).

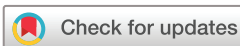When he presented a third time with worsening abdominal pain, renal colic was suspected due to the nature and severity of the pain. CT of the kidneys, ureters and bladder (CT KUB) was normal, but the scan captured the bases of the lungs which were abnormal in keeping with COVID-19; therefore, a CT of the thorax was completed (figure 1).

The patient was admitted to the infectious diseases ward for observation and analgesia. Surgical causes of abdominal pain were excluded based on clinical examination and further review of the CT KUB. Further questioning revealed a history of sore throat 5 days previously and dry cough for the last four days (admission was on day 5 of symptoms). His temperature was 38.5°C; other observations were within normal limits (heart rate 77 bpm, blood pressure (BP) 121/73 mmHg, respiratory rate (RR) 18 breaths/min and SpO<sub>2</sub> 96% on air). Empirical piperacillin–tazobactam treatment was started for possible bacterial pneumonia. Blood cultures and nasopharyngeal swabs for SARS-CoV-2 were sent. Swabs returned negative for SARS-CoV-2.

On day 2 of admission, he developed small-volume haemoptysis. Sputum samples were sent as a next line of investigation for SARS-CoV-2. He developed an oxygen requirement of 4 L via nasal cannula to maintain SpO<sub>2</sub> above 94%.

On day 3 of admission, his oxygen requirement and the volume of haemoptysis continued to increase. He required 60% FiO<sub>2</sub> via venturi mask to maintain SpO<sub>2</sub> of 94%. His RR rose to 32 breaths/min. Sputum was positive for SARS-CoV-2. Chest x-ray showed progressive consolidation (figure 2) compared with the previous CT. He was transferred to intensive care unit (ICU).

He improved on ICU without needing intubation or ventilation and was stepped down to the infectious diseases ward after 48 hours. He developed loose stools, which were negative for *Clostridium*



© BMJ Publishing Group Limited 2020. No commercial re-use. See rights and permissions. Published by BMJ.

**To cite:** Walpole SC, McHugh R, Samuel J, et al. *BMJ Case Rep* 2020;**13**:e236030. doi:10.1136/bcr-2020-236030

**Table 1** Blood results during admission

Day of admission	White cell count ( $\times 10^9/L$ )	Neutrophils ( $\times 10^9/L$ )	Lymphocytes ( $\times 10^9/L$ )	CRP (mg/L)	Ferritin ( $\mu g/L$ )	LDH (U/L)	ALT (U/L)
Day 1	6.78	5.50	0.95	40			20
Day 2	6.13	4.55	1.17	49		257	36
Day 4	7.43	5.71	1.37	94	954	368	48
Day 6	8.84	7.14	1.29	96			128
Day 7	8.52	6.34	1.30	49	1177	347	95
Day 9	9.28	6.74	1.39	52			191

ALT, alanine transaminase; CRP, C reactive protein; LDH, lactate dehydrogenase.

*difficile* or other pathogens. *Yersinia enterocolitica* was cultured from sputum. He completed a 5-day course of intravenous piperacillin-tazobactam and was gradually weaned off oxygen. He was discharged on day 9 of admission (day 13 of illness) with only mild residual abdominal pain.

The patient's bilirubin and alkaline phosphatase (ALP) remained normal throughout admission, while alanine aminotransferase (ALT) was elevated.

CT of the thorax (figure 1) showed multifocal peripheral patches of consolidation - greater than 3 cm in diameter with air bronchograms running through - in all but the left upper lobe; a pattern of consolidation which is typical for COVID-19.<sup>3,4</sup>

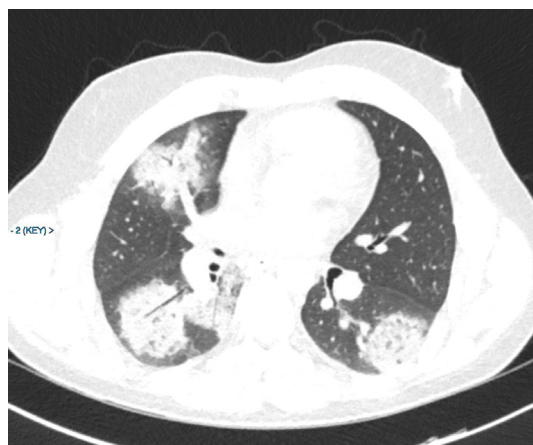Reverse transcription PCR for SARS-CoV-2 RdRp gene from Public Health England (PHE) was used for COVID-19 testing (nasopharyngeal swab negative and sputum positive).

Sputum culture grew *Y. enterocolitica*, resistant to amoxicillin and co-amoxiclav but otherwise fully sensitive. Of 669 *Y. enterocolitica* sample reports of PHE between 2004 and 2018, 8 (1.2%) were grown from sputum samples, 2 were grown from pleural fluid and 1 was grown from bronchial washings.<sup>5</sup> In our patient, there was no growth from stool or blood cultures (notably, he had already completed 4 days of piperacillin-tazobactam when the stool sample was taken).

A senior radiology consultant confirmed that on CT of the KUB, allowing for the lack of contrast, the bowel appeared normal with no apparent source of *Yersinia* infection.

**DIFFERENTIAL DIAGNOSIS**

On initial presentation, the patient was diagnosed with gastroenteritis due to predominant symptoms of diarrhoea and abdominal pain. Renal colic or pyelonephritis was later suspected due to the severity of abdominal pain with only mildly raised CRP.



**Figure 1** CT scan at admission showing multifocal bilateral consolidation.

Based on CT of the thorax, differential diagnoses at admission were COVID-19-associated pneumonia or a cryptogenic organising pneumonia. COVID-19 was eventually confirmed by both the clinical picture of respiratory deterioration and a sputum sample, which was PCR-positive for SARS-CoV-2. His sputum culture results, in the absence of a stool culture prior to antibiotic treatment, suggest *Y. enterocolitica* co-infection. His abdominal pain was likely due to viral gastroenteritis due to COVID-19, and with *Y. enterocolitica* infection likely contributing to his gastrointestinal symptoms.

**TREATMENT**

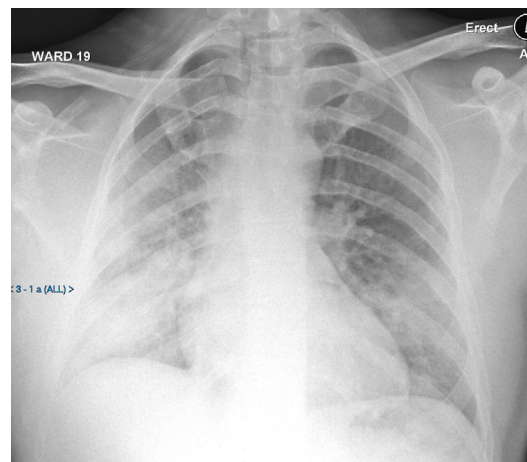
Our patient was managed with supportive care, including oxygen therapy, and empirical piperacillin-tazobactam. This empirical 5-day antibiotic course was sufficient to cover *Y. enterocolitica* co-infection. The recovery trial was not yet running at the time of his admission and a decision was made not to use experimental treatments.

**OUTCOME AND FOLLOW-UP**

The patient was discharged home on day 9 of his admission. He called again for advice 2 days after discharge due to ongoing abdominal pain, but with no concerning features, he was given advice about home management. He was followed up at 6 weeks; his symptoms had resolved and he had returned to work. Full blood count, urea and electrolytes, CRP and liver function tests were normal. Repeat CT of the thorax was requested.

**DISCUSSION**

Given our rapidly evolving understanding of COVID-19, clinical guidance changed over the course of this patient's 10-day



**Figure 2** Chest X-ray, on day 3, showing worsening peripheral consolidation. AP, anteroposterior.

admission. Following guidance from 6 April 2020, UK clinical criteria for testing for SARS-CoV-2 did not include abdominal pain,<sup>5</sup> which in this patient was the predominant symptom. Only on deeper questioning post-CT scan did the patient's respiratory symptoms become apparent. Alongside COVID-19, our patient's respiratory specimen grew a rare respiratory tract pathogen, *Y. enterocolitica*.

Study of over 16 000 patients with COVID-19 in Europe found that 29% had enteric symptoms at admission, but only 4% had enteric symptoms alone at presentation.<sup>6</sup> Detailed evaluation of samples from nine patients with COVID-19 found that stool samples were SARS-CoV-2 PCR positive between days 6 and 12 of symptoms, but SARS-CoV-2 was never successfully isolated from stool; therefore, replication in the gastrointestinal tract is likely, but there is no evidence of fomite-based transmission.<sup>7</sup> We suggest that any unusual presentation to hospital prompts questions for COVID-19 typical symptoms, with a low threshold for investigation for COVID-19 with nasopharyngeal swabs, sputum analysis±chest X-ray or CT of the thorax.

Of all reports of *Y. enterocolitica* grown in laboratories in England in 2004–2018, 12.2% were from blood cultures and a further 3.2% were from other extraintestinal sites.<sup>8</sup> A case report from the USA details *Y. enterocolitica* culture from sputum of a patient who developed acute respiratory distress syndrome requiring intubation.<sup>9</sup> Further case reports include a 60-year-old immunosuppressed man with blood cultures, stool and bronchoalveolar lavage positive for *Yersinia*,<sup>10</sup> and a 70-year-old and

an 80-year-old with pneumonia and blood cultures positive for *Yersinia*.<sup>11 12</sup>

**Acknowledgements** We thank Dr Colin Ripley for his contribution to interpreting and reproducing CT scan and X-ray images.

**Contributors** SCW and RMcH collected information and wrote the case report. MLS and JS contributed to revising and finalising the manuscript. All authors were involved in the patient's care.

**Funding** The authors have not declared a specific grant for this research from any funding agency in the public, commercial or not-for-profit sectors.

**Competing interests** None declared.

**Patient consent for publication** Obtained.

**Provenance and peer review** Not commissioned; externally peer reviewed.

This article is made freely available for use in accordance with BMJ's website terms and conditions for the duration of the covid-19 pandemic or until otherwise determined by BMJ. You may use, download and print the article for any lawful, non-commercial purpose (including text and data mining) provided that all copyright notices and trade marks are retained.

#### ORCID iD

Sarah Catherine Walpole <http://orcid.org/0000-0003-2600-0386>

#### REFERENCES

- Wang D, Hu B, Hu C, *et al*. Clinical characteristics of 138 hospitalized patients with 2019 novel coronavirus-infected pneumonia in Wuhan, China. *JAMA* 2020;323:1061.
- Jin X, Lian J-S, Hu J-H, *et al*. Epidemiological, clinical and virological characteristics of 74 cases of coronavirus-infected disease 2019 (COVID-19) with gastrointestinal symptoms. *Gut* 2020;69:1002–9.
- Xu X, Yu C, Qu J, *et al*. Imaging and clinical features of patients with 2019 novel coronavirus SARS-CoV-2. *Eur J Nucl Med Mol Imaging* 2020;47:1275–80.
- Han R, Huang L, Jiang H, *et al*. Early clinical and CT manifestations of coronavirus disease 2019 (COVID-19) pneumonia. *AJR Am J Roentgenol* 2020:1–6.
- Public Health England. COVID-19: investigation and initial clinical management of possible cases. Available: <https://www.gov.uk/government/publications/wuhan-novel-coronavirus-initial-investigation-of-possible-cases/investigation-and-initial-clinical-management-of-possible-cases-of-wuhan-novel-coronavirus-wn-cov-infection> [Accessed 13 Apr 2020].
- Docherty AB, Harrison EM, Green CA, *et al*. Features of 16, 749 hospitalised UK patients with COVID-19 using the ISARIC who clinical characterisation protocol. 2020.
- Wölfel R, Corman VM, Guggemos W, *et al*. Virological assessment of hospitalized patients with COVID-2019. *Nature* 2020;581:465–9.
- Hunter E, Greig DR, Schaefer U, *et al*. Identification and typing of *Yersinia enterocolitica* and *Yersinia pseudotuberculosis* isolated from human clinical specimens in England between 2004 and 2018. *J Med Microbiol* 2019;68:538–48.
- Rande A, Asfahan F, Sharma A, *et al*. *Yersinia enterocolitica* bacteremia leading to lung infection in liver cirrhosis. *Am J Respir Crit Care Med* 2018;197:A5227.
- Dempsey T, Kalra S. *Yersinia enterocolitica* pneumonia: a rare presentation of a common organism. *Am J Respir Crit Care Med* 2018;197:A3586.
- Wong KK, Fistek M, Watkins RR. Community-Acquired pneumonia caused by *Yersinia enterocolitica* in an immunocompetent patient. *J Med Microbiol* 2013;62:650–1.
- Nicolas X, Le Berre R, Ansart S, *et al*. [Bacteremia and pneumonia due to *Yersinia enterocolitica* serotype O:3 in an immunocompetent patient]. *Med Mal Infect* 2005;35:370–3.

#### Learning points

- ▶ This young, fit and previously well patient with COVID-19 presented with abdominal symptoms as his primary complaint, yet went on to develop respiratory compromise requiring high-level oxygen therapy.
- ▶ An initial nasopharyngeal severe acute respiratory syndrome coronavirus-2 (SARS-CoV-2) throat swab was negative. This case shows the value of sending sputum for PCR for SARS-CoV-2 where there is high suspicion of COVID-19 despite negative nasopharyngeal swabs.
- ▶ *Yersinia enterocolitica* is a recognised cause of abdominal pain and diarrhoea, and has grown infrequently from sputum samples in the context of pneumonia. This case may represent a first case of *Yersinia* co-infection with COVID-19.

Copyright 2020 BMJ Publishing Group. All rights reserved. For permission to reuse any of this content visit <https://www.bmj.com/company/products-services/rights-and-licensing/permissions/>  
BMJ Case Report Fellows may re-use this article for personal use and teaching without any further permission.

Become a Fellow of BMJ Case Reports today and you can:

- ▶ Submit as many cases as you like
- ▶ Enjoy fast sympathetic peer review and rapid publication of accepted articles
- ▶ Access all the published articles
- ▶ Re-use any of the published material for personal use and teaching without further permission

#### Customer Service

If you have any further queries about your subscription, please contact our customer services team on +44 (0) 207111 1105 or via email at [support@bmj.com](mailto:support@bmj.com).

Visit [casereports.bmj.com](http://casereports.bmj.com) for more articles like this and to become a Fellow