

Research Article

Production of Soluble Receptor Activator of Nuclear Factor Kappa-B Ligand and Osteoprotegerin by Apical Periodontitis Cells in Culture and Their Modulation by Cytokines

Miloš Duka,¹ Mile Eraković,¹ Zana Dolicanin,² Dara Stefanović,³ and Miodrag Čolić^{4,5} 

¹Clinic for Stomatology, Military Medical Academy, Belgrade, Serbia

²State University Novi Pazar, Serbia

³Institute for Radiology, Military Medical Academy, Belgrade, Serbia

⁴Medical Faculty of the Military Medical Academy, Belgrade, Serbia

⁵University of East Sarajevo, Medical Faculty Foča, R.Srpska, Bosnia and Herzegovina

Correspondence should be addressed to Miodrag Čolić; mjcolic@eunet.rs

Received 4 December 2018; Accepted 5 February 2019; Published 18 March 2019

Guest Editor: Nurcan Buduneli

Copyright © 2019 Miloš Duka et al. This is an open access article distributed under the Creative Commons Attribution License, which permits unrestricted use, distribution, and reproduction in any medium, provided the original work is properly cited.

RANKL, a bone-destructive cytokine, and OPG, its osteoprotective counterpart, are expressed in periapical lesions (PLs), which represent histopathological manifestations of apical periodontitis. However, their regulation in PLs has not been elucidated yet. Therefore, our aim was to study the production of RANKL and OPG and their modulation by pro- and anti-inflammatory cytokines in PL cell cultures. Isolated PL cells were cultured alone or with addition of TNF- α , IFN- γ , IL-17, IL-4, IL-10, and IL-33, respectively. The levels of RANKL and OPG in supernatants were measured by ELISA. The proportion of CD3⁺ (T cells) and CD19⁺/CD138⁺ (B cells/plasma cells) within isolated PLs was determined by immunocytochemistry. The levels of RANKL were higher in cultures of symptomatic PLs compared to asymptomatic PLs and PLs with the dominance of T cells (T-type lesions) over B cells/plasma cells (B-type lesions). A higher proportion of osteodestructive processes (RANKL/OPG ratio > 1.0) were detected in symptomatic PLs. The production of RANKL was upregulated by IFN- γ and IL-17 and higher concentrations of IL-33. IL-10 and lower concentrations of IL-33 augmented the production of OPG. The addition of either RANKL or anti-RANKL antibody to the cultures did not modify significantly the production of OPG. In conclusion, this original PL cell culture model suggests that increased bone destruction through upregulated production of RANKL could be associated with exacerbation of inflammation in PLs with the predominance of Th1 and Th17 responses and increased secretion of IL-33. In contrast, IL-10 and lower levels of IL-33, through upregulation of OPG, may suppress osteolytic processes.

1. Introduction

Apical periodontitis is an opportunistic infection around the apical region, which is a consequence of spreading bacteria from the necrotic pulp [1]. This is a common disease in adults, with roughly one in three individuals affected [2]. The histopathological base of the disease consists of granuloma and radicular cysts, usually named periapical lesions (PLs). They are chronic processes, due to the inability of host defense mechanisms to eradicate the infection [3]. The pathophysiology of PL involves a complex host immune/inflammatory response to the bacteria and their products. The

same mechanisms may also cause the destruction of soft and hard tissues surrounding the root apex [4]. PLs are characterized by the infiltration of the periodontal tissue with different inflammatory cells such as neutrophil granulocytes, T and B cells, plasma cells, macrophages, dendritic cells, mast cells, and other cells of the innate immunity [5]. The composition of infiltrating cells and the functional and phenotypic properties of both infiltrating and stromal cells depend on the activation status of PLs which is under control of a series of cytokines [3]. The histopathologic endpoint of PL is bone loss, which may occur to increase vascularization at the apex, thus blocking the infection in the root canal [6, 7].

Bone loss is caused by osteolytic activity of osteoclasts in which the receptor activator of nuclear factor kappa-B ligand (RANKL) plays a crucial role. RANKL was initially identified as a cell membrane-bound ligand responsible for stimulation of osteoclast differentiation and bone resorption [8, 9], by mediating the cell-to-cell interaction between osteoblasts and osteoclast precursors. RANKL is also produced as a secreted ligand by osteoblasts, fibroblasts, and activated T and B cells as well as by the cells of the monocyte-macrophage lineage [10]. The metalloprotease-disintegrin TNF- α -converting enzyme mediates its cleavage into a soluble form. By activating its cognate RANK receptor on the surface of monocytes and macrophages, RANKL triggers the fusion of macrophages and their differentiation into mature osteoclasts with the bone resorption activity [11].

The action of RANKL is antagonized by osteoprotegerin (OPG). OPG is a soluble decoy receptor which blocks RANKL and, by preventing its interaction with RANK, inhibits osteoclast activation and subsequent bone resorption [12]. OPG is largely expressed by some epithelial cells, vascular endothelial cells, and lymphoid cells [13, 14]. The overall efficiency of RANKL on osteoclast formation and bone resorption is tightly coupled to the activity of OPG, as its natural inhibitor. Therefore, it is very important to study concomitantly the expression of these two molecules in sites of hard-tissue resorption, preferably as their relative RANKL/OPG ratio. The RANKL/RANK/OPG system is involved in pathogenesis of osteodestructive processes, including periodontitis and dentoalveolar development. Several papers described the expression of RANKL and OPG in both human and experimental animal PLs, by using immunohistochemistry, mRNA, or biofluid analyses, and the results have been summarized in a recent comprehensive review [15]. Generally, the review provides the evidence that higher RANKL expression and higher RANKL/OPG ratio are associated with periapical bone loss, but it does not give any conclusive information about their role as predictive markers, or their clinical significance. However, recent data showed that RANKL may play an immunoregulatory role since RANKL inhibition resulted in an unremitting proinflammatory response in experimental PLs, persistent high proinflammatory and effector CD4 responses, decreased migration of T regulatory cells (Tregs), and lower levels of IL-10 and TGF β [16]. All these data related to PLs are in contrast to a recent systematic review on biomarkers of alveolar bone resorption in gingival crevicular fluid, which showed that RANKL could be a central biomarker indicating osteoclastic activity and a diagnostic indicator for chronic periodontitis [17].

The expression of RANKL and OPG is under control of numerous factors, including cytokines, which play a crucial role in the regulation of immune/inflammatory reactions within PLs and are critical determinants of lesion outcome [4, 18]. In this context, proinflammatory cytokines, such as interleukin-1 (IL-1), IL-6, and tumor necrosis factor- α (TNF- α) as well as some chemokines, such as IL-8, orchestrate the recruitment and activation of innate immune cells, presumably neutrophil granulocytes and monocytes in the early inflammatory phase and T and B cells in the later inflammatory phase, respectively. A large number of clinical

and experimental results suggest that T-helper 1 (Th1) cells, by producing interferon- γ (IFN- γ), are involved in the progression of PLs and bone destruction, whereas T-helper 2 (Th2) cytokines, such as interleukin 4 (IL-4), IL-5, IL-10, and IL-33, are associated with the humoral immune response and attenuation of tissue damage [3, 4, 6]. It seems that Th9 and Th22 pathways may also contribute to human and experimental periapical lesion stability [19]. IL-17 may play a role in exacerbation of inflammation in PLs [20] and stimulation of osteolysis [21]. On the other hand, Foxp3+CD4+CD25+ Tregs downregulate immune response, inflammation, and osteolysis in PLs. Their effect is predominantly mediated by transforming growth factor- β (TGF- β) and IL-10 [22–24].

The development of PLs is a dynamic process in which osteolytic and osteoprotective mechanisms are tightly balanced. However, up to now no one study investigated how a particular cytokine modulates these processes in PLs by acting on RANKL and OPG production, and this was a primary interest in our study.

To address these questions, we used an original approach by studying the production of RANKL and OPG in PL cell cultures. We described this cell-culture model in our previous paper and found it as very suitable to study the pathophysiological mechanisms involved in the progression and restriction of PLs [25]. Therefore, the concrete aim of this work was (1) to examine the production of RANKL and OPG by PL cells in culture, to determine their ratio, and to show the relationship between these parameters and clinical presentation of PLs, their size, and their lymphocyte composition within isolated PL cells; (2) to study the modulatory effect of proinflammatory cytokines (TNF- α , IFN- γ , and IL-17), anti-inflammatory cytokines (IL-4 and IL-10), and IL-33, a cytokine showing anti- and proinflammatory activity [26] on RANKL and OPG production by PL cells; and (3) to check whether the production of OPG by PL cells is modulated by RANKL.

2. Materials and Methods

2.1. Periapical Lesion Samples. Human PLs ($n = 43$) were extracted at the Department for Oral Surgery, Clinic for Stomatology, Military Medical Academy (MMA), Belgrade, Serbia, at the time of teeth extraction or apicotomy. The study was approved by the Ethical Committee of MMA in compliance with the Helsinki Declaration, followed by an informed consent from patients. The average age of the patients was 35 years (range: 21–65 years). The patients with malignant and autoimmune diseases, as well as patients on the immunosuppressive/immunomodulatory therapy, or those on the therapy of systemic modifiers of bone metabolism, were excluded. All the patients included had not been treated with antibiotics for one month before PL excision. PLs were radiographically diagnosed using the standard equipment for intraoral radiography (Carestream CS 2200 Roentgen apparatus; Carestream Dental, Atlanta, GA, USA) and extraoral radiography of the maxillofacial region (orthopantomography and dental cone beam computed tomography (CBCT); LargeV Instrument Corp. Ltd, Beijing, China). The size of

radiolucent PLs on radiographs and tomographs was analyzed by adequate softwares, and smallest and largest diameters were measured. Three patients had two lesions on two different teeth. According to the presence or absence of clinical symptoms, PLs were classified as symptomatic ($n = 22$) or asymptomatic ($n = 21$).

The lesions were divided according to their size into small and large PLs. Small lesions ($n = 18$) were PLs whose mean diameter was less than 4.0 mm. The lesions whose mean diameter was higher than 5.0 mm were classified as large lesions ($n = 25$). No further division between specimens, regarding sex, age, etiology, or tooth type, was done. After extraction, PLs were immediately placed in a medium consisting of RPMI-1640 (Sigma-Aldrich, Taufkirchen, Germany) and antibiotics/antimycotic solution (Sigma-Aldrich) containing penicillin (100 units/ml), streptomycin (0.1 mg/ml), and amphotericin B (0.25 $\mu\text{g/ml}$) and then transported to the laboratory.

Some PL cell cultures ($n = 12$) were used to study the modulatory effect of pro- and anti-inflammatory cytokines on RANKL and OPG production.

2.2. Isolation of Cells from PLs. The cells from PLs were isolated by a procedure which has been previously introduced by our research group [5, 25] with some modifications. Briefly, periapical tissue was placed in a Petri dish containing 1 ml RPMI-1640 medium and cut into 2-3 mm diameter pieces using a scalpel. The tissue was then digested for 15 min with 0.05% collagenase type IV (Sigma-Aldrich) and 0.02% DNase (Sigma-Aldrich) in 5 ml RPMI-1640 medium in a cell incubator at 37°C. After that, the tissue was pressed through a stainless-steel mesh using a syringe plunger, filtered, and resuspended in RPMI-1640 medium containing 1 mM EDTA (Sigma-Aldrich). The remaining of the tissue was subjected to another round of digestion by using 0.05% collagenase/0.02% DNase and 0.1% trypsin (Sigma-Aldrich) for 20 min. The released cells were pooled, washed twice by centrifugation in the RPMI medium containing 0.5 mM EDTA at room temperature (400 g for 10 min), and counted. The viability of cells, determined by Trypan Blue dye, was higher than 90%. After that, cytopins were prepared from each sample of cells using a cytocentrifuge (Schandon 4, Thermo Fisher Scientific, Waltham, MS, USA) on poly-L-lysine- (Sigma-Aldrich) coated glass slides. The cytopins were stained with May-Grünwald-Giemsa (Sigma-Aldrich) or used for immunocytochemistry.

2.3. Immunocytochemistry. For immunostaining, anti-CD3 monoclonal antibody (mAb) (Abcam, Cambridge, UK), anti-CD19, and anti-CD138 (mAbs) (both from Serotec, Oxford, UK) were used. Rabbit anti-mouse peroxidase-conjugated Ig was purchased from DAKO (Glostrup, Denmark). Cytopins were fixed with 2% pararosaniline (Sigma-Aldrich) for 2 min at room temperature, washed with phosphate-buffered saline (PBS) for 10 min, blocked with rabbit serum for 20 min, and washed with PBS. After that, cytopins were incubated for 60 min at room temperature with either anti-CD3 mAb, as a pan T cell marker, or the combination of anti-CD19/anti-CD138 mAbs, as markers

of B cells and plasma cells, respectively, followed by washing with PBS. After that, the slides were blocked with 0.3% H_2O_2 in PBS for 20 min and then incubated with 1:50 dilution of polyclonal rabbit anti-mouse peroxidase-conjugated antibody. The immunoperoxidase reaction was developed with diaminobenzidine (Sigma-Aldrich). Controls were samples incubated with an irrelevant mAb, mouse anti-rat CD4 (OX-38) (Serotec), nonreactive with human cells. Cytopins were analyzed by light microscopy (Olympus, Hamburg, Germany). On each cytopin, at least 500 cells were counted. The percentages of positive cells were determined on the basis of total counted cells. Based on the predominance of T cells or B cells/plasma cells, PLs were divided into T-type and B-type lesions, respectively [3].

2.4. Cell Cultures. The cells isolated from PLs were cultivated in 96 wells, with round-bottomed plates (ICN, Costa Mesa, CA) (1×10^5 cells/well, 200 μl) in the complete culture medium consisting of RPMI-1640 medium supplemented with 10% fetal calf serum (FCS) (Sigma-Aldrich) and standard culture solutions of antibiotics [25]. Phorbol myristate acetate (PMA) (20 ng/ml) (Sigma-Aldrich) and Ca^{2+} ionophore (A 23187, 1 M) (Sigma-Aldrich) were used for cell stimulation [27]. After 24 h, the cell supernatants were collected, centrifuged, and frozen at -70°C until the levels of cytokines were determined. Certain cultures were used to study the modulatory effects of cytokines on RANKL and OPG production. The following cytokines were used: IFN- γ ; (20 ng/ml), TNF- α (10 ng/ml), IL-17 (25 ng/ml), IL-4 (20 ng/ml), IL-10 (10 ng/ml), RANKL (10 ng/ml and 30 ng/ml), and IL-33 (1 ng/ml and 30 ng/ml). The concentrations of these cytokines were optimized in our previous experiments on peripheral blood mononuclear cells (PBMNC) and several PL cell cultures. All these cytokines were purchased from R&D (Lorton, VA, USA), except IL-33, which was obtained from BioLegend (San Diego, CA, USA). A neutralizing antibody to RANKL was obtained from R&D and used at the concentration of 2 $\mu\text{g/ml}$.

2.5. Cytokine Assay. The concentrations of RANKL and OPG in culture supernatants were detected by using specific ELISA kits (Abcam) following the instructions of the manufacturer. The levels of cytokines were determined on the basis of the standard curve, constructed by known concentrations of these cytokines. The cut of values for RANKL and OPG was 10 pg/ml and 1 pg/ml, respectively.

2.6. Statistical Analysis. To assess whether the differences between the groups/samples were significant, either Wilcoxon signed-rank tests or Friedman test with Dunn's multiple comparison posttest was used, since the data did not follow the Gaussian distribution according to the Kolmogorov-Smirnov normality test. To assess whether RANKL and OPG levels correlate significantly, the Spearman correlation test was used and the values of $p < 0.05$ were considered to be statistically significant. The statistical analysis was carried out using GraphPad Prism (GraphPad Software, CA, USA).

3. Results

3.1. Production of RANKL in PL Cell Cultures in Relation to Clinical Characteristics of the Lesions and T/B Cell Predominance. In the first part of this work, the levels of soluble RANKL and OPG were determined in 43 different PL cell cultures. The results varied between samples such that the mean level of RANKL was 142.7 ± 116.2 , the mean level of OPG was 91.8 ± 58.2 , and the mean RANKL/OPG ratio was 2.5 ± 2.2 . No correlation between RANKL and OPG levels was found ($r = 0.30$; $p = 0.08$). The proportion of PLs (62.8%) with active bone resorption processes (RANKL/OPG ratio > 1.0) was higher than the proportion of PLs (37.2%) in which bone resorption processes were suppressed (RANKL/OPG ratio < 1.0).

The difference in the level of RANKL between symptomatic lesions (207.9 ± 119.8) and asymptomatic lesions (88.3 ± 67.7) was statistically significant ($p < 0.001$). No significant differences between large (122.4 ± 116.4) versus small (189.0 ± 112.3) lesions were found. The mean proportion of T cells was 18.6 ± 13.8 , and the mean percentage of B cells/plasma cells was 16.3 ± 14.3 . The number of PLs with the dominance of T cells over B cells/plasma cells (T-type lesions) was 27, whereas the number of PLs with the dominance of B cells/plasma cells over T cells (B-type lesions) was 16. An example of immunocytochemical images of the lesions is given in Figure 1. The difference in the mean levels of RANKL between T-type (189.6 ± 96.3) versus B-type lesions (116.2 ± 55.2) was statistically significant ($p < 0.05$) (Figure 2(a)). The differences in the levels of OPG between any of the examined groups were not statistically significant (Figure 2(b)). The difference in the RANKL/OPG ratio was significantly higher only between symptomatic (3.10 ± 2.91) compared to asymptomatic PLs (1.18 ± 0.73) ($p < 0.05$) (Figure 2(c)). The proportion of PLs with the RANKL/OPG ratio > 1.0 in symptomatic lesions (77.3%) was significantly higher ($\chi^2 F = 4.044$; $p = 0.044$) compared to the proportion of PLs with the same ratio in asymptomatic lesions (47.6%). No differences were found when the ratio was compared between the large versus small PLs, as well as T-type versus B-type PLs (Table 1).

3.2. Modulatory Effect of Pro- and Anti-Inflammatory Cytokines on RANKL and OPG Production in Culture of PL Cells. The second part of this work was related to the modulatory effect of pro- and anti-inflammatory cytokines on RANKL and OPG production, which was studied in 12 separate PL cell cultures. The proportion of PLs reflected generally their distribution in the whole group (the proportion of symptomatic and asymptomatic PLs was equal: $n = 6$; the proportion of small size PLs versus large PLs was 5/7; and the proportion of T-type versus B-type PLs was 7/5).

IFN- γ and IL-17A augmented the production of soluble RANKL ($p < 0.05$ and $p < 0.01$, respectively) (Figure 3(a)). The level of OPG was only increased in the presence of IL-10 ($p < 0.05$) (Figure 3(b)), whereas IL-4 and TNF- α did not modulate the production of both RANKL and OPG (Figure 3(a) and Figure 3(b)). IL-17A increased the RANKL/OPG ratio, whereas IL-10 had the opposite effect (Figure 3(c)).

3.3. Modulatory Effect of IL-33 on RANKL and OPG Production in Culture of PL Cells. The same 12 cultures were used to study the effect of IL-33 on RANKL and OPG production by PL cells. Based on preliminary results on PBMNC and PL cells, showing a dose-dependent effect of IL-33 on RANKL/OPG production and their ratio, we selected two doses (1 ng/ml and 30 ng/ml) of IL-33 for final experiments. As presented in Figure 4, lower concentrations of IL-33 upregulated OPG production and decreased the RANKL/OPG ratio ($p < 0.05$), whereas higher concentrations augmented RANKL production compared to the control ($p < 0.01$) and increased the RANKL/OPG ratio compared to the low dose of IL-33 ($p < 0.01$).

3.4. RANKL Does Not Modulate the Levels of OPG in Culture of PL Cells. Finally, we tested whether the addition of exogenous RANKL modulates the production of OPG. According to mean levels of OPG ($n = 12$), it can be concluded that RANKL, at both of the two concentrations used (10 ng/ml and 30 ng/ml), did not modulate significantly the production of OPG. A similar result was obtained by addition of a neutralizing anti-RANKL antibody (Figure 5).

4. Discussion

In this study, we showed that RANKL and OPG are produced in culture of cells extracted from the periapical tissue. This procedure has been introduced previously by our group with the aim to study the pathogenesis of human apical periodontitis [25]. Its advantage over other used approaches so far in humans, related to the expression of biomolecules associated with bone resorption/repair processes, such as immunohistochemistry, mRNA expression, whole tissue homogenization, or biofluid collection, is the possibility to study the mechanisms involved, based on the manipulation with experimental conditions *in vitro*. In this context, the modulation of RANKL and OPG production by pro- and anti-inflammatory cytokines has been studied for the first time in this work.

The first *in vivo* demonstration of the involvement of RANKL and OPG in PLs came by immunohistochemical studies by using experimental pulpal exposure animal models. These and subsequent studies revealed a locally enhanced RANKL/OPG ratio in PLs and confirmed the implication of this molecular system in pathological periapical bone resorption, similarly as in other bone-destructive pathoses [15]. Several publications were related on RANKL and/or OPG in human PLs. Among them, Tay et al. showed the presence of RANKL in radicular cysts, by using an immunohistochemistry method [28]. Immunolocalization of RANKL was overlapped with staining for TRAP, a marker of osteoclasts. Sabeti et al. confirmed the presence of RANKL at the gene expression level in inflammatory PLs of undisclosed nature [29]. RANKL mRNA was also detected and semi-quantified in periapical granulomas, whilst its expression was below detection limit in healthy periodontal ligament [30]. Expression of RANKL on inflammatory cells isolated from PLs was further investigated using flow cytometry. The results showed that monocytes (CD14+) and dendritic

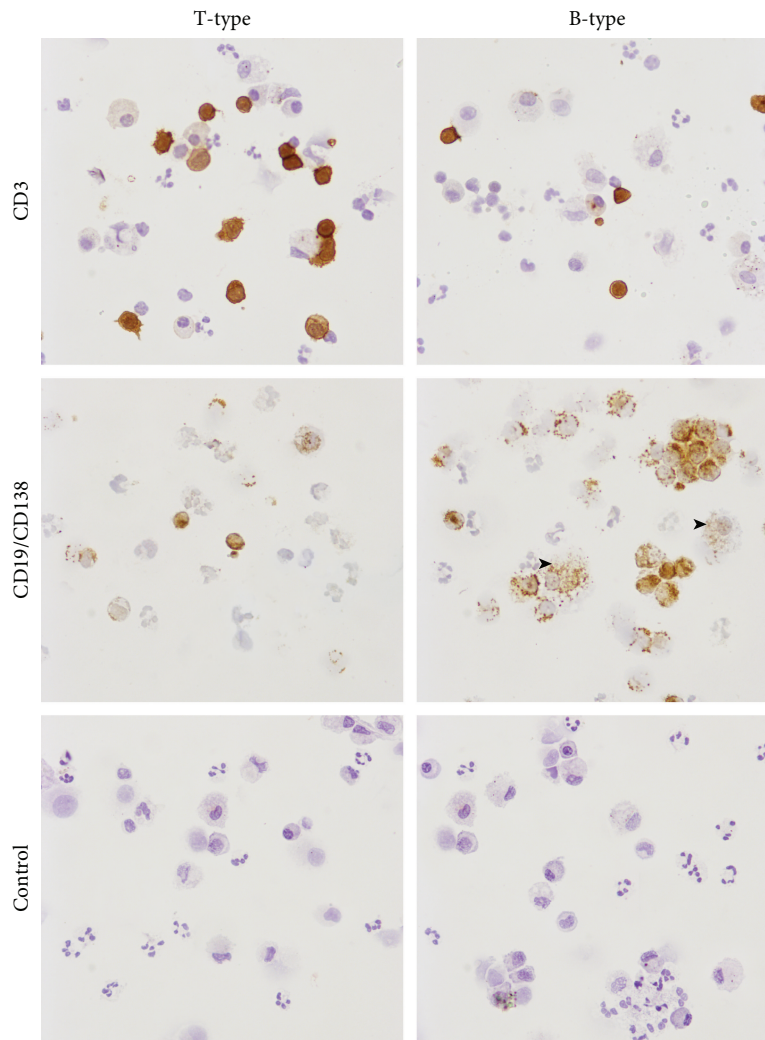


FIGURE 1: Immunocytochemical presentation of T-type and B-type periapical lesions. Cytospins of periapical lesion (PL) cells were stained with an anti-CD3 (marker of T cells) or a combination of anti-CD19 (B cell marker) and anti-CD138 (marker of plasma cells), as described in “Materials and Methods.” A representative sample of T-type PL (predominance of T cells over B cells/plasma cells) or a sample of B-type PL (predominance of B cells/plasma cells) over T cells is presented. Macrophages, which are positively stained with CD138 (intracytoplasmic granular staining), are excluded from the analysis, based on morphological criteria. Some of them are marked by arrows. Controls are stained by an irrelevant (anti-rat CD4) monoclonal antibody, nonreactive with human tissues. Magnifications: $\times 200$.

cells (CD83+) were the main producers of RANKL in granuloma [30]. By using an immunohistochemical study, Menezes and coworkers compared RANKL and OPG levels between apical granulomas and radicular cysts [31]. They found that the ratio of OPG⁺/total cells and RANKL⁺/total cells was higher in granulomas than in cysts, but the RANKL/OPG ratio did not differ between these two types of PLs. They also showed that various cell types expressed both RANKL and OPG, and the staining of macrophage-like cells (CD68⁺) was of the highest intensity. Another study demonstrated a significantly higher expression of RANKL mRNA levels in granulomas in comparison with cysts [32]. These results are in contrast to those published by Fan et al., who did not identify any difference between total RANKL or OPG protein levels or their ratio between granulomas and radicular cysts [33]. We also did not find the differences in these parameters between large- and small-size

PLs. Although we did not classify our PL samples by histological criteria, radiological appearance was very suggestive that the majority of large size PLs resembled cysts, in contrast to small-size PLs. Considering RANKL and OPG expression and radiographic size of periapical granulomas (smaller or greater than 5 mm in diameter), Menezes et al. demonstrate a trend towards higher RANKL and lower OPG expression in smaller lesions, but similarly with our results, the differences were not statistically significant [34]. However, in their study the frequency of RANKL>OPG samples was higher compared to the group of larger lesions. No association of RANKL and OPG protein expression, detected by immunocytochemistry, with lesion size was also observed by Santos et al. [35]. Their study demonstrated the possible involvement of RANKL, TNF- α , IL-33, cathepsin K, and OPG in the development of radicular cysts and periapical granulomas, with emphasis on the highest immunoreactivity of

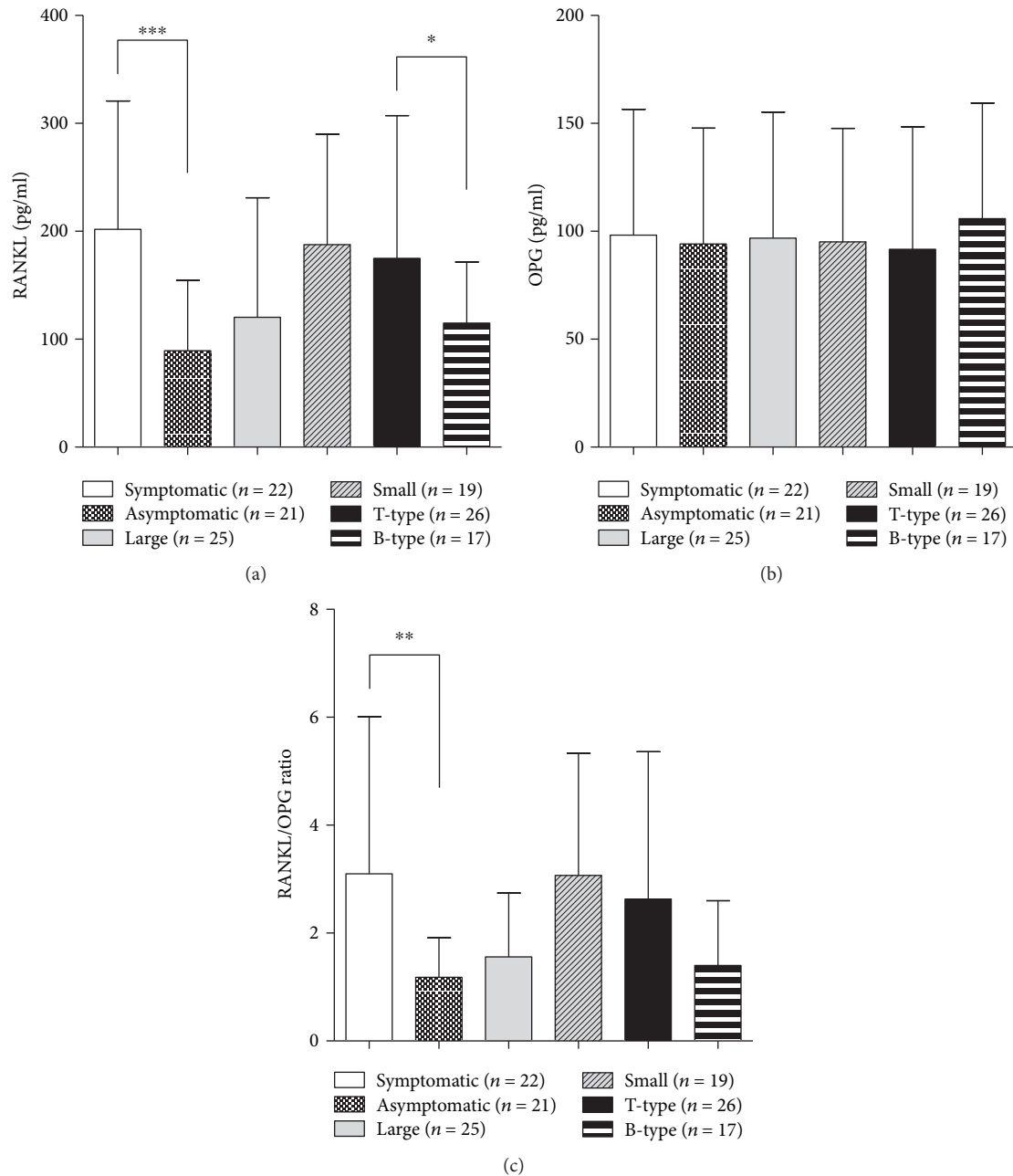


FIGURE 2: The levels of RANKL (a), OPG (b), and values of RANKL/OPG ratio (c) in PL cell cultures in relation to clinical characteristics of the lesions and T/B cell predominance. Periapical lesion (PL) cells were isolated from 43 PLs and cultivated for 24 hours as described in “Materials and Methods.” The levels of soluble RANKL and OPG in supernatants were measured by ELISA, and after that, the RANKL/OPG ratio was calculated. The differences between groups were tested by using the pair Student *t*-test. The statistically significant difference was marked on the graph. * $p < 0.05$, ** $p < 0.01$, and *** $p < 0.001$, as indicated.

cathepsin in cysts and TNF- α and OPG in granulomas. Based on these results, they supposed that OPG could determine the slower growth of granulomas compared to cysts due to its blocking activity against RANKL.

We showed that symptomatic lesions were characterized by higher production of RANKL and higher RANKL/OPG ratio, a phenomenon which has not been explored enough in previous studies. Our results are partly comparable with those published by Fan et al. who observed significantly more RANKL-positive cells in severely inflamed lesions compared

to lightly inflamed counterparts. However, the RANKL/OPG ratio was statistically similar between inflammations graded as light, moderate, or intense [36]. The explanation why the production of RANKL is significantly higher in symptomatic PLs could be found by evaluating the association between high production of proinflammatory cytokines in symptomatic PLs [3] and RANKL expression. Among them, IL-1 and TNF- α have been shown to predominate both in the early phase of apical periodontitis and during the exacerbation, and both phases are characterized by the presence of clinical

TABLE 1: RANKL/OPG ratio in PL cell cultures depending on the clinical presentation of PLs and T/B cell predominance.

RANKL/OPG ratio	Sy <i>n</i> (%)	As <i>n</i> (%)	Σ <i>n</i> (%)	χ^2 <i>F</i>	<i>p</i>
<1.00	5 (22.7)	11 (52.4)	16 (37.2)	4.044	0.0443
>1.00	17 (77.3)	10 (47.6)	27 (62.8)		
	Large <i>n</i> (%)	Small <i>n</i> (%)	Σ <i>n</i> (%)	0.1991	0.6555
<1.00	10 (40.0)	6 (33.3)	16 (37.2)		
>1.00	15 (60.0)	12 (66.7)	27 (62.8)		
	T-type <i>n</i> (%)	B-type <i>n</i> (%)	Σ <i>n</i> (%)	2.978	0.0844
<1.00	7 (26.9)	9 (52.9)	16 (37.2)		
>1.00	19 (73.1)	8 (47.1)	27 (62.8)		

Sy: symptomatic lesions; As: asymptomatic lesions.

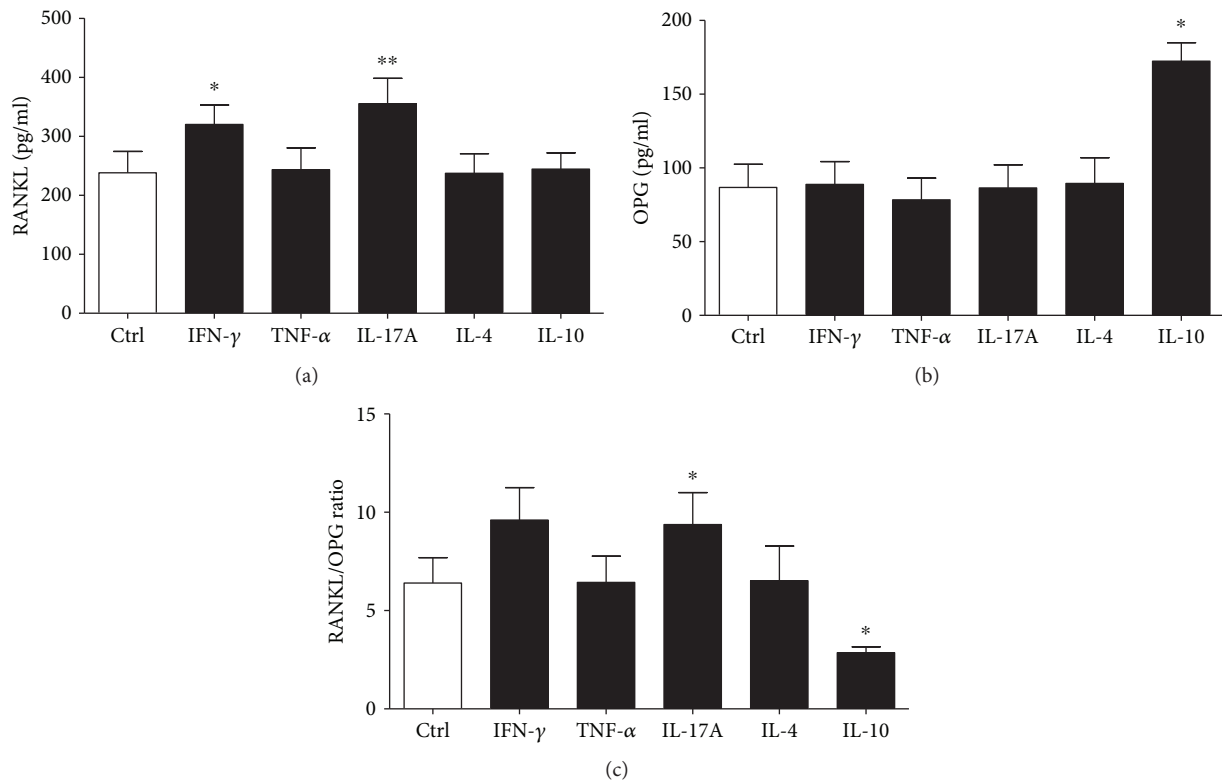


FIGURE 3: The levels of RANKL (a), OPG (b), and RANKL/OPG ratio (c) in PL cell cultures upon stimulation with pro- and anti-inflammatory cytokines. Periapical lesion (PL) cells were isolated from 12 PLs and cultivated for 24 hours with TNF- α , IFN- γ , IL-17A, IL-4, and IL-10 as described in “Materials and Methods.” The levels of soluble RANKL and OPG in supernatants were measured by ELISA, and after that, the RANKL/OPG ratio was calculated. (a) Friedman test ($n = 12$, Friedman statistics 22.1, $p = 0.0005$) and Dunn’s multiple comparison test, $*p < 0.05$ and $**p < 0.01$ vs Ctrl. (b) Friedman test ($n = 12$, Friedman statistics 15.94, $p = 0.007$) and Dunn’s multiple comparison test, $*p < 0.05$ vs Ctrl. (c) Friedman test ($n = 12$, Friedman statistics 21.14, $p = 0.0008$) and Wilcoxon signed-rank test, $*p < 0.05$ compared to Ctrl.

symptoms [3]. According to Kitaura et al., TNF- α acts directly to promote osteoclastogenesis, by increasing the expression of RANKL in macrophages and stromal cells [37]. Other studies suggest a direct effect of this cytokine on the bone resorption or through RANKL without modification of its expression. The resorption activity of osteoclasts generated by TNF- α in the absence of RANKL was critically dependent upon IL-1, which was expressed by the influence of TNF- α [38]. Zhang et al. found that TNF- α potently stimulated RANKL-induced osteoclastogenesis via coupling the

RANK signaling pathway [39]. Further results indicated that IL-1 and LPS stimulate the production of osteoclasts through two parallel processes such as direct enhancement of RANKL and suppression of OPG expression, which is mediated by PGE2 production [40]. Kubota et al. demonstrated that TNF- α promotes the expression of OPG in synovial fibroblasts, predominantly through TNF-RI which may contribute to self-protection from the bone destruction [41]. We did not find any modulation of both RANKL and OPG production by TNF- α , suggesting that TNF- α has not a

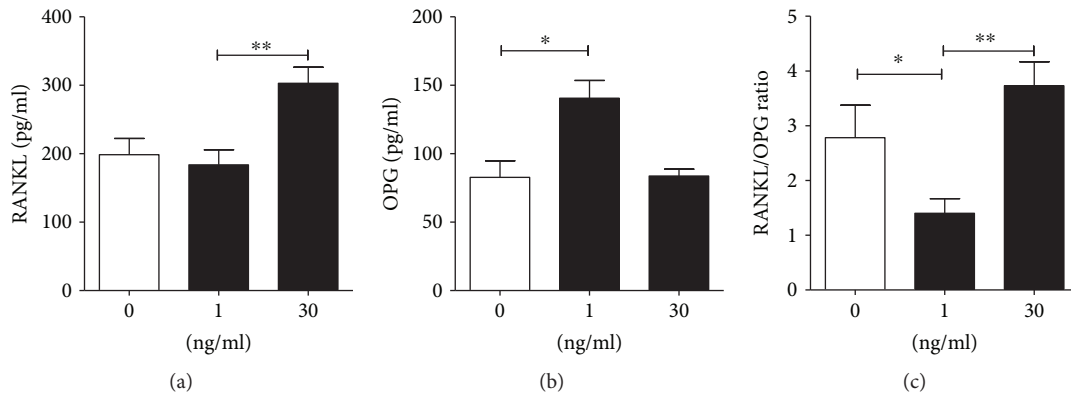


FIGURE 4: The levels of RANKL (a), OPG (b), and RANKL/OPG ratio (c) in PL cell cultures upon stimulation with IL-33. Periapical lesion (PL) cells were isolated from 12 PLs and cultivated for 24 hours with 1 ng/ml or 30 ng/ml of IL-33 as described in “Materials and Methods.” The levels of soluble RANKL and OPG in supernatants were measured by ELISA, and after that, the RANKL/OPG ratio was calculated. (a) Friedman test ($n = 12$, Friedman statistics 10.33, $p = 0.0017$) Dunn’s multiple comparison test, $**p < 0.01$ as indicated. (b) Friedman test ($n = 12$, Friedman statistics 9.33, $p = 0.0055$) Dunn’s multiple comparison test, $*p < 0.05$ as indicated. (c) Friedman test ($n = 12$, Friedman statistics 12.00, $p = 0.0001$) and Dunn’s multiple comparison test, $*p < 0.05$ and $**p < 0.01$ as indicated.

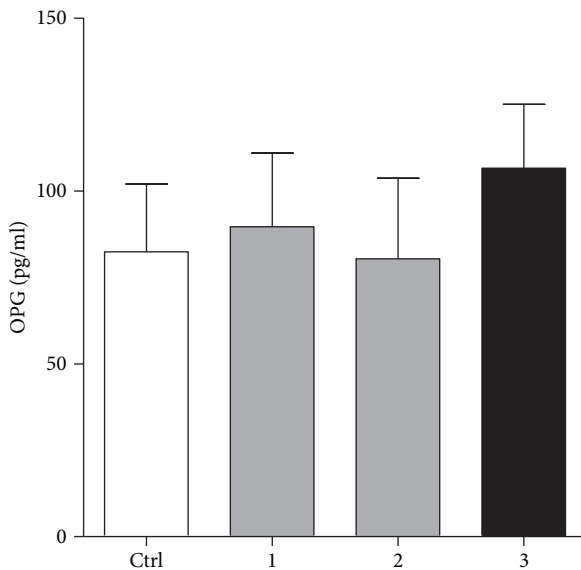


FIGURE 5: Modulation of OPG production in PL cell cultures by RANKL or anti-RANKL neutralizing antibody. Periapical lesion (PL) cells were isolated from 12 PLs and cultivated for 24 hours with 10 ng/ml (labeled as 1 on x axis), 30 ng/ml (labeled as 2) of RANKL, or anti-RANKL neutralizing antibody (2 μ g/ml) (labeled as 3) as described in “Materials and Methods.” The levels of OPG in supernatants were measured by ELISA, and after that, the RANKL/OPG ratio was calculated. All differences in relation to control (Ctrl) were not statistically significant ($p > 0.05$).

dominant effect on the expression of these bone-remodeling mediators in the mixture of the PL cell population, composed predominantly of inflammatory cells. It is interesting that we did not observe any significant modulation of OPG production by either addition of exogenous RANKL or its neutralization by anti-RANKL antibody, suggesting that, at least in this culture model, the expression of OPG is not under direct influence of RANKL. It is interesting that this phenomenon has not been examined in other cell systems. Another cytokine which is upregulated in symptomatic lesions is IL-17

[20]. IL-17⁺ T cells are important inducers of RANKL expression and can cause alterations in the RANKL/OPG balance [42]. In addition, RANKL is expressed by IL-17⁺ cells. However, a study showed that Th17 cells do not induce osteoclastogenesis in the absence of osteoblasts, which strongly suggests that RANKL expressed on Th17 cells alone is not sufficient to induce the differentiation of osteoclasts. This is partly dependent on a small amount of IFN- γ produced by Th17 cells, which could counterbalance the RANKL action [42]. It has been shown that IL-17 significantly enhances the expression of RANKL but also inhibits the expression of OPG in human periodontal ligament cells through mitogen-activated protein kinases and nuclear factor- κ B (NF- κ B) signals [43]. We showed that IL-17A augments RANKL, but not OPG secretion by PL cells, which is in accordance with the osteodestructive role of Th17⁺ cells. The increased number of activated T helper (Th) cells in PLs could be the reason why we detected a higher proportion of bone-destructive lesions (RANKL/OPG ratio > 1.0) in T-type lesions, compared with those with the predominance of B cells and plasma cells and in which humoral immune response prevails [3]. Among them are Th17⁺ cells. This is also in accordance with our findings that PL cells produce higher levels of RANKL in the presence of IL-17A.

Our previous results also showed that Th1 cells, which produce IFN- γ , are also numerous in PLs [25]. The role of IFN- γ in the pathogenesis of PLs and bone destruction is still controversial since IFN- γ can function as a pro- or anti-resorptive cytokine [4, 32]. IFN- γ blunts osteoclast formation through direct targeting of osteoclast precursors but indirectly stimulates osteoclast formation and promotes bone resorption by stimulating antigen-dependent T cell secretion of RANKL and TNF- α [44]. The opposite results were published by Takayanagi et al. who showed that IFN- γ strongly suppresses osteoclastogenesis by interfering with the RANKL-RANK signaling pathway [45]. The analysis of the *in vivo* effects of IFN- γ in mouse models revealed that IFN- γ has both direct antiosteoclastogenic and indirect pro-osteoclastogenic properties *in vivo*. Our findings, which

showed that IFN- γ stimulates the production of RANKL by PL cells in culture, are in accordance with those showing that Th1 cells, through induction of RANKL, play a direct role in bone resorption in Th1-dominant diseases [46].

However, our explanations about the dominance of osteodestructive processes in T-type lesions are simplified because other Th subsets (Th2, Th9, Th22, and Tregs) as well as different subpopulations of CD8⁺ T cells are also present in PLs. Th2 cells, by producing IL-4, IL-5, and IL-13, are believed to be associated with the humoral immune response in which anti-inflammatory processes dominate [3]. However, we found that only half of B-type lesions belong to the group of bone antiresorptive PLs (RANKL/OPG ratio < 1.0). It has been shown that IL-4 directly prevents osteoclast precursors from differentiating into osteoclasts in a signal transducer and activator of transcription (STAT) 6-dependent manner [47]. In addition, IL-4 suppresses RANK expression but enhances OPG expression in osteoblastic cells [47]. We did not show any modulatory effect of IL-4 on RANKL and OPG production in PL cell cultures, suggesting that most inflammatory cells from the PLs respond differently to IL-4 than osteoclasts do.

The only subpopulation of T cells which strongly inhibits inflammation and bone destruction is the Treg subset. Tregs produce IL-10 and TGF- β , which downregulate the production of RANKL and increase the production of OPG [48]. IL-10 directly inhibits osteoclast precursors by suppressing RANKL-induced NFATc1, c-Fos, and c-Jun expression [49]. Our results, showing an increased production of OPG and decreased RANKL/OPG ratio in PL cell cultures, support previous findings. However, we did not detect any significant change in the production of RANKL.

An interesting finding in our study was related to the dual effect of IL-33 on RANKL and OPG production. We showed for the first time that lower doses of this cytokine augment OPG production in PL cells, in contrast to higher doses which augment RANKL. It is known that IL-33 belongs to the IL-1 family and is closely related in structure to IL-18 and IL-1 β . The cytokine is synthesized as a biologically inactive precursor and then cleaved by the enzyme caspase-1 to be secreted as active mature forms. IL-33 stimulates target cells by binding to its ST2 receptor which is followed by activation of NF- κ B and MAPK pathways via identical signaling events to those observed for IL-1 β . IL-33 is also a nuclear factor abundantly expressed in high endothelial venules. The major targets of IL-33 *in vivo* are tissue-resident immune cells such as mast cells, group 2 innate lymphoid cells (ILC2s), and Tregs. However, it also acts on many other cells including Th1 cells and CD8 cells. Initially, IL-33 was proven as a potent stimulator of Th2 immune response (allergy diseases), but we know now that IL-33 is a crucial immune modulator with pleiotropic activities in type 2, type 1, and regulatory immune responses, playing important roles in allergic, fibrotic, infectious, and chronic inflammatory diseases [26]. The knowledge of the role of IL-33 in periodontal diseases is relatively scarce, and the results are contradictory. In this context, Malcolm et al. demonstrated that the expression of IL-33 and ST2 was elevated in gingival tissues from patients with chronic periodontitis as compared with healthy

tissues. Similarly, IL-33 expression was observed to be higher in periodontal tissues of *Porphyromonas gingivalis*-infected mice. IL-33 upregulated the expression of RANKL in such mice. In contrast, administration of OPG, by targeting RANKL, abrogated periodontal destruction [50]. Therefore, IL-33 could act as a proinflammatory cytokine with osteodestructive consequences. Similarly, Velickovic et al. showed higher expression of IL-33 and ST2 in periapical granulomas and radicular cysts when compared to healthy periapical tissues, suggesting that IL-33/ST2 signaling may be involved in periapical inflammation and tissue fibrosis [51]. Araujo-Pires et al. did not find any significant difference in the expression of IL-33 between active (RANKL>OPG) and inactive (RANKL<OPG) human periapical granulomas [52]. However, the opposite results were found in ST2 knockout mice in which deletion of ST2 signaling augmented the RANKL/OPG ratio in PLs. The number of CD3⁺ RANKL⁺ cells along with TRAP⁺ osteoclasts was higher in PLs of ST2^{-/-} mice compared with wild-type (WT) mice, whereas the percentages of CD3⁺ OPG⁺ cells were higher in WT mice. In addition, ST2 deletion increases inflammatory bone loss, which was associated with enhanced Th1/Th17 cell-mediated periapical immune responses and increased osteoclastogenesis [53]. Based on all these results, our findings suggest that during exacerbation of inflammation in PLs, IL-33 could potentiate bone resorption through increased production of RANKL. However, during resolution of inflammation, low secretion of IL-33, through augmented production of OPG, could act as a bone-protective cytokine.

In conclusion, PL cells in culture produce a significant amount of both RANKL and OPG, so we propose this model as a useful alternative to study mechanisms involved in the pathogenesis of apical periodontitis. Some of them, which were examined in this work, suggest that both bone resorptive and bone-protective processes are present in all stages of PL development and are finely balanced by cytokines involved in PL pathogenesis.

Data Availability

The data used to support the findings of this study are available from the corresponding author upon request.

Conflicts of Interest

The authors have no conflicts of interest to disclose.

Authors' Contributions

The following are contributions of the authors in this study: Miloš Duka—design of the study, participation in the clinical part of experiments, and drafting of the manuscript; Mile Eraković—participation in the clinical part of experiments and analysis of clinical data; Zana Dolićanin—participation in the immunological part of experiments and immunocytochemistry and analysis of data; Dara Stefanović—analysis of radiological parameters; Miodrag Čolić—design of the study, participation in the immunological part of experiments,

analysis of data, and manuscript final revision. All authors approved the final version of the manuscript for submission.

Acknowledgments

The study is supported by the Ministry for Education, Science and Technological Development, R. Serbia (OI 175102) and MMA (project No. MFVMA 07/17-19). We thank Sergej Tomić and Marina Bekić for technical assistance during the preparation of the manuscript.

References

- [1] J. Warnsinck and H. Shemesh, "The dynamics of the periapical lesion," *Endodontic Practice Today*, vol. 11, no. 3, pp. 167–171, 2018.
- [2] L. Bjorndal and C. Reit, "The annual frequency of root fillings, tooth extractions and pulp-related procedures in Danish adults during 1977-2003," *International Endodontic Journal*, vol. 37, no. 11, pp. 782–788, 2004.
- [3] M. Colic, D. Gazivoda, D. Vucevic, S. Vasilijic, R. Rudolf, and A. Lukic, "Proinflammatory and immunoregulatory mechanisms in periapical lesions," *Molecular Immunology*, vol. 47, no. 1, pp. 101–113, 2009.
- [4] D. T. Graves, T. Oates, and G. P. Garlet, "Review of osteoimmunology and the host response in endodontic and periodontal lesions," *Journal of Oral Microbiology*, vol. 3, no. 1, 2011.
- [5] A. Lukic, S. Vasilijic, I. Majstorovic et al., "Characterization of antigen-presenting cells in human apical periodontitis lesions by flow cytometry and immunocytochemistry," *International Endodontic Journal*, vol. 39, no. 8, pp. 626–636, 2006.
- [6] P. N. R. Nair, "Pathogenesis of apical periodontitis and the causes of endodontic failures," *Critical Reviews in Oral Biology & Medicine*, vol. 15, no. 6, pp. 348–381, 2004.
- [7] P. Stashenko, R. Teles, and R. D'Souza, "Periapical inflammatory responses and their modulation," *Critical Reviews in Oral Biology and Medicine*, vol. 9, no. 4, pp. 498–521, 1998.
- [8] Y. Y. Kong, H. Yoshida, I. Sarosi et al., "OPGL is a key regulator of osteoclastogenesis, lymphocyte development and lymph-node organogenesis," *Nature*, vol. 397, no. 6717, pp. 315–323, 1999.
- [9] D. L. Lacey, E. Timms, H. L. Tan et al., "Osteoprotegerin ligand is a cytokine that regulates osteoclast differentiation and activation," *Cell*, vol. 93, no. 2, pp. 165–176, 1998.
- [10] U. H. Lerner, "Inflammation-induced bone remodeling in periodontal disease and the influence of post-menopausal osteoporosis," *Journal of Dental Research*, vol. 85, no. 7, pp. 596–607, 2006.
- [11] S. L. Teitelbaum and F. P. Ross, "Genetic regulation of osteoclast development and function," *Nature Reviews Genetics*, vol. 4, no. 8, pp. 638–649, 2003.
- [12] W. S. Simonet, D. L. Lacey, C. R. Dunstan et al., "Osteoprotegerin: a novel secreted protein involved in the regulation of bone density," *Cell*, vol. 89, no. 2, pp. 309–319, 1997.
- [13] E. M. Sordillo and R. N. Pearse, "RANK-Fc: a therapeutic antagonist for RANK-L in myeloma," *Cancer*, vol. 97, Supplement 3, pp. 802–812, 2003.
- [14] E. Terpos, I. Ntanasis-Stathopoulos, M. Gavriatopoulou, and M. A. Dimopoulos, "Pathogenesis of bone disease in multiple myeloma: from bench to bedside," *Blood Cancer Journal*, vol. 8, no. 1, p. 7, 2018.
- [15] G. N. Belibasakis, D. K. Rechenberg, and M. Zehnder, "The receptor activator of NF- κ B ligand-osteoprotegerin system in pulpal and periapical disease," *International Endodontic Journal*, vol. 46, no. 2, pp. 99–111, 2013.
- [16] C. F. Francisconi, A. E. Vieira, M. C. S. Azevedo et al., "RANKL triggers Treg-mediated immunoregulation in inflammatory osteolysis," *Journal of Dental Research*, vol. 97, no. 8, pp. 917–927, 2018.
- [17] A. H. Almeahmadi and F. Alghamdi, "Biomarkers of alveolar bone resorption in gingival crevicular fluid: a systematic review," *Archives of Oral Biology*, vol. 93, pp. 12–21, 2018.
- [18] G. P. Garlet, "Destructive and protective roles of cytokines in periodontitis: a re-appraisal from host defense and tissue destruction viewpoints," *Journal of Dental Research*, vol. 89, no. 12, pp. 1349–1363, 2010.
- [19] A. M. F. Aranha, C. E. Repeke, T. P. Garlet et al., "Evidence supporting a protective role for th9 and th22 cytokines in human and experimental periapical lesions," *Journal of Endodontics*, vol. 39, no. 1, pp. 83–87, 2013.
- [20] M. Čolić, S. Vasilijić, D. Gazivoda, D. Vučević, M. Marjanović, and A. Lukić, "Interleukin-17 plays a role in exacerbation of inflammation within chronic periapical lesions," *European Journal of Oral Sciences*, vol. 115, no. 4, pp. 315–320, 2007.
- [21] H. Takayanagi, "New developments in osteoimmunology," *Nature Reviews Rheumatology*, vol. 8, no. 11, pp. 684–689, 2012.
- [22] Y. Belkaid and K. Tarbell, "Regulatory T cells in the control of host-microorganism interactions," *Annual Review of Immunology*, vol. 27, no. 1, pp. 551–589, 2009.
- [23] G. P. Garlet, C. R. Cardoso, F. S. Mariano et al., "Regulatory T cells attenuate experimental periodontitis progression in mice," *Journal of Clinical Periodontology*, vol. 37, no. 7, pp. 591–600, 2010.
- [24] A. J. Glowacki, S. Yoshizawa, S. Jhunjhunwala et al., "Prevention of inflammation-mediated bone loss in murine and canine periodontal disease via recruitment of regulatory lymphocytes," *Proceedings of the National Academy of Sciences of the United States of America*, vol. 110, no. 46, pp. 18525–18530, 2013.
- [25] M. Čolić, A. Lukić, D. Vučević et al., "Correlation between phenotypic characteristics of mononuclear cells isolated from human periapical lesions and their in vitro production of Th1 and Th2 cytokines," *Archives of Oral Biology*, vol. 51, no. 12, pp. 1120–1130, 2006.
- [26] C. Cayrol and J. P. Girard, "Interleukin-33 (IL-33): a nuclear cytokine from the IL-1 family," *Immunological Reviews*, vol. 281, no. 1, pp. 154–168, 2018.
- [27] D. P. Collins, "Cytokine and cytokine receptor expression as a biological indicator of immune activation: important considerations in the development of in vitro model systems," *Journal of Immunological Methods*, vol. 243, no. 1–2, pp. 125–145, 2000.
- [28] J. Y. Y. Tay, B. H. Bay, J. F. Yeo, M. Harris, S. Meghji, and S. T. Dheen, "Identification of RANKL in osteolytic lesions of the facial skeleton," *Journal of Dental Research*, vol. 83, no. 4, pp. 349–353, 2004.
- [29] M. Sabeti, J. Simon, V. Kermani, Y. Valles, and I. Rostein, "Detection of receptor activator of NF- κ β ligand in apical periodontitis," *Journal of Endodontics*, vol. 31, no. 1, pp. 17–18, 2005.
- [30] R. Vernal, A. Dezerega, N. Dutzan et al., "RANKL in human periapical granuloma: possible involvement in periapical bone destruction," *Oral Diseases*, vol. 12, no. 3, pp. 283–289, 2006.

- [31] R. Menezes, C. M. Bramante, K. B. da Silva Paiva et al., "Receptor activator NF κ B-ligand and osteoprotegerin protein expression in human periapical cysts and granulomas," *Oral Surgery, Oral Medicine, Oral Pathology, Oral Radiology, and Endodontology*, vol. 102, no. 3, pp. 404–409, 2006.
- [32] S. Y. Fukada, T. A. Silva, G. P. Garlet, A. L. Rosa, J. S. da Silva, and F. Q. Cunha, "Factors involved in the T helper type 1 and type 2 cell commitment and osteoclast regulation in inflammatory apical diseases," *Oral Microbiology and Immunology*, vol. 24, no. 1, pp. 25–31, 2009.
- [33] R. Fan, C. F. Zhang, and Y. Gao, "Expression of receptor activator of nuclear factor kappaB ligand and osteoprotegerin in chronic apical periodontitis," *Beijing da xue xue bao. Yi xue ban= Journal of Peking University. Health Sciences*, vol. 40, no. 1, pp. 39–42, 2008.
- [34] R. Menezes, T. P. Garlet, A. Letra et al., "Differential patterns of receptor activator of nuclear factor kappa B ligand/osteoprotegerin expression in human periapical granulomas: possible association with progressive or stable nature of the lesions," *Journal of Endodontia*, vol. 34, no. 8, pp. 932–938, 2008.
- [35] S. C. L. T. Santos, L. A. Couto, J. M. Fonseca et al., "Participation of osteoclastogenic factors in immunopathogenesis of human chronic periapical lesions," *Journal of Oral Pathology & Medicine*, vol. 46, no. 9, pp. 846–852, 2017.
- [36] R. Fan, B. Sun, C. F. Zhang et al., "Receptor activator of nuclear factor kappa B ligand and osteoprotegerin expression in chronic apical periodontitis: possible association with inflammatory cells," *Chinese Medical Journal*, vol. 124, no. 14, pp. 2162–2166, 2011.
- [37] H. Kitaura, K. Kimura, M. Ishida, H. Kohara, M. Yoshimatsu, and T. Takano-Yamamoto, "Immunological reaction in TNF- α -mediated osteoclast formation and bone resorption in vitro and in vivo," *Clinical and Developmental Immunology*, vol. 2013, article 181849, 8 pages, 2013.
- [38] D. O' Gradaigh, D. Ireland, S. Bord, and J. E. Compston, "Joint erosion in rheumatoid arthritis: interactions between tumour necrosis factor α , interleukin 1, and receptor activator of nuclear factor κ B ligand (RANKL) regulate osteoclasts," *Annals of the Rheumatic Diseases*, vol. 63, no. 4, pp. 354–359, 2004.
- [39] Y.-H. Zhang, A. Heulsmann, M. M. Tondravi, A. Mukherjee, and Y. Abu-Amer, "Tumor necrosis factor- α (TNF) stimulates RANKL-induced osteoclastogenesis via coupling of TNF type 1 receptor and RANK signaling pathways," *Journal of Biological Chemistry*, vol. 276, no. 1, pp. 563–568, 2001.
- [40] K. Suda, N. Udagawa, N. Sato et al., "Suppression of osteoprotegerin expression by prostaglandin E2 is crucially involved in lipopolysaccharide-induced osteoclast formation," *The Journal of Immunology*, vol. 172, no. 4, pp. 2504–2510, 2004.
- [41] A. Kubota, K. Hasegawa, T. Suguro, and Y. Koshihara, "Tumor necrosis factor-alpha promotes the expression of osteoprotegerin in rheumatoid synovial fibroblasts," *The Journal of Rheumatology*, vol. 31, no. 3, pp. 426–435, 2004.
- [42] K. Sato, A. Suematsu, K. Okamoto et al., "Th17 functions as an osteoclastogenic helper T cell subset that links T cell activation and bone destruction," *The Journal of Experimental Medicine*, vol. 203, no. 12, pp. 2673–2682, 2006.
- [43] D. Lin, L. Li, Y. Sun et al., "Interleukin-17 regulates the expressions of RANKL and OPG in human periodontal ligament cells via TRAF6/TBK1-JNK/NF- κ B pathways," *Immunology*, vol. 144, no. 3, pp. 472–485, 2015.
- [44] Y. Gao, F. Grassi, M. R. Ryan et al., "IFN- γ stimulates osteoclast formation and bone loss in vivo via antigen-driven T cell activation," *The Journal of Clinical Investigation*, vol. 117, no. 1, pp. 122–132, 2007.
- [45] H. Takayanagi, K. Ogasawara, S. Hida et al., "T-cell-mediated regulation of osteoclastogenesis by signalling cross-talk between RANKL and IFN- γ ," *Nature*, vol. 408, no. 6812, pp. 600–605, 2000.
- [46] S. Kotake, Y. Nanke, M. Mogi et al., "IFN- γ -producing human T cells directly induce osteoclastogenesis from human monocytes via the expression of RANKL," *European Journal of Immunology*, vol. 35, no. 11, pp. 3353–3363, 2005.
- [47] P. Palmqvist, P. Lundberg, E. Persson et al., "Inhibition of hormone and cytokine-stimulated osteoclastogenesis and bone resorption by interleukin-4 and interleukin-13 is associated with increased osteoprotegerin and decreased RANKL and RANK in a STAT6-dependent pathway," *Journal of Biological Chemistry*, vol. 281, no. 5, pp. 2414–2429, 2006.
- [48] B. Chen, W. Wu, W. Sun, Q. Zhang, F. Yan, and Y. Xiao, "RANKL expression in periodontal disease: where does RANKL come from?," *BioMed Research International*, vol. 2014, Article ID 731039, 7 pages, 2014.
- [49] K. E. Evans and S. W. Fox, "Interleukin-10 inhibits osteoclastogenesis by reducing NFATc1 expression and preventing its translocation to the nucleus," *BMC Cell Biology*, vol. 8, no. 1, p. 4, 2007.
- [50] J. Malcolm, R. A. Awang, J. Oliver-Bell et al., "IL-33 exacerbates periodontal disease through induction of RANKL," *Journal of Dental Research*, vol. 94, no. 7, pp. 968–975, 2015.
- [51] M. Velickovic, N. Pejnovic, R. Petrovic et al., "Expression of interleukin-33 and its receptor ST 2 in periapical granulomas and radicular cysts," *Journal of Oral Pathology & Medicine*, vol. 45, no. 1, pp. 70–76, 2016.
- [52] A. C. Araujo-Pires, C. F. Francisconi, C. C. Bigueti et al., "Simultaneous analysis of T helper subsets (Th1, Th2, Th9, Th17, Th22, Tfh, Tr1 and Tregs) markers expression in periapical lesions reveals multiple cytokine clusters accountable for lesions activity and inactivity status," *Journal of Applied Oral Science*, vol. 22, no. 4, pp. 336–346, 2014.
- [53] M. Velickovic, N. Pejnovic, S. Mitrovic et al., "ST2 deletion increases inflammatory bone destruction in experimentally induced periapical lesions in mice," *Journal of Endodontics*, vol. 41, no. 3, pp. 369–375, 2015.