

Comparison of conjunctival graft thickness after primary and recurrent pterygium surgery: Anterior segment optical coherence tomography study

Engin Bilge Ozgurhan, Necip Kara, Ercument Bozkurt, Baran Gencer¹, Kemal Yuksel, Ahmet Demirok

Objective: The objective of the following study is to compare the conjunctival graft thickness measured with anterior segment optical coherence tomography (OCT) after primary and recurrent pterygium excision. **Design:** Prospective, interventional and comparative study. **Participants:** A total of 20 eyes of 20 patients with primary pterygium (primary group) and 20 eyes of 20 patients with recurrent pterygium (recurrent group) were enrolled. **Materials and Methods:** All patients underwent pterygium excision with conjunctival autograft transplantation. Conjunctival graft thickness was measured at 1 week, 1 month and 3 months after surgery using the Visante-OCT (Carl-Zeiss Meditec, Dublin, CA, USA). Main outcome measure was the mean conjunctival thickness determined as the mean of three measurements at 1, 2 and 3 mm posterior to the scleral spur. **Results:** There were no statistically significant differences in age, sex, or laterality between the groups. Mean thickness of the graft in primary and recurrent groups, respectively, was $430 \pm 127 \mu\text{m}$ and $461 \pm 178 \mu\text{m}$ at 1 week after surgery ($P = 0.587$), $114 \pm 19 \mu\text{m}$ and $162 \pm 48 \mu\text{m}$ at 1 month after surgery ($P = 0.001$) and $109 \pm 15 \mu\text{m}$ and $107 \pm 18 \mu\text{m}$ at 3 months after surgery ($P = 0.726$). **Conclusion:** The findings revealed that conjunctival thickness after primary or recurrent pterygium excision was greatest at 1 week after surgery and continued to decrease for up to 3 months. Mean graft thickness differed significantly between the two groups only at 1 month after surgery.

Key words: Conjunctival graft, primary pterygium, recurrent pterygium

Pterygium is one of the most common ocular diseases and it is characterized by a slightly elevated, triangular shaped conjunctival overgrowth extended to cornea. When it is associated with chronic ocular irritation, cosmetic reasons, or visual impairment that may be secondary to its growth over the pupillary axis or induced astigmatism, the standard treatment of this disease is surgical excision. The major problem associated with pterygium surgery is that high recurrence rates (2.1-87%) remain a major concern.^[1,2]

Although the recurrence of pterygium after excision remains a great challenge, several techniques have been developed to reduce the recurrence rate. These techniques include limbal conjunctival autograft, bulbar conjunctival autograft, amniotic membrane transplantation and the application of adjuncts such as mitomycin C, β -irradiation and antiangiogenic agents.^[3-6] At present, there is no established consensus on which surgical technique should serve as the gold standard, because there is no consensus on whether any of these techniques completely prevents recurrence. Nevertheless, conjunctival autograft transplantation is currently the most frequently used procedure for the treatment of both primary and recurrent pterygium. This technique has been associated with low complications and recurrence rates, as well as with improved post-operative comfort and favorable cosmetic results.^[7-9]

Anterior segment optical coherence tomography (AS-OCT), which is a new non-invasive, non-contact, high-resolution imaging

technique, has been shown in previous studies to objectively assess anterior segment structures, including anterior chamber angle, cornea, conjunctiva and tear meniscus.^[10-15] The aim of this study is to assess the post-operative changes in the thickness of conjunctival autografts using Visante-OCT (Carl-Zeiss Meditec, Dublin, CA, USA), which is a commonly used AS-OCT device for imaging the anterior segment structures, after primary or recurrent pterygium surgeries.

Materials and Methods

Study design and participants

This prospective, randomized and interventional study was performed at the Beyoglu Eye Research and Training Hospital. The study was conducted according to the principles of the Declaration of Helsinki and was approved by the local ethics committee. Once the informed consent document has been signed, subjects are considered enrolled in the study.

A total of 20 eyes of 20 patients with primary pterygium (primary group) and 20 eyes of 20 patients with recurrent pterygium (recurrent group) were enrolled in study. All patients underwent pterygium excision with conjunctival autograft transplantation. Exclusion criteria included prior conjunctival and scleral surgery, a history of a systemic condition that could compromise wound healing and a history of any ocular surface disease other than pterygium, uveitis and retinal vascular diseases.

Surgical procedure

All pterygium surgeries were performed under subconjunctival (lidocaine 2% and epinephrine) anesthesia by the same surgeon (EBO) to reduce operator bias. The head of the pterygium was separated at the limbus and dissected toward the central cornea using a crescent knife. Then, the

Access this article online

Website:

www.ijo.in

DOI:

10.4103/0301-4738.129765

Quick Response Code:

Department of Ophthalmology, Beyoglu Eye Research and Training Hospital, Istanbul, ¹Canakkale Onsekiz Mart University, Canakkale, Turkey

Correspondence to: Dr. Necip Kara, Kartaltepe Mh. Akın Sk. Akın Apt No: 8/14, Bakırköy, Istanbul, Turkey. E-mail: dr.necipkara@gmail.com

Manuscript received: 16.02.13; **Revision accepted:** 02.12.13

pathologic fibrovascular tissue underlying the pterygium was exposed through blunt and sharp dissection up to the insertion of the medial rectus muscle. The wound bed was scraped to clear the cornea and sclera. Minimal cauterization was used to control bleeding. A free conjunctival autograft of a size equivalent to the recipient's bed was harvested from the superotemporal bulbar area with attentive dissection under topical anaesthesia to avoid the inclusion of any Tenon's tissue. Then, the autograft was secured in place with Nylone 10-0 sutures. Post-operatively, patients were instructed to instill a fluorometolon asetat and tetrahydrozolin HCl (Efemoline®, Novartis) 4 times daily as well as a topical Moxifloxacin (Vigamox; Alcon, Fort Worth, Texas) 4 times daily for the 1st month following the surgery. Patients were seen prior to surgery and thereafter at 1 day, 1 week, 1 month and 3 months after surgery.

Visante AS-OCT measurement

All measurements were performed using the commercially available Visante-OCT. The details of AS-OCT imaging technology have been previously described.^[16] Anterior segment measurements using AS-OCT were performed under the same room conditions by a single clinician who was masked in terms of groups. Imaging with AS-OCT was performed at 1 week, 1 month and 3 months after surgery to measure thickness of the conjunctival graft. Enhanced high resolution corneal scans were used to obtain high quality AS-OCT images. While the patient's head was kept straight, the imaging was done in the primary position and also the subjects viewed an external fixation target to scan the graft. The AS-OCT measurements were performed at the horizontal meridian in the center of the graft at a line crossing the pupil center. Graft thickness at 1, 2 and 3 mm posterior to scleral spur was measured with a caliper tool provided by the AS-OCT software [Figs. 1 and 2].

Main outcome measures

The main outcome measures were the thickness of the conjunctival graft at 1, 2 and 3 mm posterior to the scleral spur and the average of these measurements.

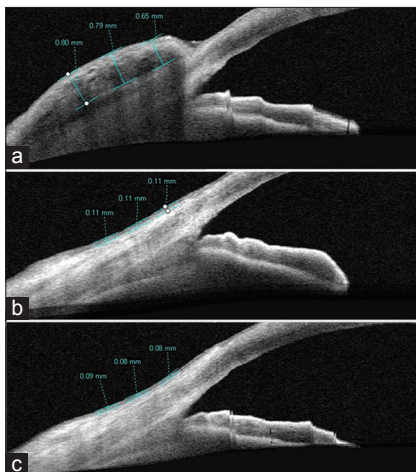


Figure 1: Imaging of anterior segment optical coherence tomography shows measurement of thickness of the conjunctival graft after primary pterygium surgery at post-operative 1 week (a), 1 month (b) and 3 months (c)

Data analyses

Statistical analysis was performed using SPSS version 15 (SPSS Inc., Chicago, IL). Fisher exact test was used to compare categorical variables. Paired *t*-tests were performed to compare the graft thickness between various follow-up time points. Independent Student's *t*-test was used to compare variables between two groups. A $P < 0.05$ was considered to be significant.

Results

Demographic profile

This study included 40 eyes of 40 patients. The demographic characteristics of the two groups of subjects are as shown in Table 1. No statistically significant difference was observed between the two groups in terms of age, gender distributions, laterality and length of pterygium (from limbus to apex). The surgery was uneventful in all cases with no intra or post-operative complications as at 3 months of follow-up.

Conjunctival graft changes

Table 2 displays the average conjunctival graft thickness and the graft thickness of the 1, 2 and 3 mm locations at 1 week, 1 month and 3 months after surgery in the primary and recurrent groups. Both the average graft thickness and the graft thicknesses of all measured locations were significantly lower in the primary group than in the recurrent group at 1 month after surgery ($P < 0.01$ for all); however, no significant difference was found between the two groups at post-operative 1 week or 3 months ($P > 0.05$ for all).

Table 3 shows a pairwise comparison of average graft thickness at 1 week, 1 month and 3 months. Average graft thickness significantly decreased between 1 week and 1 month in both groups. Although the graft thickness in the recurrent group did significantly decrease between 1 month and 3 months, the thickness did not significantly decrease in the primary group between 1 and 3 months.

Discussion

Pterygium excision with conjunctival autograft is a well-accepted technique and is currently one of the most commonly used methods for pterygium surgery. It has been shown to be

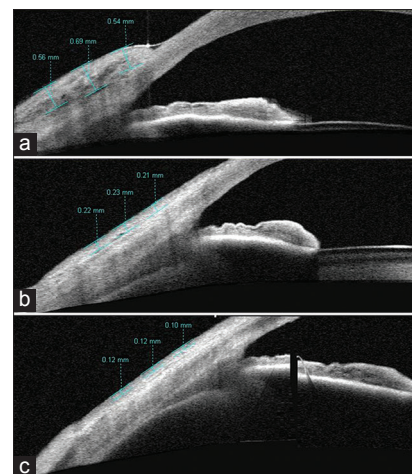


Figure 2: Anterior segment optical coherence tomography image of a patient after recurrent pterygium excision shows conjunctival graft thickness at post-operative 1 week (a), 1 month (b) and 3 months (c)

Table 1: The demographic and clinical characteristics of patients

	Primary group (n=20)	Recurrent group (n=20)	P
Age (year)			
Mean±SD (range)	47.8.5±15.7 (24-83)	50.9±13.2 (22-77)	0.569 ^a
Gender			
Female/male	9/11	6/14	0.514 ^b
Eye			
Right/left	8/12	13/7	0.204 ^b
Number of recurrence (%)			
1		16 (80)	
2		4 (20)	
Length of pterygium (mm)			
Mean±SD (range)	3.3±0.8 (1.6-4.8)	3.7±0.9 (1.7-5.1)	0.360 ^a

SD: Standard deviation. ^aindependent-t test, ^bFisher exact test**Table 2: Changes of the conjunctival graft thickness (µm) after pterygium surgery**

	Mean±SD		P ^a
	Primary group	Recurrent group	
Post-operative 1 week			
1 mm	387±97	441±150	0.252
2 mm	448±141	467±186	0.760
3 mm	454±156	475±211	0.763
Average	430±127	461±178	0.587
Post-operative 1 month			
1 mm	107±19	143±40	0.004
2 mm	112±21	167±59	0.002
3 mm	122±23	177±49	0.001
Average	114±19	162±48	0.001
Post-operative 3 month			
1 mm	101±15	104±21	0.666
2 mm	110±16	109±19	0.910
3 mm	117±16	108±18	0.177
Average	109±15	107±18	0.726

SD: Standard deviation. ^aindependent-t test**Table 3: Pairwise comparisons of average graft thickness at different post-operative visits**

Post-operative visit	P ^a	
	Primary group	Recurrent group
1 week-1 month	<0.001	<0.001
1 month-3 months	0.236	0.001

^apaired t test

safe and effective at reducing post-operative recurrences.^[17,18] However, conjunctival graft morphology after surgery has not

been sufficiently investigated. Only the study by Kheirkhah *et al.* has conducted a quantitative assessment of conjunctival graft morphology after primary pterygium surgery.^[16]

Recurrent pterygium excision with a conjunctival autograft differs somewhat from primary pterygium surgery. The recurrent excision involves a markedly longer operative time, more surgical manipulation and higher expected recurrence rates.^[19] Therefore, we hypothesized that the post-operative graft morphology after recurrent pterygium surgery would differ from the morphology after primary pterygium surgery. In this study, we evaluated the conjunctival graft thickness using AS-OCT after primary and recurrent pterygium surgery. To the best of our knowledge, this is the first quantitative study to investigate graft thickness after recurrent pterygium surgery and to compare that thickness with the thickness after primary pterygium surgery. The study obtained some new findings. First, the average conjunctival graft thickness and each measured point of graft thicknesses was significantly higher in the recurrent group than in the primary group at 1 month after surgery, but no significant difference was found between the groups at 1 week or 3 months after surgery. These findings indicate that there was significant thinning of the graft and faster conjunctival healing during post-operative 1 month in the primary group. However, the thickness values at post-operative 3 months were similar for the two groups. Second, the average thickness of the graft in the recurrent group decreased significantly from 1 week to 1 month after surgery and continued to decrease up to 3 months post-operatively. In contrast, the graft thickness in the primary group decreased significantly at post-operative 1 month, but no significant difference was found between the 1- and 3-month values. These findings were similar to those of the study by Kheirkhah *et al.*, who also found no significant difference between the 1- and 3-month values after primary pterygium surgery.^[18] Third, the conjunctival graft was thickest at the 1 mm location and thinnest at 3 mm location during all post-operative visits for both groups. These findings are partially similar to Kheirkhah *et al.*'s findings, except for the 1-month values. Specifically, Kheirkhah *et al.* found that the conjunctival graft and the normal temporal conjunctival epithelium were thickest at the 1 mm location and thinnest at the 3 mm location at only 1 week and 3 months after surgery.^[16]

Data for conjunctival graft thickness acquired with the AS-OCT might be valuable because graft edema and the healing process of the graft implantations could be visualized, objectively measured and monitored. Previous studies have shown clinically noticeable edema of the free conjunctival graft after pterygium surgery without using any imaging methods.^[6,20-24] Mutlu *et al.* in their study have reported graft edema in 100% of eyes with recurrent pterygium after undergoing the limbal conjunctival autograft.^[20] Sarnicola *et al.* indicated that 40.5% of eyes fulfilled the clinical diagnosis of graft edema 7 days after surgery, yet all cases were resolved during the 1st month of follow-up.^[21] On the other hand, Dadeya *et al.* reported graft edema in only 2.8% of eyes.^[22] Given the present findings and the findings of Kheirkhah *et al.*, it seems that all conjunctival grafts exhibit some visible degree of edema when imaged with AS-OCT. Thus, graft edema could remain undetected if ophthalmologists use only clinical measures to verify its presence. This study seems to suggest

that self-limiting conjunctival graft edema invariably occurs in all grafts in the early post-operative period.

Although the exact mechanism of post-operative graft edema remains unknown, this edema has been attributed to excessive surgical manipulation, the use of Vicryl sutures, graft desiccation, inadequate Tenon's excision, poor graft orientation, young patients and hematoma of the graft.^[6,20,23] The groups in the present study were similar in age and gender distribution. The conjunctival graft was harvested with attentive dissection to avoid the inclusion of any Tenon's tissue and it was tightly sutured with Nylon 10-0 sutures to prevent overlap. Furthermore, the surgeries were performed without intraoperative or post-operative complications, such as pterygium recurrence, hematoma beneath the graft and pyogenic granuloma, despite the fact that the recurrent pterygium excision required more surgical manipulation. Further studies involving a quantitative evaluation of conjunctival grafts using AS-OCT could investigate the effects of the various possible causes of conjunctival graft edema.

This research was restricted by some limitations. First, it featured a relatively small sample size. Larger studies are needed to validate these findings. Second, the study did not include a control group of eyes with normal conjunctival thickness. Although AS-OCT is a commonly used device for imaging anterior segment structures, attempting to determine the entire thickness of normal bulbar conjunctiva, including the epithelium and stroma, is a challenge, because of the anatomical characteristics of this tissue and the limitations of the imaging techniques. Third, the surgeon dissected the conjunctival graft from Tenon's tissue. Even so, some residual Tenon's tissue could be found beneath the grafts.

In summary, this is the first report to compare the post-operative conjunctival graft thicknesses between primary and recurrent pterygium excisions using AS-OCT measurements. The outcomes of this study demonstrated that graft thickness decreased significantly during the post-operative 1 month in the primary group and was reduced significantly during the post-operative 3 months in the recurrent group. Graft thickness increased significantly in the recurrent group over the primary group at 1 month after surgery and no significant difference was found between the groups at 1 week or 3 months after surgery. The effects of this conjunctival graft edema on outcomes of primary or recurrent pterygium surgery such as recurrence rate and cosmetic appearance require future studies with long-term follow-up in large case series. Finally, AS-OCT appears to offer a non-contact, convenient and rapid method for assessing conjunctival graft morphology after pterygium excision and it could be used for *in vivo* investigations of conjunctival grafts in clinical and experimental studies.

References

1. Anduze AL, Burnett JM. Indications for and complications of mitomycin-C in pterygium surgery. *Ophthalmic Surg Lasers* 1996;27:667-73.
2. Singh G, Wilson MR, Foster CS. Mitomycin eye drops as treatment for pterygium. *Ophthalmology* 1988;95:813-21.
3. Chen PP, Ariyasu RG, Kaza V, LaBree LD, McDonnell PJ. A randomized trial comparing mitomycin C and conjunctival autograft after excision of primary pterygium. *Am J Ophthalmol* 1995;120:151-60.
4. Prabhasawat P, Barton K, Burkett G, Tseng SC. Comparison of conjunctival autografts, amniotic membrane grafts, and primary closure for pterygium excision. *Ophthalmology* 1997;104:974-85.
5. Kenyon KR, Wagoner MD, Hettlinger ME. Conjunctival autograft transplantation for advanced and recurrent pterygium. *Ophthalmology* 1985;92:1461-70.
6. Starck T, Kenyon KR, Serrano F. Conjunctival autograft for primary and recurrent pterygia: Surgical technique and problem management. *Cornea* 1991;10:196-202.
7. Hirst LW. The treatment of pterygium. *Surv Ophthalmol* 2003;48:145-80.
8. Ang LP, Chua JL, Tan DT. Current concepts and techniques in pterygium treatment. *Curr Opin Ophthalmol* 2007;18:308-13.
9. Küçükerdönmez C, Akova YA, Altınörs DD. Comparison of conjunctival autograft with amniotic membrane transplantation for pterygium surgery: Surgical and cosmetic outcome. *Cornea* 2007;26:407-13.
10. Sakata LM, Lavanya R, Friedman DS, Aung HT, Gao H, Kumar RS, *et al.* Comparison of gonioscopy and anterior segment optical coherence tomography in detecting angle closure in different quadrants of the anterior chamber angle. *Ophthalmology* 2008;115:769-74.
11. Doors M, Tahzib NG, Eggink FA, Berendschot TT, Webers CA, Nuijts RM. Use of anterior segment optical coherence tomography to study corneal changes after collagen cross-linking. *Am J Ophthalmol* 2009;148:844-512.
12. Wang J, Aquavella J, Palakuru J, Chung S. Repeated measurements of dynamic tear distribution on the ocular surface after instillation of artificial tears. *Invest Ophthalmol Vis Sci* 2006;47:3325-9.
13. Chen Q, Wang J, Shen M, Cai C, Li J, Cui L, *et al.* Lower volumes of tear menisci in contact lens wearers with dry eye symptoms. *Invest Ophthalmol Vis Sci* 2009;50:3159-63.
14. Singh M, Aung T, Aquino MC, Chew PT. Utility of bleb imaging with anterior segment optical coherence tomography in clinical decision-making after trabeculectomy. *J Glaucoma* 2009;18:492-5.
15. Ciancaglini M, Carpineto P, Agnifili L, Nubile M, Lanzini M, Fasanella V, *et al.* Filtering bleb functionality: A clinical, anterior segment optical coherence tomography and *in vivo* confocal microscopy study. *J Glaucoma* 2008;17:308-17.
16. Kheirkhah A, Adelpour M, Nikdel M, Ghaffari R, Ghassemi H, Hashemi H. Evaluation of conjunctival graft thickness after pterygium surgery by anterior segment optical coherence tomography. *Curr Eye Res* 2011;36:782-6.
17. Tan DT, Chee SP, Dear KB, Lim AS. Effect of pterygium morphology on pterygium recurrence in a controlled trial comparing conjunctival autografting with bare sclera excision. *Arch Ophthalmol* 1997;115:1235-40.
18. Sharma A, Gupta A, Ram J, Gupta A. Low-dose intraoperative mitomycin-C versus conjunctival autograft in primary pterygium surgery: Long term follow-up. *Ophthalmic Surg Lasers* 2000;31:301-7.
19. Ozkurt YB, Kocams O, Comez AT, Uslu B, Dogan OK. Treatment of primary pterygium. *Optom Vis Sci* 2009;86:1178-81.
20. Mutlu FM, Sobaci G, Tatar T, Yildirim E. A comparative study of recurrent pterygium surgery: Limbal conjunctival autograft transplantation versus mitomycin C with conjunctival flap. *Ophthalmology* 1999;106:817-21.
21. Sarnicola V, Vannozzi L, Motolese PA. Recurrence rate using fibrin glue-assisted ipsilateral conjunctival autograft in pterygium surgery: 2-year follow-up. *Cornea* 2010;29:1211-4.
22. Dadeya S, Kamlesh, Khurana C, Fatima S. Intraoperative daunorubicin versus conjunctival autograft in primary pterygium surgery. *Cornea* 2002;21:766-9.

23. Bahar I, Weinberger D, Dan G, Avisar R. Pterygium surgery: Fibrin glue versus Vicryl sutures for conjunctival closure. *Cornea* 2006;25:1168-72.
24. Marticorena J, Rodríguez-Ares MT, Touriño R, Mera P, Valladares MJ, Martínez-de-la-Casa JM, *et al.* Pterygium surgery: Conjunctival autograft using a fibrin adhesive. *Cornea* 2006;25:34-6.

Cite this article as: Ozgurhan EB, Kara N, Bozkurt E, Gencer B, Yuksel K, Demirok A. Comparison of conjunctival graft thickness after primary and recurrent pterygium surgery: Anterior segment optical coherence tomography study. *Indian J Ophthalmol* 2014;62:675-9.

Source of Support: Nil. **Conflict of Interest:** None declared.