


Ultrasonographic features of ulnar nerve instability around the elbow in fresh cadavers

Beom Suk Kim, MD^{a,b}, Im Joo Rhyu, MD, PhD^{c,d}, Dong Hwee Kim, MD, PhD^{e,*} 

Abstract

Ultrasound (US) is commonly used to evaluate ulnar nerve instability (UNI) and snapping of the medial head of the triceps brachii muscle (ST). We aimed to determine the diagnostic accuracy of US in evaluating UNI, through cadaveric dissection, and to evaluate the US features and relationships of UNI and ST according to elbow flexion. Dynamic US was performed with elbow extension, 90° flexion, and full flexion positions on 18 elbows from 9 fresh cadavers. UNI was classified into N (normal), S (subluxation), and D (dislocation) types. On US exams, the following findings and parameters were evaluated: the presence of UNI and ST; the horizontal distance from the apex of the medial epicondyle (ME) to the margins of the UN and medial head of the triceps brachii muscle (ME_UN and ME_TB, respectively); cross-sectional area and flattening ratio (FR) of UN. After US, all cadavers were dissected to expose the UN and TB, and elbow flexion and extension were simulated to confirm UNI and ST. The gross anatomic findings of UNI and ST were consistent with the US findings. In extension and 90° flexion positions, all cases were type N. In full flexion position, types N and S occurred in 10 (56%) and 8 (44%) elbows, respectively. FR and ME_UN in 90° flexion position, FR, ME_UN, and ME_TB in full flexion position differed significantly between types S and N. Positive correlations were found between ME_UN and ME_TB in 90° flexion and full flexion positions. Dynamic US accurately assessed UNI and ST. UNI was positively correlated to medial TB movement.

Abbreviations: FR = flattening ratio, ME = medial epicondyle, ST = snapping of the medial head of the triceps brachii muscle, TB = triceps brachii, UN = ulnar nerve, UNI = UN instability, US = ultrasound.

Keywords: peripheral nerves, ulnar nerve (UN), ulnar neuropathies, ultrasonography

1. Introduction

The ulnar nerve (UN) and the medial head of the triceps brachii muscle (TB) have been reported to move anterior to the medial epicondyle (ME) of the humerus during elbow flexion. UN instability (UNI), including subluxation and dislocation, is considered a potential risk factor for friction neuritis around the elbow by increasing the vulnerability to external compression forces.^[1-3]

While computed tomography scans and magnetic resonance imaging after dislocation have been used to assess UNI and snapping of the medial head of the triceps brachii muscle (ST), ultrasound (US) is considered the diagnostic modality of choice. US not only enables the identification of UN by dynamic scan but also allows the morphometric characterization and quantification of nerve parameters.^[1,2,4-8]

Despite the clinical importance of the UNI, few studies have elucidated the mechanism and relationship between UNI and ST. Furthermore, investigations comparing US findings of UNI and ST with actual anatomical findings after cadaver dissection for diagnostic confirmation are lacking. Considering that one potential pitfall of dynamic US when evaluating UNI is that excessive pressure of the transducer can inhibit UN dislocation, a comparison of the US findings of UNI with post-dissection results is an essential process when documenting the diagnostic accuracy of US.^[9]

Therefore, we aimed to determine the diagnostic accuracy of US in evaluating UNI, through fresh cadaveric dissection, and to evaluate the US features and relationships of UNI and ST according to elbow flexion.

IJR and DHK contributed equally to this work.

This work was supported by the National Research Foundation of Korea (NRF) grant funded by the Korean government (MSIT) (NRF-2020R1F1A1069106). This research was supported by Basic Science Research Program through the National Research Foundation of Korea (NRF) funded by the Ministry of Education (2020R111A1A01074880).

The authors have no conflicts of interest to disclose.

The datasets generated during and/or analyzed during the current study are available from the corresponding author on reasonable request.

We confirm that we have read the Journal's position on issues involved in ethical publication and affirm that this report is consistent with those guidelines.

^a Department of Physical and Rehabilitation Medicine, Chung-Ang University Gwangmyeong Hospital, Gyeonggi-do, Republic of Korea, ^b Department of Physical and Rehabilitation Medicine, Chung-Ang University College of Medicine, Seoul, Republic of Korea, ^c Department of Anatomy, Korea University College of Medicine, Seoul, Republic of Korea, ^d Department of Biomedical Sciences, Brain Korea 21 FOUR, Korea University College of Medicine, Seoul, Korea, ^e

Department of Physical Medicine and Rehabilitation, Korea University College of Medicine, Seoul, Republic of Korea.

* Correspondence: Dong Hwee Kim, Department of Physical Medicine and Rehabilitation, Korea University Ansan Hospital, 123, Jeokgeum-ro, Danwon-gu, Ansan-si, Gyeonggi-do 15355, Republic of Korea (e-mail: rmkdh@korea.ac.kr).

Copyright © 2023 the Author(s). Published by Wolters Kluwer Health, Inc. This is an open-access article distributed under the terms of the Creative Commons Attribution-Non Commercial License 4.0 (CCBY-NC), where it is permissible to download, share, remix, transform, and buildup the work provided it is properly cited. The work cannot be used commercially without permission from the journal.

How to cite this article: Kim BS, Rhyu IJ, Kim DH. Ultrasonographic features of ulnar nerve instability around the elbow in fresh cadavers. *Medicine* 2023;102:5(e32835).

Received: 11 April 2021 / Received in final form: 14 December 2022 / Accepted: 15 December 2022

<http://dx.doi.org/10.1097/MD.0000000000032835>

2. Methods

2.1. Cadaver preparation

Eighteen elbows of 9 fresh cadavers (3 female, 6 male) were evaluated after obtaining approval from the cadaver research review board. There was no known evidence of previous surgery or trauma around the upper extremities. None of the causes of death indicated a nature that could have affected this investigation regarding dissection or manipulation. This cadaveric study was exempted from review of Institutional Review Board because it was conducted before Act on Dissection and Preservation of Corpses was enacted.

2.2. Ultrasonographic examination

Real-time US was conducted using the MySono U6 system (Samsung Medison, Seoul, Republic of Korea) with a 5 to 12 MHz high-frequency linear array transducer. The cadavers were laid on autopsy tables in the supine position with minimal external rotation of the shoulder for easy access to the ME and olecranon. One rehabilitation medicine physician with >20 years of experience in neuromuscular US performed all examinations.

Dynamic US was performed in 3 elbow positions: extension, 90° flexion, and full flexion (Fig. 1). The US probe was applied on an imaginary line connecting the ME and olecranon process in the elbow extension position. In contrast, in the 90° flexion and full flexion positions, the transducer was stabilized to the ME and placed perpendicular to the nerve fibers for the exact identification of the nerve and precise measurement of the parameters.^[11,9]

The UNI was classified into 3 types in each elbow position: type N, normal (no subluxation or dislocation of the UN); type S, subluxation (UN on the ME), and type D, dislocation (UN moved beyond the tip of the ME) (Fig. 2).^[2] ST was defined as anterior dislocation of the muscle over the tip of ME during elbow flexion.

The sonographically measured parameters included the cross-sectional area of the UN, flattening ratio (FR, the ratio of the major axis to the minor axis of the nerve), and the horizontal distance from the apex of ME to the margin of UN and TB (ME_UN and ME_TB, respectively) (Fig. 2).^[2,10] The cross-sectional area of the nerve was measured with a direct tracing method along the innermost part of the linear hyperechogenic line corresponding to the epineurium.

2.3. Dissection and assessment

After the US examinations, all cadavers were dissected to expose the UN and TB and elbow flexion and extension were repeatedly simulated to confirm the UNI and ST (Fig. 1). During the dissection, special caution was paid to retain the retinaculum over the UN, as it might prevent the UN from moving or over the ME.

2.4. Statistical analysis

Data analyses were conducted using IBM SPSS Statistics for Windows, version 20.0 (IBM Corp., Armonk, NY). We used Mann–Whitney *U* tests to compare the differences in US parameters between the normal and subluxation groups. In addition, Spearman correlation tests were used to assess the relationships between ME_UN and ME_TB. Statistical significance was set at $P < .05$.

3. Results

3.1. Ultrasonographic examinations

In the elbow extension and 90° flexion positions, all cases were type N. In the full flexion position, types N and S were observed in 10 (56%) and 8 (44%) elbows, respectively. Type D was not

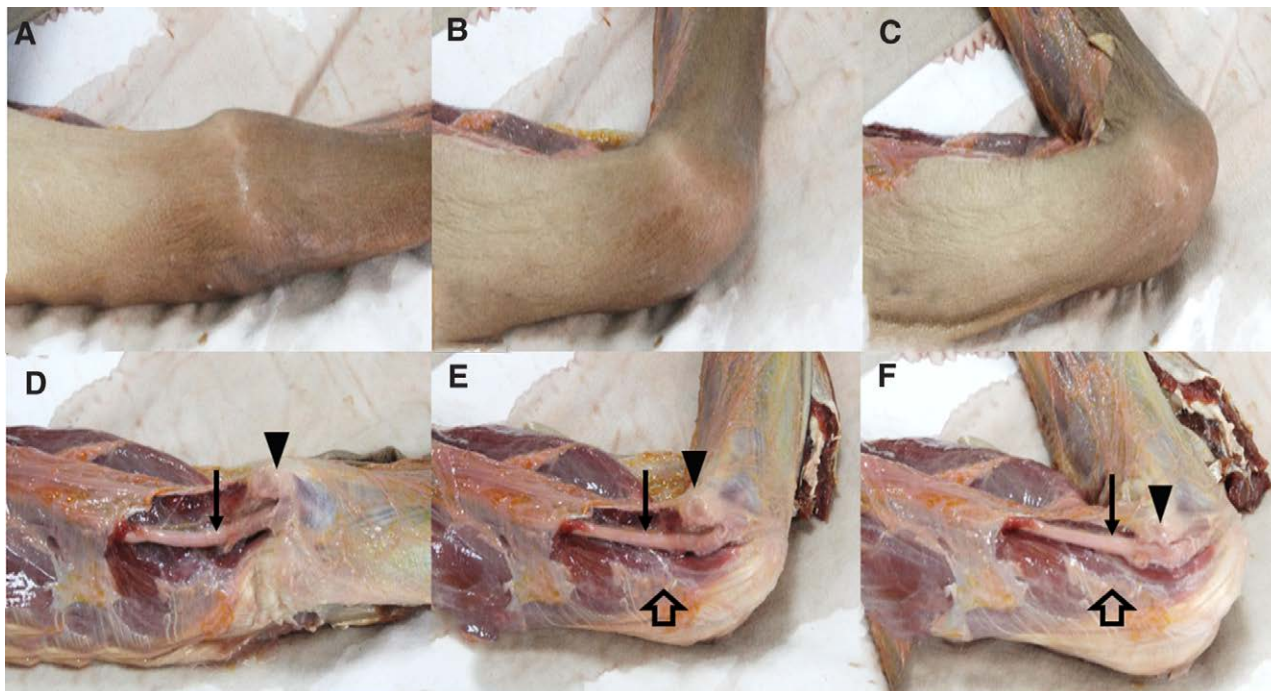


Figure 1. Dynamic ultrasound was performed in 3 elbow positions: (A) extension, (B) 90° flexion, and (C) full flexion. (D–F) After US examinations, all cadavers were dissected to expose the ulnar nerve and medial head of the triceps brachii muscle, and elbow flexion and extension were simulated to confirm the ulnar nerve instability and snapping of the triceps. *Solid arrow: ulnar nerve; open arrow: medial head of the triceps brachii; arrowhead: medial epicondyle. US = ultrasound.

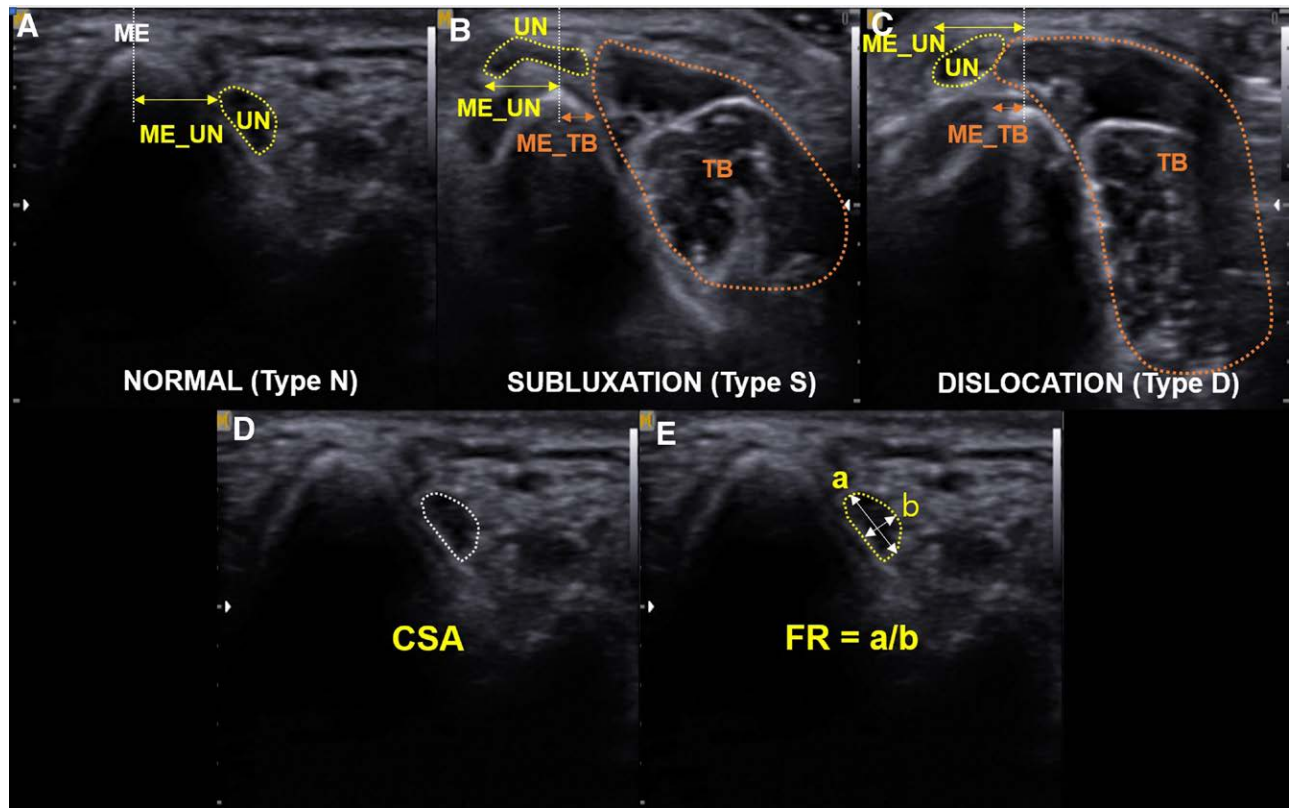


Figure 2. Ulnar nerve instability was classified into 3 types: type N, normal; type S, subluxation; type D, dislocation. (A–C) The horizontal distances from the apex of the medial epicondyle (ME) to the margins of the ulnar nerve (UN) and medial head of the triceps brachii (TB), ME_UN, and ME_TB, respectively, were measured. (D and E) The cross sectional area (CSA) and flattening ratio (FR) of the UN were also measured. FR was defined as the ratio of the major axis to the minor axis of the nerve. * a: long axis of the ulnar nerve; b: short axis of the ulnar nerve. CSA = cross-sectional area, FR = flattening ratio, ME = medial epicondyle of the humerus, TB = medial triceps brachii muscle, UN = ulnar nerve, UNI = ulnar nerve instability.

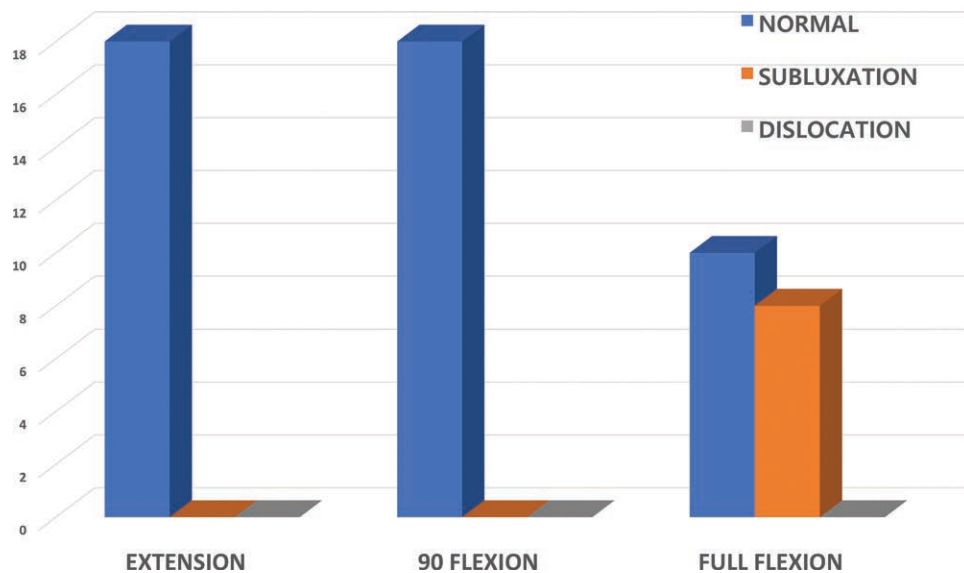


Figure 3. Frequency of ulnar nerve instability (UNI) according to the 3 elbow positions: extension, 90° flexion, and full flexion. UNI = ulnar nerve instability.

observed in any elbow position and ST was not observed in any of the cases (Fig. 3).

The US parameters of type S that differed significantly from type N were FR and ME_UN in the 90° flexion position, FR, ME_UN, and ME_TB in the full flexion position (Table 1).

Positive correlations were observed between ME_UN and ME_TB in the 90° flexion and full flexion positions (Spearman correlation coefficients of 0.74 and 0.82, respectively, $P < .001$) (Fig. 4).

3.2. Cadaver dissection

The gross anatomic findings of UNI and ST were consistent with the US findings. In cases of subluxation of the UN at the full flexion position of the elbow on US examinations, consistent results were observed at dissection. Throughout the repetitive simulations of elbow flexion and extension, dislocation of the UN or snapping of the TB muscle was not observed in any case.

Table 1**Ultrasonographic parameters of the ulnar nerve and medial triceps muscle in 3 elbow positions.**

Elbow position	US parameters	Type N (10 elbows)	Type S (8 elbows)	Total (18 elbows)	P value
Extension	CSA	8 (5–11)	11.0 (5–19)	8.5 (5–19)	.095
	FR	2.3 (1.6–2.5)	1.5 (1.4–2.4)	1.9 (1.4–2.9)	.006
	ME_UN	6.9 (4.7–8.7)	5.6 (2.4–8.0)	6.3 (2.4–8.7)	.211
90° flexion	CSA	7.5 (5–13)	10.5 (6–20)	10.0 (5–20)	.178
	FR	2.1 (1.3–3.2)	1.5 (1.2–1.6)	1.6 (1.2–3.2)	.004*
	ME_UN	5.9 (4.6–6.5)	3.7 (2.0–7.8)	5.2 (2–7.8)	.036*
Full flexion	ME_TB	10.6 (6.9–15.5)	7.6 (5.3–12.1)	9.3 (5–15.5)	.096
	CSA	7 (3–14)	10 (6–20)	9.5 (3–20)	.083
	FR	1.8 (1.2–2.3)	2.7 (2–4.6)	2.2 (1.2–4.6)	.027*
	ME_UN	4.7 (2.8–5.7)	-1 (-6.9–0.1)	3.2 (-6.9–5.7)	<.001*
	ME_TB	7.7 (5.1–10.7)	2.9 (1.6–6.7)	5.8 (1.6–10.7)	.002*

CSA = cross-sectional area, FF = full flexion of the elbow, FR = flattening ratio, ME = medial epicondyle, ME_TB = the horizontal distance from the apex of the medial epicondyle to the margins of the medial head of the triceps brachii muscle, ME_UN = the horizontal distance from the apex of the medial epicondyle to the margins of the ulnar nerve, N = normal, S = subluxation, TB = medial triceps brachii muscle, UN = ulnar nerve, US = ultrasound.

Values are presented as median (range).

* $P < .05$.

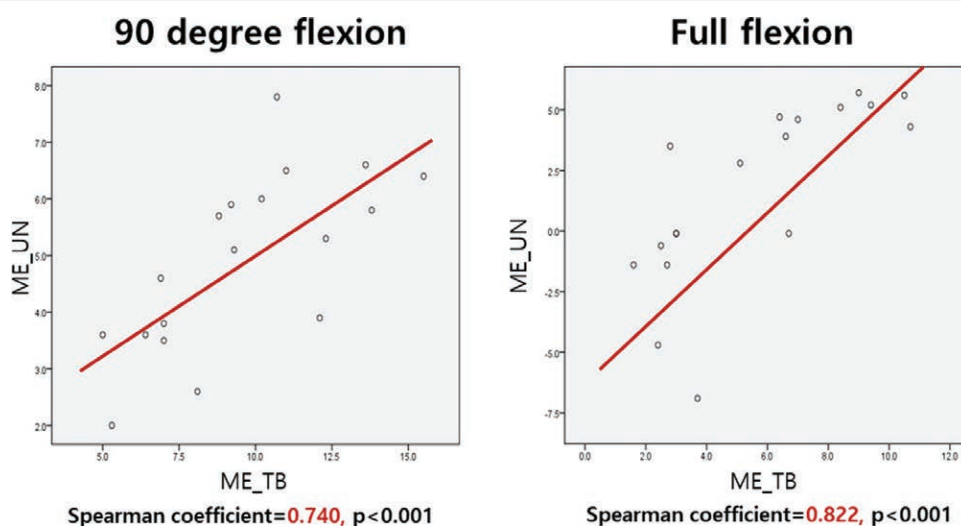


Figure 4. Spearman correlations between the horizontal distance from the tip of the medial epicondyle to the margin of the ulnar nerve (ME_UN) and the horizontal distance from the tip of the medial epicondyle to the margin of triceps brachii (ME_TB) during (A) 90° flexion and (B) full flexion of the elbow.

4. Discussion

The results of this study showed that the gross anatomic findings of UNI and ST were consistent with the US findings. UN subluxation was induced by full flexion of the elbow in 8 (44%) cases. In terms of morphology, UN with subluxation was less flattened than normal in the 90° flexion position but was more flattened in the full flexion position. In the subluxation cases, the TB was closer to the ME than normal in the full flexion position, while the UN was closer to the ME in both the 90° flexion and full flexion positions. In addition, ME_UN was positively correlated with ME_TB in the elbow flexion positions.

Several studies have investigated the usefulness of US in diagnosing UNI and ST. A dynamic US study by Okamoto et al that examined 200 normal elbows observed types S and D in 27% and 20% of cases, respectively, in the elbow flexion position.^[2] In a previous study by other group that evaluated 26 healthy individuals, types S and D were observed in 15.4% and 5.6% of elbows, respectively, in the 90° flexion position, and 36.5% and 17.3%, respectively, in the full flexion position.^[1] In the present cadaveric study, although type S was observed in a similar proportion of elbows as reported previously, type D was not observed. This might be due to the small number of subjects in the study. However, this study is novel in that, to our knowledge, it is the first to elucidate the diagnostic accuracy of

US in evaluating UNI and ST through anatomic confirmation after cadaver dissection. In a report that utilized dynamic US for the diagnosis of UNI and ST, Jacobson et al commented a critical pitfall that clinicians can face is that the excessive pressure loading of the transducer inhibits the UN and TB from anterior dislocation.^[9] We also encountered a case in which UNI and ST were regarded as false-negative findings when the test was performed by an inexperienced physician. Therefore, comparing the US findings of UNI and ST to gross anatomic findings after cadaveric dissection (anatomic confirmation) is essential when documenting diagnostic accuracy. Considering the consistent results of this study, between US findings solely by a specialist with >20 years of experience in neuromuscular US and those following simulation after cadaver dissection, US is considered an accurate diagnostic tool for the assessment of UNI and ST.

In terms of morphologic characteristics, compared to previous studies, the findings of this study were consistent with reports of a more flattened UN in type S than in type N when the elbow was fully flexed. However, in the present study, there was a difference in that the FR of type S was smaller than that of type N in the 90° flexion position. This is likely due to differences in baseline characteristics. Although the difference in FR between types S and N in the elbow extension position was not statistically significant, the P value was relatively low at 0.06. As the FR was greater for type S than for type N in the full flexion

position despite this baseline difference, the UN flattened as it subluxated.

The results of this study are consistent with those of previous studies reporting anterior movement of the UN and TB with elbow flexion in both types S and N.^[1,2,10-13] Furthermore, the finding of a positive correlation between ME_UN and ME_TB is also concordant with that reported previously by the authors' group.^[1] This study is meaningful in that it confirmed the possible association between UNI and ST suggested by Jacobsen and Kang et al^[9,10] Further research on the biomechanical linkage and mechanism of UNI and ST is warranted.

This study has several limitations. First, as this was a fresh cadaveric study, alterations in anatomic structures could have affected the results. Second, the sample size was small, which limits the generalizability of the findings. Third, as there were no cases of UN dislocation, this study was limited to UN subluxation.

In conclusion, dynamic US is considered an accurate and useful diagnostic tool for evaluating UNI and ST. In elbow flexion positions, US features of the UN subluxation cases differed from those of normal cases. In addition, UNI was related to the medial movement of the TB.

Author contributions

Conceptualization: Beom Suk Kim, Im Joo Rhyu, Dong Hwee Kim.

Data curation: Im Joo Rhyu, Dong Hwee Kim.

Formal analysis: Beom Suk Kim, Im Joo Rhyu.

Funding acquisition: Beom Suk Kim, Dong Hwee Kim.

Investigation: Dong Hwee Kim.

Methodology: Dong Hwee Kim.

Project administration: Dong Hwee Kim.

Supervision: Beom Suk Kim, Im Joo Rhyu, Dong Hwee Kim.

Validation: Beom Suk Kim, Dong Hwee Kim.

Visualization: Beom Suk Kim.

Writing – original draft: Dong Hwee Kim.

Writing – review & editing: Beom Suk Kim.

References

- [1] Kang JH, Joo BE, Kim KH, et al. Ultrasonographic and electrophysiological evaluation of ulnar nerve instability and snapping of the triceps medial head in healthy subjects. *Am J Phys Med Rehabil.* 2017;96:e141–6.
- [2] Okamoto M, Abe M, Shirai H, et al. Morphology and dynamics of the ulnar nerve in the cubital tunnel. Observation by ultrasonography. *J Hand Surg Br.* 2000;25:85–9.
- [3] Rioux-Forker D, Bridgeman J, Brogan DM. Snapping triceps syndrome. *J Hand Surg Am.* 2018;43:90 e1–5.
- [4] Okamoto M, Abe M, Shirai H, et al. Diagnostic ultrasonography of the ulnar nerve in cubital tunnel syndrome. *J Hand Surg Br.* 2000;25:499–502.
- [5] Spinner RJ, Goldner RD. Snapping of the medial head of the triceps and recurrent dislocation of the ulnar nerve. anatomical and dynamic factors. *J Bone Joint Surg Am.* 1998;80:239–47.
- [6] Cho NS, Kim DH, Kim MY, et al. Electrophysiological and ultrasonographic findings in ulnar neuropathy with Martin-Gruber anastomosis. *Muscle Nerve.* 2013;47:604–7.
- [7] Chang KV, Wu WT, Han DS, et al. Ulnar nerve cross-sectional area for the diagnosis of cubital tunnel syndrome: a meta-analysis of ultrasonographic measurements. *Arch Phys Med Rehabil.* 2018;99:743–57.
- [8] Chen IJ, Chang KV, Wu WT, et al. Ultrasound parameters other than the direct measurement of ulnar nerve size for diagnosing cubital tunnel syndrome: a systemic review and meta-analysis. *Arch Phys Med Rehabil.* 2019;100:1114–30.
- [9] Jacobson JA, Jebson PJ, Jeffers AW, et al. Ulnar nerve dislocation and snapping triceps syndrome: diagnosis with dynamic sonography--report of three cases. *Radiology.* 2001;220:601–5.
- [10] Nakano K, Murata K, Omokawa S, et al. Dynamic analysis of the ulnar nerve in the cubital tunnel using ultrasonography. *J Shoulder Elbow Surg.* 2014;23:933–7.
- [11] Grechenig W, Mayr J, Peicha G, et al. Subluxation of the ulnar nerve in the elbow region--ultrasonographic evaluation. *Acta Radiol.* 2003;44:662–4.
- [12] Xarchas KC, Psillakis I, Koukou O, et al. Ulnar nerve dislocation at the elbow: review of the literature and report of three cases. *Open Orthop J.* 2007;1:1–3.
- [13] Imao K, Miwa H, Tsubokawa N, et al. Dislocation of the medial head of the triceps with ulnar nerve location anterior to the medial epicondyle. *J Hand Surg Am.* 2020;45:72 e1–4.