




ELSEVIER

Contents lists available at [ScienceDirect](https://www.sciencedirect.com)

Trauma Case Reports

journal homepage: www.elsevier.com/locate/tcr

Treatment of neglected quadriceps tendon ruptures using LARS™ ligament augmentation: A case series

Ms R. Mahoney^{*}, K. Veravalli, A. Mofidi

Morrison Hospital, Swansea SA6 6NL, United Kingdom of Great Britain and Northern Ireland

ARTICLE INFO

Keywords:

Quadriceps tendon rupture
Quadriceps tendon augmentation
Knee extensor mechanism

ABSTRACT

Background: Late presentation of Quadriceps tendon rupture (QTR) is rare. Treatment of neglected QTR's can be challenging due to scar tissue and muscle wasting and may require augmentation. Delayed tendon repairs tend to have less favourable outcome compared to acute repairs. There are very few case reports of delayed repair using various techniques.

Methods: a case series of 5 patients (6 tendon ruptures) presenting late with quadriceps tendon rupture. Repair was performed using a Codivilla V–Y plasty to extend the tendon, followed by LARS artificial ligament augmentation. All patients then received 6 weeks targeted physiotherapy after wound healing.

Results: Repair using our technique was possible in all patients. No patients needed to return to theatre due to re-rupture or infection. Only one patient required oral antibiotics for a superficial wound infection. No patient was left with a functional deficit following physiotherapy, with 4 of the 6 repairs achieving a full range of movement.

Conclusions: V–Y plasty followed by LARS augmentation can be used safely and reproducibly for the repair of delayed presentation quadriceps tendon ruptures in our cohort comprising of both healthy and co-morbid patients to achieve good functional results.

Introduction

Damage to the extensor mechanism causes significant loss of function, most often following trauma or may occur spontaneously in the setting of underlying metabolic disorders. Quadriceps tendon tears are the second most common cause for extensor mechanism disruption after patellar fractures [1]. Patients usually present early and undergo primary repair, ideally in first 48–72 h after injury, as delay is known to adversely affect outcome [2,3]. However, in the case of a late presentation or delayed diagnosis this is not possible and tendon grafts may be required to facilitate reconstruction [4]. Although autologous tendon grafting is a well-established technique [5], it is recognised that the harvesting of tendons leads to prolonged rehabilitation and increased surgical morbidity, particularly in patients that are elderly or have pre-existing co-morbidities. The use of synthetic ligament grafts and allografts is a proposed alternative [6], and has been successfully used in repair of cruciate and collateral knee ligament reconstruction, as well as patella tendon reconstruction. An isolated case report has described the use of the LARS (ligament augmentation and reconstruction system) artificial ligament, (UK Distributor, Corin Group PLC, The Corinium Centre, Cirencester, GL7 1YJ, UK) with good functional results in the repair of an incomplete intra-substance tear of the rectus femoris muscle 15 months' post injury [7].

We present a case series of five patients (six ruptured ligaments) who underwent surgical treatment of neglected quadriceps tendon

^{*} Corresponding author.

E-mail address: Rachel.mahoney@nhs.net (M.R. Mahoney).

ruptures using LARS ligament augmentation.

Methods

Patient cohort

Between May 2013 and September of 2018 five adult male patients who had sustained quadriceps tendon presented in a delayed fashion to Morriston hospital fracture clinic. The length of time between original injury and presentation was six weeks to 26 weeks. The reason for delay was late presentation in two cases and missed diagnosis by the referring clinician in 3 cases (four knees).

The mean age of our patient cohort was 52 years old (range 36–68 years), and included a body builder who used anabolic steroids, a rheumatoid patient on methotrexate, a patient renal failure with bilateral rupture and diabetic patient. One patient had already undergone an attempt at repair with Codivilla procedure that failed. Three of the patients were heavy smokers (greater than 10 cigarettes per day). All patients underwent preoperative ultrasound scan and one patient had additional MRI. On the ultrasound scan the tendon gap in hyperextension of the knee was measured to be on average 4.6cms (range 4.0–5.0 cm).

The indication for surgery in these patients was total quadriceps tendon rupture, as diagnosed by ultrasound scan of the knee joint showing significant retraction and gap in full extension.

Surgical method

Repair was performed using a longitudinal midline incision. A significant irreducible gap of over 5 cms in hyperextension was present, and the tendon required advancement to reach the patella in all cases except the patient who had failed a previous attempt at repair using Codivilla V—Y plasty, in whom the gap was closable. Initial debridement of scar tissue from the distal end of the tendon to the superior pole of the tendon was performed, as shown in [Image A](#). Rectoplasty was required in for all patients as in every case as the distal quadriceps muscle and tendon were scarred to the anterior femur. A V—Y advancement of the retracted tendon (Codivilla V—Y plasty technique), as shown in [Image B](#), was performed to adequately extend the tendon to reach proximal patella in tension free manner. The tendon was then repaired with three Fastin™ suture anchors (Deputy, Mitek, Earth city, Missouri) with (size 2 Fibre wire

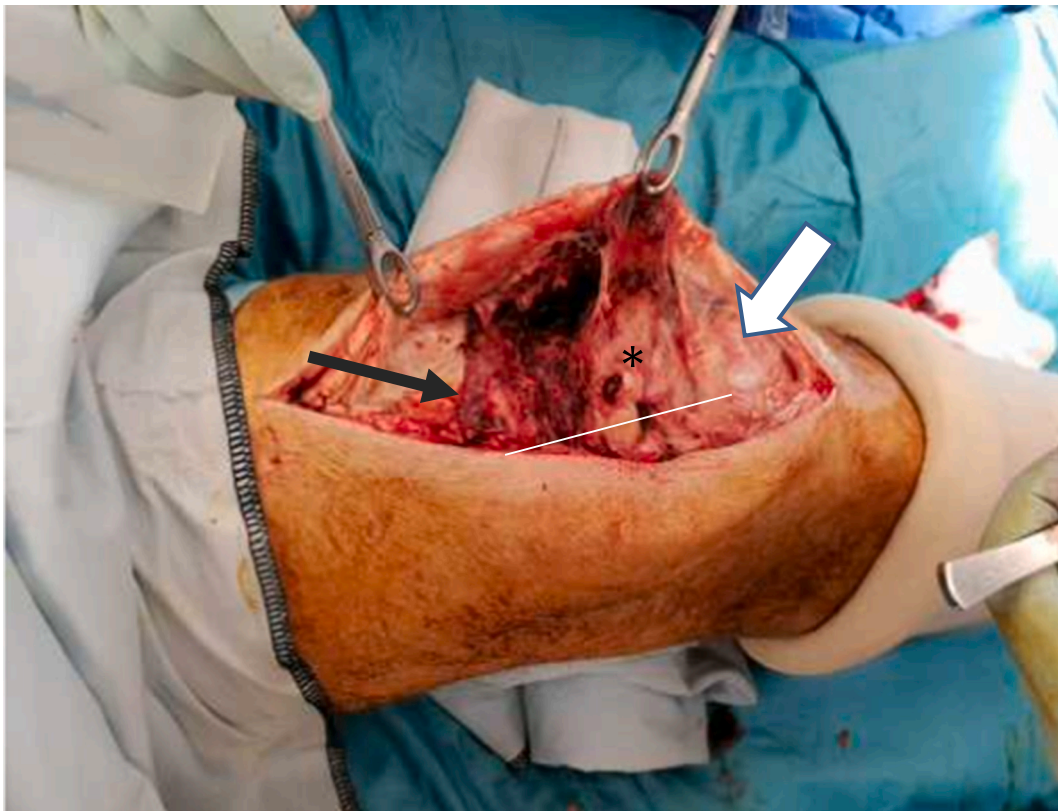


Image A. Intra-operative photographs demonstrating the defect, white arrow showing the patella and the black arrow showing the retracted tendon the distance in between is the gap (white line shows the length of the gap). Asterisks is the superior fat pad and supra patellar pouch which is uncovered by the gap.

sutures) to superior pole of patella and fibre wire sutures, with Krakow technique to the quadriceps tendon in a tension free manner [8].

In all cases we then used the LARS (ligament augmentation and reconstruction system). Tumour resection mesh was used in order to augment the tendon, which was sutured using size 2 Ethibond sutures to the tendon patellar periosteum, and quadriceps tendon, as shown in [Image C](#).

The deep fascia and sub cutaneous tissues were then closed in layers and clips were used to close the skin.

Post-operative management

All patients were fully weight bearing, braced in full extension with a Richard Splint and commenced isometric strengthening in the brace to allow for wound healing. At 4 weeks post-operatively, once the wound was healed and fibrous ingrowth of the band has begun in the Richard splint was removed. Then the patient received 6 weeks targeted physiotherapy and weekly graduated increase in knee bending from thirty, sixty, ninety, one hundred and twenty and full range of motion in a range of motion knee brace (I-ROM, Donjoy TM).

Results

All 5 patients were able to complete 6 weeks of targeted physiotherapy, following which 4 of the 6 repairs achieved a full range of movement ([Image D](#)). Bilateral repair did not impede the ability to participate in a physiotherapy regime and achieve a full range of movement. Of the patients who didn't achieve a full range of movement, one patient had achieved a full range of flexion, but a 10-degree extensor lag, with the other patient able to achieve a range of flexion of 5–110 degrees. All patient had MRC grade 5 strength. However neither of these represented a functional deficit reported by the patient. The only complication was a superficial wound infection, which was successfully treated with a short course of oral antibiotics. All patients were followed up for two years, one patient passed away from metastatic gastric carcinoma a year after the repair. There were no cases of late extension lag or rupture however one patient sustained contralateral quadriceps rupture which was treated successfully early with primary repair.

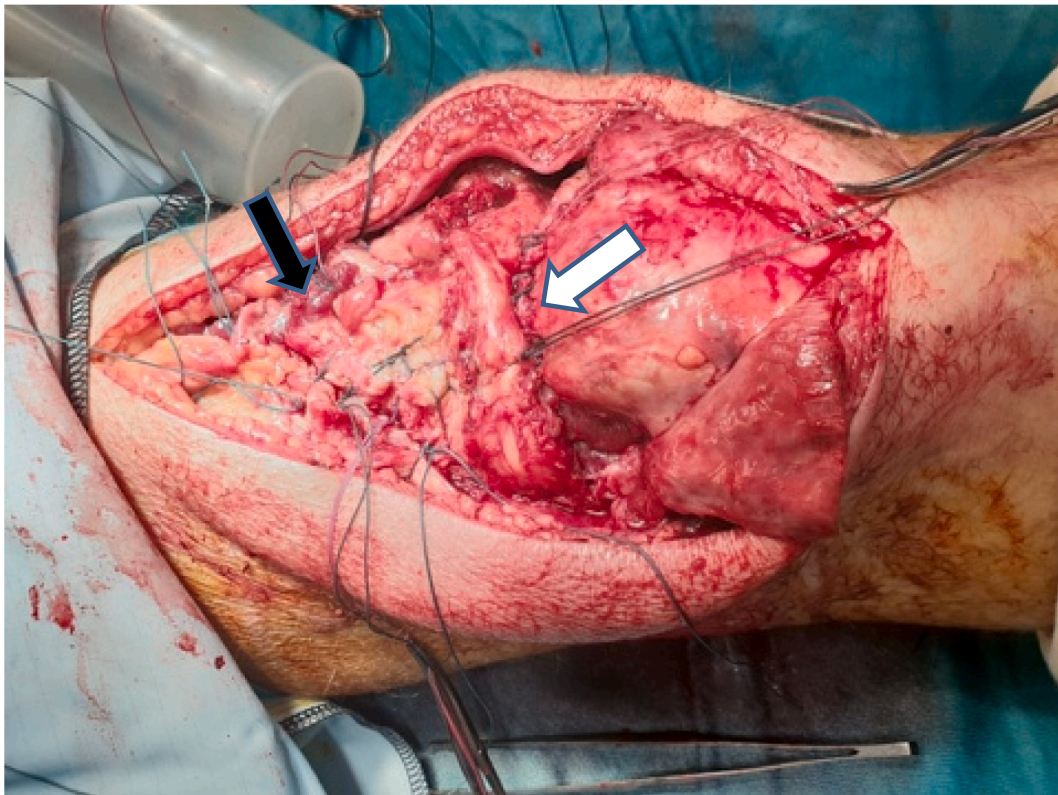


Image B. The use of the V—Y plasty technique (Black arrow) resulting in abolishing of the gap (White arrow) and fixation quadriceps tendon advancement to the patella using suture anchors to the patella and Krakow suture technique to the quadriceps tendon.

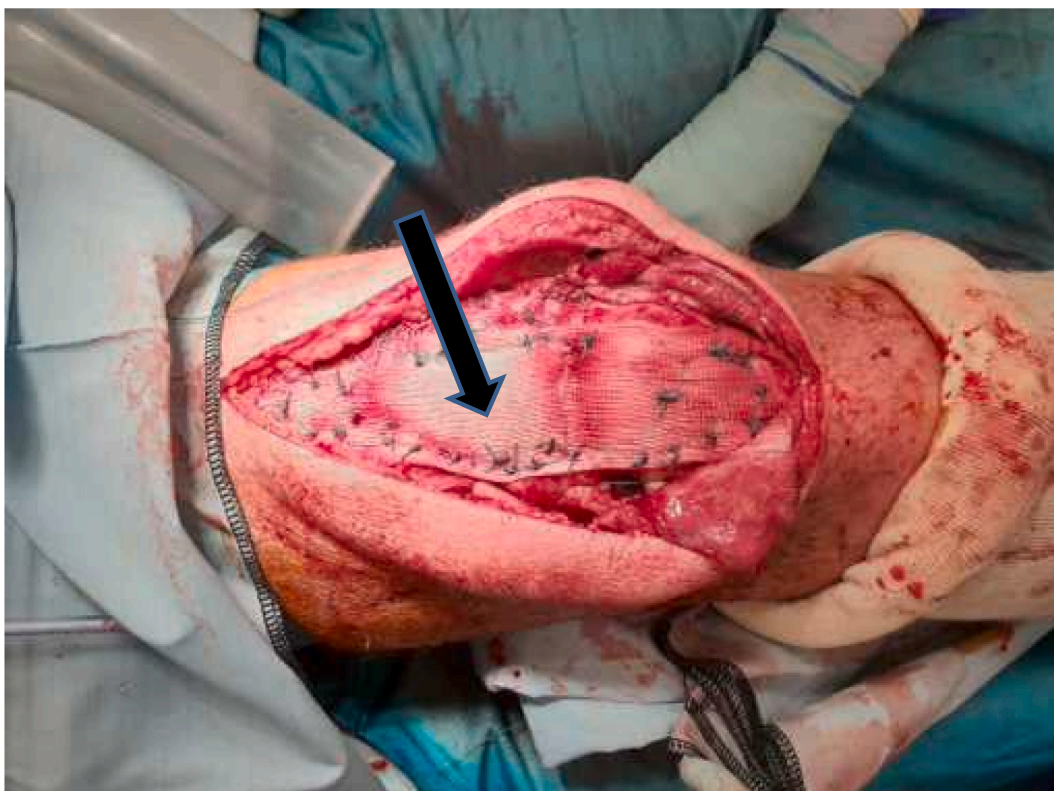

Image C. LARS augmentation (Black arrow). The ligament has been sutured over the repair including V–Y plasty and retinacula and patellar periosteum of the patella and retinacula, down to proximal ligamentum patella.

Discussion

We present a series of patient with chronic quadriceps rupture who have presented to our unit and were successfully treated with reconstruction using tumour mesh, in spite of a significant delay in their repair, resulting in return to normal daily activity of living, work and recreational activity.

Chronic extensor mechanism quadriceps tendon rupture is a devastating injury which is usually caused by failure to diagnose the rupture either due to misdiagnosis, progression of incomplete to complete rupture or seeking delayed medical help [3,5,9–12]. Chronic rupture will result in enlargement gap due to muscle contraction and muscle body is scarred in this position and the gap becomes irreducible (Fig. A). Coupled with this the quadriceps muscle atrophies resulting in weak quadriceps even after repair and inability to achieve the full range of motion has resulted in arthrofibrosis and residual stiffness [3,5,9–12]. Historically, a successful reconstruction historically has involved advancement techniques or insertion of auto or allograft to bridge the gap biologically with varied result [3,5,9–12].

Successful attempts at reconstruction of chronic quadriceps rupture after total knee replacement or tumour using tumour or hernia mesh has been reported [13–15]. The theory behind it being that the tumour band acts as an internal dynamic splinting, therefore reducing the amount of extension lag that results from tendon lengthening while tendon remodelling occurs, and so allowing early rehabilitation [13–15]. This technique has resulted in significant reduction of residual extension lag caused by a scarred down quadriceps muscle, and prevents the delayed rehabilitation that often impairs quadriceps strength [13–15].

We applied this technique to primary chronic ruptures of the quadriceps tendon in native knees [9,12,16]. In this series, where the tendon gap was universally more than 10 cm in 90 degrees of flexion and 5 cm in hyperextension (Fig. A and Table 1), we reversed the consequences of neglected injury, by reducing the tendon gap with Codivilla V–Y advancement (Fig. B).

By applying a tumour band as an internal splint (Fig. C), this allowed us to start quadriceps drill as early as 2 to 3 weeks post-operatively, with resumption of graduated knee flexion at six weeks (Fig. D).

This description is important as use of tumour band, in our series we do not use it for filling of the gap formed by tendon shortening. The shortening in our series, due to a scarred and retracted tendon is corrected using rectoplasty and advancement, bringing the muscle to correct length and reducing the gap [3,5,9–12]. The function of the mesh is purely for splintage, to allow early rehabilitation without risking rupture of repair [13–15]. Tendon augmentation with allograft or autograft has been reported, resulting in good outcome [21,22]. We prefer LARS TM tumour band, as unlike biological materials, which undergo remodelling and typically show a dip in strength as the graft undergoes creeping substitution, resulting in susceptibility in lengthening at six weeks to six months



Image D. Range of motion of the knee at 6 weeks please note full extension and flexion.

Table 1

Patient demographics cause of injury and outcomes following 6 weeks of targeted physiotherapy. * denotes the defect when the knee is in full extension based on imaging at delayed diagnosis.

Patient	Age	Delay in presentation	Defect size*	Side	Comorbidities	Cause of injury	Complications	Range of movement
1	52	8 weeks	4.5 cm	Right	None	Fall	None	5–110 degrees
2	68	6 months	5 cm	Left	Rheumatoid arthritis with immune-suppression	Fall while mobilising from Zimmer frame	Superficial Wound Infection	10 degree extension lag, full flexion
3	50	6 weeks	4.5 cm	Right	Steroid abuse	Quads curls, Weight training	None	Full
4	37	4 months	>5 cm	Bilateral	Renal failure	Fall from height	None	Full
5	62	3 months	5 cm	Right	Diabetic	Fall	None	Full

[2,5,6,9–16,21,22]. The synthetic nature of LARS ligament mesh may risk foreign body reaction and infection [15]. However, in spite of majority of patients suffering from co-morbidities that are significant risk factors for delayed healing such as diabetes, immunosuppression, diabetes, steroid use and smoking, only one patient developed superficial wound infection, necessitating 2 weeks of antibiotic therapy.

The use of autologous tendon repairs is said to be a potential alternative to allograft [21,22], particularly those patients with other co-morbidities by reducing the need for a donor site, and therefore the associated morbidity. A previous case series of five patients used carbon fibre for repair of ruptures to both patella and quadriceps tendons and presented promising results [6].

There are few reports on the surgical management of delayed presentation of quadriceps tendon repair, with various techniques used including tendon lengthening and repair [11], the Scuderi technique [23], dacron vascular grafts [24], carbon fibre grafts [6] Pulvertaft weave [9] and medial transposition of vastus lateralis [25], however as yet there is no consensus on the best method of repair for this group patients.

The LARS ligament is a well-established autograft in the repair of cruciate and collateral knee reconstruction [17–20], with well documented advantages of avoiding donor site morbidity, early mobilisation, quicker rehabilitation, without any reports of tissue intolerance or fibroblast ingrowth around artificial ligament bundles [21], as well as allowing for the potential to repeat the reconstruction if the graft were to fail. LARS tumour band use has been described for successful intramuscular rectus femoris repair with

significant weakness [7].

Given these benefits, we used the LARS ligament for the reconstruction of neglected quadriceps rupture and show excellent results, with most patients achieving a full range of movement by 6 weeks post operatively. The technique is simple and reproducible, using already available artificial ligaments, showing good results in a traditionally difficult to treat cohort of patients.

Limitation to this case series and technique is threefold:

- 1- Need for augmentation: Tendon advancement has been shown to be successful in similar patient, without a need for augmentation, so the question will arise is augmentation necessary [3,5,9–12]. To counter this argument, we have shown repeatable technique with good results in challenging cohort with significant comorbidities, with the use of mesh augmentation to allow dynamic splintage of repair - facilitating early rehabilitation [6,13–15]. Also, our cohort has consistently better knee flexion compared to the previous series. We hypothesis this is due to earlier post-operative rehabilitation because of the security that is afforded by splinting by the LARS tumour band [3,5,9,11].
- 2- Risk of infection: We did not see a significant infection problem in our series. However, a cohort case series reported a significant rate of infection in mesh augmentations for patients with total knee replacement [15]. Therefore we cannot advocate use of our technique in this patient group.
- 3- This is a small case series and larger series are needed to validate this technique

Conclusions

Various previous techniques have been used to treat patients with neglected or delayed presentation of quadriceps tendon ruptures, however, there remains no widespread consensus on the best method of treatment for these patients. By combining previous techniques and with use of the LARS ligament for tendon augmentation, our study shows neglected QTRs can be safely and reproducibly treated with V–Y plasty and LARS augmentation to achieve good functional results for the patients.

CRedit authorship contribution statement

All the surgical procedures were performed by the senior surgeons AM and KV, data collection including clinical & functional parameters in the pre-operative and post-operative period was done by KV. The study was designed by AM. Drafting of the manuscript and data analysis was done by RM. All authors read and approved the manuscript.

Declaration of competing interest

Patients were consented as per local policy pre-operatively. Ethical approval was not required.
The authors declare they have no competing interests.
No external funding was required.

Acknowledgements

Nil.

References

- [1] J.W. Miles, W.A. Grana, D. Egle, et al., The effect of anabolic steroids on the biomechanical and histological properties of rat tendon, *J. Bone Joint Surg. Am.* 74A (1992) 411–422.
- [2] C.W. Siwek, J.P. Rao, Ruptures of the extensor mechanism of the knee joint, *J. Bone Joint Surg. Am.* 63 (1981) 932–937.
- [3] R.H. Ramsey, G.E. Muller, Quadriceps tendon rupture, a diagnostic trap, *Clin Orthop* 70 (1970) 161–164.
- [4] P.E. Greis, A. Lahav, M.C. Holmstrom, Surgical treatment options for patella tendon rupture, part II: chronic, *Orthopedics* 28 (8) (2005) 765–769.
- [5] H. Kelikian, E. Riashi, J. Glisson, Restoration of quadriceps function in neglected tear of the patellar tendon, *J Surg Gynecol Obstetr* 104 (1957) 200–204.
- [6] P.D. Evans, G.A. Pritchard, D.H.R. Jenkins, Carbon fibre used in the late reconstruction of rupture of the extensor mechanism of the knee, *Injury* 18 (1987) 57–60.
- [7] Clare Taylor, Rathan Yarlagadda, Jonathan Keenan, Repair of rectus femoris rupture with LARS ligament, *BMJ Case Rep.* 2012 (2012) bcr0620114359.
- [8] K.A. Krackow, The Krackow suture: how, when, and why, *Orthopedics* 31 (9) (2008 Sep) 931–933.
- [9] J.L. Rocha de Faria, M. Barroso de Matos, H.A. de Araújo Barros Cobra, N. Cavanellas, E. Branco de Sousa, J.M. Barretto, J.M. Guimarães, Surgical treatment of chronic rupture of the quadriceps using a modified pulvertaft weave technique, *Arthroscopy Techniques* 8 (10) (2019) 1163–1169. October.
- [10] C. Scuderi, Rupture of the quadriceps tendon: study of twenty tendon ruptures, *Am. J. Surg.* 95 (1958) 626–634.
- [11] B.M. Katzman, S. Silberberg, D.A. Caligiuri, D.M. Klein, P. DiPaolo, Delayed repair of quadriceps tendon, *Orthopedics.* 20 (1997) 553–554.
- [12] C.A.J. Pocock, S.P. Trikha, J.S.P. Bell, Delayed reconstruction of a quadriceps tendon, *Clin. Orthop. Relat. Res.* 466 (2008) 221–224.
- [13] C. Matthew, Morrey, Jonathan D Barlow, Matthew P Abdel, Arlen D Hanssen Synthetic Mesh Augmentation of Acute and Subacute Quadriceps Tendon Repair *Orthopedics.* 39 (1) (Jan-Feb 2016), 9-1.
- [14] Matthew P. Abdel, Christopher G. Salib, Kristin C. Mara, Mark W. Pagnano, Kevin I. Perry, Arlen D. Hanssen, Extensor Mechanism reconstruction with use of marlex mesh: a series study of 77 total knee arthroplasties, *J. Bone Joint Surg. Am.* 100 (15) (2018 Aug 1) 1309–1318.
- [15] R. Scott, NodzoSridhar R. Rachala, Polypropylene mesh augmentation for complete quadriceps rupture after total knee arthroplasty, *Knee, The* 23 (1) (2016) 177–180, 01-01.
- [16] P. Leopardi, Vico Gd, D. Rosa, F. Cigala, N. Maffulli, Reconstruction of a chronic quadriceps tendon tear in a body builder, *Knee Surg Sports Traumatol Arthrosc* 14 (10) (2006 Oct) 1007–1011.

- [17] P. Lavoie, J. Fletcher, N. Duval, Patient satisfaction needs as related to knee stability and objective findings after ACL reconstruction using the LARS artificial ligament, *Knee* 7 (3) (2000) 157–163.
- [18] T. Nau, P. Lavoie, N. Duval, A new generation of artificial ligaments in reconstruction of the anterior cruciate ligament. Two-year follow-up of a randomised trial, *J Bone Joint Surg Br* 84 (3) (2002) 356–360.
- [19] S.A. Ibrahim, F.H. Ahmad, M. Salah, A.R. Al Misfer, S.A. Ghaffer, S. Khirat, Surgical management of traumatic knee dislocation, *Arthroscopy* 24 (2) (2008) 178–187.
- [20] K. Trieb, H. Blahovec, G. Brand, M. Sabeti, M. Dominkus, R. Kotz, In vivo and in vitro cellular ingrowth into a new generation of artificial ligaments, *Eur. Surg. Res.* 36 (3) (2004) 148–151.
- [21] M.L. Ecker, P.A. Lotke, R.M. Glazer, Late reconstruction of the patellar tendon, *J. Bone Joint Surg. Am.* 81A (1979) 884–886.
- [22] N. Roidis, S. Varitimidis, L. Poultsides, P. Liakou, T. Karachalios, K. Malizos, A “biologic technique” for the treatment of a disruption of the extensor mechanism after revision total knee arthroplasty: a case report, *Knee Surg. Sports Traumatol. Arthrosc.* 16 (7) (2008) 661–665.
- [23] B.T. Rougraff, C.C. Reeck, J. Essenmacher, Complete quadriceps tendon ruptures, *Orthopaedics* 19 (6) (1996) 509–514.
- [24] M. Levy, Rosner M. GoldsteinJ, A method repair of quadriceps tendon or patellar ligament ruptures without cast immobilisation, *Clin Orthop* 218 (1987) 297–301.
- [25] O.O. Oni, S.H. Ahmad, The vastus lateralis, derived flap for repair of neglected rupture of the quadriceps femoris tendon, *Surg Gynaecol Obstet* 161 (1985) 385–387.