

## Exogastric stromal tumor of the stomach

Konstantinos H. Katsanos<sup>a</sup>, Georgios K. Glantzounis<sup>b</sup>,  
Michael Fatouros<sup>b</sup>, Epameinondas V. Tsianos<sup>a</sup>

Medical School, University of Ioannina, Greece

Gastric stromal tumors form a group of uncommon neoplasms originating from pluripotent mesenchymal cells. Gastrointestinal stromal tumors can be located in the upper, middle or lower third of the stomach. Many patients are asymptomatic or present with bleeding, pain, palpable mass and weight loss.

We present herein a 74-year-old female patient who complained of chronic abdominal discomfort. Gastroscopy was negative but abdominal radiology revealed a giant exogastric tumor (Fig. 1). The patient underwent laparotomy and was diagnosed with a 9x8 cm exogastric stromal tumor of the stomach. Patient is on imatinib and was in excellent health on the 6-month follow up.

In patients with gastric stromal tumors, magnetic resonance imaging provides an excellent means of evaluating the site and extension of the neoplasm and enables surgical planning. The neoplasm usually arises from the wall of the gastric fundus and appears well circumscribed and sharply demarcated from the adjacent structures [1]. Adenocarcinomas and smooth muscle tumors should be excluded [2]. Open laparotomy or laparoscopic resection are both safe and feasible with good results in both surgical and oncologic outcomes [3].

Concerning prognostic factors the following are related to poor survival: mitotic count >5/50 HPF, severe pleomorphism, necrosis, marked cellularity, presence of ulceration of overlying gastric mucosa, tumor size >5 cm and exogastric growth pattern. In clinical practice, tumors with mitotic count >5/50 HPF and size > 5 cm are strong indicators of an unfavorable prognosis [4].

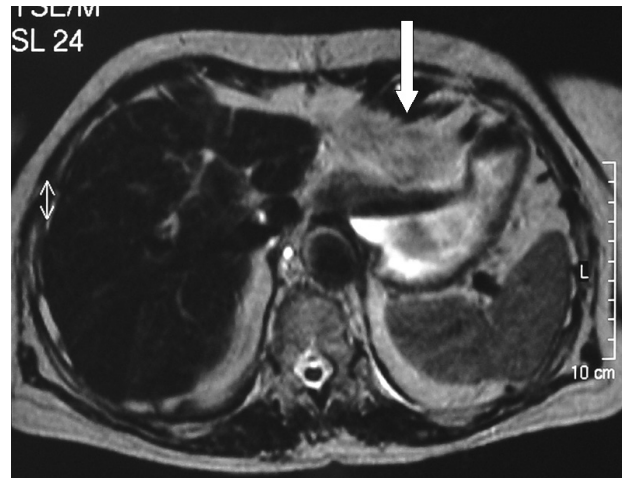


Figure 1 Exogastric 9x8 cm stromal tumor of the stomach

### References

1. Pinto A, Grassi R, Scialpi M, Romano L. MR findings in a case of exogastric stromal tumor of the stomach. *JBR-BTR* 2004;**87**:67-69.
2. Davis GB, Blanchard DK, Hatch GF 3rd, et al. Tumors of the stomach. *World J Surg* 2000;**24**:412-420.
3. Sasaki A, Koeda K, Obuchi T, et al. Tailored laparoscopic resection for suspected gastric gastrointestinal stromal tumors. *Surgery* 2010;**147**:516-520.
4. Kwon SJ, Korean Gastric Cancer Study Group. Surgery and prognostic factors for gastric stromal tumor. *World J Surg* 2001;**25**:290-295.

<sup>a</sup>1<sup>st</sup> Division of Internal Medicine & Hepato-Gastroenterology Unit (Konstantinos H. Katsanos, Epameinondas V. Tsianos); <sup>b</sup> Division of General Surgery (Georgios K. Glantzounis, Michael Fatouros), Medical School, University of Ioannina, Greece

Conflict of Interest: None

Correspondence to: Prof. Epameinondas V. Tsianos, MD, PhD, FEBG, AGAF, Professor of Internal Medicine, 1st Division of Internal Medicine & Hepato-Gastroenterology Unit, Department of Medicine, Medical School, University of Ioannina, 451 10 Ioannina, Greece, Tel: 0030-26510-07501, Fax: 00-30-26510-07016, e-mail: etsianos@uoi.gr

Received 21 September 2011; accepted 9 October 2011