



Cavernous sinus adenoid cystic carcinoma mimicking meningioma: a case study and literature analysis

Hongjing Zhang^{1,2^}, Ting Fang², Shuang Li¹, Xiaorui Su¹, Lang Wang², Jinyan Zhang³, Xibiao Yang¹, Jing Zhang⁴, Qiang Yue¹

¹Department of Radiology, West China Hospital of Sichuan University, Chengdu, China; ²Department of Radiology, West China School of Public Health and West China Fourth Hospital, Sichuan University, Chengdu, China; ³Department of Pathology, West China Hospital of Sichuan University, Chengdu, China; ⁴Institute of Research and Clinical Innovations, Neusoft Medical Systems Co., Ltd, Shanghai, China

Correspondence to: Qiang Yue, MD, PhD. Department of Radiology, West China Hospital of Sichuan University, No. 37 Guoxue Alley, Chengdu 610041, China. Email: scu_yq@163.com.

Submitted Jun 29, 2023. Accepted for publication Nov 02, 2023. Published online Dec 12, 2023.

doi: 10.21037/qims-23-938

View this article at: <https://dx.doi.org/10.21037/qims-23-938>

Introduction

Adenoid cystic carcinoma (ACC) is a rare malignant epithelial tumor of the oral and maxillofacial regions. It was first described by Bill Ross in 1856 and was initially referred to as a cylindrical tumor (1). ACC accounts for approximately 1% of all head and neck cancers and 10% of all salivary gland tumors (2). ACC of the head and neck region is often featured by a deceptively indolent manifestation followed by perineural invasion (PNI), local relapse, and metastatic spread. This disease is a challenging clinical entity to manage due to its particular clinical and pathologic peculiarities and the shortage of prospective data guiding ideal therapeutic method (3).

In this report, we present a rare case of ACC in the cavernous sinus, which was initially suspected as a meningioma but was later found to have the MYB proto-oncogene, transcription factor (MYB) translocation and Ki-67 hyperexpression. The tumor was significantly reduced in size after three months of preoperative gamma knife treatment but recurred rapidly three months later. Postoperative high-dose radiotherapy also did not effectively control the progression of the disease. We provide this case report to aid in the differential diagnosis of cavernous sinus tumors and to encourage consideration of the treatment options for ACC.

Case description

A 48-year-old woman visited West China Hospital of Sichuan University with facial deformity and pain for over two years. Over time, she developed ptosis and ipsilateral facial muscle atrophy. An outpatient magnetic resonance imaging (MRI) examination showed an isointense lesion on T1-weighted and T2-weighted imaging and hyperintense mass on enhanced T1-weighted imaging in the cavernous sinus (*Figure 1A-1D*). The lesion enveloped the internal carotid artery and locally extended to the parapharyngeal space via the foramen ovale. The MRI imaging presentation was similar to that of an extracranial extension of a skull base meningioma, thus a meningioma was highly suspected.

It is technically challenging to remove the tumor completely in the cavernous sinus area. Due to the lesion's specific location, the patient underwent gamma knife treatment before surgery to inhibit its growth. The radiation therapeutic dose for the right of sella turcica included 24 Gy at the center and 12 Gy at the periphery, with an irradiation time of 3,295 seconds. After treatment, the mass significantly reduced in size (*Figure 1E-1H*), and the patient's clinical symptoms improved over the next three months. However, three months after treatment, the symptoms gradually worsened. The follow-up MRI images showed rapid growth of the lesion, leading to recurrence.

[^] ORCID: 0009-0004-0324-8009.

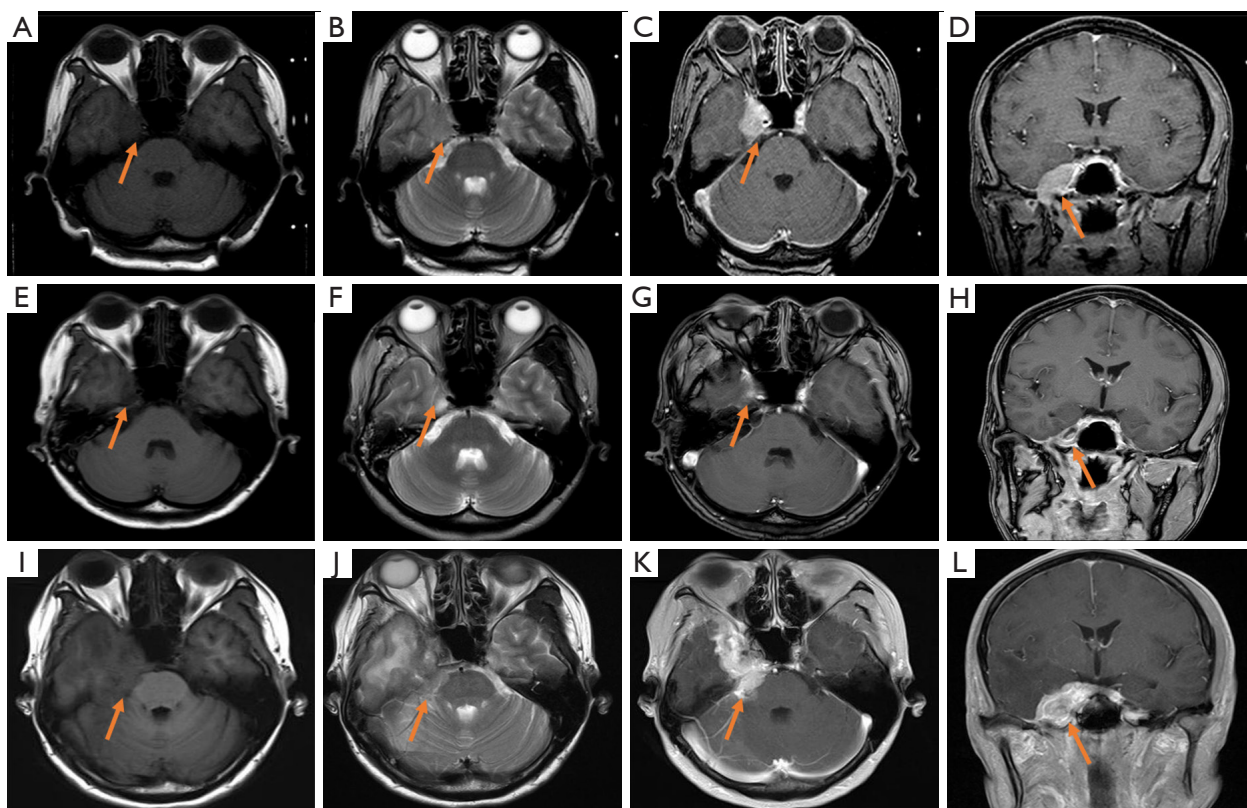


Figure 1 MRI findings of the lesion. (A-D) MR images showed a lesion in the cavernous sinus enveloped the internal carotid artery and locally extended to the parapharyngeal space via the foramen ovale before gamma knife treatment. (E-H) MR images showed the lesion was significantly reduced after gamma knife treatment. (I-L) MR images showed a recurrent lesion before craniotomy. (A,E,I) MRI showed an isointense lesion on T1-weighted imaging (arrows). (B,F,J) MRI showed an isointense lesion on T2-weighted imaging (arrows). (C,G,K) MRI showed a hyperintense mass on axial enhanced T1-weighted imaging (arrows). (D,H,L) MRI showed a hyperintense mass on coronal enhanced T1-weighted imaging (arrows). MRI, magnetic resonance imaging.

The patient started experiencing dizziness, vomiting, blindness in the right eye, and a leftward tilt in the corner of her mouth, then she went to hospital. Upon admission, an MRI examination showed a very large mass in the right cavernous sinus area that had invaded the meninges, skull base, temporalis, and tentorium cerebelli and had an indistinct boundary from brain tissue (*Figure 1I-1L*). On neurological examination, the patient exhibited a loss of direct and indirect light reflexes, complete blindness in the right eye, right upper eyelid ptosis, and facial palsy. The patient's medical history included a 20-year history of hepatitis B, but the laboratory blood test results were negative.

Subsequently, the patient underwent a craniotomy. Intraoperative findings showed that the tumor severely compressed the peripheral cranial nerves, involved the

base of the skull, meninges, and tentorium cerebelli, and adhered closely to brain tissues, making complete removal impossible. Microscopic examination revealed predominantly cribriform and solid tumor cell pattern types, with a few sporadic tubular-type cells (*Figure 2A-2C*). The immunohistochemical staining results were as follows: glandular epithelial cells: EMA (+), PCK (+), CK7 (+), PR (-), Ki-67 (+, 60%): (*Figure 2D-2H*); myoepithelial/basal cells: SMA (+), SOX10 (+), CK5/6 (+) (*Figure 2I-2K*); and positivity for MYB translocation by molecular pathology analysis using fluorescence in situ hybridization (FISH) (*Figure 2L*). Histopathology and immunohistochemistry confirmed that the patient had ACC. After surgery, because of the residual lesion, the patient received intensity-modulated radiation therapy (IMRT) 27 times, with total dose of 54 Gy.

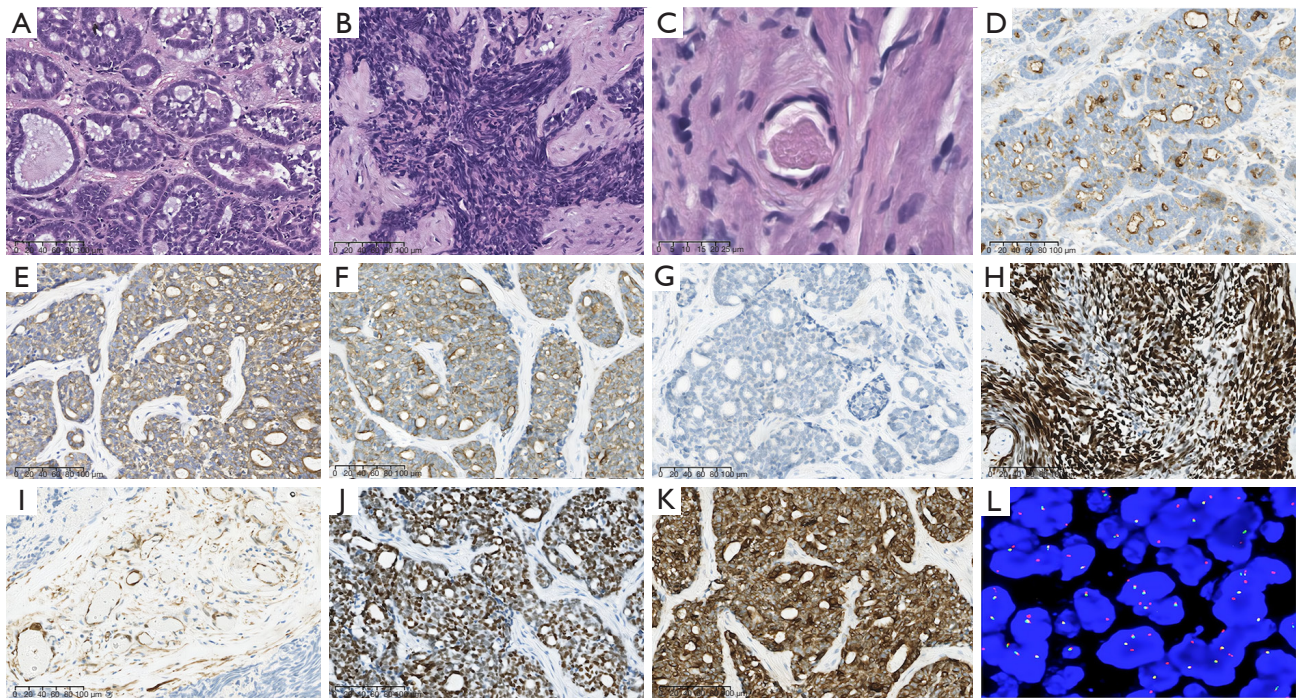


Figure 2 Histopathology (hematoxylin and eosin staining), immunohistochemical staining, and *MYB* gene detection were performed in this case of ACC of the cavernous sinus. (A) Cribriform type (20× magnification). (B) Solid type (20× magnification). (C) Tubular type (80× magnification). (D) Glandular epithelial cells positive for EMA. (E) Glandular epithelial cells positive for PCK. (F) Glandular epithelial cells positive for CK7. (G) PR was negative. (H) Rate of Ki-67 positivity of approximately 60%. (I) Myoepithelial cells positive for SMA. (J) SOX10 was positive. (K) Basal cells positive for CK5/6. (L) Molecular pathological analysis by fluorescence *in situ* hybridization revealed that the tumor was positive for *MYB* translocation. ACC, adenoid cystic carcinoma; EMA, epithelial membrane antigen; PCK, pan-cytokeratin; PR, progesterone receptor; SMA, smooth muscle actin.

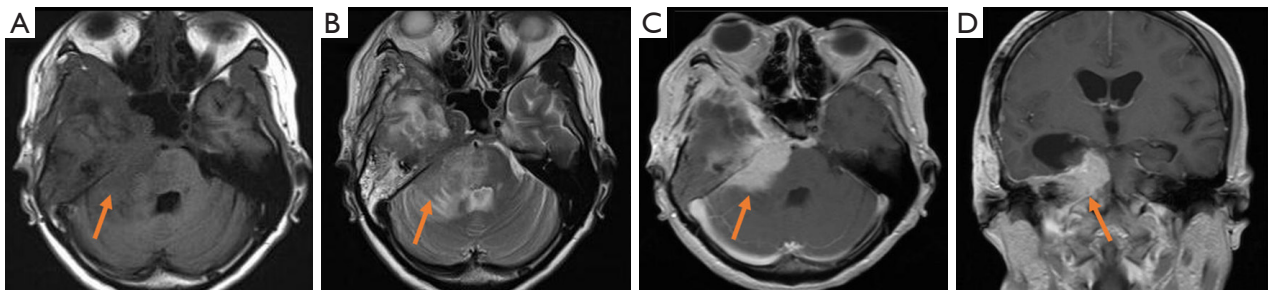


Figure 3 MRI findings revealed that the lesion had partially decreased in size, the compression on the cerebellum and brainstem had increased after surgery and radiotherapy. (A) MRI showed an isointense lesion on T1-weighted imaging (arrow). (B) MRI showed an isointense lesion on T2-weighted imaging (arrow). (C) MRI showed a hyperintense mass on axial enhanced T1-weighted imaging (arrow). (D) MRI showed a hyperintense mass on coronal enhanced T1-weighted imaging (arrow). MRI, magnetic resonance imaging.

Two months after surgery and radiotherapy, a follow-up MRI examination revealed that the previous intracranial lesion had partially decreased in size; however, the compression on the cerebellum and brainstem had increased,

indicating disease progression (Figure 3A-3D). The treatment process for this patient is illustrated in Figure 4. Unfortunately, the patient passed away 9 months after postoperative radiotherapy.

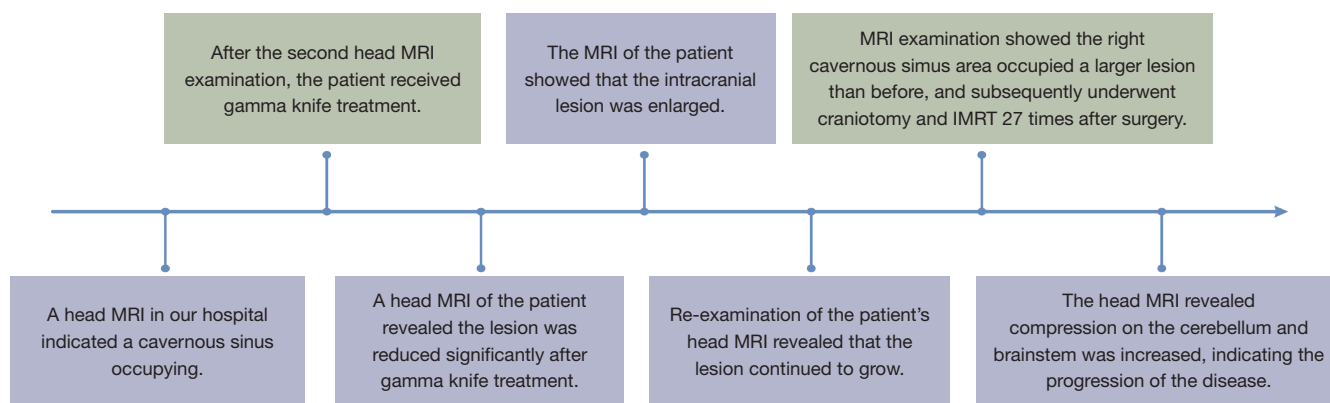


Figure 4 Timeline of the patient's treatment process. MRI, magnetic resonance imaging; IMRT, intensity-modulated radiation therapy.

All procedures performed in this study were in accordance with the ethical standards of the institutional and/or national research committee(s) and with the Helsinki Declaration (as revised in 2013). Written informed consent was obtained from the patient for publication of this case report and accompanying images. A copy of the written consent is available for review by the editorial office of this journal.

Review and discussion

ACC is a biphasic malignant tumor that can develop at various anatomical sites (4). ACC is the most general malignant tumor of the minor salivary glands and common to the major salivary glands, including the parotid, submandibular and sublingual glands (5). Rare sites include nasopharynx, paranasal sinuses, lacrimal glands and glandular tissue of the breast, lung, trachea, cervix, vulva and skin (6). Salivary and lacrimal ACC present high incidence of PNI and increased tendency of intracranial invasion (7). ACC of the head and neck region is characterized by slow progression, a strong tendency for nerve invasion, rare spread to the lymph nodes in the neck region, a high recurrence rate, and the potential for distant metastasis (8). Despite its slow clinical course, the prognosis remains poor in the long term.

The cavernous sinus is a common site for several types of tumors, including meningiomas, hemangiomas, and schwannomas. However, the origin of how ACC develops from the cavernous sinus region remains unknown. The probability of metastasis or PNI into the cavernous sinus remains controversial because no lesions have been detected other than that in the cavernous sinus by multiple imaging

investigations. In this case, intraoperative findings and MRI images showed that the tumor was mainly located in the cavernous sinus region which suggested that the Cavernous Sinus may be the primary source of the ACC. ACC is most common among people aged between 40 and 60 years, and no specific genetic or environmental risk factors have been identified (9). The age range of previous case reports (*Table 1*) (10-13) was between 38 and 62 years, with an average age of 50.5 years. All ACC cases reported occurred in the right cavernous sinus, and most patients presented with varying degrees of trigeminal neuralgia, some also with oculomotor nerve disorders. MRI, with or without computed tomography (CT), was the primary diagnostic modality used in identifying the lesion in all cases except one, which was identified through CT (11). In none of the cases was ACC suspected or diagnosed until the histological examination after surgery. Two patients underwent craniotomy to obtain pathological tissues (10,11), while transnasal surgery was performed in the other two cases (12,13). Follow-up information was available for only two patients; one patient experienced relapse six months after right temporal lobe craniotomy combined with stereotactic radiation surgery (SRS), and the other relapsed two years after endoscopic transnasal surgery combined with SRS. Immunohistochemical and genetic information was not provided in the previous cases. The scarcity of such cases reported in the medical literature makes this case unique due to the extensive and thorough treatment records coupled with preoperative and postoperative MRI data, which provide a comprehensive understanding of this particular type of lesion.

Similar to previous reports, in this case, the ACC of the cavernous sinus was initially suspected as meningioma

Table 1 Studies reporting on ACC involving the cavernous sinus

Case No.	Authors	Age, years	Sex	Side of ACC of the cavernous sinus	Clinical symptoms	Imaging methods	Treatment	Follow-up
1	Adachi <i>et al.</i> [2006] (10)	62	M	R	Right oculomotor, abducens, and trigeminal nerve disorders	MRI + CT	Right temporal craniotomy + SRS	The recurrent lesion was found 6 months postoperatively
2	Piepmeier <i>et al.</i> [1983] (11)	38	M	R	Complete ophthalmoplegia, facial anosmia in the trigeminal nerve region, and decreased vision	CT	Right frontotemporal craniotomy	No follow-up
3	Hayashi <i>et al.</i> [2014] (12)	42	F	R	Facial numbness, photophobia, diplopia, and eye pain	MRI	Endoscopic transnasal surgery + SRS	The tumor recurred along the trigeminal nerve in 2 years after the first SRS
4	Dzięciółowska-Baran <i>et al.</i> [2018] (13)	60	F	R	Severe trigeminal neuralgia	MRI	Transnasal partial resection + PORT	The patient survived and her tumor was reduced, but there was no long-term follow-up

ACC, adenoid cystic carcinoma; M, male; F, female; R, right; MRI, magnetic resonance imaging; CT, computed tomography; SRS, stereotactic radiation surgery; PORT, postoperative radiotherapy.

due to the similar imaging manifestations, including the tumor location, signal intensity on MRI, and enhancement patterns. However, after obtaining the pathological results, we reviewed the patient's MR images before gamma knife treatment and noted the absence of a distinct dural tail sign and a poorly defined tumor base, which may be helpful in the differentiation of ACC from meningioma.

The MYB site (*chr.6*) can undergo a translocation with the Nuclear Factor I/B (NFIB) site (*chr.9*), and the MYB-NFIB *t(6;9)(q22-23;p23-24)* translocation can induce the MYB-NFIB fusion gene, which drives the underlying pathogenesis of ACC (14). This translocation is the most common genetic alteration observed in ACC, leading to overexpression of MYB-NFIB transcripts and overactivity of MYB target genes that are associated with cell cycle control, apoptosis, cell adhesion, and angiogenesis (9). Notably, MYB-NFIB fusion is a highly specific diagnostic marker for ACC, with a mean incidence of 54% (15). Previous studies have shown that the presence of MYB translocation (16) and MYB protein expression (17) were associated with higher recurrence rates and poor clinical outcomes. Similarly, in this case, the FISH test results demonstrated the MYB gene translocation.

ACC has three distinct growth patterns, i.e., cribriform, tubular, and solid, and is composed of glandular epithelial cells and myoepithelial cells. Often, more than one pattern can be found in a single tumor. The histological

pattern of ACC correlates with the clinical behavior. The cribriform and tubular growth patterns are less erosive (18), while tumors exhibiting a solid pattern or having solid components are more likely to spread and have a poorer prognosis (19). The solid growth pattern is an independent prognostic factor associated with tumor recurrence (20). In this case, the histological growth pattern was partially solid, which may be responsible for the rapid recurrence of ACC. The Ki-67 protein exists in proliferating cells, including the cell nucleus in the G1, S, G2, and M phases of the cell cycle. Ki-67 protein levels are low in the G1 and early S phases and gradually increase to a maximum during mitosis. Consequently, the Ki-67 labeling index (LI) can be used as a valuable marker of cell proliferation (21). Multiple studies have confirmed that the Ki-67 hyperexpression is connected with the relapse of various malignancies, such as breast cancer (22), pancreatic neuroendocrine tumors (23), gallbladder cancer (24), oral tongue cancer (25), endometrial stromal sarcoma (26), and mantle cell lymphoma (27). Xia *et al.* conducted a study on 12 ACC samples and found that the Ki-67 LI in recurrent cases was higher than that in nonrecurrent cases (28). In the present case, the solid growth pattern, MYB translocation, and 60% Ki-67 LI seem to explain why the patient relapsed and progressed so quickly after therapy. Nonetheless, prospective controlled studies with larger sample sizes are necessary to verify this conclusion.

The primary goal of treating ACC is to achieve long-term survival, including cancer survival (29). The current consensus regarding treatment for ACC is to perform surgical excision followed by postoperative radiotherapy (PORT) with or without chemotherapy (30). PORT is believed to prevent local recurrence and distant metastases, as radical resection of ACC at the base of the skull is often limited by its proximity to the base of the skull and orbit, resulting in complete resection rates of only 36% to 50% (31,32). Previous data have shown that radiotherapy can help improve survival and reduce recurrence rates, highlighting the radiosensitivity of ACC (33). Postoperatively, a dose of 60 Gy is recommended for the primary tumor bed, and this can be increased to 66 Gy in the case of close or positive margins (34). If elective neural coverage is required, a dose of 50–60 Gy is recommended, with dose decrease to 50 Gy favored for volumes closest to the base of skull (35,36). In this case, the patient received preoperative gamma knife therapy and high dose radiotherapy after surgery, the tumor was not well controlled unfortunately.

There are currently only a few systemic therapies available for ACC, including cytotoxic drugs targeting vascular endothelial growth factor receptors and multitargeted tyrosine kinase inhibitors, and such drugs exhibit moderate activity (37,38). In general, clinicians prefer targeted or personalized therapies for ACC over cytotoxic chemotherapy.

Almost all patients with ACC of the salivary gland (SACC) have oncogene fusion and overexpression of *MYB* transcription factor or *MYB* homolog (*MYBL1*), which is associated with higher recurrence rates and poorer clinical outcomes (39). *MYB* has been shown to promote pulmonary metastasis in SACC, suggesting that *MYB* may be a new therapeutic target for SACC (40). However, recent systematic reviews have shown that *MYB* mutations and *MYB* protein expression have minimal or no potential prognostic value (41,42). Therefore, more studies may be required to confirm whether *MYB* can be a potential target for treating ACC. In contrast to *MYB*/*MYBL1* changes, other genetic changes in ACC are low-probability events. NOTCH pathway activation occurs in up to 20% of patients with ACC (43), and *NOTCH1* mutation (38) is found in approximately 25% of cases with recurrent or metastatic ACC. *NOTCH1/3* mutations are significantly associated with reduced relapse-free survival and overall survival (OS) after an initial diagnosis compared to the *NOTCH1/3* wild type (44). Since NOTCH pathway activation is associated with the prognosis of patients with

ACC, it may become a potential therapeutic target for ACC. Previous analyses of publicly available genomic datasets or individual institutional case series have confirmed that up to 5–10% of patients with SACC have TP53 mutations (43). Tp53-mutated SACC has a remarkably shorter median OS and a lower 10-year survival rate than TP53-wild-type ACC (45). This indicates that TP53 might be a potential therapeutic target in patients with ACC. Additionally, in one reported case, an ACC patient with a BCL-6 corepressor mutation experienced significant inhibition of his disease after combination treatment with eribulin and anlotinib (46), which provides a certain basis for the use of this combination in treating ACC and emphasizes the need to find new therapeutic targets for ACC.

ACC is a rare and complex tumor to manage, particularly when located in the cavernous sinus region. The imaging features of ACC are nonspecific, and definitive diagnosis mainly depends on the results of immunohistochemistry and genetic detection. Although surgery followed by radiotherapy is the main treatment option for ACC, it is vital to consider histological growth patterns, molecular markers, and potential genetic targets when deciding on the most suitable treatment approach. There is a need for more extensive sample sizes and prospective controlled studies to better understand the diagnosis, therapeutic options, and prognosis of patients with ACC.

Acknowledgments

We would like to thank the members of the Department of Pathology and Radiology of West China Hospital of Sichuan University and Department of Radiology, West China School of Public Health and West China Fourth Hospital, Sichuan University who contributed to this manuscript.

Funding: This study was supported by the National Natural Science Foundation of China (Grant No. 82271961), and the Sichuan Provincial Foundation of Science and Technology (Grant Nos. 2019YFS0428, 2022YFS0073).

Footnote

Conflicts of Interest: All authors have completed the ICMJE uniform disclosure form (available at <https://qims.amegroups.com/article/view/10.21037/qims-23-938/coif>). J.Z. is an employee (serves as a scientist) of the Institute of Research and Clinical Innovations, Neusoft Medical Systems Co., Ltd, Shanghai, China, during the study. The

other authors have no conflicts of interest to declare.

Ethical Statement: The authors are accountable for all aspects of the work in ensuring that questions related to the accuracy or integrity of any part of the work are appropriately investigated and resolved. All procedures performed in this study were in accordance with the ethical standards of the institutional and/or national research committee(s) and with the Helsinki Declaration (as revised in 2013). Written informed consent was obtained from the patient for publication of this case report and accompanying images. A copy of the written consent is available for review by the editorial office of this journal.

Open Access Statement: This is an Open Access article distributed in accordance with the Creative Commons Attribution-NonCommercial-NoDerivs 4.0 International License (CC BY-NC-ND 4.0), which permits the non-commercial replication and distribution of the article with the strict proviso that no changes or edits are made and the original work is properly cited (including links to both the formal publication through the relevant DOI and the license). See: <https://creativecommons.org/licenses/by-nc-nd/4.0/>.

References

- Alleyne CH, Bakay RA, Costigan D, Thomas B, Joseph GJ. Intracranial adenoid cystic carcinoma: case report and review of the literature. *Surg Neurol* 1996;45:265-71.
- Dodd RL, Slevin NJ. Salivary gland adenoid cystic carcinoma: a review of chemotherapy and molecular therapies. *Oral Oncol* 2006;42:759-69.
- Rodriguez-Russo CA, Junn JC, Yom SS, Bakst RL. Radiation Therapy for Adenoid Cystic Carcinoma of the Head and Neck. *Cancers (Basel)* 2021.
- Ferrarotto R, Mitani Y, McGrail DJ, Li K, Karpinets TV, Bell D, Frank SJ, Song X, Kupferman ME, Liu B, Lee JJ, Glisson BS, Zhang J, Aster JC, Lin SY, Futreal PA, Heymach JV, El-Naggar AK. Proteogenomic Analysis of Salivary Adenoid Cystic Carcinomas Defines Molecular Subtypes and Identifies Therapeutic Targets. *Clin Cancer Res* 2021;27:852-64.
- Bjørndal K, Krogdahl A, Therkildsen MH, Overgaard J, Johansen J, Kristensen CA, Homøe P, Sørensen CH, Andersen E, Bundgaard T, Primdahl H, Lambertsen K, Andersen LJ, Godballe C. Salivary gland carcinoma in Denmark 1990-2005: a national study of incidence, site and histology. Results of the Danish Head and Neck Cancer Group (DAHANCA). *Oral Oncol* 2011;47:677-82.
- Li N, Xu L, Zhao H, El-Naggar AK, Sturgis EM. A comparison of the demographics, clinical features, and survival of patients with adenoid cystic carcinoma of major and minor salivary glands versus less common sites within the Surveillance, Epidemiology, and End Results registry. *Cancer* 2012;118:3945-53.
- Andreasen S, Tan Q, Agander TK, Steiner P, Bjørndal K, Høgdall E, Larsen SR, Erentaite D, Olsen CH, Ulhøi BP, von Holstein SL, Wessel I, Heegaard S, Homøe P. Adenoid cystic carcinomas of the salivary gland, lacrimal gland, and breast are morphologically and genetically similar but have distinct microRNA expression profiles. *Mod Pathol* 2018;31:1211-25.
- Ellington CL, Goodman M, Kono SA, Grist W, Wadsworth T, Chen AY, Owonikoko T, Ramalingam S, Shin DM, Khuri FR, Beitler JJ, Saba NF. Adenoid cystic carcinoma of the head and neck: Incidence and survival trends based on 1973-2007 Surveillance, Epidemiology, and End Results data. *Cancer* 2012;118:4444-51.
- Nightingale J, Lum B, Ladwa R, Simpson F, Panizza B. Adenoid cystic carcinoma: a review of clinical features, treatment targets and advances in improving the immune response to monoclonal antibody therapy. *Biochim Biophys Acta Rev Cancer* 2021;1875:188523.
- Adachi K, Yoshida K, Ueda R, Kawase T. Adenoid cystic carcinoma of the cavernous region. Case report. *Neurol Med Chir (Tokyo)* 2006;46:358-60.
- Piepmeyer JM, Virapongse C, Kier EL, Kim J, Greenberg A. Intracranial adenocystic carcinoma presenting as a primary brain tumor. *Neurosurgery* 1983;12:348-52.
- Hayashi Y, Iwato M, Kita D, Miyashita K, Yoshizaki T, Hamada J. Adenoid cystic carcinoma in the cavernous sinus diagnosed with the endoscopic endonasal approach. *Turk Neurosurg* 2014;24:814-8.
- Dzięciołowska-Baran E, Gawlikowska-Sroka A. Adenoid Cystic Carcinoma of the Cavernous Sinus - Otolaryngological Sequelae of Therapy: Case Report. *Adv Exp Med Biol* 2018;1040:23-7.
- Ben Salha I, Bhide S, Mourtzoukou D, Fisher C, Thway K. Solid Variant of Adenoid Cystic Carcinoma: Difficulties in Diagnostic Recognition. *Int J Surg Pathol* 2016;24:419-24.
- Brayer KJ, Frerich CA, Kang H, Ness SA. Recurrent Fusions in MYB and MYBL1 Define a Common, Transcription Factor-Driven Oncogenic Pathway in Salivary Gland Adenoid Cystic Carcinoma. *Cancer Discov* 2016;6:176-87.
- West RB, Kong C, Clarke N, Gilks T, Lipsick JS, Cao

- H, Kwok S, Montgomery KD, Varma S, Le QT. MYB expression and translocation in adenoid cystic carcinomas and other salivary gland tumors with clinicopathologic correlation. *Am J Surg Pathol* 2011;35:92-9.
17. Mitani Y, Li J, Rao PH, Zhao YJ, Bell D, Lippman SM, Weber RS, Caulin C, El-Naggar AK. Comprehensive analysis of the MYB-NFIB gene fusion in salivary adenoid cystic carcinoma: Incidence, variability, and clinicopathologic significance. *Clin Cancer Res* 2010;16:4722-31.
 18. Jaso J, Malhotra R. Adenoid cystic carcinoma. *Arch Pathol Lab Med* 2011;135:511-5.
 19. Khan AJ, DiGiovanna MP, Ross DA, Sasaki CT, Carter D, Son YH, Haffty BG. Adenoid cystic carcinoma: a retrospective clinical review. *Int J Cancer* 2001;96:149-58.
 20. Cantù G. Adenoid cystic carcinoma. An indolent but aggressive tumour. Part A: from aetiopathogenesis to diagnosis. *Acta Otorhinolaryngol Ital* 2021;41:206-14.
 21. Urruticoechea A, Smith IE, Dowsett M. Proliferation marker Ki-67 in early breast cancer. *J Clin Oncol* 2005;23:7212-20.
 22. Pan H, Gray R, Braybrooke J, Davies C, Taylor C, McGale P, Peto R, Pritchard KI, Bergh J, Dowsett M, Hayes DF; . 20-Year Risks of Breast-Cancer Recurrence after Stopping Endocrine Therapy at 5 Years. *N Engl J Med* 2017;377:1836-46.
 23. Hamilton NA, Liu TC, Cavatiao A, Mawad K, Chen L, Strasberg SS, Linehan DC, Cao D, Hawkins WG. Ki-67 predicts disease recurrence and poor prognosis in pancreatic neuroendocrine neoplasms. *Surgery* 2012;152:107-13.
 24. Hui AM, Shi YZ, Li X, Sun L, Guido T, Takayama T, Makuuchi M. Proliferative marker Ki-67 in gallbladder carcinomas: high expression level predicts early recurrence after surgical resection. *Cancer Lett* 2002;176:191-8.
 25. Wangsa D, Ryott M, Avall-Lundqvist E, Petersson F, Elmberger G, Luo J, Ried T, Auer G, Munck-Wikland E. Ki-67 expression predicts locoregional recurrence in stage I oral tongue carcinoma. *Br J Cancer* 2008;99:1121-8.
 26. Meng Y, Quan Q, Zhang F, Liu Y, Ren S, Mu X. Prognostic Value of Ki-67 Index in Patients With Endometrial Stromal Sarcoma. *Front Med (Lausanne)* 2021;8:823505.
 27. Chihara D, Asano N, Ohmachi K, Nishikori M, Okamoto M, Sawa M, Sakai R, Okoshi Y, Tsukamoto N, Yakushijin Y, Nakamura S, Kinoshita T, Ogura M, Suzuki R. Ki-67 is a strong predictor of central nervous system relapse in patients with mantle cell lymphoma (MCL). *Ann Oncol* 2015;26:966-73.
 28. Xia RH, Zhang CY, Wang LZ, Hu YH, Sun JJ, Tian Z, Li J. Adenoid cystic carcinoma in children and young adults: A clinicopathological study of 12 cases. *Oral Dis* 2023;29:3289-97.
 29. Ishida E, Ogawa T, Rokugo M, Ishikawa T, Wakamori S, Ohkoshi A, Usubuchi H, Higashi K, Ishii R, Nakanome A, Katori Y. Management of adenoid cystic carcinoma of the head and neck: a single-institute study with over 25-year follow-up. *Head Face Med* 2020;16:14.
 30. Coca-Pelaz A, Rodrigo JP, Bradley PJ, Vander Poorten V, Triantafyllou A, Hunt JL, Strojan P, Rinaldo A, Haigentz M Jr, Takes RP, Mondin V, Teymoortash A, Thompson LD, Ferlito A. Adenoid cystic carcinoma of the head and neck--An update. *Oral Oncol* 2015;51:652-61.
 31. Dou S, Li R, He N, Zhang M, Jiang W, Ye L, Yang Y, Zhao G, Yang Y, Li J, Chen D, Zhu G. The Immune Landscape of Chinese Head and Neck Adenoid Cystic Carcinoma and Clinical Implication. *Front Immunol* 2021;12:618367.
 32. Lupinetti AD, Roberts DB, Williams MD, Kupferman ME, Rosenthal DI, Demonte F, El-Naggar A, Weber RS, Hanna EY. Sinonasal adenoid cystic carcinoma: the M. D. Anderson Cancer Center experience. *Cancer* 2007;110:2726-31.
 33. Testa D, Guerra G, Conzo G, Nunziata M, D'Errico G, Siano M, Ilardi G, Vitale M, Riccitiello F, Motta G. Glottic-Subglottic adenoid cystic carcinoma. A case report and review of the literature. *BMC Surg* 2013;13 Suppl 2:S48.
 34. Garden AS, Weber RS, Morrison WH, Ang KK, Peters LJ. The influence of positive margins and nerve invasion in adenoid cystic carcinoma of the head and neck treated with surgery and radiation. *Int J Radiat Oncol Biol Phys* 1995;32:619-26.
 35. Bakst RL, Glastonbury CM, Parvathaneni U, Katabi N, Hu KS, Yom SS. Perineural Invasion and Perineural Tumor Spread in Head and Neck Cancer. *Int J Radiat Oncol Biol Phys* 2019;103:1109-24.
 36. Amit M, Eran A, Billan S, Fridman E, Na'ara S, Charas T, Gil Z. Perineural Spread in Noncutaneous Head and Neck Cancer: New Insights into an Old Problem. *J Neurol Surg B Skull Base* 2016;77:86-95.
 37. Tchekmedyian V, Sherman EJ, Dunn L, Tran C, Baxi S, Katabi N, Antonescu CR, Ostrovnya I, Haque SS, Pfister DG, Ho AL. Phase II Study of Lenvatinib in Patients With Progressive, Recurrent or Metastatic Adenoid Cystic Carcinoma. *J Clin Oncol* 2019;37:1529-37.

38. de Sousa LG, Jovanovic K, Ferrarotto R. Metastatic Adenoid Cystic Carcinoma: Genomic Landscape and Emerging Treatments. *Curr Treat Options Oncol* 2022;23:1135-50.
39. Drier Y, Cotton MJ, Williamson KE, Gillespie SM, Ryan RJ, Kluk MJ, Carey CD, Rodig SJ, Sholl LM, Afrogheh AH, Faquin WC, Queimado L, Qi J, Wick MJ, El-Naggar AK, Bradner JE, Moskaluk CA, Aster JC, Knoechel B, Bernstein BE. An oncogenic MYB feedback loop drives alternate cell fates in adenoid cystic carcinoma. *Nat Genet* 2016;48:265-72.
40. Xu LH, Zhao F, Yang WW, Chen CW, Du ZH, Fu M, Ge XY, Li SL. MYB promotes the growth and metastasis of salivary adenoid cystic carcinoma. *Int J Oncol* 2019;54:1579-90.
41. de Almeida-Pinto YD, Costa SFDS, de Andrade BAB, Altemani A, Vargas PA, Abreu LG, Fonseca FP. t(6;9) (MYB-NFIB) in head and neck adenoid cystic carcinoma: A systematic review with meta-analysis. *Oral Dis* 2019;25:1277-82.
42. Liu X, Chen D, Lao X, Liang Y. The value of MYB as a prognostic marker for adenoid cystic carcinoma: Meta-analysis. *Head Neck* 2019;41:1517-24.
43. Ho AS, Kannan K, Roy DM, Morris LG, Ganly I, Katabi N, et al. The mutational landscape of adenoid cystic carcinoma. *Nat Genet* 2013;45:791-8.
44. Feeney L, Hapuarachi B, Adderley H, Rack S, Morgan D, Walker R, Rauch R, Herz E, Kaye J, Harrington K, Metcalf R. Clinical disease course and survival outcomes following disease recurrence in adenoid cystic carcinoma with and without NOTCH signaling pathway activation. *Oral Oncol* 2022;133:106028.
45. Adderley H, Rack S, Hapuarachi B, Feeney L, Morgan D, Hussell T, Wallace AJ, Betts , Hodgson C, Harrington K, Metcalf R. The utility of TP53 and PIK3CA mutations as prognostic biomarkers in salivary adenoid cystic carcinoma. *Oral Oncol* 2021;113:105095.
46. Zheng S, Li H, Lin Y, Xie Y, Yin Z, Ge W, Yu T. Treatment response to eribulin and anlotinib in lung metastases from rare perianal adenoid cystic carcinoma: a case report. *Anticancer Drugs* 2022;33:e548-54.

Cite this article as: Zhang H, Fang T, Li S, Su X, Wang L, Zhang J, Yang X, Zhang J, Yue Q. Cavernous sinus adenoid cystic carcinoma mimicking meningioma: a case study and literature analysis. *Quant Imaging Med Surg* 2024;14(1):1288-1296. doi: 10.21037/qims-23-938