

Case report

Fulminant group B Streptococcal necrotizing fasciitis in a patient with undiagnosed malignancy: a case report

Sophia Collis^{a,*}, Scott Hoskinson^b

^a Brown University Class of 2020, Providence, RI, United States

^b Division of Infectious Disease, Hawaii Permanente Medical Group/Kaiser Permanente Hawaii Region, Wailuku, HI, United States

ARTICLE INFO

Article history:

Received 18 September 2019

Received in revised form 5 October 2019

Accepted 6 October 2019

ABSTRACT

Group A Streptococcus is well established as the most common pathogen causing necrotizing fasciitis. In contrast, Group B Streptococcus (GBS, or *Streptococcus agalactiae*) is a rare cause of necrotizing fasciitis, particularly in adults. We present the case of a patient who developed a fulminant case of GBS necrotizing fasciitis on a backdrop of a previously undiagnosed malignancy, and review the relevant literature.

© 2019 The Author(s). Published by Elsevier Ltd. This is an open access article under the CC BY-NC-ND license (<http://creativecommons.org/licenses/by-nc-nd/4.0/>).

Case report

A 70 year old woman—a visiting tourist from Canada with no known medical problems—was brought to an emergency room on Maui with confusion and severe pain in her upper back.

The patient was a retiree without known medical problems; three days prior to admission, during a vacation on Maui, she developed pain in the region of her right scapula without antecedent trauma. She sought relief from a chiropractor and masseuse but her back pain grew constant and severe, she became confused, and her speech grew slurred; her family brought her to the emergency room for evaluation.

On presentation the patient was febrile (102.9 F), tachycardic, tachypneic, hypotensive, and disoriented. Her physical exam showed erythema, evolving subcutaneous ecchymoses, and extreme tenderness in her right upper back, shoulder area, and right upper arm.

The patient's labs were remarkable for a peripheral white blood cell count of 13.5 K/uL with 100% lymphocytes (absolute neutropenia). The patient's hemoglobin was 10.7 g/dl; her platelet count and creatinine were normal, as was her Hemoglobin A1c (5.3%).

The patient was started empirically on Vancomycin and Piperacillin-Tazobactam for a presumed soft tissue infection with sepsis, and General Surgery was consulted. A thoracic CT scan showed body wall anasarca without gas in the soft tissues or musculature of her back, as well as extensive thoracic

adenopathy concerning for possible lymphoma or metastatic malignancy.

Profound hypotension ensued, requiring intubation and pressor support; the patient was taken to the OR emergently. Intra-operatively, necrotizing fasciitis involving her deep dermis and multiple muscle groups was found, requiring extensive debridement and resection of much of the skin, adipose tissue, and fascia of her upper back (Fig. 1). Enlarged lymph nodes near her scapula were sent for pathology. Tissue Gram stain from the OR showed many gram-positive cocci in pairs and chains. Her antibiotics were changed to Ceftriaxone and high-dose Clindamycin for Streptococcal necrotizing fasciitis, and a three-day course of intravenous immunoglobulin was begun.

Floridly septic, the patient was taken back to the OR the following day for further debridement, and her extensive wounds were left open (Fig. 2); she stabilized subsequently. GCSF was started and antibiotics were continued. Tissue cultures from the OR and blood cultures from admission both grew Group B streptococcus (*Streptococcus agalactiae*) in pure culture, sensitive to Penicillin (MIC 0.12 µg per milliliter).

Lymph nodes from the patient's back showed architectural effacement by a population of small, mature lymphocytes; immunohistochemistry was consistent with chronic lymphocytic leukemia (CLL)/small lymphocytic lymphoma (Fig. 3). Flow cytometry was positive for a mature B-cell lymphoproliferative disorder.

The patient slowly recovered with intensive ICU support. She was weaned off vasopressors and extubated within a week of admission; Clindamycin was stopped after six days of treatment, and Ceftriaxone continued.

* Corresponding author.

E-mail address: sophia_collis@brown.edu (S. Collis).

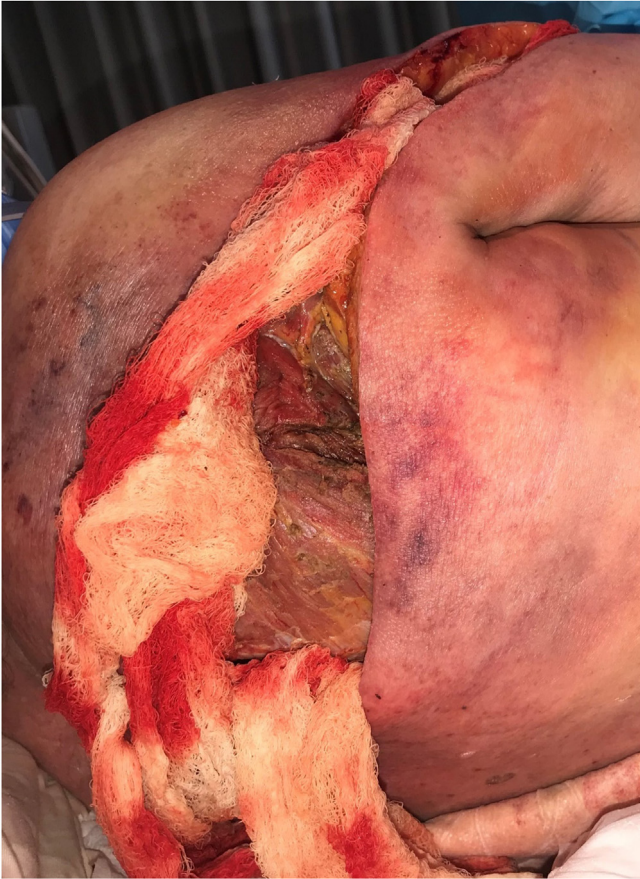

Fig. 1. Despite initial broad resection of devitalized skin, fascia, and muscle, areas of ecchymosis and tissue necrosis continued to evolve on the patient's upper back.

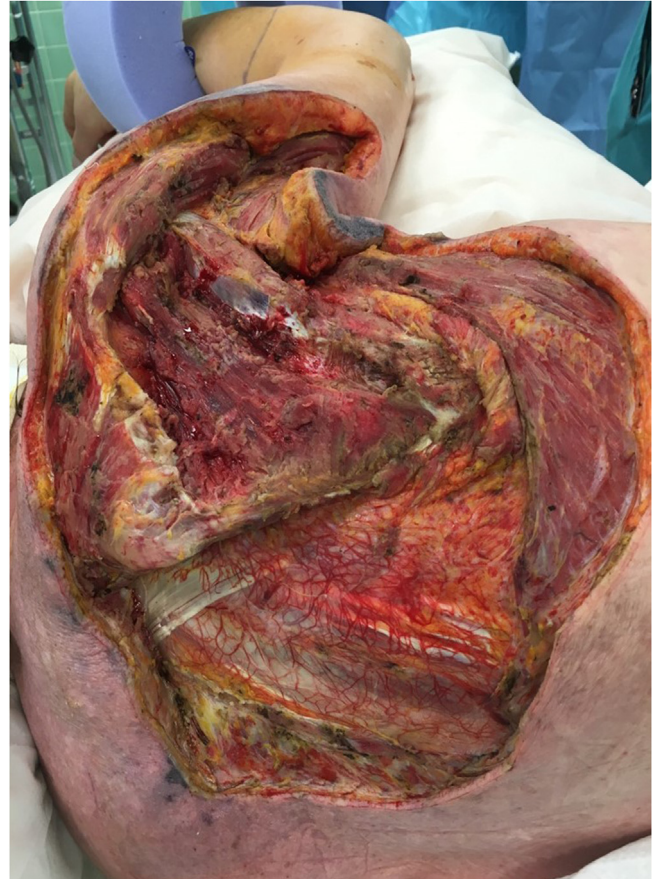

Fig. 2. Healthy wound margins were obtained after a second debridement, and the patient stabilized subsequently.

Nine days after admission she was transferred by air ambulance to a hospital in Vancouver to be nearer her family. Ceftriaxone was stopped after fourteen days of total therapy. She underwent extensive skin grafting, and is receiving treatment for her CLL/lymphocytic lymphoma currently.

Discussion

Group A *Streptococcus* is well established as the most common pathogen causing necrotizing fasciitis [1,2]. In contrast, Group B *Streptococcus* (GBS, or *Streptococcus agalactiae*) is primarily known as a major cause of perinatal sepsis and meningitis in infants and pregnant women [3,4]. Necrotizing fasciitis (NF) in non-pregnant adults due to GBS is exceedingly rare [3,5,6]. For example, during nearly two decades of active surveillance for invasive GBS infection in ten US states, only seventeen cases of NF due to GBS were noted [6].

Invasive infections due to GBS in non-pregnant adults usually strike those with a significant degree of immunocompromise:

diabetes [4,7,8] and malignancy [4,8] appear to be particularly common risk factors. In our patient's case, her previously undiagnosed CLL/small lymphocytic lymphoma was almost certainly a precipitant for her severe infection.

There is a suggestion in several studies that the incidence of invasive GBS infections appears to be increasing among non-pregnant adults, [1,3,6], including cases of necrotizing fasciitis [5,7]. The cause of this apparent increase in severe GBS infections does not appear related to temporal changes in virulence factors among GBS isolates. Whether this seeming increase in aggressive, non-perinatal GBS infections is due improved surveillance, an increase in the numbers of individuals with relative immunocompromise, or other factors is not yet clear.

Our patient's particularly aggressive form of group B streptococcal necrotizing fasciitis underscores the association between this rare infection and underlying immunocompromise. The case also highlights the need not only to treat the offending pathogen in a severe infection, but to also diagnose and treat the physiologic underpinnings that allowed the infection to take root and flourish.

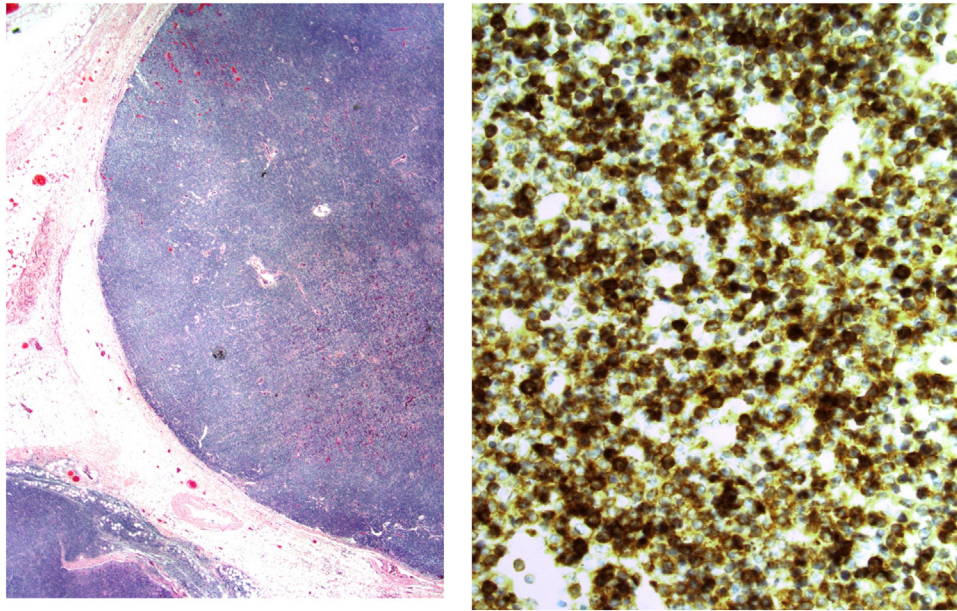


Fig. 3. Peri-scapular lymph node staining positive (brown) for CD20/CD5 and negative for CD10 and cyclin D, a profile consistent with CLL/small lymphocytic lymphoma.

Funding source

There is no funding source to report; neither author received grant funding nor commercial/institutional financing in support of authoring this paper.

Ethical approval

IRB approval was not required for this case report. Sophia Collis completed mandatory Ethics/Compliance training as required by Kaiser Permanente of all student researchers. The patient graciously provided her consent for the use of clinical images and her clinical history in support of publication/medical education.

Author statement

Dear Sir or Madam,

Our roles in creation of this manuscript and its subsequent revision after review are as follows:

Conceptualization; Ms. Collis and Dr. Hoskinson.

Data curation, Formal analysis; Funding acquisition; Not applicable (N/A)

Investigation, Methodology: Ms. Collis and Dr. Hoskinson

Project administration; Resources; Software; N/A

Supervision; Dr. Hoskinson

Writing - original draft; Ms. Collis

Writing - review & editing; Ms. Collis

Writing - revision after review; Ms. Collis.

Thank you again for considering our manuscript.

Yours,

Ms. Sophia Collis

Bachelor's Candidate and Kaiser Student Researcher,

Brown University,

Providence, Rhode Island

Dr. Scott Hoskinson, M.D.,

Division of Infectious Diseases,

Hawaii Permanente Medical Group/Kaiser Permanente,
Wailuku, Hawaii

Neither author (Ms. Sophia Collis and Dr. Scott Hoskinson) has any competing interest to declare.

Declaration of Competing Interest

Neither author (Ms. Sophia Collis and Dr. Scott Hoskinson) has any competing interest to declare.

Acknowledgements

We'd like to thank the patient for graciously allowing her story to be shared. We also owe a debt of gratitude to Dr. Stacey Honda for her help with Pathology images.

References

- [1] Wong CH, et al. Necrotizing fasciitis: clinical presentation, microbiology, and determinants of mortality. *Adv Pediatr* 2003 U.S. National Library of Medicine, Aug.
- [2] Walker Mark J, et al. Disease manifestations and pathogenic mechanisms of group a streptococcus. *Clin Microbiol Rev* 2014;27(2)264–301 PMC. Web. 15 Aug. 2018.
- [3] Fukuda Keitaro, et al. Bilateral necrotizing fasciitis of the foot associated with group B streptococcus. *Case Rep Dermatol* 2016;8(3)243–9 PMC. Web. 15 Aug. 2018.
- [4] Sendi P, et al. Invasive group B Streptococcal disease in non-pregnant adults: a review with emphasis on skin and soft-tissue infections. *Adv Pediatr* 2008 U.S. National Library of Medicine, Mar..
- [5] Skoff TH, et al. Increasing burden of invasive group B Streptococcal disease in nonpregnant adults, 1990–2007. *Adv Pediatr* 2009 U.S. National Library of Medicine, 1 July.
- [6] Wong CH, et al. Group B Streptococcus necrotizing fasciitis: an emerging disease? *Adv Pediatr* 2004 U.S. National Library of Medicine, July.
- [7] Gardam MA, et al. Group B Streptococcal necrotizing fasciitis and streptococcal toxic shock-like syndrome in adults. *Adv Pediatr* 1998 U.S. National Library of Medicine, 10 Aug..
- [8] Caínzos M, et al. Wound erysipelas following appendectomy caused by group B beta-hemolytic streptococcus (*Streptococcus agalactiae*). *Adv Pediatr* 2001 U.S. National Library of Medicine, Mar..