

## Case report

## Coronavirus disease-19 (COVID-19) associated with acute necrotising pancreatitis (ANP)

Naren K Kumaran , Biraj K Karmakar, Ormond M Taylor 

Department of General Surgery,  
Kettering General Hospital NHS  
Foundation Trust, Kettering, UK

**Correspondence to**

Dr Naren K Kumaran;  
narenkumar.kumaran@nhs.net

NKK and BKK contributed  
equally.

NKK and BKK are joint first  
authors.

Accepted 10 August 2020

**SUMMARY**

Coronavirus is a severe infectious disease (COVID-19) caused by severe acute respiratory syndrome coronavirus 2 (SARS-CoV-2) and has led to increased mortality worldwide. Multiple reports have been published citing that gastrointestinal symptoms are common in patients with COVID-19 infection. It has also been found that the ACE2 receptor of SARS-CoV-2 is expressed more in the pancreas than the lungs. Despite this, little attention has been paid to the extent and details of pancreatic injury caused by COVID-19. Lack of awareness regarding the COVID-19 status of patients presenting with pancreatitis may expose healthcare workers to SARS-CoV-2 while performing interventions to manage complications of pancreatitis such as necrosis. We report a case of COVID-19-induced acute necrotising pancreatitis in the absence of any known risk factors.

**BACKGROUND**

Coronavirus is a severe infectious disease (COVID-19) caused by severe acute respiratory syndrome coronavirus 2 (SARS-CoV-2) that leads to increased mortality worldwide. It was first identified in Wuhan, China in December 2019. It initially started as an epidemic in China and eventually, the WHO declared this medical emergency as a global pandemic.<sup>1</sup> Globally, as of, 29 June 2020, there have been 10021401 confirmed cases of COVID-19 with 499913 deaths reported to WHO.<sup>2</sup>

A meta-analysis of 3062 patients positive for COVID-19 in China showed that the most common clinical manifestations are fever, fatigue, cough and expectoration. Other common symptoms included muscle soreness, anorexia, chest tightness and shortness of breath.<sup>3</sup> It has also been reported that gastrointestinal symptoms are common in patients with COVID-19 infection.<sup>4</sup>

However, not much attention has been paid to pancreatic injury caused by COVID-19 infection. We report a case of COVID-19 who presented with severe acute necrotising pancreatitis (ANP) without any known risk factors.

**CASE PRESENTATION**

A 67-year-old Caucasian woman presented to our emergency department with a 1-day history of epigastric pain, diarrhoea and vomiting. Her significant surgical history consisted of laparotomy and a small bowel resection and anastomosis for a superior mesenteric artery (SMA) stenosis, a year back. She was on apixaban owing to her previous

thrombotic event. Her only other comorbidity was well-controlled hypertension. On assessment in the emergency department, she was haemodynamically stable with a heart rate of 112 bpm, blood pressure of 158/90 mm Hg, and temperature of 37.5°C. Due to the nationwide lockdown that was in place at the time of presentation, she had ventured out of her house only for essential trips such as and groceries and collection of medication. She was not in close contact with anyone known to have COVID-19. Her body mass index on the initial assessment was 27.5 kg/m<sup>2</sup>. The patient reported having alcohol on just one or two occasions in a year and was a non-smoker. She was not known to have gallstones or diabetes. The patient is not on any hormone replacement therapy for postmenopausal symptoms.

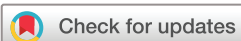**INVESTIGATIONS**

On admission, a CT scan of the abdomen and pelvis with contrast was requested for diagnostic clarity. Her CT did not show any enhancement of the pancreatic head and body, indicating necrotising pancreatitis. It revealed extensive peripancreatic fluid collection (figure 1). The arterial blood gas analysis showed a partial pressure of oxygen (PO<sub>2</sub>) of 12 kPa on room air. An ultrasound scan of the abdomen did not detect any gallstones. Her serum amylase was significantly elevated at 1483 U/L. As it is not normal practice to analyse the serum lipase level in Kettering General Hospital (KGH) National Health Service Foundation Trust, we do not have a serum lipase value in her case. Her haemoglobin A1c level done during the course of her admission turned out to be within the normal range at 40 mmol/mol. Her other laboratory investigation results are listed in table 1.

Due to the patient's worsening clinical status and her history of an SMA stenosis, a CT angiogram was done within the next 24 hours. This showed an interval progression of previously seen peripancreatic inflammatory changes and non-enhancement of most of the head and proximal body (necrotising pancreatitis)(figure 2).

**DIFFERENTIAL DIAGNOSIS**

In this case, at the point of referral from the emergency department, we suspected this to be either a case of small bowel obstruction due to adhesions, following her previous laparotomy or acute pancreatitis due to common causes like gallstones, alcohol or ischaemia as she had a previous thrombotic event. The raised serum amylase heightened our suspicion



© BMJ Publishing Group  
Limited 2020. No commercial  
re-use. See rights and  
permissions. Published by BMJ.

**To cite:** Kumaran NK,  
Karmakar BK, Taylor OM. *BMJ  
Case Rep* 2020;**13**:e237903.  
doi:10.1136/bcr-2020-  
237903

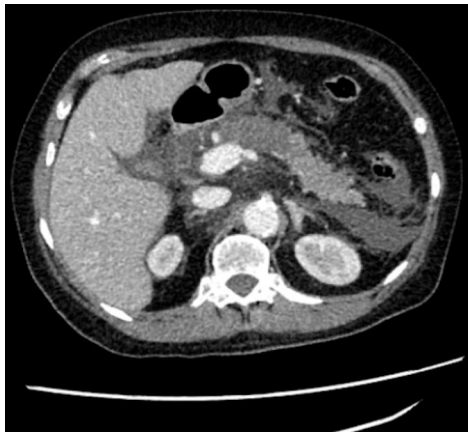

Figure 1 CT abdomen and pelvis with contrast.

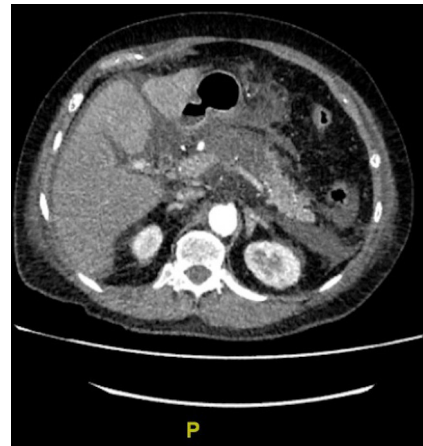

Figure 2 CT angiogram.

of pancreatitis and CT imaging confirmed a diagnosis of ANP, ruling out the above differential of small bowel obstruction.

The patient reported having a very limited alcohol intake and an ultrasound scan of the abdomen did not show any gallstones. It is acknowledged that gallstone-related acute pancreatitis can manifest without radiological evidence of gallstones if the gallstone has already passed or if the stones are too small to be detected by imaging. However, the lack of changes in the biliary tree and the normal Liver function test patterns do not suggest this as a possible explanation. This prompted us to look for other causes. Autoimmune pancreatitis was unlikely due to a normal immunoglobulin G4 (IgG4) level. The CT angiogram ruled out an ischaemic event and meanwhile, a reverse transcription PCR of her nasopharyngeal swab detected the presence of COVID-19 infection.

According to the revised Atlanta classification, the diagnosis of acute pancreatitis requires two of the following three features: (a) abdominal pain consistent with acute pancreatitis, (b) serum

lipase activity (or amylase activity) at least three times greater than the upper limit of normal and (c) characteristic findings of acute pancreatitis on contrast-enhanced CT and, less commonly, MRI or transabdominal ultrasonography.<sup>5</sup>

Thus, the clinical presentation of acute abdominal pain in the epigastric region, associated with an increased serum amylase level and CT imaging that demonstrated non-enhancement of the pancreatic parenchyma led us to our diagnosis of ANP.

### TREATMENT

Following the results of the CT, fluid resuscitation was started immediately for a confirmed diagnosis of ANP. The patient was admitted in the acute surgical unit and was being managed conservatively with intravenous fluids and intravenous antibiotics.

The patient had to be moved to intensive care unit (ICU) as her vital signs deteriorated, particularly her respiratory rate which was high at 26 per minute. She had a new-onset oxygen requirement of 2 L to maintain a saturation of 96% (figure 3).

In ICU she was on an array of antibiotics including meropenem, metronidazole and clindamycin at various stages after

Table 1 Laboratory investigation results	
White cell count	18.1×10 <sup>9</sup> /L
Platelet	502×10 <sup>9</sup> /L
C-reactive protein	158 mg/L
Lymphocytes	0.4×10 <sup>9</sup> /L
Amylase	1483 U/L
Creatinine	76 µmol/L
Urea	7.4 mmol/L
Estimated glomerular filtration rate	70.0 mL/min
Lactate	3.70 mmol/L
Procalcitonin	1.22 µg/L
Triglycerides	3.5 mmol/L
Calcium	2.24 mmol/L
IgG4	0.66
Bilirubin	7 mg/dL
Alkaline phosphatase	46 mg/dL
Alanine transaminase	22 mg/dL
Lactate dehydrogenase	213 U/L
SARS-CoV-2	Detected by reverse transcription PCR of nasopharyngeal swab at KGH Laboratory
Hepatitis B surface antigen	Negative
Hepatitis C antibody	Negative
Hepatitis A IgM	Negative
HbA1c (glycated haemoglobin)	40 mmol/mol

IgG4, immunoglobulin G4; IgM, immunoglobulin M; KGH, Kettering General Hospital.

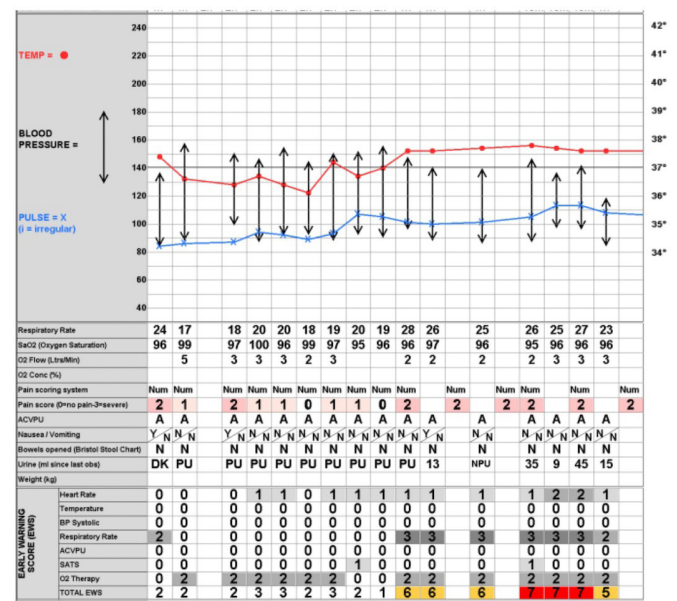


Figure 3 Vital signs before transfer to intensive care unit. ACVPU, Alert, Confused, responding to Voice, responding to Pain, Unresponsive; SATS, saturation.

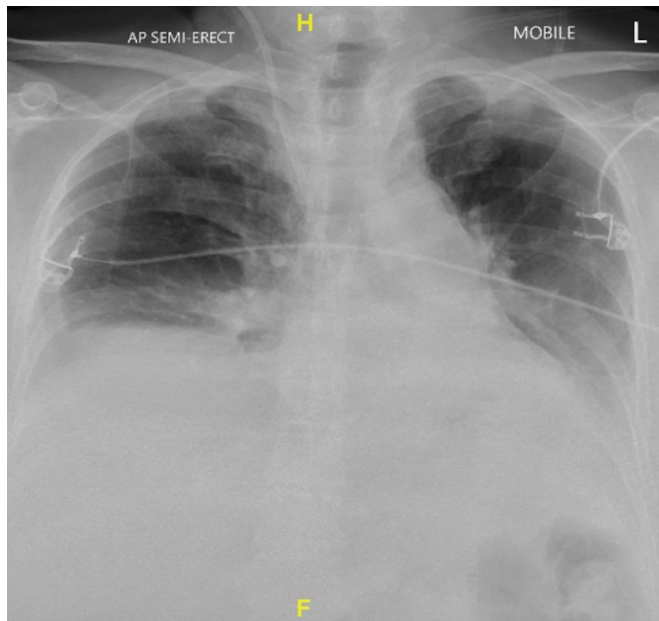


Figure 4 Semierect chest x-ray.

appropriate discussion with the clinical microbiologists. This antibiotic coverage was for the treatment of: necrotising pancreatitis, sepsis and COVID-19 pneumonia. She was not on any antiviral or anti-inflammatory medications nor on any medication that was a part of the COVID-19 RECOVERY Trial.<sup>6</sup> The patient also did not require any form of ventilation or inotropic support during her stay in ICU.

### OUTCOME AND FOLLOW-UP

Within 24 hours of admission, with her worsening clinical status, an urgent chest x-ray was requested. This showed bibasal linear atelectasis (figure 4). Subsequently, the patient's COVID-19 swab that was done on admission returned back as positive. She was isolated immediately as per standard protocol.

The patient had severe inflammatory changes in the pancreas as shown by the CT accompanying her poor clinical status and coexisting COVID-19 infection. Therefore, she was moved to the ICU for close monitoring and management.

As her CT angiogram showed the progression of the peripancreatic and inflammatory changes, her case was discussed with the hepatobiliary surgeons in a nearby tertiary care centre who advised the continuation of conservative management. Following a 10-day stay in the ICU, the patient was stepped down to the ward and currently remains stable as an in-patient. A snapshot of the patient's clinical parameters immediately after she was transferred to the ward is shown in figure 5. As of now, she is having physiotherapy to help regain her preadmission functional baseline. The overall management of the patient's pancreatitis was not affected due to her COVID-19-positive status aside from having to be cared for in a COVID-19 ICU bay with appropriate personal protective equipment.

### DISCUSSION

Several aetiological factors have been described for acute pancreatitis. The most common causes for acute pancreatitis are gallstones and heavy alcohol consumption.<sup>7</sup> However, in 10%–20% of cases an aetiological factor cannot be identified.<sup>8</sup> The patient denied excessive alcohol intake and an ultrasound scan did not show any evidence of gallstones.

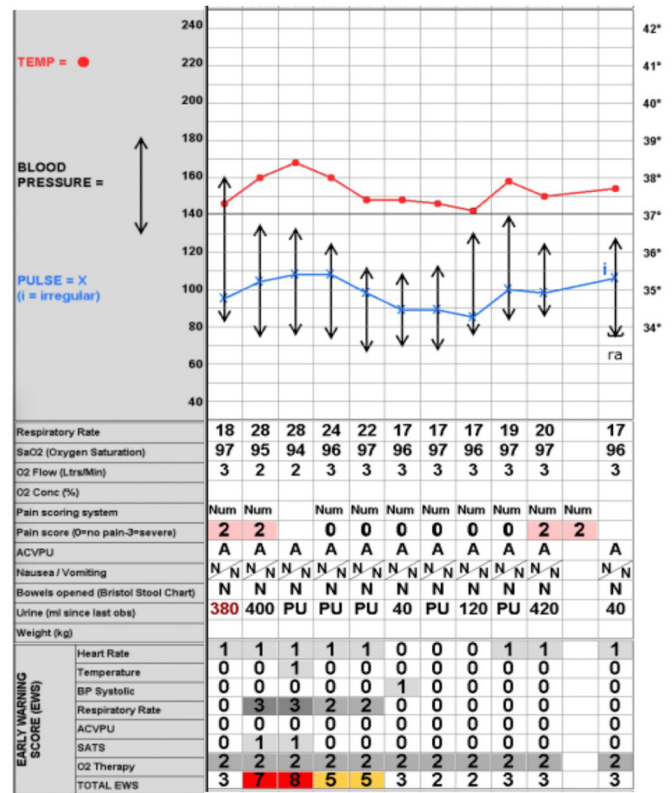


Figure 5 Vital signs just after patient was stepped down to the ward. BP, blood pressure.

A number of infectious agents, including viruses, parasites and bacteria are known to infect the pancreas.<sup>9</sup> Viral pancreatitis has been extensively described in literature to be most commonly caused by mumps, Coxsackie B virus and hepatitis A virus.<sup>10</sup> There were neither reasons for clinical suspicion, nor direct evidence of the above-mentioned viruses in our case. This increases the suspicion of COVID-19-induced pancreatitis. Coronavirus or coronavirus-like virus has been identified in pigeons with severe pancreatitis but no similar studies have been done in humans.<sup>11</sup>

A study of 52 patients with COVID-19 pneumonia showed that there was a 17% incidence of pancreatic injury. This study defined pancreatic injury as any abnormality in the serum amylase or lipase level.<sup>12</sup> However, it is known that the pancreas is not the only source of the pancreatic enzymes (PE) amylase and lipase. For example, gastroenteritis is a well-recognised cause of raised PE. Furthermore, a meta-analysis of patients with COVID-19 showed that 18% had gastrointestinal symptoms.<sup>13</sup> This indicates that raised PE in patients with COVID-19 cannot be directly attributed to pancreatitis.

In the previous global outbreak of severe acute respiratory syndrome (SARS) caused by SARS-associated coronavirus (SARS-CoV) in 2003, studies were done using immunohistochemistry and in situ hybridisation on autopsy samples of patients who died of SARS-CoV. These showed the presence of SARS-CoV antigen and RNA in pancreatic tissue.<sup>14</sup> Genome sequences of SARS-CoV and SARS-CoV-2 are almost identical and share a 79.6% sequence identity.<sup>15</sup> In a study that explored the expression and distribution of ACE2 receptor of SARS-CoV-2, it was reported that ACE2 is expressed more in the pancreas than the lungs.<sup>16</sup> This potentiates the pancreas as a target for SARS-CoV-2. Although the exact pathogenesis of pancreatitis caused by COVID-19 is unclear,

it is thought to develop from the direct cytopathic effect mediated by the local replication of SARS-CoV-2.

The most serious complication of COVID-19 is sepsis-like inflammation leading to a dysregulated inflammatory response resulting in a cytokine storm.<sup>17</sup> Excessive systemic inflammatory response syndrome in acute pancreatitis leads to distant organ damage and multiple organ dysfunction. Inflammatory mediators such as tumour necrosis factor-alpha, interleukin (IL)-6 and IL-10 play a critical role in the inflammatory response of both acute pancreatitis and COVID-19.<sup>17 18</sup> Coexisting pancreatitis and COVID-19 lead to an accelerated clinical course and may be extremely challenging for the clinician to handle. In cases of ANP complicated by a secondary infection, interventions such as necrosectomies may be warranted. Such procedures pose as increased risks to the operating surgeon. This is due to the fact that SARS-CoV-2 is prevalent throughout the gastrointestinal tract and peritoneal fluid has a higher viral load than the upper respiratory secretions.<sup>19 20</sup> The risk of exposure to healthcare workers is much higher in aerosol-generating procedures such as endoscopic or minimally invasive drainage/necrosectomy.

In conclusion, this report highlights the importance of the consideration of COVID-19 as a potential cause in patients presenting with idiopathic pancreatitis, especially during the pandemic. Operating surgeons and interventional radiologists who are involved in dealing with complications associated with pancreatitis need to be aware of the risk of infection.

### Learning points

- ▶ Essential imaging, especially contrast-enhanced CT abdomen and pelvis, can be vital in patients with COVID-19 with abdominal pain.
- ▶ Adoption of a low threshold for escalation to intensive care unit is vital in patients presenting with acute pancreatitis and COVID-19.
- ▶ Donning of appropriate personal protective equipment is imperative for surgeons/interventionalists dealing with potential complications of pancreatitis.
- ▶ An elevated serum amylase level in patients presenting with COVID-19 should not be directly attributed to pancreatitis without appropriate imaging to support the diagnosis.
- ▶ Further studies could be done to address how long the virus lasts in the peripancreatic fluid once the acute inflammatory episode is over.

**Twitter** Biraj K Karmakar @bkk\_27

**Contributors** NKK was involved in the acquisition, analysis, interpretation of the data and drafting of the article. BKK revised the article for important intellectual content and gave final approval of the version published. NKK and BKK agree to be accountable for the article and to ensure that all questions regarding the accuracy or integrity of the article are investigated and resolved. OMT conceptualised the case report.

**Funding** The authors have not declared a specific grant for this research from any funding agency in the public, commercial or not-for-profit sectors.

**Competing interests** None declared.

**Patient consent for publication** Obtained.

**Provenance and peer review** Not commissioned; externally peer reviewed.

This article is made freely available for use in accordance with BMJ's website terms and conditions for the duration of the covid-19 pandemic or until otherwise determined by BMJ. You may use, download and print the article for any lawful, non-commercial purpose (including text and data mining) provided that all copyright notices and trade marks are retained.

### ORCID iDs

Naren K Kumaran <http://orcid.org/0000-0002-0706-9276>

Ormond M Taylor <http://orcid.org/0000-0003-4738-3283>

### REFERENCES

- 1 Who.int. 2020. Coronavirus. Available: [https://www.who.int/health-topics/coronavirus#tab=tab\\_1](https://www.who.int/health-topics/coronavirus#tab=tab_1)
- 2 Who coronavirus disease (COVID-19) Dashboard, 2020. Available: <https://covid19.who.int/> [Accessed 29 Jun 2020].
- 3 Zhu J, Ji P, Pang J, et al. Clinical characteristics of 3062 COVID-19 patients: a meta-analysis. *J Med Virol* 2020;54.
- 4 Pan L, Mu M, Yang P, et al. Clinical characteristics of COVID-19 patients with digestive symptoms in Hubei, China. *Am J Gastroenterol* 2020;115:766–73.
- 5 Banks PA, Bollen TL, Dervenis C, et al. Classification of acute pancreatitis—2012: revision of the Atlanta classification and definitions by international consensus. *Gut* 2013;62:102–11.
- 6 Welcome—recovery trial, 2020. Available: <https://www.recoverytrial.net/> [Accessed 23 Jul 2020].
- 7 Forsmark CE, Swaroop Vege S, Wilcox CM. Acute pancreatitis. *N Engl J Med Overseas Ed* 2016;375:1972–81.
- 8 Whitcomb DC. Acute pancreatitis. *N Engl J Med Overseas Ed* 2006;354:2142–50.
- 9 Steinberg W, Tenner S. Acute pancreatitis. *N Engl J Med* 1994;330:1198–210.
- 10 Kottanattu L, Lava SAG, Helbling R, et al. Pancreatitis and cholecystitis in primary acute symptomatic Epstein-Barr virus infection - Systematic review of the literature. *J Clin Virol* 2016;82:51–5.
- 11 Qian DH, Zhu GJ, Wu LZ, et al. Isolation and characterization of a coronavirus from pigeons with pancreatitis. *Am J Vet Res* 2006;67:1575–9.
- 12 Wang F, Wang H, Fan J, et al. Pancreatic injury patterns in patients with coronavirus disease 19 pneumonia. *Gastroenterology* 2020;159:367–70.
- 13 Cheung KS, Hung IFN, Chan PPY, et al. Gastrointestinal manifestations of SARS-CoV-2 infection and virus load in fecal samples from a Hong Kong cohort: systematic review and meta-analysis. *Gastroenterology* 2020;159:81–95.
- 14 Ding Y, He L, Zhang Q, et al. Organ distribution of severe acute respiratory syndrome (SARS) associated coronavirus (SARS-CoV) in SARS patients: implications for pathogenesis and virus transmission pathways. *J Pathol* 2004;203:622–30.
- 15 Zhou P, Yang X-L, Wang X-G, et al. A pneumonia outbreak associated with a new coronavirus of probable bat origin. *Nature* 2020;579:270–3.
- 16 Liu F, Long X, Zhang B, et al. Ace2 expression in pancreas may cause pancreatic damage after SARS-CoV-2 infection. *Clin Gastroenterol Hepatol* 2020;18:2128–30.
- 17 Manjili RH, Zarei M, Habibi M, et al. COVID-19 as an acute inflammatory disease. *J Immunol* 2020;205:12–19.
- 18 Bhatia M. Acute pancreatitis as a model of SIRS. *Front Biosci* 2009;14:2042.
- 19 Ng SC, Tilg H. COVID-19 and the gastrointestinal tract: more than meets the eye. *Gut* 2020;69:973–4.
- 20 Cocolini F. Journals.lww.com, 2020. Available: <https://journals.lww.com/annalsurgery/Documents/SARS-CoV-2%20is%20present%20in%20peritoneal%20fluid%20in%20COVID-19%20patients.pdf> [Accessed 27 Jun 2020].

Copyright 2020 BMJ Publishing Group. All rights reserved. For permission to reuse any of this content visit <https://www.bmj.com/company/products-services/rights-and-licensing/permissions/>  
BMJ Case Report Fellows may re-use this article for personal use and teaching without any further permission.

Become a Fellow of BMJ Case Reports today and you can:

- ▶ Submit as many cases as you like
- ▶ Enjoy fast sympathetic peer review and rapid publication of accepted articles
- ▶ Access all the published articles
- ▶ Re-use any of the published material for personal use and teaching without further permission

**Customer Service**

If you have any further queries about your subscription, please contact our customer services team on +44 (0) 207111 1105 or via email at [support@bmj.com](mailto:support@bmj.com).

Visit [casereports.bmj.com](http://casereports.bmj.com) for more articles like this and to become a Fellow