

Concomitant Primary CNS Lymphoma and FSH-Pituitary Adenoma Arising Within the Sella. Entirely Coincidental?

Vin Shen Ban, MB, BChir, MSc*
Bedansh Roy Chaudhary,
MBBS, MSc*
Kieran Allinson, BSc (Hons),
MB, ChB[†]
Thomas Santarius, MD, PhD*
Ramez Wadie Kirolos, MB,
ChB, MD*

*Division of Neurosurgery, Addenbrooke's Hospital, Cambridge, UK; †Department of Histopathology, Addenbrooke's Hospital, Cambridge, UK

Correspondence:

Vin Shen Ban, MB, BChir, MSc,
 Department of Neurological Surgery,
 UT Southwestern Medical Center,
 5323 Harry Hines Blvd,
 Dallas, TX 75390-8855.
 E-mail: vinshen.ban@cantab.net

Received, October 4, 2015.

Accepted, November 22, 2016.

Published Online, December 7, 2016.

© Congress of Neurological Surgeons 2016.

This is an Open Access article distributed under the terms of the Creative Commons Attribution-NonCommercial-NoDerivs licence (<http://creativecommons.org/licenses/by-nc-nd/4.0/>), which permits non-commercial reproduction and distribution of the work, in any medium, provided the original work is not altered or transformed in any way, and that the work is properly cited. For commercial re-use, please contact journals.permissions@oup.com

BACKGROUND AND IMPORTANCE: Collision tumors are the simultaneous occurrence of more than one type of neoplasm within an anatomic space. In the pituitary sella, collision tumors are exceedingly rare, and not much is known about their etiology and prognosis.

CLINICAL PRESENTATION: A 74-year-old man presented with a concomitant primary pituitary lymphoma (diffuse large B-cell non-Hodgkin's lymphoma; DLBCL) and follicle-stimulating hormone (FSH)-adenoma diagnosed histologically after clinical features of apoplexy prompted urgent surgical decompression and resection. Strong immunoreactivity for FSH by the lymphoma was evident. Full-body workup demonstrated no other source for the lymphoma. He subsequently underwent 4 cycles of chemotherapy and has been in remission for over 32 months. His ophthalmoplegia at presentation persisted with no further deficits.

CONCLUSIONS: Four cases of collision tumors of primary pituitary lymphoma and adenoma have previously been reported. This case represents the first combination of an FSH-adenoma and a DLBCL in the literature. Prompt involvement of the hematology-oncology team contributed to the good outcome seen in this case. The putative role played by pituitary hormones in tumorigenesis is reviewed in this case report. The association is either a chance occurrence or due to the induction of lymphoma cell proliferation by the binding of FSH produced by the adenoma to the FSH receptors on the lymphoma cells.

KEY WORDS: Apoplexy, Diffuse large B-cell lymphoma, Follicle-stimulating hormone, Gonadotroph, Lymphoma, Macroadenoma, Pituitary

Neurosurgery 80:E170–E175, 2017

DOI:10.1093/neuros/nyw003

www.neurosurgery-online.com

Of all the primary central nervous system tumors, 15.3% are pituitary tumors, the majority of which are pituitary adenomas, while 2.2% of tumors are lymphomas.¹ We report a case of a diffuse large B-cell non-Hodgkin's lymphoma (DLBCL) within a pituitary follicle-stimulating hormone (FSH)-macroadenoma, presenting with the classical features of pituitary apoplexy. Rarely, collision tumors in the sella are discovered on histological examination.^{2–10} As these have only ever been reported in case reports and case series, their etiology is still being debated. We review here the literature and discuss the possible relationships between the 2 distinct tumors.

CLINICAL PRESENTATION

A 74-year-old Caucasian man presented to the neurosurgical department with a 10-day history of acute onset bilateral retro-orbital pain, headaches, and nausea. Four days after the onset of headaches, he developed left-sided ptosis. On the following day, he also noticed some double vision. He had no features of endocrinopathy.

On examination, his visual acuity and visual fields were normal. He had a partial left third nerve palsy with ptosis and partial mydriasis of the left pupil, which sluggishly reacted to light. He reported diplopia on right lateral gaze, with a left medial rectus dysfunction. Systemic

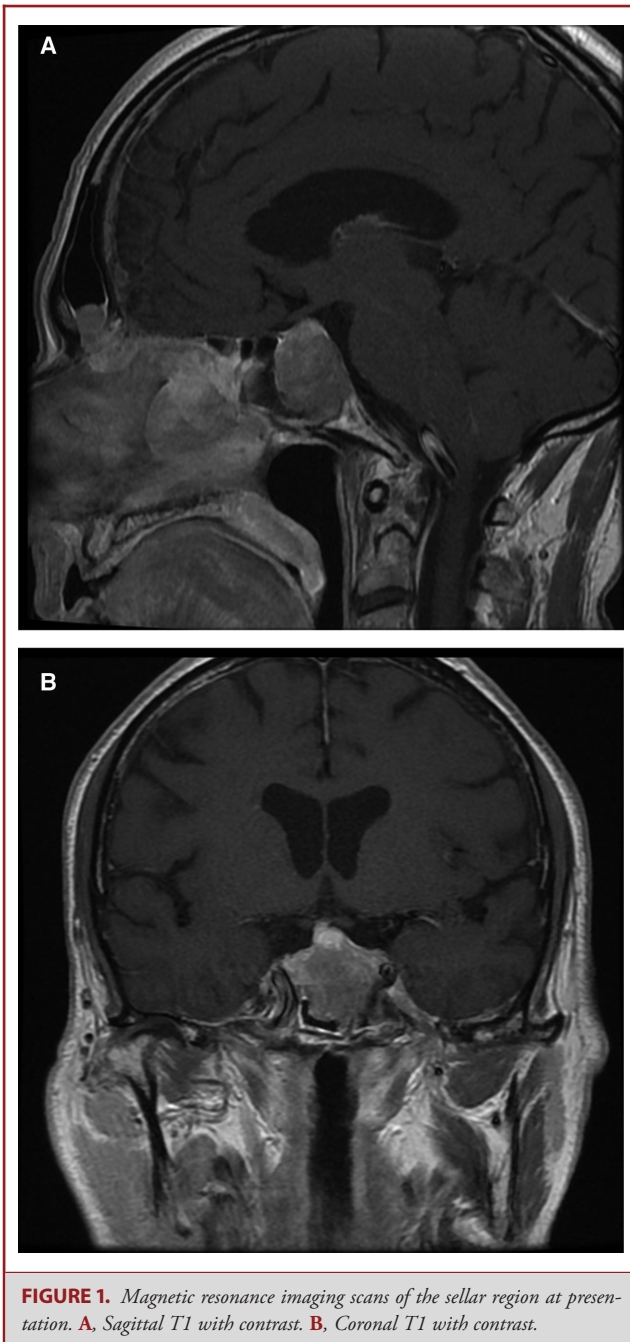


FIGURE 1. Magnetic resonance imaging scans of the sellar region at presentation. **A.** Sagittal T1 with contrast. **B.** Coronal T1 with contrast.

examination was unremarkable, with no palpable lymphadenopathy or intra-abdominal masses.

Imaging

Computed tomography (CT) and, subsequently, magnetic resonance imaging (MRI) scans of the head revealed a $27 \times 25 \times 20$ mm soft tissue mass in the pituitary fossa with suprasellar extension, which just abutted the inferior surface of the optic chiasm (Figure 1). There was an extension into the sphenoid

sinuses and the left cavernous sinus. On the unenhanced scan, there were no areas of significant hemorrhage to radiologically suggest a major apoplexy. The diagnosis was that of a pituitary macroadenoma.

The history, however, was suggestive of a pituitary apoplexy (the MRI was performed 10 days after the acute event), and although it was explained to the patient that he may improve with conservative treatment, the plan was to proceed with elective surgical resection of the pituitary lesion in a few weeks' time, during which his progress would be monitored.

Laboratory Tests

The complete blood count was within normal ranges. Pituitary function tests showed a low testosterone (6 nmol/L, ref: 8-29 nmol/L), raised prolactin (624 mIU/L, ref: 45-375 mIU/L), raised Insulin-like Growth Factor 1, IGF-1 (33.9 nmol/L, ref: 5-22.5 nmol/L), and normal thyroid-stimulating hormone (0.8 mIU/L, ref: 0.35-5.5 mIU/L), Free T4 (12.2 pmol/L, ref: 10-19.8 pmol/L), luteinizing hormone (1.6 u/L, ref: 1.5-6.3 IU/L), FSH (3.4 u/L, ref: 1.0-10.1 IU/L), and 0900 hours Cortisol (354 nmol/L).

Treatment

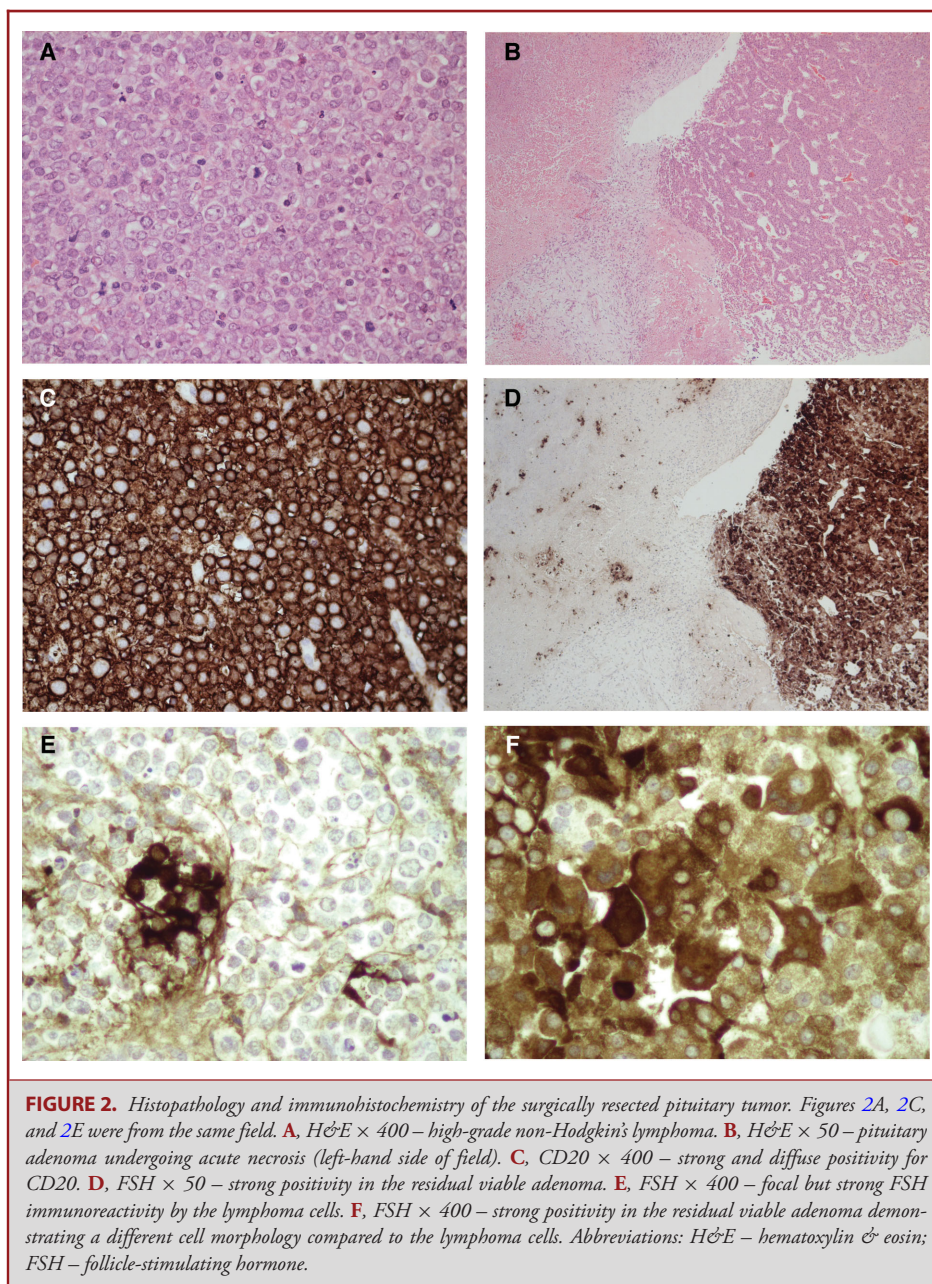
During the 3 weeks prior to the planned surgery, the patient reported worsening of his vision and diplopia. Thus, the patient was prematurely admitted for an urgent endoscopic endonasal transsphenoidal resection of his pituitary macroadenoma, mainly to prevent the future compromise of his vision and to aid the recovery of his ocular motor function. The anterior sella wall was found to be eroded by tumor extending partially into the sphenoid sinus. The lesion was heterogeneous in consistency and appearance but was not particularly suspicious of a lesion other than a pituitary adenoma. A gross macroscopic resection was achieved and the diaphragma sellae fully descended intact.

There were no operative complications, and the patient was discharged later after an uneventful postoperative recovery. Three weeks following surgery, the patient was recovering well with less pain and an improvement in his ptosis.

Pathology

Histological examination of hematoxylin & eosin-stained sections revealed 2 separate neoplastic processes (Figure 2). The larger component comprised sheets of malignant lymphoid cells with enlarged nuclei, vacuolated chromatin, conspicuous nucleoli, and a high level of apoptotic and mitotic activity (Figures 2A, 2C, 2E). The MIB-1 proliferation index was greater than 90%. The morphology and immunohistochemical profile, as demonstrated by the positive staining with anti-CD20 antibodies, were that of a DLBCL.

Molecular tests were entirely consistent with a DLBCL: interphase fluorescent in situ hybridization (FISH) performed on paraffin sections showed no evidence of BCL2, BCL6, or MYC gene rearrangement or copy number change at BCL6 or MYC locus but an extra copy of BCL2 locus, representing a partial



or complete trisomy 18 in the tumor cells examined, with no evidence of a MYC-involved translocation.

Fragments of a separate tumor were also present in histological sections (Figures 2B, 2D, 2F). This consisted of ribbons of neoplastic adenohypophyseal cells with small round nuclei, delicate chromatin, eosinophilic cytoplasm, and strong immunoreactivity for FSH. This tumor was partially necrotic.

There was also focal but strong immunoreactivity for FSH by the lymphoma (Figure 2E). The morphology of these cells was consistent with the ones surrounding them (ie, they were of a

lymphoid origin) rather than that of the adenohypophyseal cells (Figure 2F).

Follow-up

Following the histological diagnosis, the patient was referred to the hematology-oncological service for further input and management of his lymphoma. The postoperative MRI showed minimal residual intrasellar tissue. There was no evidence of systemic lymphoma. A positron emission tomography (PET) CT scan showed increased uptake in the pituitary gland just to

the left of midline. Bone marrow aspirate showed no atypical lymphocytes, and a bone marrow trephine biopsy showed no lymphoblasts. He received 4 cycles of chemotherapy; R-CHOP with intrathecal methotrexate over about 8 weeks and granulocyte-colony stimulating factor (G-CSF) support for 6 days. After 2 cycles, the PET-CT scan became negative.

He has remained in remission for over 32 months from treatment, and the follow-up scans have revealed no recurrence. The hydrocortisone supplementation has stopped, and currently his medications include thyroxine, statin, aspirin, and vitamin supplements. Apart from the residual visual symptoms, he has no other deficits and remains generally very well. There is still a degree of partial ophthalmoplegia that is deemed not suitable for ophthalmological intervention.

DISCUSSION

Simultaneous occurrence of another neoplasm with a pituitary adenoma is very rare.^{2,7,8} The association between a pituitary adenoma and another intracranial neoplasm occurring spontaneously usually lacks another explanation other than a chance occurrence and, hence, may require histological confirmation of the second lesion.²

Incidental pituitary adenomas are found in 15% of the general population.¹¹ While pituitary adenomas are mostly benign,¹ and their effects limited to the over- and undersecretion of pituitary hormones as well as the mass effect on surrounding structures, primary pituitary lymphomas have a much poorer prognosis and hence early detection and management is key to improved outcomes.¹² Although the diagnosis of pituitary lymphoma is mostly dependent on histology, immunohistochemistry and in situ hybridization, suspicion should be raised in a fast-growing tumor presenting with symptoms of apoplexy.

The coexistence in the sella of primary pituitary lymphoma and pituitary adenoma is extremely rare. In addition to our case, there have been only 4 other such cases reported in the literature (Table). Morita et al⁹ reported a relapse of systemic lymphoma to the sella with a pre-existing pituitary adenoma. Several examples of metastasis to a pre-existing intracranial neoplasm – the so-called collision tumors – have also been reported.^{8,13,14} In one case reported, the infiltration of the hypothalamus by a lymphoma was postulated to lead to the simultaneous development of a pituitary adenoma through hormonal mechanisms.¹⁰

It is well known that pituitary hormones can act as cytokines and influence immunomodulation.^{15–17} Pituitary hormone receptors have also been shown to be expressed in lymphoid tissues.¹⁸ In experimental and in vitro studies, several pituitary hormones including FSH,¹⁹ growth hormone (GH),^{20–23} prolactin, PRL^{24,25}, and thyroid-stimulating hormone (TSH)²⁶ were shown to induce lymphocytic proliferation.

In vitro studies by Costa et al¹⁹ showed the strong induction of proliferation of lymphocytes (T cells) by FSH and identified 2 groups of responders vs nonresponders, with age or menopausal factors affecting this response. The explanation proposed is related to the changes in FSH receptors on lymphocytes by age. Melmed et al, in an experimental study,²⁷ demonstrated that human chorionic gonadotropin (hCG) stimulates proliferation of Nb-2 node rat lymphoma cell line, which was dose dependent. While the previously described cases of concomitant lymphomas were of T-cell type, our case was DLBCL.

There remains some doubt regarding the case of concomitant lymphoma and TSH-adenoma reported by Au et al,⁴ as systemic lymphoma was not totally excluded by thorough examination, and, hence, confirmation of this being a primary lymphoma was not certain. Although the mitogenic effect of GH is accepted and, furthermore, this effect on lymphocytes has been

TABLE. Reported Cases of Coexisting Primary Pituitary Lymphoma and Pituitary Adenoma

Case report	Age and sex at lymphoma presentation	Timing of lymphoma presentation from pre-existing adenoma	Type of pituitary adenoma	Type of lymphoma
Kuhn et al (1999) ³	67 F	25 years	FSH	T cell T-LBL
Au et al (2000) ⁴	82 M	Concomitant	TSH	B cell DLBCL
Romeike et al (2008) ⁵	64 F	17 years	FSH	T cell T-LBL
Martinez et al (2011) ⁶	71 F	Concomitant	GH + hypophysitis	B cell DLBCL
Ban et al (2017) ^a	74 M	Concomitant	FSH	B cell DLBCL

Abbreviations: FSH – follicle-stimulating hormone; TSH – thyroid-stimulating hormone; GH – growth hormone; T-LBL – T-cell lymphoblastic lymphoma; DLBCL – diffuse large B-cell lymphoma.

^aThe present case.

demonstrated,^{21,22,28} histological diagnosis of the case by Martinez et al of concomitant primary pituitary lymphoma and GH-adenoma revealed the additional presence of hypophysitis.⁶ In such a case, the role played by chronic inflammation in inducing the lymphoma cannot be excluded.

Despite prolactinomas being a frequent type of pituitary adenoma, a concomitant case of PRL-adenoma and lymphoma has not been described. In vitro PRL is mitogenic to T-cell leukemia and Nb-2 rat T-lymphoma cell lines, independent of interleukin-2 and possibly by modulating transcriptional induction of growth-related genes such as C-Myc.^{24,25} There is a possibility that the elevated PRL due to stalk effect from suprasellar extension, such as in our case, may play a role in the induction of the lymphoma.

The other explanation is that the FSH produced by the adenoma induced the proliferation of the lymphoma cells. This theory is supported by the finding of a focal but strong area of FSH immunoreactivity in the lymphoma tissue, which could potentially be explained by the binding of FSH to FSH receptors on the lymphoma cells.

It has to be acknowledged that the induction of an adjacent lymphoma by an FSH-adenoma through hormonal mechanisms has been proposed by Kuhn et al in 1999.³ Based on this review, the association between FSH-adenoma and adjacent induction of a lymphoma is more compelling than the other adenoma types. Of course, chance association remains a possible explanation, as no studies have demonstrated a causal relationship.

CONCLUSION

In conclusion, collision tumors of a primary pituitary lymphoma and an adenoma are rare. We identified a case of an elderly patient with the first reported combination of a primary pituitary DLBCL and an FSH-adenoma. It is still not entirely clear if the coexistence of these tumors is entirely coincidental, or if the development of the lymphoma was triggered by the pituitary adenoma, for example, through its hormonal effects. The demonstration of a focal but strong immunoreactivity for FSH in the lymphoma tissue supports this theory, but is by no means conclusive. As it has been demonstrated by this case, identification of a coexisting tumor was only possible through histological examination. Prompt workup to determine the origin of the coexisting tumor will aid treatment decisions and likely determine the patient's course of recovery and prognosis.

Disclosures

The authors have no personal, financial, or institutional interest in any of the drugs, materials, or devices described in this article.

REFERENCES

1. Dolecek TA, Propp JM, Stroup NE, Kruchko C. CBTRUS statistical report: primary brain and central nervous system tumors diagnosed in the United States in 2005-2009. *Neuro Oncol*. 2012;14(suppl 5):v1-49.

- Ganesan D, Dean AF, Antoun N, Kirillos RW. A second biopsy?—Tandem lesion. *Acta Neurochir (Wien)*. 2008;150(5):501-503.
- Kuhn D, Buchfelder M, Brabletz T, Paulus W. Intracellular malignant lymphoma developing within pituitary adenoma. *Acta Neuropathol*. 1999;97(3):311-316.
- Au WY, Kwong YL, Shek TW, Leung G, Ooi C. Diffuse large-cell B-cell lymphoma in a pituitary adenoma: an unusual cause of pituitary apoplexy. *Am J Hematol*. 2000;63(4):231-232.
- Romeike BF, Joellenbeck B, Stein H, et al. Precursor T-lymphoblastic lymphoma within a recurrent pituitary adenoma. *Acta Neurochir (Wien)*. 2008;150(8):833-836.
- Martinez JH, Davila Martinez M, Mercado de Gorgola M, Montalvo LF, Tome JE. The coexistence of an intrasellar adenoma, lymphocytic hypophysitis, and primary pituitary lymphoma in a patient with acromegaly. *Case Rep Endocrinol*. 2011;2011:941738.
- Karsy M, Sonnen J, Couldwell WT. Coincident pituitary adenoma and sellar meningioma. *Acta Neurochir (Wien)*. 2015;157(2):231-233.
- Koutourousiou M, Kontogeorgos G, Wesseling P, Grotenhuis AJ, Seretis A. Collision sellar lesions: experience with eight cases and review of the literature. *Pituitary*. 2010;13(1):8-17.
- Morita K, Nakamura F, Kamikubo Y, et al. Pituitary lymphoma developing within pituitary adenoma. *Int J Hematol*. 2012;95(6):721-724.
- Roglii VL, Suzuki M, Armstrong D, McGavran MH. Pituitary microadenoma and primary lymphoma of brain associated with hypothalamic invasion. *Am J Clin Pathol*. 1979;71(6):724-727.
- Ezzat S, Asa SL, Couldwell WT, et al. The prevalence of pituitary adenomas: a systematic review. *Cancer*. 2004;101(3):613-619.
- Koiso T, Akutsu H, Takano S, et al. Malignant lymphoma in the parasellar region. *Case Rep Med*. 2014;2014:747280.
- Sogani J, Yang W, Lavi E, Zimmerman RD, Gupta A. Sellar collision tumor involving metastatic lung cancer and pituitary adenoma: radiologic-pathologic correlation and review of the literature. *Clin Imaging*. 2014;38(3):318-321.
- Nassiri F, Cusimano M, Rotondo F, Horvath E, Kovacs K. Neuroendocrine tumor of unknown origin metastasizing to a growth hormone-secreting pituitary adenoma. *World Neurosurg*. 2012;77(1):201 e209-201 e212.
- Matera L. Endocrine, paracrine and autocrine actions of prolactin on immune cells. *Life Sci*. 1996;59(8):599-614.
- Velkeniers B, Dogusan Z, Naessens F, Hooghe R, Hooghe-Peters EL. Prolactin, growth hormone and the immune system in humans. *Cell Mol Life Sci*. 1998;54(10):1102-1108.
- Weigent DA. Immunoregulatory properties of growth hormone and prolactin. *Pharmacol Ther*. 1996;69(3):237-257.
- O'Neal KD, Schwarz LA, Yu-Lee LY. Prolactin receptor gene expression in lymphoid cells. *Mol Cell Endocrinol*. 1991;82(2-3):127-135.
- Costa O, Bouthet C, Sauvage P, Michel JP, Deschaux P. Age-dependent LH and FSH effect on the proliferation of women's peripheral blood lymphocytes in vitro. *Int J Immunopharmacol*. 1990;12(8):821-829.
- Giustina A, Veldhuis JD. Pathophysiology of the neuroregulation of growth hormone secretion in experimental animals and the human. *Endocr Rev*. 1998;19(6):717-797.
- Fleming WH, Murphy PR, Murphy LJ, Hatton TW, Matusik RJ, Friesen HG. Human growth hormone induces and maintains c-myc gene expression in Nb2 lymphoma cells. *Endocrinology*. 1985;117(6):2547-2549.
- Luthman M, Wallerman E, Roos P, Werner S. Growth hormone specific stimulation of mitosis by size-fractionated serum from patients with growth hormone insufficiency: a study on the rat lymphoma cell line, Nb2. *Acta Endocrinol (Copenh)*. 1991;125(2):113-121.
- Lee PD, Rosenfeld RG, Hintz RL, Smith SD. Characterization of insulin, insulin-like growth factors I and II, and growth hormone receptors on human leukemic lymphoblasts. *J Clin Endocrinol Metab*. 1986;62(1):28-35.
- Matera L, Cutufia M, Geuna M, et al. Prolactin is an autocrine growth factor for the Jurkat human T-leukemic cell line. *J Neuroimmunol*. 1997;79(1):12-21.
- Yu-Lee LY. Prolactin stimulates transcription of growth-related genes in Nb2 T lymphoma cells. *Mol Cell Endocrinol*. 1990;68(1):21-28.
- Braesch-Andersen S, Paulie S, Stamenkovic I. Dopamine-induced lymphoma cell death by inhibition of hormone release. *Scand J Immunol*. 1992;36(4):547-553.

27. Melmed S, Braunstein GD. Human chorionic gonadotropin stimulates proliferation of Nb 2 rat lymphoma cells. *J Clin Endocrinol Metab.* 1983;56(5):1068-1070.
28. Baglia LA, Cruz D, Shaw JE. Production of immunoreactive forms of growth hormone by the Burkitt tumor serum-free cell line sfRamos. *Endocrinology.* 1992;130(5):2446-2454.

COMMENT

The authors have presented a concise but detailed and important case and literature review on this topic, including excellent illustra-

tions. Collision tumors in the pituitary and sella area have been observed with several tumor entities, for instance, growth hormone secreting adenoma and gangliocytoma in the pituitary gland, pituitary adenoma and craniopharyngioma, and others. Reports of collision tumors related to lymphoma are rare.

Christian A. Koch
Jackson, Mississippi