

Received: 2013.06.22  
Accepted: 2013.07.22  
Published: 2013.09.19

# Montelukast is as effective as penicillin in treatment of acute otitis media: An experimental rat study

Authors' Contribution:  
Study Design A  
Data Collection B  
Statistical Analysis C  
Data Interpretation D  
Manuscript Preparation E  
Literature Search F  
Funds Collection G

ABCDEF 1 **Seçil Uçar**  
BCD 1 **Tural Huseynov**  
CD 2 **Melahat Çoban**  
BCD 3 **Sülen Sarıoğlu**  
BDG 1 **Bülent Şerbetçioğlu**  
ADEF 4 **Arzu Didem Yalcin**

1 Dokuz Eylül University, Medical School, Department of Otorhinolaryngology, Izmir, Turkey  
2 Internal Medicine, Antalya Training and Research Hospital, Antalya, Turkey  
3 Dokuz Eylül University, Medical School, Department of Pathology, Izmir, Turkey  
4 Internal Medicine, Allergy and Clinical Immunology Unit, Antalya Training and Research Hospital, Antalya, Turkey

**Corresponding Authors:** Seçil Uçar, e-mail: [sucar@yahoo.com](mailto:sucar@yahoo.com)  
**Source of support:** Departmental sources

**Background:** Leukotrienes are the major factors in the formation of edema and mucus, as well as development of tuba Eustachii dysfunction in acute otitis media. We developed an experimental acute suppurative otitis media model and compared the responses of rats to penicillin and combinations of leukotriene antagonist with respect to histopathological observations conducted in early and late phases.

**Material/Methods:** A total of 83 ears from 56 Wistar rats were used in this study. Pneumococcus suspension was injected trans-tympanically into all rats. Subjects were classified into 4 different groups with 14 rats in each. In Group A, intramuscular penicillin G was injected for a period of 5 days. In Group B, intraperitoneal montelukast was injected for 21 days in addition to penicillin. In Group C, intraperitoneal montelukast isotonic NaCl in Group D was injected into rats for 21 days.

**Results:** No significant difference was found between the groups, except for mucosal vascularization with respect to mucosal and TM parameters in early phases. Furthermore, considerable deviations were observed for the recuperation of TM and mucosal inflammation for groups in which subjects were injected with montelukast as compared to other groups of the study in the late phases.

**Conclusions:** When the parameters of inflammation in the rat middle ear were compared with each other, most of these parameters did not show any statistically significant beneficial effects in montelukast and penicillin groups.

**Key words:** acute otitis media • leukotriene • montelukast • tympanic membrane

**Full-text PDF:** <http://www.basic.medscimonit.com/download/index/idArt/889474>




2713



6



1



18

## Background

Otitis media (OM) is an inflammatory response of the middle ear (ME) caused by multiple factors such as infection and eustachian tube dysfunction [1]. Acute otitis media (AOM) is one of the commonest pediatric diseases [2–4]. *Streptococcus pneumoniae* and *Haemophilus influenzae* are the most common causative microorganisms for AOM [5–7]. Patients with AOM present with 2 important problems – infection and effusion. The infection is usually under control within a few days with successful antibiotic treatment. However, the middle ear effusion lasts for months [4]. In most cases, AOM is a self-limiting disease, and it has been argued that untreated infections might promote the production of antibodies and thus strengthen the immune response and improve resistance in cases of repeated exposure. Furthermore, development of bacterial resistance to common antibiotics is an increasing problem in some parts of the world, which could be limited by strict indications and prescription of narrow-spectrum antibiotics. However, risk of potentially life-threatening complications clearly justifies the use of antibiotics [8]. Earlier studies of pneumococcal otitis media in the rat demonstrated that the clinical course of pneumococcal AOM in the rat resembles that in human beings. Mucosal changes were shown to be present during the acute phase of infection, but these changes persisted throughout the study period [7]. Mucosal alterations have been suggested to be of importance for the subsequent development of secretory otitis media, and of recurrent episodes of AOM [5].

The pathogenesis of effusion in AOM is extraordinarily complex. Viral, bacterial, and/or inert respiratory antigens stimulate a complicated interaction between macrophages, mast cells, eosinophils, and neutrophils [9]. The cells produce a cascade of many types of inflammatory mediators, which result in damage by causing epithelial shedding, plasma leakage, edema, and mucus formation [4]. Of the numerous inflammatory mediators found in a MEE, leukotrienes have been shown to be a major cause of edema, mucus production, and eustachian tube dysfunction [10–12]. LT C4 and LTD4 stimulate mucus production in human airway cells *in vitro* and have been shown to depressive activity of human nasal cilia [4,13]. Cysteinyl leukotrienes are products of arachidonic acid metabolism and are released by various cells that are involved in the inflammatory cascade. Arachidonic acid metabolites are important in the pathogenesis of middle ear effusion and may even be responsible for the sensorineural hearing loss that is occasionally observed with OME [4,14].

Montelukast sodium (MK) is a selective and orally active leukotriene receptor antagonist. It seemed appropriate to investigate the possibility that MK might be beneficial in an experimental rat model [4]. Although montelukast has long been used in clinical practice, this drug has rarely been of interest in terms of experimental rat models seeking effectiveness for AOM therapy [15].

The aim of this study was to compare the effects of penicillin and montelukast in treatment of acute and chronic acute otitis.

## Material and Methods

The animals used in the present study were supervised and handled according to the Dokuz Eylül University Medical School Guidelines for Care and Use of laboratory animals. Fifty-six healthy female rats weighing 200–250 g were used in this study. The experimental animals were housed in plastic cages under laboratory conditions of 28°C temperature with 75% relative humidity and a photoperiod of 12-h light/dark cycle. The rats were given standard pelleted diet and water *ad libitum*. The animals were anesthetized with intraperitoneal injections of 50 mg/kg ketamine hydrochloride (Ketalar®, Park-Davis, Turkey) and xylazine hydrochloride combination. All procedures were performed under sterile conditions. In all rats, 2 ears and tympanic membranes were examined under an otomicroscope and the ears in which otitis media with effusion was observed were excluded. We administered 0.03 ml suspension of type 3 *Pneumococci* (ATCC 49619), at a concentration of 10<sup>9</sup> CFU/ml) via 26-gauge needle through the healthy tympanic membranes into the middle ear cavities of all animals. All tympanic membranes and middle ears were examined by otomicroscopic examination 48 hours after pneumococci suspension injection. Acute otitis media was confirmed in 84 middle ears of 56 rats. The animals with AOM were divided into 4 groups with 14 rats in each group.

In Group A (*Antibiotic-treated group, n=20*), 14 animals (20 ears) were treated with intramuscular penicillin G (Penicillin-G®, Pfizer Warner Lambert, ABD) 160.000 U/kg once daily for 5 days.

In Group B (*Antibiotic and montelukast co-treated group n=23*), 14 animals (23 ears) were treated with penicillin G 160.000 U/kg once daily for 5 days and Montelukast Na (Singulair®, Merck Sharp Dohme, ABD) (10 mg/kg/day) for 21 days intraperitoneally.

In Group C (*montelukast-treated group, n=21*), 14 animals (21 ears), were treated with Montelukast Na (10 mg/kg/day) for 21 days intraperitoneally.

In Group D (*placebo group, n=20*), 14 rats (20 ears), were not given any medication, only 2 cc phosphate-buffered saline intraperitoneally.

Two rats died – 1 in the antibiotic and montelukast co-treatment group and 1 infected control – and were excluded from the study.

## Histologic preparation

On days 7 and 21, 7 rats from each group were otomicroscopically examined under general anesthesia with an intramuscular

injection of 50 mg/kg of ketamine hydrochloride and 50 mg/kg of xylazine. They were then killed by intraperitoneal injection of 80 mg/kg pentobarbital. Their temporal bones were removed, fixed in 10% formalin for 1 day, and decalcified with formic acid for 2 days.

### Morphologic examination

Specimens of middle ear, including the promontory, bulla, and tympanic membrane, were divided into 2 equal parts. Incisions passed through the tympanic membrane and bull and specimens were embedded in paraffin following a dehydration procedure and sectioned serially by a microtome for light microscopy (0.5  $\mu$ m). Hemotoksilen & Eosin and Alcian blue staining was performed for morphologic examination.

The histopathologic specimens were than blindly evaluated with light microscopy by the same pathologist. Seven measurements were performed for each specimen: tympanic membrane parameters (thickness, vascularization, and inflammation) and mucosal parameters of tympanic bulla (thickness, vascularization, inflammation, and goblet cell metaplasia) were evaluated separately [5] (Olympus BX50, Olympus Optical Co, Tokyo, Japan).

The average value was recorded to increase reproducibility so that changes were graded as 0 if unchanged (as compared to the controls), 1 when mild, 2 when moderate, and 3 when severe for the following variables:

Mucosa and tympanic membrane thickness was graded as 1 when it had increased by >10% but <25%, as 2 when it had increased >25% but <50%, and as 3 when it had increased by >50%.

Vascular changes of mucosa and tympanic membrane were graded as 1 when the vascular lumen seen in 1 field had increased by >10% but <25%, as 2 when it had increased by >25% but <50%, and as 3 when it had increased by >50%.

An inflammatory cell count of mucosa and tympanic membrane <5 cells/field at 200 $\times$  magnification was designated as 1, a count of >5 cells/field but <10 cells/field was designated as 2, and a count of >10 cells/field was designated as 3.

Goblet cell metaplasia was defined as the transformation of the normally flat epithelium to goblet cells. The changes are graded as 1 when the transformed cells accounted for < 50% of the cells observed, and as 2 when the transformed cells accounted for >50% of the cells observed [5].

### Statistical analyses

All statistical analyses were performed using SPSS v11.00 software. Results are expressed as mean  $\pm$  standard deviation

(SD). The Kruskal-Wallis test was used to compare the variables. Bonferroni correction was used to calculate p values and a p value less than 0.01 was considered statistically significant. Comparisons of 2 different data were conducted using the Mann-Whitney U test and a p value less than 0.05 was considered statistically significant.

## Results

### Otomicroscopic findings

On day 7, in all groups, inflammatory response was as severe as in the control group, drum vessels were dilated, and tympanic membranes were thick and inflamed.

On day 21, in the antibiotic-treated group, in 8 ears of 7 rats, inflammatory response was less severe than in the infected groups, but more severe than in the antibiotic-montelukast co-treated and montelukast-treated groups.

In the antibiotic-montelukast co-treated group, in 9 ears of 6 rats, inflammatory response was least severe than in the infected groups and the antibiotic-only – treated group. Six ears showed no inflammatory sign on their tympanic membrane and 1 showed myringosclerosis.

In the montelukast-treated group, in 9 ears of 7 rats, inflammatory response was less severe than in the infected groups and the antibiotic-only – treated group. Six ears showed no inflammatory sign on their tympanic membrane and 3 ears showed effusion.

In the infected controls, in 9 ears of 6 rats, inflammatory response was as severe as on day 7. Tympanic membranes of 6 rats showed effusion, 2 of them showed retraction of TM, and only 1 was normal.

### Histological findings

In several areas of the middle ear and bulla, the inflammatory response of the mucosa showed a similar pattern and the degree of inflammatory response were recorded.

On day 7, 43 ears of 28 animals were histopathologically examined for 7 parameters: tympanic membrane thickness, vascularization, inflammation, mucosal thickness, vascularization, inflammation and secretory metaplasia. All groups had decreased mucosal vascularization when compared with the placebo group, but in other parameters, all groups showed similar changes (Tables 1 and 2).

When treated groups were compared with each other according to mucosal vascularization, there was not statistically significant difference between them (Table 3).

**Table 1.** For all parameters in the early period of the average scores obtained from four groups.

Findings	Group A	Group B	Group C	Group D
TM thickness	1.20±1.22	0.91±1.13	0.86±1.21	1.33±0.86
TM vascularization	0.10±0.31	0.27±0.64	0.43±0.78	0.56±0.52
TM inflammation	1.30±1.16	0.83±1.11	0.86±1.21	1.33±0.86
Mucosal thickness	2.00±1.0	1.75±0.86	0.78±1.20	1.78±0.66
Mucosal vascularization	0.55±0.52	0.75±0.62	0.67±0.86	1.67±0.50
Mucosal inflammation	1.82±0.75	1.58±0.66	1.44±1.04	1.78±0.66
Mucosal secretory metaplasia	0.64±0.67	0.92±0.28	0.56±0.52	0.78±0.44

Data are presented as mean ±SD. TM – tympanic membrane.

**Table 2.** Differences between groups in the early period parameters.

TM thickn.	TM vascul.	TM inflam.	Muco. thick.	Muco vascul.	Muco inflam.	Muc metapl.
0.631	0.196	0.467	0.068*	<b>0.005**</b>	0.619	0.299

\* p<0.05; \*\* p<0.01; TM – tympanic membrane.

In the early phase of inflammation, polymorphonuclear leucocytes were the dominant cells of inflammation.

On day 21, 38 ears of 26 animals were histopathologically examined for 7 parameters; tympanic membrane thickness, vascularization, inflammation, mucosal thickness, vascularization, inflammation, and secretory metaplasia (Table 4).

In all groups, no significant difference was found in tympanic membrane inflammation, tympanic membrane vascularization, and mucosal secretory metaplasia data (Table 5). In all groups, chronic inflammatory cells in the middle ear and fibrosis of tympanic membrane were observed, but in the control group, acute inflammatory cells were still observed in submucosal

**Table 3.** Early period to compare the groups in terms of mucosal vascularization.

Mucosa vascularization (P)	
Grups A-B	0.438
Grup A-C	0.933
Grup A-D	<b>0.001*</b>
Grup B-C	0.642
Grup B-D	<b>0.004*</b>
Grup C-D	<b>0.016*</b>

\* p<0.05.

**Table 4.** Groups for all parameters mean values obtained in the late period.

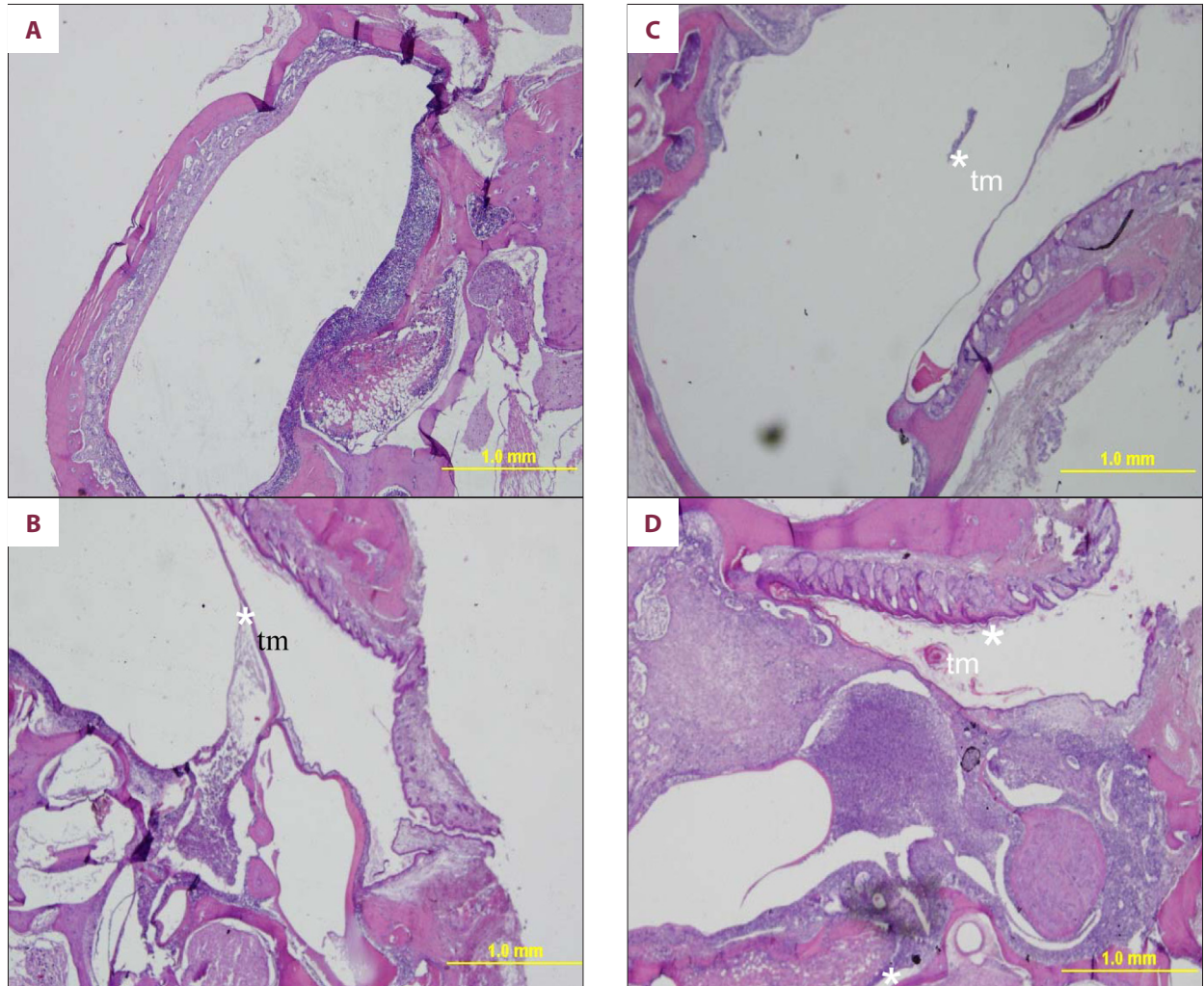
	Group A	Group B	Group C	Group D
TM thickness	1.00±0.00	0.88±0.64	0.82±0.60	2.00±0.70
TM vascularization	0.20±0.44	0.13±0.35	0.09±0.30	0.11±0.33
TM inflammation	0.80±0.44	0.63±1.00	0.45±0.93	1.22±0.66
M thickness	2.00±1.00	1.25±0.88	1.25±0.75	2.44±0.52
M vascularization	1.00±0.57	0.75±0.70	0.25±0.45	0.89±0.33
M inflammation	2.00±1.00	1.50±0.75	1.42±0.76	2.44±0.72
M secretory Metaplasia	0.71±0.48	0.63±0.51	0.92±0.51	0.89±0.60

Data are presented as mean ±SD; TM – tympanic membrane.

**Table 5.** Differences between groups in the late period parameters.

TM thick.	TM vasküla.	TM enflam.	Mucosa thick.	Mucos. vask.	Mukos. Enfla.	Mucos. metapl.
0.003**	0.944	0.054	0.007**	0.015*	0.036*	0.611

\* p<0.05; \*\* p<0.01; TM – tympanic membrane.



**Figure 1.** Microscopic appearances of the middle ears from different groups at 21<sup>st</sup> day of the experiment. (A) Penicillin-treated group: mild inflammation; (B) penicillin and montelukast co-treated group: minimal inflammation; (C) montelukast treated group: almost nearly no inflammation; (D) placebo group: severe inflammation. TM is thick. (: inflammation).

sections. Mucosal and tympanic membrane changes were found on day 21 in all groups (Figure 1).

All groups showed significant decrease in tympanic membrane thickness when compared with the control group (group A – p=0.010, group B – p=0.007, group C – p=0.002). But when antibiotic-treated, antibiotic and montelukast co-treated, and montelukast-treated groups were compared with each other, no significant difference was found (Table 6).

The antibiotic and montelukast co-treated group and the montelukast-treated group showed significant decreases in mucosal thickness when compared with the control group (p=0.007, p=0.002). In antibiotic-treated group, no significant difference was found when compared with the control group (p=0.361) (Table 6). But when all 3 treated groups were compared with each other, no significant differences were found in mucosal thickness.

In mucosal vascularization, there was a significant decrease in the montelukast-only-treated group when compared with the

**Table 6.** The groups differed significantly in terms indicating parameters compared to late periods.

	TM thickness	Mucosa thickness	Mucosa vasculari.	Mucosa inflammation
Grup A-B	0.620	0.144	0.428	0.308
Grup A-C	0.454	0.097	<b>0.010</b>	0.166
Grup A-D	<b>0.010</b>	0.361	0.641	0.358
Grup B-C	0.847	0.928	0.081	0.667
Grup B-D	<b>0.007</b>	<b>0.007</b>	0.507	<b>0.025</b>
Grup C-D	<b>0.002</b>	<b>0.002</b>	<b>0.005</b>	<b>0.009</b>

p<0.05.

antibiotic-only- treated group and the control group (p=0.010 and p=0.005, respectively). No significant difference in mucosal vascularization was found between the antibiotic-only treatment and the antibiotic-montelukast co-treatment groups, between the antibiotic-montelukast co-treatment and montelukast treatment groups, and between the antibiotic-montelukast co-treatment group and the control group.

In mucosal inflammation, there was a significant decrease in antibiotic-montelukast co-treatment and montelukast treatment group when compared with the control group (p=0.025 and p=0.009, respectively). There was no significant difference in the antibiotic-only treatment group when compared with the control group (p=0.358) (Table 6). When the 3 treatment groups were compared with each other, no significant difference was found. When all groups were compared with each other and with placebo on day 7 and 21, no significant difference was found in goblet cell metaplasia.

## Discussion

As reported previously [7,16], untreated experimental pneumococcal AOM in rats causes changes in the middle ear mucosa that persist for at least 6 months. The histological changes include a thickened mucosa, an increased number of glands, and the occurrence of ciliated cells. Beneficial effects on the mucosal changes were reported in experimental pneumococcal AOM when penicillin V was given prophylactically or used as an early treatment [8,17,18].

Thomassen et al. [8,17,18] demonstrated that penicillin clearly prevented epithelial cells from differentiating into goblet cells. The increased goblet cell density is conceivably a result of both hyperplasia (involving cell division) and metaplasia (involving cell differentiation). To our knowledge, few middle ear data exist on these aspects, but when the tracheo-bronchial epithelium is exposed to various noxious stimuli, new and perhaps pre-existing goblet cells proliferate by

division, and basal and indeterminate epithelial cells differentiate into goblet cells. The mechanisms leading to goblet cell hyperplasia, an epithelial cell metaplasia, are comparatively unknown, although several strong indications exist. Airway infection is accompanied by hypersecretion of mucus from goblet cells. In turn, loss of intracellular mucus to a critical level stimulates goblet cells to enter the cell cycle. Mediators of the inflammatory response to bacterial colonization also play a role, as elucidated by stimulation of goblet cell hyperplasia by neutrophil lysates, inhibition by corticosteroids and NSAIDs, and administration of antibiotics during middle ear infection. Specific mechanisms underlying these findings are partly due to products and metabolites of the cyclooxygenase and lipoxygenase pathways of arachidonic acid. These are activated through cell membrane release, induced by noxious and other agents released during inflammation. Prostaglandin E and eicosanoids are examples of such products, which have been shown to induce differentiation of epithelial cells to goblet cells and the release of mucous glycoproteins, possibly through a regulatory mechanism mediated by cyclic adenosine monophosphate. But in our study, goblet cell metaplasia in mucosa was not statically significant in any group compared with infected controls.

Although clinical trials proving the efficiency of this combination therapy in inflammatory diseases have been reported in the literature, the effect of combination therapy with antibiotics and montelukast in experimental AOM has not yet been investigated. Cumbs et al. [4] demonstrated that combination treatment with antibiotics and montelukast in clinical treatment showed a significantly beneficial effect on acute otitis media, compared with an antibiotic-treated group.

Cysteinyl leukotrienes (CysLTs) are being increasingly implicated in the etiology of acute and chronic inflammatory diseases of nonallergic origin, including cardiovascular diseases, autoimmune diseases, and certain malignancies. The spectrum of proinflammatory activities of CysLTs may therefore extend beyond eosinophils, monocytes/macrophages, type 2 helper

T (Th2) lymphocytes, and airway smooth muscle cells, to other types of inflammatory cells such as neutrophils.

Montelukast inhibits physiological actions of LTD4 at the CysLT1 receptor without any agonist activity. It also exerts a substantial and apparently direct inhibitory effect on 5-lipoxygenase activity *in vitro*. Thus, montelukast decreases vascular permeability, inhibits inflammatory cell activation, smooth muscle proliferation, and bronchoconstriction and activates mucociliary clearance.

Ganbo et al. [12] showed that in guinea pigs, LTD4 progressively inhibits ciliary activity, but PGE2 promoted it. Leukotriene C4 also induced ciliary inhibition. This may be another means by which montelukast decreases the duration of middle ear effusion after AOM.

The results of this study indicate that montelukast may have a place in the medical management of AOM. Acute otitis media commonly presents with only a partial effusion, and spontaneous resolution of the effusion generally occurs in about 50% of ears within 1 month. Full effusion occurs only about 30% of the time. A full effusion is not only more durable than a partial effusion; it is also more predictive of a clinically important conductive hearing impairment. Unilateral conductive hearing loss is not nearly as debilitating as a bilateral

impairment. Montelukast may prove to be most appropriate and cost effective for a small subset of AOM patients with bilateral disease and full effusions.

## Conclusions

The present study was performed in rats. Thus, it is not possible to generalize these findings to humans. However, it is obvious that earlier studies did not show effects of penicillin or montelukast different from placebo. This agrees with the results of previous studies. This is probably related to the fact that the accumulating effects of the antibiotic, as well as the leukotriene antagonist (montelukast sodium), become beneficial 7 to 10 days after the inoculation (inflammation). However, the results of this study clearly show that the beneficial effects of the antibiotic (penicillin), as well as the leukotriene antagonist (montelukast), are statistically different from those of placebo in AOM in rats. When the parameters of inflammation in the rat middle ear were compared with each other, most of these parameters did not show any statistically different beneficial effects in montelukast and penicillin groups.

## Conflict of interests

The authors declare no conflict of interests.

## References:

1. Sutbeyaz Y, Yakan B, Ozdemir H et al: Effect of SC-41930, a potent leukotriene B4 receptor antagonist, in the guinea pig model of middle ear inflammation. *Ann Otol Rhinol Laryngol*, 1996; 105: 476–80
2. Aladag İ, Guven M, Eyibilen A et al: Efficacy of vitamin A in experimentally induced acute otitis media. *Int J Pediatr Otorhinolaryngol*, 2007; 71: 623–28
3. Shurin PA, Pelton SI, Klein JO et al: Persistence of middle-ear effusion after acute otitis media in children. *N Engl J Med*, 1979; 300: 1121–23
4. Combs JT: The effect of Montelukast sodium on the duration of effusion of otitis media. *Clinic pediatri (Phila)*, 2004; 43: 529–33
5. Park SN, Yeo SW: Effects of antibiotics and steroid on middle ear mucosa in rats with experimental acute otitis media. *Acta Otolaryngol*, 2001; 121: 808–12
6. Hermansson A, Prellner K, Hellström S: Persistent structural changes in the middle ear mucosa of the rat, after an experimentally induced episode of pneumococcal otitis media. *Acta Otolaryngol*, 1990; 109: 421–30
7. Hermansson A, Hellstrom S, Prellner K: Mucosal changes induced by experimental pneumococcal otitis media are prevented by penicillin V. *Otolaryngol Head Neck Surg*, 1991; 105: 578–85
8. Caye-Thomasen P, Hermansson A, Tos M et al: Penicillin reduces secretory capacity in rat middle ear mucosa in acute otitis media. *Am J Otol*, 1996; 17: 354–59
9. Barnes PJ: Pathophysiology of allergic inflammation. In: Middleton E Jr, Reed CE, Ellis EF et al. (eds.), *Allergy Principles and Practice*, 4<sup>th</sup> ed. St Louis: Mosby, 1993; 243–66
10. Brodsky L, Faden H, Bernstein J et al: Arachidonic acid metabolites in middle ear effusion in children. *Ann Otol Rhinol Laryngol*, 1991; 100: 589–92
11. Sabater JR, Wanner A, Abraham WM: Montelukast prevents antigen-induced mucociliary dysfunction in sheep. *Am J Respir Crit Care Med*, 2002; 166: 1457–60
12. Ganbo T, Hisamatsu K, Shimomura S et al: Inhibition of mucociliary clearance of the Eustachian tube by leukotrienes C4 and D4. *Ann Otol Rhinol Laryngol*, 1995; 104: 231–36
13. Bisgaard H, Pederson M: SRS-A leukotrienes decrease the activity of human respiratory cilia. *Clin Allergy*, 1987; 17: 95–103
14. Tachibana F, Shimada T, Hori Y et al: Platelet activation factor and leukotrienes in acute otitis media, secretory otitis media and chronic otitis media on the acute exacerbation. *Auris Nasus Larynx*, 1996; 23: 20–25
15. Van Adelsberg J, Philip G, LaForce CR et al: Randomized controlled trial evaluating the clinical benefit of montelukast sodium for treating seasonal allergic rhinitis. *Ann Allergy Asthma Immunol*, 2003; 90: 214–22
16. Fayle-Ansson M, White P, Hermansson A et al: Otomicroscopic findings systemic interleukin-6 levels in relation to etiologic agent during experimental acute otitis media. *APMIS (Denmark)*, 2006; 114: 285–91
17. Caye-Thomasen P, Hermansson A, Tos M et al: Changes in mucosal goblet cell density in acute otitis media caused by non-typeable *Haemophilus influenzae*. *Acta Otolaryngol*, 1998; 118: 211–15
18. Caye-Thomasen P, Hermansson A, Tos M, Prellner K: Increased secretory capacity of the middle ear mucosa after acute otitis media caused by *Haemophilus influenzae* type B. *Otolaryngol Head Neck Surg*, 1997; 117: 263–67