



Case report

Concurrent *Clostridium septicum* bacteremia and colorectal adenocarcinoma with metastasis to the brain – A Case Report



David Chirikian^{a,*}, Sohun Awsare^a, John Fitzgibbon^a, Lenora Lee^b

^a California Northstate University College of Medicine, 9700 West Taron Drive, Elk Grove, CA, 95757, USA

^b Department of Infectious Disease, Kaiser Permanente Sacramento Medical Center, 2025 Morse Avenue, Sacramento, CA, 95825, USA

ARTICLE INFO

Article history:

Received 4 November 2020

Accepted 10 June 2021

Keywords:

Colorectal malignancy

Bacteremia

Brain metastasis

Adenocarcinoma

Clostridium septicum

ABSTRACT

There is a known relationship between *Clostridium septicum* bacteremia and colorectal malignancies. *C. septicum* is a gram-positive, anaerobic, spore-forming bacterium that can survive the acidic colorectal tumor microenvironment, where it is thought to enter the blood by tumor-mediated epithelial tissue damage. While in circulation, *C. septicum* can release exotoxins which may lead to life-threatening sepsis. The patient in this case presented with a mild fever, abdominal pain, and left hand weakness. Imaging of the head and abdomen revealed a right frontal lucency and wall thickening of the ascending colon. Two colonic adenocarcinomas were found and removed via an exploratory laparotomy and right hemicolectomy. The blood culture was positive for *C. septicum*. Brain MRI confirmed a right frontal mass concerning for metastasis. Here, we discuss the relationship between colonic cancers and *Clostridium septicum* bacteremia.

© 2021 Published by Elsevier Ltd. This is an open access article under the CC BY-NC-ND license (<http://creativecommons.org/licenses/by-nc-nd/4.0/>).

Introduction

There is a known relationship between certain inflammatory microbes and colon cancer. The strongest association is with infection of *Streptococcus bovis/galloyticus*, a gram-positive organism, which can cause endocarditis, sepsis, and bacteremia [1]. Less commonly, *Clostridium septicum*, *Fusobacterium nucleatum*, *Bacteroides fragilis*, enterococci, and streptococci species have also been linked with gastrointestinal malignancies [2,3]. *C. septicum* is an opportunistic anaerobe that has been associated with other conditions, including hematological malignancies, diabetes mellitus, neutropenia, and immunosuppression [3]. Additionally, *C. septicum* bacteremia is often severe, having a mortality rate of greater than 60% [4], and can cause an array of clinical symptoms including atraumatic myonecrosis, aortitis, and gas gangrene [4]. Here, we describe a case of a 95-year-old patient with colonic adenocarcinoma with metastases to the brain and concurrent *C. septicum* bacteremia.

Case report

A 95-year-old female presented to the Emergency Department with a chief complaint of abdominal pain and associated left-handed weakness. She stated the abdominal pain had persisted for several days with accompanying nausea without vomiting. She reported no chest pain, SOB or headache. On physical exam, there was diffuse tenderness and guarding of the abdomen with normal bowel sounds. Additionally, there was decreased grip strength in the left hand compared to the right while sensation was intact and symmetric. She presented as hypotensive with a blood pressure of 100/75, an elevated WBC of 50.9 K/ul and decreased hemoglobin (6.8 g/dL). The patient was transfused with 2 units of blood. Her troponin level increased from 0.17 ng/mL to 0.24 ng/mL over 24 h. Her NIHSS score was 1. Computed topography scan of the head indicated a probable subacute infarct of the right frontal lobe which on a subsequent Magnetic Resonance Imaging of the head revealed small bilateral acute infarcts along with findings in the right frontal lobe that were suspicious for malignancy (Fig. 1). CT of the abdomen revealed bowel wall thickening of the ascending colon with suspicion of focal perforation, loculated extraluminal air density medial to the ascending colon, and mild pericolic fat stranding (Figs. 2, 3). An exploratory laparotomy and right hemicolectomy were performed. During surgery, she had a

* Corresponding author.

E-mail addresses: david.chirikian3831@cnsu.edu (D. Chirikian), sohun.awsare6247@cnsu.edu (S. Awsare), john.fitzgibbon@cnsu.edu (J. Fitzgibbon), Lenora.w.lee@kp.org (L. Lee).

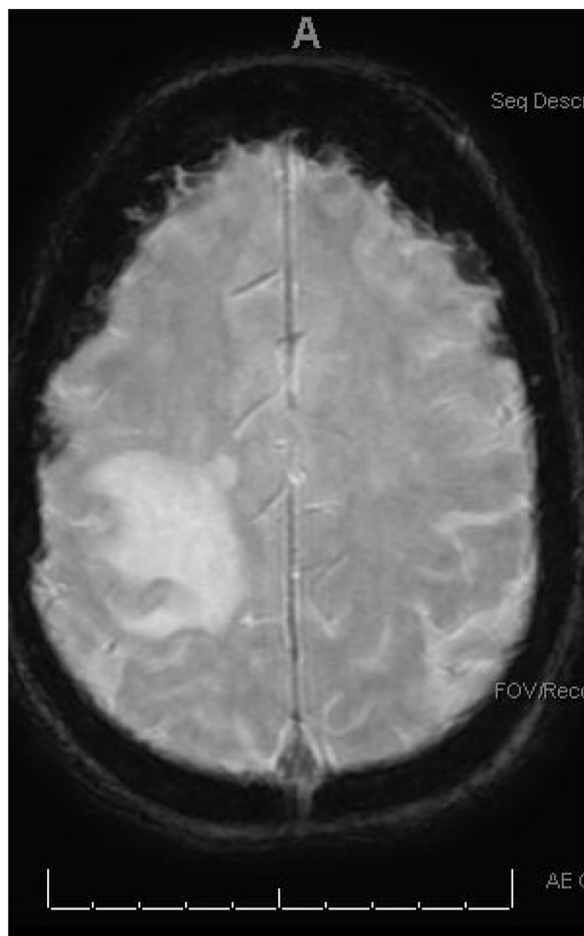


Fig. 1. MRI of the right frontal parietal 1.2 cm mass concerning for malignancy and metastatic disease.

perforated ascending colon cancer with perforation into Gerota's fascia. Mild purulence in the paracolic gutter was noted. She had two synchronous colonic adenocarcinomas invading through the muscularis propria into the pericolic fat. The first mass was a 4.5 cm moderately differentiated adenocarcinoma adjacent to the ileocecal valve. The second mass was a 5.5 cm poorly differentiated adenocarcinoma with extensive mucinous differentiation and singlet ring forms located in the ascending colon. Metastatic carcinoma was present in 3 lymph nodes. The tumor stained positive for CD20 and CDX2. Blood cultures from admission were positive for gram variable rods and *C. septicum* was isolated. Given the findings on MRI and the high suspicion for metastatic colonic malignancy, the patient was placed on hospice and discharged home.

Discussion

The genus *Clostridium* is composed of gram-positive, anaerobic, spore-forming bacilli with many species playing a commensal role in the human gastrointestinal tract [5]. However, some *Clostridia*, such as *Clostridium difficile* and *Clostridium perfringens*, cause inflammatory disorders that alter normal gastrointestinal physiology [5]. Additionally, some *Clostridia* cause opportunistic infections leading to fatal conditions such as botulism, gas gangrene, or tetanus [6].

Clostridium septicum is associated with colorectal cancer [7]. Colorectal tumors produce an acidic microenvironment through tumor anaerobic metabolism, and it is thought that *C. septicum* can

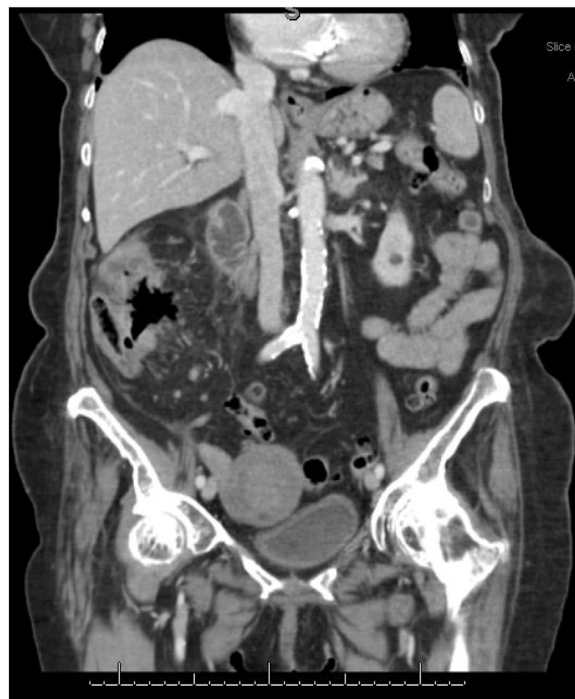

Fig. 2. Coronal Computed Topography of Abdomen with Focal Perforation and Loculated Extraluminal Air Density.

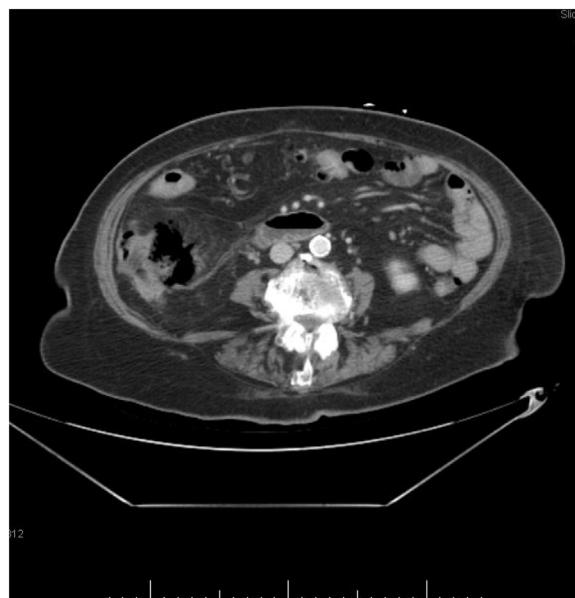


Fig. 3. Axial Computed Topography of Abdomen with Focal Perforation and Loculated Extraluminal Air Density.

survive due to its anaerobic and spore-forming properties [8,9]. Perforation of the gastrointestinal or colorectal epithelium allows *C. septicum* spores to enter the blood where it can cause bacteremia and life-threatening sepsis [4,9]. *C. septicum* produces several exotoxins, including alpha toxin, which is thought to be an essential virulence factor [10]. However, the exact pathophysiology of *C. septicum* infection is still unknown.

C. septicum infection can present with a spectrum of clinical findings including cellulitis, fasciitis, myonecrosis, abscess, aortitis, aortic aneurysm, hemolysis, or septic shock [11]. Nonspecific symptoms of *C. septicum* infection include abdominal pain, fever,

and malaise [11]. As stated previously, *C. septicum* infection is associated with concurrent colorectal and hematological malignancies. One study found that over a 3-year period, 7 out of 7 patients with *C. septicum* gangrene or sepsis had concurrent malignancies: 4 had colon adenocarcinomas, 3 had acute myeloblastic leukemias, and 1 had a breast carcinoma [12].

Given the high mortality rates of untreated *C. septicum* infection, early diagnosis and treatment are necessary. The treatment for *C. septicum* bacteremia consists of antibiotics and surgical debridement. Penicillin G or piperacillin/tazobactam are considered first-line treatments [13,14]. Metronidazole, clindamycin, tetracycline, cefoxitin, and imipenem/cilastatin should be considered if the patient has a penicillin allergy [13,14].

Colorectal adenocarcinomas are malignant gland-forming neoplasms that originate from the colorectal mucosa [15] and considered to be one of the leading causes of cancer-related deaths in the United States [16,17]. Worldwide, colorectal cancer is the third most commonly diagnosed cancer in men and second most common in females. Within the United States, there are an estimated 104,610 incidences in 2020 with a mortality rate of 51% [16]. Colorectal cancer has known locations of metastasis within the peritoneum [18]. Uncommonly, however, colon cancer has been shown to metastasize to locations outside the peritoneum. In one population study, the incidence of brain metastasis was 1.38% for over 192,000 incidences of metastatic colon cancer [19]. In another study, patients undergoing a segmental colonic resection were reviewed for metastasis and concluded that patients undergoing right sided colectomies had a lower overall rate of metastasis and brain metastasis was less than 3% of the patients [20].

C. septicum causes a rare and often lethal infection that needs to be diagnosed and treated with early and aggressive surgical and antibiotic intervention. If a patient presents with signs and symptoms of *C. septicum* bacteremia, one should suspect an underlying hematological or colonic malignancy. Positive blood cultures for *C. septicum* warrant further investigation with colonoscopy or imaging to search for concurrent malignancies.

Funding sources

No funding sources to be reported.

Consent

The patient described in this paper (or her guardians) has given written, informed consent to publish her case, radiographic images, and pathological reports. The research in this paper was conducted ethically in accordance with the World Medical Association Declaration of Helsinki.

Author contributions

Sohun Awsare and David Chirikian equally contributed to reviewing the patient chart, conducting a literature review and drafting the manuscript. Dr. John Fitzgibbon and Dr. Lenora Lee reviewed literature and revised the manuscript.

Declaration of Competing Interest

The authors report no declarations of interest.

Acknowledgement

We thank all members of our research team for their assistance with this project.

References

- [1] Abdulmir AS, Hafidh RR, Abu Bakar F. The association of Streptococcus bovis/galloyticus with colorectal tumors: the nature and the underlying mechanisms of its etiological role. *J Exp Clin Cancer Res* 2011;30(11).
- [2] Dahmus JD, Kotler DL, Kastenberg DM, Kistler CA. The gut microbiome and colorectal cancer: a review of bacterial pathogenesis. *J Gastrointest Oncol* 2018;9(4):769–77, doi:<http://dx.doi.org/10.21037/jgo.2018.04.07>.
- [3] Mirza NN, McCloud JM, Cheatham MJ. Clostridium septicum sepsis and colorectal cancer – a reminder. *World J Surg Oncol* 2009;6(October (7)):73.
- [4] Nanjappa S, Shah S, Pabbathi S. Clostridium septicum gas gangrene in colon cancer: importance of early diagnosis. *Case Rep Infect Dis* 2015;2015:694247, doi:<http://dx.doi.org/10.1155/2015/694247>.
- [5] Lopetuso LR, Scaldaferrri F, Petito V, Gasbarrini A. Commensal Clostridia: leading players in the maintenance of gut homeostasis. *Gut Pathog* 2013;5(1) 23, doi:<http://dx.doi.org/10.1186/1757-4749-5-23> Published 2013 Aug 13.
- [6] Wells CL, Wilkins TD. Clostridia: sporeforming anaerobic bacilli. In: Baron S, editor. *Medical microbiology*. 4th edition Galveston (TX): University of Texas Medical Branch at Galveston; 1996 Chapter 18. Available from: <https://www.ncbi.nlm.nih.gov/books/NBK8219/>.
- [7] Hermsen JL, Schurr MJ, Kudsk KA, Faucher LD. Phenotyping Clostridium septicum infection: a surgeon's infectious disease. *J Surg Res* 2008;148(1):67–76.
- [8] Dahmus JD, Kotler DL, Kastenberg DM, Kistler CA. The gut microbiome and colorectal cancer: a review of bacterial pathogenesis. *J Gastrointest Oncol* 2018;9(4):769–77, doi:<http://dx.doi.org/10.21037/jgo.2018.04.07>.
- [9] Khan AA, Davenport K. A reminder of the association between Clostridium septicum and colonic adenocarcinoma. *Int Semin Surg Oncol* 2006;3:12.
- [10] Kennedy CL, Krejany EO, Young LF, O'Connor JR, Awad MM, Boyd RL, et al. The alpha-toxin of Clostridium septicum is essential for virulence. *Mol Microbiol* 2005;57(5):1357–66, doi:<http://dx.doi.org/10.1111/j.1365-2958.2005.04774.x> PMID: 16102005.
- [11] Mao E, Clements A, Feller E. Clostridium septicum sepsis and colon carcinoma: report of 4 cases. *Case Rep Med* 2011;2011:248453, doi:<http://dx.doi.org/10.1155/2011/248453>.
- [12] Katlic MR, Derkac WM, Coleman WS. Clostridium septicum infection and malignancy. *Ann Surg* 1981;193(3):361–4, doi:<http://dx.doi.org/10.1097/0000658-198103000-00020>.
- [13] Stevens DL, Aldape MJ, Bryant AE. Life-threatening clostridial infections. *Anaerobe* 2012;18(2):254–9.
- [14] Panikkath R, Konala V, Panikkath D, Umyarova E, Hardwicke F. Fatal Clostridium septicum infection in a patient with a hematological malignancy. *Proc (Bayl Univ Med Cent)* 2014;27(2):111–2, doi:<http://dx.doi.org/10.1080/08998280.2014.11929074>.
- [15] Fleming M, Ravula S, Tatishchev SF, Wang HL. Colorectal carcinoma: pathologic aspects. *J Gastrointest Oncol* 2012;3(3):153–73, doi:<http://dx.doi.org/10.3978/j.issn.2078-6891.2012.030>.
- [16] Siegel RL, Miller KD, Goding Sauer A, Fedewa SA, Butterly LF, Anderson JC, et al. Colorectal cancer statistics, 2020. *CA Cancer J Clin* 2020;70(3):145–64, doi:<http://dx.doi.org/10.3322/caac.21601> Epub 2020 Mar 5. PMID: 32133645.
- [17] Siegel RL, Miller KD, Jemal A. Cancer statistics, 2020. *CA Cancer J Clin* 2020;70(1):7–30, doi:<http://dx.doi.org/10.3322/caac.21590>.
- [18] Riihimäki Matias, Hemminki A, Sundquist J, Hemminki K. Patterns of metastasis in colon and rectal cancer. *Sci Rep* 2016;6(July (15)):29765, doi:<http://dx.doi.org/10.1038/srep29765>.
- [19] Lei S, Ge Y, Tian S, Cai B, Gao X, Wang N, et al. Colorectal cancer metastases to brain or bone and the relationship to primary tumor location: a population-based study. *J Gastrointest Surg* 2020;24(8):1833–42, doi:<http://dx.doi.org/10.1007/s11605-019-04308-8> Epub 2019 Jul 16. PMID: 31313144.
- [20] Amri R, Bordeianou LG, Sylla P, Berger DL. Variations in metastasis site by primary location in colon cancer. *J Gastrointest Surg* 2015;19(8):1522–7, doi:<http://dx.doi.org/10.1007/s11605-015-2837-9>.