



A new species of *Eimeria* Schneider, 1875 from the Serra dos Órgãos National Park, Rio de Janeiro, Brazil, with notes on its endogenous development in the montane grass mouse, *Akodon montensis* Thomas, 1913 (Rodentia: Sigmodontinae)

Marcos Tobias de Santana Miglionico^{1,5} · Lúcio André Viana² · Helene Santos Barbosa³ · Ester Maria Mota⁴ · Sócrates Fraga da Costa Neto^{1,5} · Edwards Frazão-Teixeira^{1,3} · Paulo Sergio D'Andrea^{1,5}

Received: 10 October 2017 / Accepted: 1 December 2017 / Published online: 11 December 2017
© The Author(s) 2017. This article is an open access publication

Abstract

A total of 53 specimens of the montane grass mouse, *Akodon montensis* Thomas, 1913 were collected in the Serra dos Órgãos National Park (SONP) in November 2014 and July 2015. The fecal material was analyzed, and a prevalence of 7.5% was recorded for a new coccidian species of the genus *Eimeria* Schneider, 1875, with part of its endogenous development recorded in the small intestine. The oocysts of a new coccidian species of genus *Eimeria* are ellipsoidal to subspherical. The wall is bilayered, c. 1.5 μm (1.3–1.6 μm) thick, outer layer rough. Oocyst ($n = 126$) mean length is 25.3 μm (21.0–28.0 μm), with a width of 20.2 μm (17.0–22.0 μm) and mean length/width (L:W) ratio of 1.3 (1.2–1.4). Polar granule is present, with the oocyst residuum as a large spherical to subspherical globule. Sporocyst shape ($n = 126$) is ellipsoidal, with a mean length of 11.8 μm (9.3–14.4 μm), width of 7.9 μm (6.7–9.3 μm), and mean L:W ratio of 1.5 (1.4–1.7). Sporocysts with nipple-like Stieda body and sub-Stieda body are absent. A sporocyst residuum formed by several globules, usually along the sporocyst wall. This is the first record of *Eimeria* in the montane grass mouse from Brazil.

Keywords Rodents · Coccidia · *Akodon montensis* · Atlantic Forest · Histopathology · Cricetidae

Introduction

Eimeria spp. are protozoan parasites with worldwide distribution that might cause enteritis in many vertebrate species

(Duszynski and Upton 2001). In Brazil, only three species are known to infect Sigmodontinae rodents: *Eimeria oryzomyi* Carini, 1937 from specimens of Oryzomyini rodents; *Eimeria zygodontomyis* Lainson and Shaw, 1990 in *Zygodontomys lasiurus* [= *Necromys lasiurus* (Lund, 1840)], and *Besnoitia akodoni* Dubey, Sreekumar, Rosenthal, Lindsay, Grisard and Vitor, 2003 in *Akodon montensis*.

The rodent family Cricetidae has 130 genera encompassing 681 species, 55 of which are endemic in Brazil. The cricetid genus *Akodon* Meyen, 1833 has 44 species distributed throughout South America (Musser and Carlenton 2005), with 10 species being found in Brazil, on the east coast between Paraíba and Rio Grande do Sul, and inland in highland areas of Minas Gerais, and in the southwest of the state of Mato Grosso do Sul (Bonvicino et al. 2008). The ecology and taxonomy of some common *Akodon* species are well known. They are found in a range of different environments, both pristine and impacted, in addition to their epidemiological importance, as reservoirs of zoonoses (Oliveira et al. 2012; Müller et al. 2013; Teixeira et al. 2014). Four species are

✉ Marcos Tobias de Santana Miglionico
miglionio@gmail.com

¹ Programa de Pós-Graduação em Biodiversidade e Saúde, Instituto Oswaldo Cruz/Fiocruz, Rio de Janeiro, RJ 21040-360, Brazil
² Departamento de Ciências Biológicas e da Saúde, Universidade Federal do Amapá, Macapá, AP 68903-419, Brazil
³ Laboratório de Biologia Estrutural, Instituto Oswaldo Cruz/Fiocruz, Rio de Janeiro, RJ 21040-360, Brazil
⁴ Laboratório de Patologia, Instituto Oswaldo Cruz/Fiocruz, Rio de Janeiro, RJ 21040-360, Brazil
⁵ Laboratório de Biologia e Parasitologia de Mamíferos Silvestres Reservatórios, Instituto Oswaldo Cruz/Fiocruz, Rio de Janeiro, RJ 21040-360, Brazil

found in the Brazilian state of Rio de Janeiro—*Akodon cursor* (Winger, 1887), *Akodon serrensis* (Thomas, 1902), *Akodon paranaensis* Christoff et al., 2000, and *Akodon montensis* Thomas, 1913 (Paglia et al. 2012). These rodents are terrestrial insectivore-omnivores (Graipel et al. 2003).

The present study describes a new species of *Eimeria*, with notes on its endogenous development in the montane grass mouse, *Akodon montensis*.

Material and methods

Study area

The study area encompasses a continuous tract of well-preserved Brazilian Atlantic Forest, isolated from human settlements or urban zones. The rodents were captured in the Serra dos Órgãos National Park (SONP), in the municipality of Petrópolis, Rio de Janeiro State, Brazil (22° 27' 49" S, 43° 05' 14.09" W). This park is located near the center of the Serra do Mar Ecological Corridor (Aguiar et al. 2005) and is one of the principal remnants of Atlantic Forest in the state of Rio de Janeiro.

Capture of the rodents

Rodents were captured in November 2014 and July 2015 along ten transects in each expedition. The specimens were captured in Tomahawk® (16 × 5 × 5 in.) and Sherman® traps set on the ground, a total of 90 live traps set per day. Additionally, 20 pitfall traps, made of 100-l buckets, were buried in the ground, along four transects, a capture effort of 80 pitfalls traps set per day. Each trapping session lasted for ten consecutive days. All animals were captured alive and euthanized a posteriori for sample collection. Voucher specimens were deposited in the scientific collection of the National Museum (Museu Nacional) at the Universidade

Federal do Rio de Janeiro (UFRJ). All the samples were collected during the Rede Bioma (Biome Network) project “Inventories: Patterns of Diversity, Biogeography, and Endemism of Mammals, Birds, Amphibians, Fruit Flies, and Parasites in the Atlantic Forest,” which is supported by a consortium of Brazilian research agencies, financed by CNPq PPBio Rede Bioma.

Collection and morphological analyses of oocysts

Samples were collected during necropsy, directly from the large intestine. The fecal material was placed in a 15-ml conical centrifuge tube containing a 2.5% (w/v) solution of K₂Cr₂O₇ and maintained at room temperature. On five consecutive days, the tube was opened and the solution was stirred vigorously to oxygenate it and promote the sporulation of any oocyst present in the faeces. The samples were processed in a saturated sugar solution by the centrifugal flotation method (Sheather's method), placed on slides examined under a microscope at a magnification of × 400 (Duszynski and Wilber 1997). Morphological observations and measurements were obtained using a Carl Zeiss Axio Scope.A1 binocular microscope with an apochromatic oil immersion objective lens and AxioVision imaging system. The oocysts were examined with an Imager.A2 light microscope Zeiss equipped with Nomarski interference contrast microscopy × 100 objective lenses, and the images captured with an AxioCam MRc. All measurements are given as the mean value in micrometers, followed by the range of values in parentheses.

Histopathological analysis

To determine the site of infection, the small intestines of specimens positive for oocysts in their feces were segmented and fixed overnight in Carson Millonig formalin. The tissue samples were subsequently dehydrated in a progressive series of ethyl alcohol concentrations, diaphonized using xylol, and

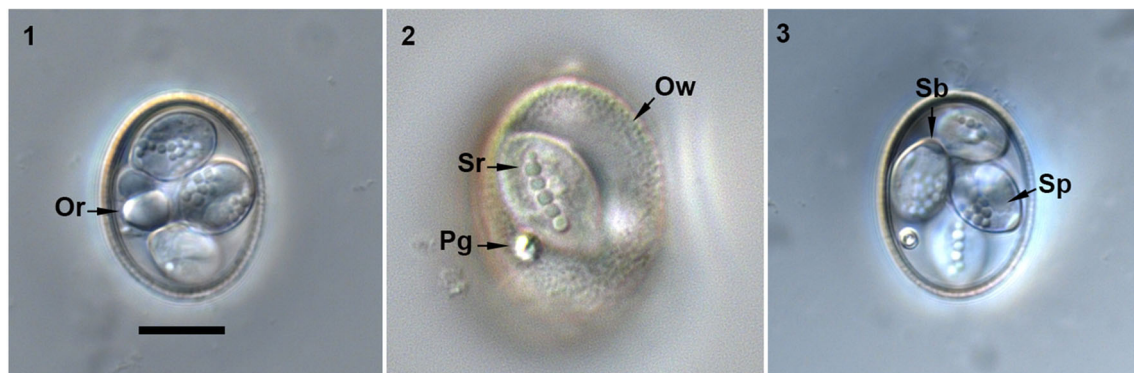


Fig. 1–3 Nomarski interference-contrast photomicrographs of *Eimeria akodonensis* n. sp. from the montane grass mouse, *Akodon montensis*. Presence of oocyst residuum (Or) and highly refractile polar granule (Pg);

Sporocyst residuum (Sr); wall (Ow); Stieda body (Sb); sporozoite (Sp). Scale bar = 10 μm

4

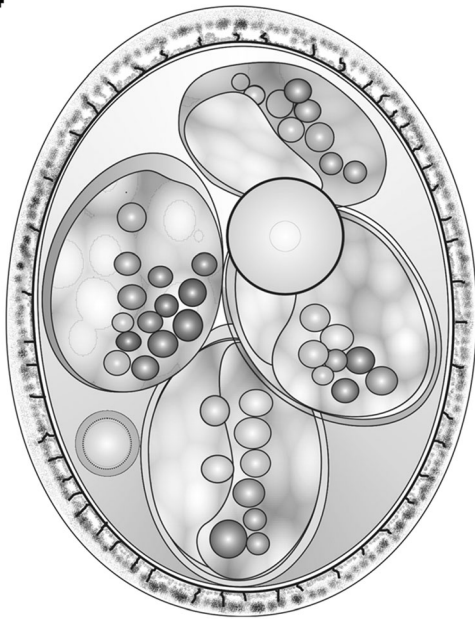


Fig. 4 Composite line drawing of the sporulated oocyst of *Eimeria akodonensis* n. sp. Scale bar = 10 μ m

then embedded in paraffin blocks for the preparation of serial sections of 5 μ m. The tissue sections were stained with hematoxylin and eosin and examined under a light microscope Carl

Zeiss (Humason 1979). The developmental stages were photographed and measured, and then analyzed qualitatively and described based on the scheme of Kheysin (2013).

Results

Four (7.5%) of the 53 *A. montensis* specimens analyzed were infected by an undescribed form of *Eimeria*. The histological analyses revealed the endogenous stages of the parasite in the small intestine of the mice, including the presence of macrogametocytes, microgametocytes, zygotes, and oocysts.

Eimeria akodonensis n. sp.

Type host: *Akodon montensis* Thomas, 1913 (Rodentia: Sigmodontinae), Symbiotype host (Frey et al. 1992), skin and skeleton, deposited in the National Museum of Rio de Janeiro (adult males, MNRJ nos. 83768, 83774, 83776, 83777).

Type-locality: Serra dos Órgãos National Park in Petrópolis, in the state of Rio de Janeiro, Brazil (22° 27' 49" S, 43° 05' 14.09" W).

Type-material: The oocysts were preserved in 70% ethanol, based on Duszynski and Gardner (1991). The samples were deposited in the Parasite Collection of the Department of Animal Parasitology (<http://r1.ufrj.br/lcc>) at the Federal Rural University of Rio de Janeiro, in Seropédica, Rio de

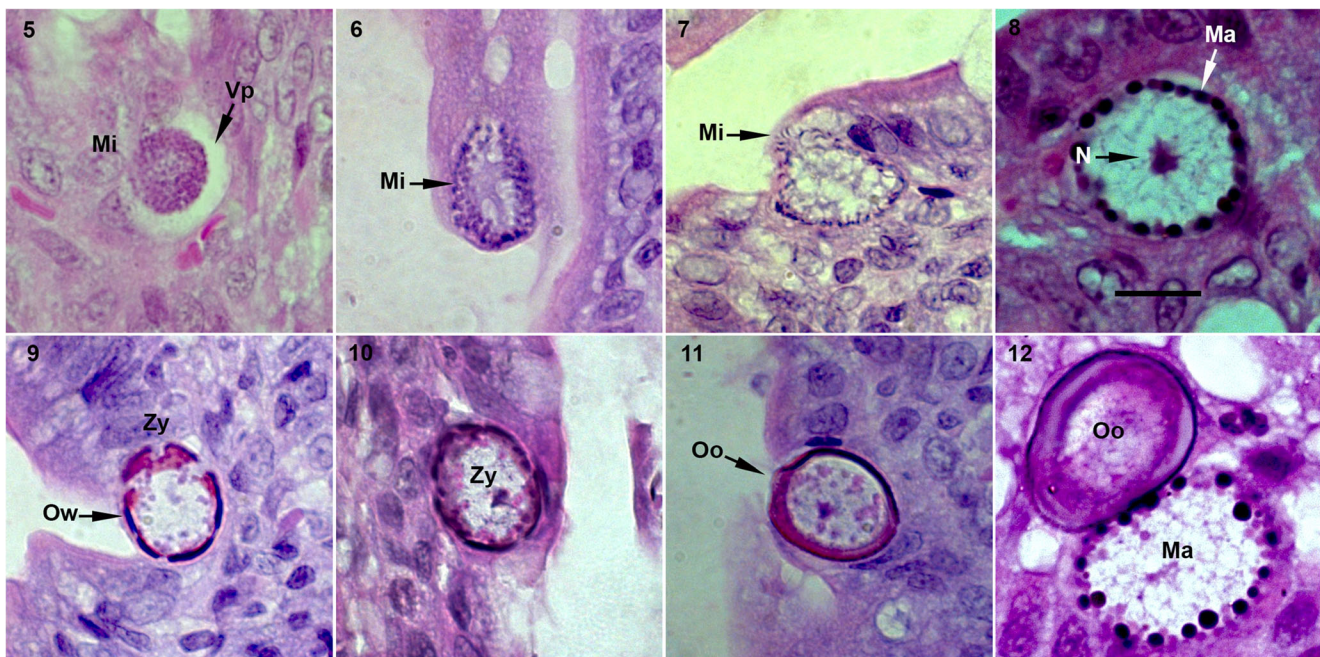


Fig. 5–12 Light micrographs of the endogenous stages of *Eimeria akodonensis* n. sp. observed in the lamina propria of the small intestine of *Akodon montensis*, showing the microgametes (Mi) and the parasitophorous vacuole in the host cell (Vp); microgametes (Mi);

macrogametes (Ma); nucleus (N) and the zygote (Zy) with wall-forming bodies arranged around its periphery (Ow); oocyst (Oo). Scale bar = 10 μ m

Janeiro, Brazil. Phototypes and line drawings were deposited together with the specimens. The catalog number is P-77/2017.

Sporulation time: Unknown.

Site of infection: Small intestine.

Prevalence: 4 of 53 (7.5%).

Etymology: The specific epithet is derived from the name of the host genus.\

Exogenous stage

Description (Figs. 1–3 and 4)

Sporulated oocyst

Oocyst shape ($n = 126$) is ellipsoidal to subspherical, wall bi-layered, $1.5 \mu\text{m}$ (1.3–1.6) thick, outer layer rough. Oocyst length is $25.3 \mu\text{m}$ (21.0–28.0), with a width of $20.2 \mu\text{m}$ (17.0–22.0) and length/width (L/W) ratio of 1.3 μm (1.2–1.4). Polar granule is present, with oocyst residuum as a large spherical to subspherical globule.

Sporocyst

Sporocyst shape ($n = 126$) is ellipsoidal with length of $11.8 \mu\text{m}$ (9.3–14.4), width of $7.9 \mu\text{m}$ (6.7–9.3), and (L/W) ratio of 1.5 μm (1.4–1.7). Sporocysts with nipple-like Stieda body and sub-Stieda body are absent. A sporocyst residuum formed by several globules, usually along the sporocyst wall.

Endogenous stages

Description (Fig. 5–12)

The histological analysis revealed the endogenous development of the parasite in the jejunum portion of the small intestine. The infected cells of the lamina propria contained only parasites in the gametogenic phase, with the immature microgametocytes being enveloped by the parasitophorous vacuole, and having a rounded shape, approximately $10.9 \mu\text{m}$ (5.4–16.8) in length and $11.8 \mu\text{m}$ (5.5–17.3) in width (Fig. 5). Free immature micro-gametocytes and microgametes were also observed (Figs. 6–7), as were macrogametes at different stages of development, including the formation of the oocyst wall from the granules, approximately $20.9 \mu\text{m}$ (15.9–25.7) in length and $16.2 \mu\text{m}$ (12.6–19.9) in width, subspherical to ellipsoidal in shape (Figs. 8–10). Mature and immature oocysts were also observed (Figs. 11–12).

Discussion

In Brazil, the coccidian diversity found in wild rodents is still poorly known, since only three species were reported infecting rodents of the subfamily Sigmodontinae (Rodentia: Cricetidae): *Eimeria oryzomyisi* from specimens of *Oryzomyini* rodents (Carini 1937), *Eimeria zygodontomyis* in *Necromys lasiurus* (Lainson and Shaw 1990), and *Besnoitia akodoni* in *Akodon montensis* (Dubey et al. 2003). In Venezuela, *Eimeria akodoni* was described in the grass mouse *Necromys urichi* J. A. Allen and Chapman, 1897 (Arcay-de-Peraza 1981), while *Eimeria ojasitii*

Table 1 Comparative morphology of *Eimeria akodonensis* n. sp. and other *Eimeria* species recorded from rodents from Brazil and Venezuela. The metrical data are given in micrometers as the mean followed by the range in parentheses. When no data were provided, or the data are inadequate for comparisons, the variable is shown as NR = Not Reported

Host	Species	Reference, country	Oocyst shape	Oocyst size L × W	Oocyst wall thickness	Oocyst shape index	Polar granule	Sporocyst size L × W	Stieda body /sub-Stieda body
<i>Akodon montensis</i>	<i>Eimeria akodonensis</i> n. sp.	Present study, Brazil	Ellipsoidal to subspherical	25.3×20.2 (21.0–28.0 × 17.0–22.0)	Bi-layered 1.5 (1.3–1.6)	1.3 (1.2–1.4)	Present	11.8×7.9 (9.3–14.4 × 6.7–9.3)	Present /absent
<i>Euryoryzomys</i> sp.	<i>E. oryzomyisi</i>	Carini (1937), Brazil	Ellipsoidal to subspherical	NR (22–25 × 17–19)	Bi-layered NR	1.25	Absent	11×8 NR	Present /absent
<i>Nephelomys albicularis</i>	<i>E. ojasitii</i>	Arcay-de-Peraza (1964), Venezuela	Ellipsoidal	17.4×13.2 NR	Bi-layered NR	NR	NR	7.5×5.9 NR	Absent/absent
<i>Necromys urichi</i>	<i>E. akodoni</i>	Arcay-de-Peraza (1981), Venezuela	Fusiform to ellipsoidal	27×18 NR	Tri-layered (1.5)	NR	Present	14×7 NR	Present /absent
<i>Necromys lasiurus</i>	<i>E. zygodontomyis</i>	Lainson and Shaw (1990), Brazil	Ellipsoidal to cylindrical	16.5×12 (13.7–18.7 × 11.2–12.5)	Uni-layered (0.6)	1.4 (1.2–1.5)	Present	8.4×5.5 (7.4–8.7 × 5.0–6.2)	Present /absent

Arcay-de-Peraza, 1964 was recorded from *Nephelomys albigularis* Tomes, 1860 (Arcay-de-Peraza, 1964).

The morphology and morphometry of *Eimeria akodonensis* n. sp. were compared with data for coccidia of the family Eimeriidae described from other cricetid hosts in Brazil and Venezuela (Table 1). In the case of the study of Arcay-de-Peraza (1964), some data were missing, although they were not crucial to the comparison with *Eimeria akodonensis* n. sp.. *Eimeria oryzomyisi* (Carini 1937) has the same shape as *Eimeria akodonensis* n. sp., but is slightly smaller, on average (22–25 $\mu\text{m} \times 17$ –19 μm vs. 21–28 $\mu\text{m} \times 17$ –22 μm), and does not have a polar granule, its wall is smooth and not very thick, and the residua of the sporocysts are made up of fine granules. *Eimeria ojustii* (Arcay-de-Peraza, 1964) is considerably smaller (17.4 \times 13.2 vs. 25.3 \times 20.2), ellipsoidal in shape, and its sporocyst does not have a Stieda body; no data were presented on the presence or absence of a polar granule. *Eimeria zygodontomyis* (Lainson and Shaw 1990) is also much smaller (16.5 $\mu\text{m} \times 12 \mu\text{m}$ vs. 25.3 $\mu\text{m} \times 20.2 \mu\text{m}$), significantly different in shape, and have a fine, single-layered wall (0.6 vs. 1.5 μm) in comparison with the rough double wall of *Eimeria akodonensis* n. sp.

Morphologically, the most similar of the four species to *Eimeria akodonensis* n. sp. is *E. akodoni*, which was described by Arcay-de-Peraza (1981) parasitizing *N. urichi*. The two species are similar in size (27 $\mu\text{m} \times 18 \mu\text{m}$ vs. 25.3 $\mu\text{m} \times 20.2 \mu\text{m}$) and both have a polar granule, although the sporocysts are slightly different in their morphology and size (14 $\mu\text{m} \times 7 \mu\text{m}$ vs. 11.8 $\mu\text{m} \times 7.9 \mu\text{m}$). Arcay-de-Peraza (1981) describes the oocysts of *E. akodoni* as fusiform, and when they were observed in immersion, their thick wall was apparent along their whole length except for the extremities, where they become thinner, taking on the appearance of “false opercules,” in the words of the author. This characteristic is not observed in *Eimeria akodonensis* n. sp., and the oocysts are not fusiform in shape. Arcay-de-Peraza describes the presence of three walls in *E. akodoni* and the absence of residuum in the oocyst, whereas in *Eimeria akodonensis* n. sp., the oocyst has a double wall, with a large residuum. Despite these broad morphological similarities, the endogenous development of *Eimeria akodonensis* n. sp. occurs in different portions of the intestine in comparison with *E. akodoni*. Whereas *Eimeria akodonensis* n. sp. develops in the small intestine, Arcay-de-Peraza (1981) found *E. akodoni* in the large intestine. According to Arcay-de-Peraza (1981), merogony and gametogony of *E. akodoni* occurred in epithelial cells of the large intestine. In the case of *E. akodonensis* n. sp., gametogony was only recorded in the jejunum portion of the small intestine. The microgametocytes of *E. akodonensis* n. sp. were smaller (10.9 \times 11.8 μm) than *E. akodoni* (30.6 \times 20.4 μm). In addition, macrogametocytes of *E. akodonensis* n. sp. were sub-spherical, 20.9 \times 16.2 μm (L/W ratio: 1.2 μm), and those of *E. akodoni* were ellipsoidal, 19.7 \times

11.7 μm (L/W ratio: 1.6 μm). The effects of infection by *Eimeria akodonensis* n. sp. on the intestinal tissue of *Akodon montensis* varied considerably, from a total absence to a light and diffuse infiltration distributed in the intestinal mucosa composed of neutrophils and mononuclear cells. However, this infiltration was not found in association with the parasites themselves, but rather in the epithelium of the intestinal villi. Overall, the set of morphological and physiological characteristics found in *Eimeria akodonensis* n. sp. supports conclusively its description as a new species.

Acknowledgements We are grateful for the help in fieldwork to the field team of LABPMR/IOC-Fiocruz and LabVert/UFRJ. Work is supported by CNPq and FAPERJ.

Compliance with ethical standards

Conflict of interest The authors declare that they have no conflict of interest.

Ethical approval All trapping procedures followed the guidelines for the capture, handling, and care of animals established by the Ethics Committee on the Use of Animals in Research of Oswaldo Cruz Foundation/Fiocruz, Rio de Janeiro, under license numbers L-049/08 and LW81/12. The capture of wild animals was authorized by Instituto Chico Mendes de Conservação da Biodiversidade (ICMBio) through authorization number 45839-1, based on the pertinent Brazilian legislation.

Open Access This article is distributed under the terms of the Creative Commons Attribution 4.0 International License (<http://creativecommons.org/licenses/by/4.0/>), which permits unrestricted use, distribution, and reproduction in any medium, provided you give appropriate credit to the original author(s) and the source, provide a link to the Creative Commons license, and indicate if changes were made.

References

- Aguiar AP, Chiarello AG, Mendes SL, Matos EN (2005) Os corredores central e da Serra do Mar na Mata Atlântica brasileira. In: Galindo-Leal C, Câmara IG (eds) Mata Atlântica Biodiversidade, Ameaças e Perspectivas. Fundação SOS Mata Atlântica/Conservação Internacional, Belo Horizonte, pp 119–132
- Arcay-de-Peraza L (1964) Tres nuevas especies de *Eimeria* (Protozoa, Coccidia Eimeriidae) de Roedores Silvestres de Venezuela. Acta Biol Venez 4:185–203
- Arcay-de-Peraza L (1981) Nuevos coccidia de roedores silvestres de Venezuela: *Eimeria guerlingueti* sp. nov. y *Wenyonella maligna* sp. nov. de *Sciurus (Guerlinguetus) granatensis* y *Eimeria akodoni* sp. nov. de *Akodon urichi venezuelensis* (Rodentia, Myomorpha, Cricetidae, Cricetinae). Acta Biol Venez 11:125–148
- Bonvicino CR, De Oliveira JA, D’Andrea PS (2008) Guia dos Roedores do Brasil, com chaves para gêneros baseadas em caracteres externos. Centro Pan-Americano de Febre Aftosa - OPAS/OMS, Rio de Janeiro
- Carini A (1937) Sobre uma nova *Eimeria* (*E. oryzomyisi* n. sp.) do intestino de um ratinho do campo. Arch Biol 21:47–49
- Dubey JP, Sreekumar C, Rosenthal BM, Lindsay DS, Grisard EC, Vitor RWA (2003) Biological and molecular characterization of *Besnoitia*

- akodoni* n. sp.(Protozoa: Apicomplexa) from the rodent *Akodon montensis* in Brazil. *Parassitologia* 45(2):61–70
- Duszynski DW, Gardner SL (1991) Fixing coccidian oöcysts is not an adequate solution to the problem of preserving protozoan type material. *J Parasitol* 77(1):52–57. <https://doi.org/10.2307/3282555>
- Duszynski DW, Wilber PG (1997) A guideline for the preparation of species descriptions in the Eimeriidae. *J Parasitol* 83(2):333–336. <https://doi.org/10.2307/3284470>
- Duszynski DW, Upton SJ (2001) Enteric Protozoans: Cyclospora, Eimeria, Isospora, and Cryptosporidium spp. In: *Parasitic Diseases of Wild Mammals*. Iowa State University Press, Ames, Iowa, USA, pp 416–459. <https://doi.wiley.com/10.1002/9780470377000.ch16c>
- Frey JK, Yates TL, Duszynski DW, Gannon WL, Gardner SL (1992) Designation and curatorial management of type host specimens (symbiotypes) for new parasite species. *J Parasitol* 78(5):930–932. <https://doi.org/10.2307/3283335>
- Graipel ME, Miller PR, Glock L (2003) Padrão de atividade de *Akodon montensis* e *Oryzomys russatus* na Reserva Volta Velha, Santa Catarina, sul do Brasil. *Mastozool Neotrop* 10:255–260
- Humason GL (1979) *Animal tissue techniques*, 4th edn. W.H. Freeman, San Francisco
- Kheysin YM (2013) *Life cycles of coccidia of domestic animals*. University Park Press, Baltimore
- Lainson R, Shaw JJ (1990) Coccidia of Brazilian mammals: *Eimeria corticulata* n. sp. (Apicomplexa: Eimeriidae) from the anteater *Tamandua tetradactyla* (Xenarthra: Myrmecophagidae) and *Eimeria zygodontomyis* n. sp. from the cane mouse *Zygodontomys lasiurus* (Rodentia: Cricetidae). *J Protozool* 37(1):51–54. <https://doi.org/10.1111/j.1550-7408.1990.tb01115.x>
- Müller L, Gonçalves GL, Cordeiro-Estrela P, Marinho JR, Althoff SL, Testoni AF, González EM, Freitas TR (2013) DNA barcoding of sigmodontine rodents: identifying wildlife reservoirs of zoonoses. *PLoS One* 8:1–12
- Musser GG, Carleton MD (2005) Superfamily Muroidea. In: Wilson DE, Reeder DM (eds) *Mammal species of the world: a taxonomic and geographic reference*. The John Hopkins University Press, Baltimore, pp 894–1531
- Oliveira RCD, Guterres A, Schrago CG, Fernandes J, Teixeira BR, Zeccer S, Lemos ERSD (2012) Detection of the first incidence of *Akodon paranaensis* naturally infected with the Jabora virus strain (Hantavirus) in Brazil. *Mem Inst Oswaldo Cruz* 107(3):424–428. <https://doi.org/10.1590/S0074-02762012000300020>
- Paglia AP, Fonseca GAB, Rylands AB, Herrmann G, Aguiar LMS, Chiarello AG, Leite YLR, Costa LP, Siciliano S, Kierulff MCM, Mendes SL, Tavares VC, Mittermeier RA, Patton JL (2012) Lista Anotada dos Mamíferos do Brasil/Annotated checklist of Brazilian mammals, 2ª Edição/ 2nd Edition. Occasional Papers in Conservation Biology, No. 6. Conservation International, Arlington, VA 76pp. https://www.conservation.org/global/brasil/publicacoes/Documents/annotated_checklist_of_brazilian_mammals_2nd_edition.pdf
- Teixeira BR, Loureiro N, Strecht L, Gentile R, Oliveira RC, Guterres A, Fernandes J, Mattos LH, Raboni SM, Rubio G, Bonvicino CR, dos Santos CN, Lemos ER, D'Andrea PS (2014) Population ecology of hantavirus rodent hosts in Southern Brazil. *Am J Trop Med Hyg* 91(2):249–257. <https://doi.org/10.4269/ajtmh.13-0465>