



Original article

Posterior three-column osteotomies for the treatment of rigid thoracic kyphosis – a case series[☆]



Marcelo Simoni Simões, Ernani Vianna de Abreu, Bruno Costamilan Winkler*

Hospital Ernesto Dornelles, Porto Alegre, RS, Brazil

ARTICLE INFO

Article history:

Received 16 December 2015

Accepted 31 May 2016

Available online 24 January 2017

Keywords:

Osteotomy

Kyphosis

Spinal curvatures

Spinal diseases

ABSTRACT

Objective: To evaluate the results and complications of a series of patients who underwent three-column osteotomy using the posterior approach for correction of complex cases of rigid dorsal kyphotic deformity.

Methods: Review of clinical records and images of 15 consecutive cases of pedicle subtraction osteotomies, bone-disk-bone osteotomies, or vertebral column resection, recording the etiology, type and level of osteotomy, extension of fixation, complications, and pre- and post-surgical measurements of the sagittal curves and pelvic parameters.

Results: Six pedicle subtraction osteotomies were performed, one of which in two adjacent vertebrae, as well as two bone-disk-bone osteotomies and seven vertebral column resection, two of which were performed in two adjacent vertebrae. The mean correction was 39.3° for the angular kyphosis and 33.9° for dorsal kyphosis. The corrections were similar regardless of the kind of osteotomy, the operated spinal segment, or the approach in one or two levels, but this may be a sample effect.

Eight complications were observed in six patients (40% of cases): two medical complications, five early and one late surgical complication (over 90 days after surgery). There were three reoperations within less than one year from the initial surgery and one case of persistent paraparesis. Clinical complications were resolved without sequelae. There was no significant loss of correction during the segment, except in two cases of major mechanical failure due to a junctional segment fracture.

Conclusion: Despite being complex and aggressive procedures, prone to various complications, osteotomies with resection of the three columns are highly effective in the correction of rigid kyphotic deformities and safe enough to justify its use in selected cases.

© 2017 Published by Elsevier Editora Ltda. on behalf of Sociedade Brasileira de Ortopedia e Traumatologia. This is an open access article under the CC BY-NC-ND license (<http://creativecommons.org/licenses/by-nc-nd/4.0/>).

[☆] Study conducted at Hospital Ernesto Dornelles, Porto Alegre, RS, Brazil.

* Corresponding author.

E-mail: brunobcw@gmail.com (B.C. Winkler).

<http://dx.doi.org/10.1016/j.rboe.2017.01.004>

2255-4971/© 2017 Published by Elsevier Editora Ltda. on behalf of Sociedade Brasileira de Ortopedia e Traumatologia. This is an open access article under the CC BY-NC-ND license (<http://creativecommons.org/licenses/by-nc-nd/4.0/>).

Osteotomias posteriores de três colunas para tratamento de cifose dorsal rígida – Série de casos

R E S U M O

Palavras-chave:

Osteotomia
Cifose
Curvaturas da coluna vertebral
Doenças da coluna vertebral

Objetivo: Avaliar os resultados e as complicações de uma série de pacientes submetidos a osteotomias das três colunas por abordagem posterior para correção de casos complexos de deformidade cifótica dorsal rígida.

Métodos: Revisão dos prontuários e das imagens de 15 casos consecutivos de osteotomias de subtração pedicular, osteotomias osso-disco-osso ou vertebrectomias posteriores totais, com registro das etiologias, tipo e nível de osteotomia, extensão da fixação, complicações e medidas pré- e pós-cirúrgicas das curvas sagitais e dos parâmetros pélvicos.

Resultados: Foram feitas seis osteotomias de subtração pedicular, uma em duas vértebras adjacentes e duas osso-disco-osso e sete vertebrectomias posteriores totais, duas em duas vértebras adjacentes. As médias de correção foram de 39,3° para a cifose angular e 33,9° para a cifose dorsal total. As correções foram semelhantes, independentemente do tipo de osteotomia usado, do segmento espinhal operado ou da abordagem em um ou dois níveis, mas isso pode ser efeito da amostra.

Ocorreram oito complicações em seis pacientes (40% dos casos), duas clínicas, cinco cirúrgicas precoces e uma cirúrgica tardia (mais de 90 dias após a cirurgia). Houve três reoperações com menos de um ano da cirurgia inicial e um caso de paraparesia mantida. As complicações clínicas foram resolvidas sem sequelas maiores. Não houve perda de correção significativa durante o segmento, exceto em dois casos de falha mecânica maior por fratura de segmento juncional.

Conclusão: Embora sejam procedimentos complexos, agressivos e sujeitos a complicações, as osteotomias com ressecção das três colunas são altamente eficazes na correção das deformidades cifóticas rígidas e seguras o bastante para justificar seu uso em casos selecionados.

© 2017 Publicado por Elsevier Editora Ltda. em nome de Sociedade Brasileira de Ortopedia e Traumatologia. Este é um artigo Open Access sob uma licença CC BY-NC-ND (<http://creativecommons.org/licenses/by-nc-nd/4.0/>).

Introduction

The development of spinal surgery has led surgeons to face increasingly complex cases, aiming not only at spinal decompression and stabilization, but also at deformities correction and the spine biomechanical balance restoration.¹

In the last decade, subtraction osteotomies have become popular in the management of spinal deformities^{2,3} and have begun to be used in a wide range of situations. The focuses of this study are pedicular subtraction osteotomy (PSO), bone-disk-bone osteotomy (BDB), and vertebral column resection (VCR), all of which are posterior, middle, and anterior resection techniques through a single posterior access that can be used in very rigid deformities, with three-column arthrodesis or ankylosis, providing significant angular corrections in a single level without elongation of the anterior column of the spine (Fig. 1).

Material and methods

This was a retrospective study of 15 cases of patients with rigid dorsal kyphotic or kyphoscoliotic deformities of several etiologies, surgically treated, whose postoperative follow-up ranged from 6 to 60 months (mean of 36 months). Data from charts and measurements of spine curves were collected by the

four-line Cobb method. Lumbar lordosis and dorsal kyphosis were measured between the points of inversion of the curve, regardless of the level (Fig. 2). In cases where more than one surgery was performed, results considered measurements taken after the last approach.

Surgical technique

Patients were operated on a conventional surgical table, positioned in a manner that allowed transoperative maneuvers of hyperextension of the trunk or thighs, either through the controls of the table or through access to the positioning pads. Intraoperative neurophysiological monitoring was available in only eight cases (53%). The extent of the fixation was defined based on current principles of deformity correction; in all cases, it was sought to use a minimum of six anchorage points above and below the osteotomy. Wide laminectomy and disarticulation of the ribs were performed at the level to be osteotomized and at the levels above and below it. In more complex cases, secondary to tumors, infections, or associated with scoliosis, laminectomy and osteotomy were performed in a manner that was adapted to the pathology, comprising more levels or conducted asymmetrically. Nerve roots were sacrificed only when necessary to allow bone resection. An intersomatic cage was not used.

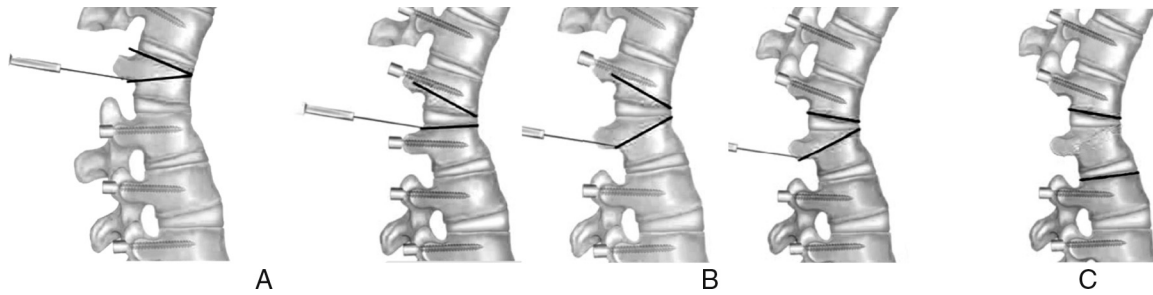


Fig. 1 – Types of three-column osteotomy. (A) Pedicular subtraction osteotomy (PSO); resection of a vertebral body wedge. (B) Bone-disk-bone osteotomies (BDB); resection of a wedge with the apex on the disk. (C) Vertebral column resection (VCR); resection of the entire vertebral body with the disks above and below.

Results

Sample data

Five men and ten women, aged between 13 and 66 years (mean: 38, SD = ±18.8), were operated. There were four cases of post-traumatic kyphosis (26.6%), four cases of kyphoscoliosis due to hemivertebrae (26.6%), two cases of Pott's disease (13.3%), two cases of junctional kyphosis (13.3%), one case of deformity after pathological fracture due to multiple

myeloma, one case of kyphoscoliosis due to neurofibromatosis, and one case of rigid Scheuermann's kyphosis in an adult patient. Only the two patients with junctional kyphosis, in whom a long fixation of the lumbosacral spine was observed, presented significant sagittal imbalance. For all other cases, even in the presence of significant kyphosis, overall sagittal balance was maintained at the expense of compensatory lumbar hyperlordosis and pelvic anteversion.

Nine of the 15 cases presented very significant spinal cord compression, but there were only two cases of neurological compressive deficits (case 1, Pott's disease and case 8,

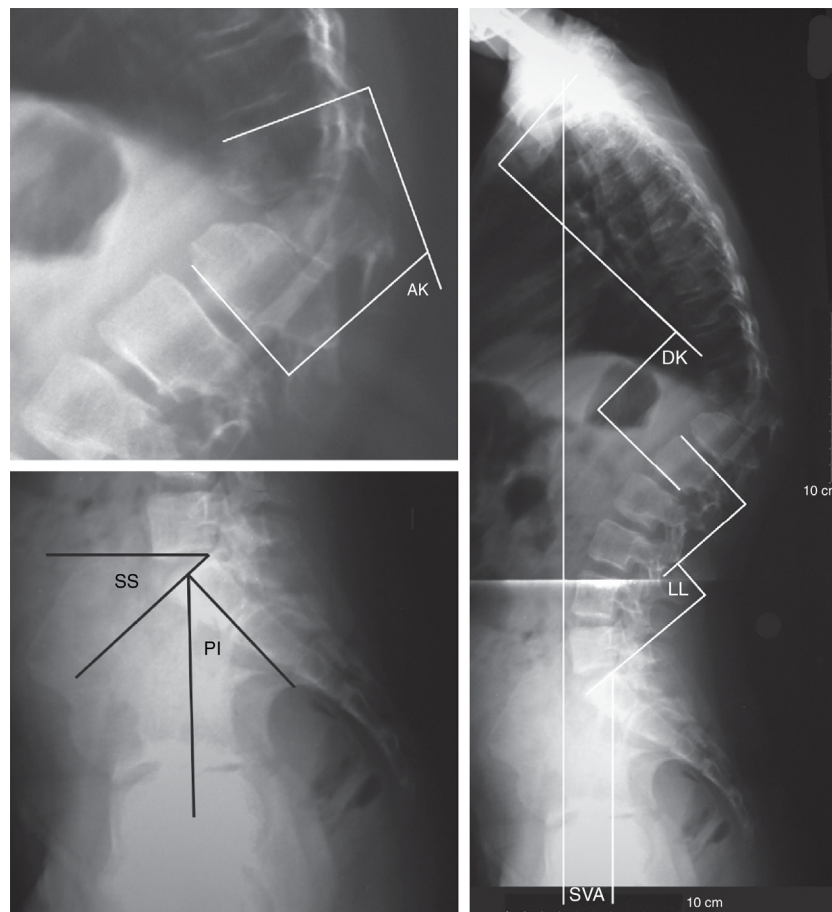


Fig. 2 – Method of taking measurements of angular kyphosis (AK), sacral slope (SS), pelvic incidence (PI), dorsal kyphosis (DK), lumbar lordosis (LL), and sagittal vertical axis (SVA).

post-neoplastic). In case 5, paraplegia was caused by acute trauma, not by late deformity.

The following procedures were performed: six PSOs (40%), one of which occurred in two adjacent vertebrae (case 6); two BDBs (13.3%); and seven VCRs (46.7%), two of which were conducted in two adjacent vertebrae (cases 1 and 2). One osteotomy was performed in the proximal thoracic segment (T2-T4), seven (46.7%) in the middle thoracic segment (T5-T9), and seven (46.7%) in the lower thoracic segment (T10-T12).

Data are summarized in [Table 1](#).

Surgical results

The mean angular kyphosis correction was 39.3° (SD = ±14.6°) and total kyphosis 33.9° (SD = ±17.7°). Considering the operated segment, angular kyphosis correction and full dorsal kyphosis were, respectively, 33° and 22° in upper dorsal lesions (T2-T4), 41.1° (SD = ±13°) and 35° (SD = ±21.3°) in medial dorsal lesions (T5-T9), and 38.3° (SD = ±17.7°) and 34.4° (SD = ±15.9°) in lower dorsal lesions (T10-T12). Considering the type of osteotomy used, the correction of angular kyphosis achieved by BDB was 28° (26° and 30°); by PSO, 41.5° (29-53°, SD = ±9.4°); and by PTV, 42° (10-63°, SD = ±19.5°). Complete neurological recovery was observed in the two cases that presented paraparesis due to deformity.

Complications

Eight complications occurred in six patients, as shown in [Table 2](#). The clinical complications were a pulmonary thromboembolism and a thyroid storm in a young woman with hypothyroidism who discontinued the medication on her own. Both cases were resolved without major sequelae.

In the case of neurofibromatosis, there was a partial medullary lesion during vertebrectomy, which was performed via the transdural access, since the meningoceles embraced the entire contour of the vertebra. Patient presented left dorsal paresis in the postoperative period, compatible with gait, and with progressive improvement. However, seven months after surgery, patient returned with severe spastic paraparesis. Investigation showed significant spinal cord compression by an arachnoid cyst above the operated area, probably due to arachnoid adhesions after the transdural approach. Further surgery was performed, but patient remained paraparetic and spastic (case 9, [Fig. 3](#)). There were three early mechanical complications, one instrumentation failure (case 8, [Fig. 4](#)), and two junctional fractures at the most caudal instrumented level, with a small loss of correction in one and important loss in another, which led to the decompensation of the sagittal balance (case 11, [Fig. 5](#)). A significant loss of correction was not observed in any of the other cases during follow-up.

Discussion

Three-column osteotomies are aggressive surgeries, usually indicated in situations in which other techniques with lower potential morbidity are not applicable, either due to lack of flexibility of the spine or the presence of severe focal angular deformity.² Its primary advantage is to allow the correction of

rigid deformities without the need for anterior release. PSO is the best known technique; some publications have described a gain of 30 to 40 degrees of lordosis per level addressed.⁴⁻⁶ In the dorsal spine, its use has been much more limited and the potential for correction is not so clear.⁷ In 1994, Lehmer et al.⁸ reported four cases operated in the lower dorsal spine, with a mean correction of 29.5 degrees. Bridwell² reported gains of approximately 25 degrees. With the use of the VCR in the dorsal spine, Rajasekaran et al.⁹ reported a mean of 36 degrees of correction in cases of tuberculosis, while Shimode et al.⁵ reported a mean correction of 56 degrees in severe kyphoscoliosis. In the present series, the corrections were of approximately 40 degrees, with no significant difference between techniques.

Thoracic osteotomies differ greatly from those of the lumbar. First, to allow an effective closure of the osteotomy, the ribs that articulate with the superior and inferior disks must be released; second, because the surgery is done at levels where there is bone marrow, there is a limit to the bone mobilization that can be achieved with acceptable risk. O'Shaughnessy et al.⁷ reported that 20-25 mm of posterior laminar closure can be tolerated without neurological problems, but this value has not been validated experimentally. Tomita has shown that spinal cord shortening associated with the removal of a vertebral body is not a problem, and neither is the ligation of segmental vessels in up to three levels.^{10,11} Gertzbein and Harris¹² postulated that distortion of the cord and clamping of the dural sac are potential risks associated with spinal cord shortening; these authors recommend avoiding corrections of more than 40°. In the present series, resections of up to two vertebral bodies and corrections of up to 63 degrees were made, without neurological complications. The care measures taken included very large decompressions and laminectomy of at least one level above and below the injury,¹³ which allows observing the dural sac during correction maneuvers and avoids distortions by sublaxation, dural compression, or impingement. Perioperative neurophysiological monitoring is a desired standard, but it was used in only eight cases (53%), due to limitations of access in public healthcare patients. In the literature, the incidence of postoperative neurological deficits in dorsal osteotomy is quite small,^{5,7,14,15} probably due to the great care taken regarding spinal manipulation in all series, in addition to the fact that the nerve structures better resist shortening of the dural sac than its stretching.² The potential for neurological complications is greater in VCR than in PSO, since there are more manipulations and the spine is left more unstable at the time of correction.^{2,13} Rajasekaran et al.⁹ reported 17 cases with irreversible neurological damage. Bakaloudis et al.¹⁶ reported complete loss of motor evoked potentials in one case, with immediate improvement after loosening of correction and without postoperative clinical deficit. Lenke et al.¹⁷ published a series of 40 TVPs of the thoracic spine without spinal cord injury. Seven patients, however, presented alterations in motor evoked potentials during surgery, five due to vertebral sublaxation during correction maneuvers, and two due to exaggerated spinal cord shortening. In all cases, the potentials returned after correction of the sublaxation or placement of larger cages.¹⁷ In another study, the same author reported a complete loss of motor potentials with normal somatosensory findings in 21.4% of

Table 1 – Patients and summary of results.

Case	G-A	Etiology	PS	Deficit pre	AK pre	PI	SVA pre	DK pre	LL pre	SS pre	L OP	L FIX	T OS	AK post	SVA post	DK post	LL post	SS post	Cor K
1	M-28	Post TBC	0	Paraparesis	60	60	4	52	48	36	T8 + T9	T5-T12	VPC	21	2	33	40	31	39
2	M-48	Post TBC	0		105	59	6	82	46	40	T5 + T6	T2-T10	VPC	42	4	44	40	38	63
3	F-54	PTD + Infection	5		33	55	6.5	51	47	30	T12	T8-L3	VPC	4	5.5	43	50	30	29
4	M-16	Congenital	0		78	66	-3	73	90	49	T11	T7-L2	VPC	20	2	43	70	45	58
5 ^a	F-27	Post PTD	0	Paraplegia	33	50	0	68	40	0	T11-T12	T9-L3	BDB	3	-3	42	52	15	30
6	F-62	Post PTD	0		54	42	4.5	75	58	33	T8 + T9	T5-T12	PSO	15	1	62	62	35	39
7	M-13	Congenital	0		63	42	3	90	90	40	T11	T8-L2	VPC	28	1	33	38	23	35
8	F-63	Post Neo	0	Paraparesis	70	60	5	72	50	30	T3	C2-T7	PSO	37	0	50	66	40	33
9	F-20	Dysplastic	0		90	50	1	126	78	38	T11	T8-L4	VPC	30	0	70	70	42	60
10	F-22	Congenital	0		42	68	-4.5	70	90	45	T7-T8	T2-L1	BDB	16	-2	44	70	50	26
11	F-66	Junctional	2		45	54	8.5	75	49	27	T9	T2-L3	PSO	16	6	44	49	30	31
12	F-37	Scheuermann	0		60	53	1.5	73	78	35	T11	T4-L3	PSO	14	0	40	60	35	46
13	M-17	CEH	0		30	64	-1	73	90	45	T10	T8-L3	VPC	20	0.5	52	70	39	10
14	F-48	Post PTD	1		63	60	0	108	89	36	T8 + T9	T2-L2	PSO	14	-6	34	60	42	74
15	F-50	Junctional	1		75	66	36	106	50	47	T7	T2-IL	PSO	22	8	66	74	45	53

AK pre, preoperative angular kyphosis (degrees); AK post, postoperative angular kyphosis (degrees); DK pre, total preoperative dorsal kyphosis (degrees); DK post, postoperative dorsal kyphosis (degrees); Cor AK, correction of angular kyphosis (degrees); PS, number of previous surgeries; SVA pre, preoperative sagittal vertical axis (centimeters); SVA post, postoperative sagittal vertical axis (centimeters); IL, sacral and iliac fixation; PI, pelvic incidence; SS pre, preoperative sacral slope (degrees); SS post, postoperative sacral slope (degrees); LL pre, preoperative lumbar lordosis (degrees); LL post, post-operative lumbar lordosis (degrees); NEO, deformity after bone neoplasia; L FIX, fixated levels; L OP, level at which the osteotomy was performed; G-A, gender-age; T OS, osteotomy type; PTD, post traumatic deformity.

^a The patient could not stand before surgery. CS and LL pre were measured in decubitus position. SS pre and SVA pre were not measured.

Table 2 – Complications.

Case	Early clinical	Early surgical	Surgical procedures	Reoperations	Sequelae
03		Deep infection		Surgical dressing	
06		T12 fracture			Loss of correction
08		Cervical pullout		Revision of the fixation	
09		Spinal cord injury	Arachnoid cyst	Cyst resection	Spastic paraparesis
10	Thyroid crisis				
11	TEP	L4 fracture			Loss of correction

cases. The recommended approach is to maintain a mean arterial pressure of at least 75 mHg, loosen the correction and, if the potentials do not restore, then remove the rods and undo the correction, attempting again with another strategy after signals are restored.¹⁵ Neurological deficit in the present series was not related to the correction of the deformity, but rather occurred during bone resection performed via transdural access in the case of neurofibromatosis, while the patient was being monitored. Mechanical complications are more common than neurological ones, since kyphotic deformities have a natural tendency to progression and instrumentation overload is not uncommon, especially when sagittal balance is not corrected. In some cases, the patient appears to be used to the anterior position of the trunk and the projection of the head, and assumes this type of posture even after correction of the deformity, which suggests the existence of some neurological or proprioceptive mechanism that influences the individual ability to maintain the body balance.⁶ The most described mechanical complications are pseudarthrosis, failure of instrumentation, and loss of correction over time. In the literature, the incidence of pseudarthrosis ranges from 0 to 5%^{5,18,19} and instrumentation failures occur in up to 8% of the cases, generally related to insufficient correction, osteoporosis, or lack of anterior support in VCR.^{7,9,19} In the present series, there were no cases of pseudarthrosis, and

only one patient was followed-up for less than a year. Three early mechanical complications were observed: one case in which screws pulled out (case 8, Fig. 4) and two fractures of the instrumented lower vertebra, both related to osteoporosis. The first case was a fixation from T5 to T12, and fracture occurred due to insufficiency in T12. As loss of correction was small and clinical outcome was satisfactory, the authors decided not to perform a second surgical approach. After this case, the group's conduct was modified and the definition of distal fixation levels was made including the first level in lordosis, as recommended in the treatment of Scheuermann's kyphosis.²⁰ In the second case, there was an L4 fracture with significant impact on sagittal balance and functional outcome, but patient was not reoperated due to clinical contraindication (case 11, Fig. 5). With the exception of these two cases of fracture, no significant loss of correction was observed during follow-up. This maintenance of the correction over time in uncomplicated cases was observed in most series.^{8,10,11,17,21} As there are no absolute values for defining normal kyphosis, the important parameters in the evaluation of corrections are reduced angular kyphosis and the restoration of sagittal balance.²² In this series, only two cases of junctional kyphosis, which had previous fixations of T10 to the sacrum, had significant sagittal decompensation. This is due to two factors: first, the most powerful spinopelvic sagittal compensation

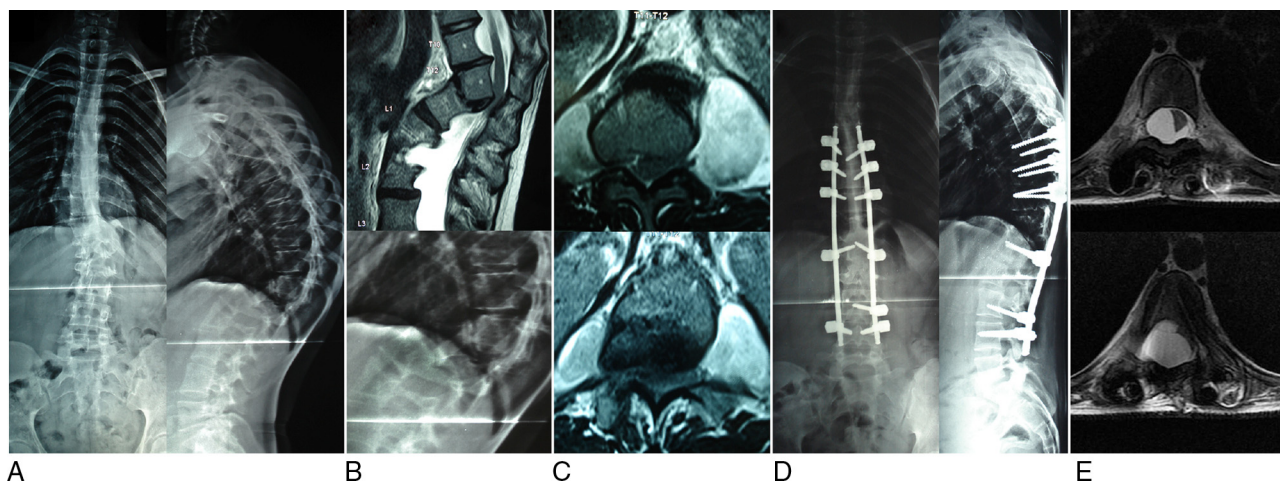


Fig. 3 – Kyphoscoliosis due to dysplastic neurofibromatosis, with 90-degree rotation of T11 on T12, with spinal compression. Patient presented only lower limb hyperreflexia, but was bedridden due to pain. (A) Panoramic radiograph. (B) Magnetic resonance imaging and radiograph, focused showing the angular deformity with 90° of T10–T12 kyphosis and spinal compression. (C) Magnetic resonance imaging showing the extent of the meningeoceles around the angular deformity that led to the transdural approach. (D) Postoperative radiograph showing good correction of the deformity. (E) Magnetic resonance imaging seven months after the initial surgery showing an arachnoid cyst at the upper end of the instrumentation, two levels above the VCR, with important compression and displacement of the spinal cord. The patient had rapidly progressive spastic paraparesis, which persisted even after cyst surgery (case 9).

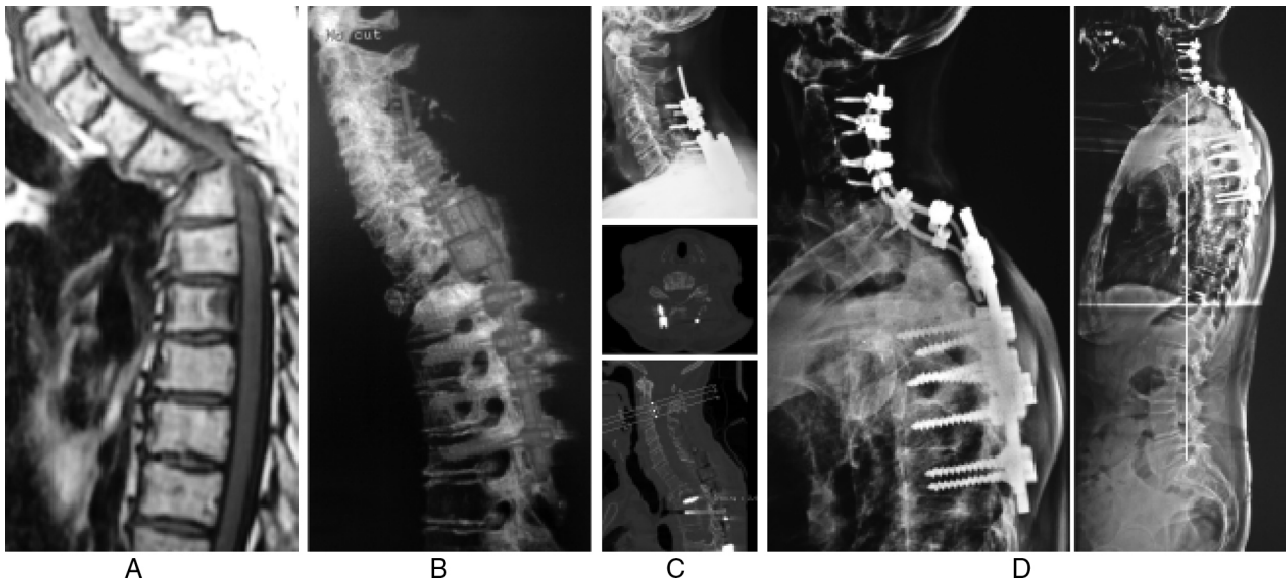


Fig. 4 – Angular kyphosis due to pathological fracture of T3 after multiple myeloma treatment. Paraparetic patient with strength grade III. (A) Initial appearance on magnetic resonance imaging with 70° of T2-T4 kyphosis and spinal cord compression. (B) Postoperative tomography showing good correction of the deformity. (C) Radiograph and tomography made after discharge due to sudden increase in cervical pain. The exams show pulling of the screws in the lateral cervical masses, with little loss of correction. (D) Final aspect after a new approach, in which the dorsal screws were maintained and the cervical implants replaced, with extension of the fixation up to C2. The orthostatic radiograph shows the C7 plumb line exactly on the posterior aspect of the sacral plateau (case 8).

mechanism is the adjustment of lumbar lordosis,^{23,24} and injuries that do not compromise the lumbar mobility are more easily balanced; second, as a matter of trigonometry, the higher the level of angular kyphosis, the lower its impact on

the overall sagittal balance, because it is further away from the base.²⁵ In both cases, an improvement on the sagittal vertical axis (SVA) without complete normalization was observed. In cases of lumbar osteotomies for sagittal imbalance correction,

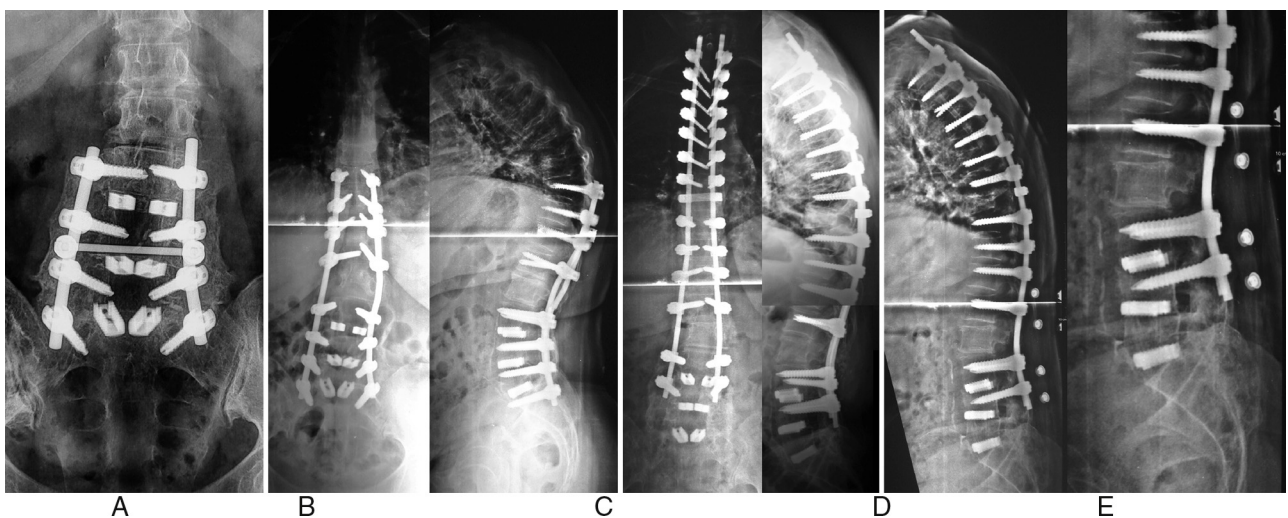


Fig. 5 – L3-S1 arthrodesis for over ten years, which evolved with L2-L3 stenosis and extension of the fixation up to T10 for three years, developing progressive junctional kyphosis. (A) Radiograph showing the consolidation of the old arthrodesis. (B) Extension of the fixation up to T10, with development of junctional kyphosis. (C) Postoperative radiograph showing fixation extension up to T2 and T9 PSO, with good kyphosis correction. As the lumbar segment was firmly consolidated and there were 12 anchorage points distal to the osteotomy, it was decided to fixate only up to L4. (D) Radiograph 60 days after surgery showing loss of lumbar lordosis and sagittal imbalance. The patient projected her trunk when rising from a low chair and felt a crack in her lower back. (E) Detail of the radiograph showing wedging of L4 and lumbar rectification. As the patient had pulmonary thromboembolism postoperatively and was anticoagulated, in addition to other clinical problems, it was decided to maintain the use of a vest and observe the evolution (case 11).

Rose et al.²⁶ concluded that the combination of PI + CD-LL $\leq 45^\circ$ has a predictive value of 91% for maintaining sagittal balance up to two years after surgery. In the dorsal spine, this principle does not appear to be valid, since the loss of balance that occurs over time is mainly due to the progression of dorsal kyphosis; it is more noticeable in cases in which the superior instrumented level is below T5.²⁶ In the present series, only 50% of patients met this criterion and yet there was no loss of correction.

Final considerations

Although these procedures are complex, aggressive, and subject to complications, osteotomies with three-column resection have proved to be quite effective and sufficiently safe for the correction of rigid sagittal deformities. Due to the severity of this type of deformity, the authors believe that the use of osteotomies in the treatment of this condition is highly justified.

Conflicts of interest

The authors declare no conflicts of interest.

REFERENCES

- Gokce A, Ozturkmen Y, Mutlu S, Caniklioglu M. Spinal osteotomy: correcting sagittal balance in tuberculous spondylitis. *J Spinal Disord Tech.* 2008;21(7):484-8.
- Bridwell KH. Decision making regarding smith-petersen vs. pedicle subtraction osteotomy vs. vertebral column resection for spinal deformity. *Spine (Phila Pa 1976).* 2006;31(19):S171-8.
- Costa RJF, Carelli LE, Barcellos ALL, Araújo Junior AEP, Schetino LCV. Correção das deformidades sagitais fixas pela técnica de osteotomia de subtração pedicular (PSO). *Coluna/Columna.* 2011;10(2):139-43.
- Li F, Sagi HC, Liu B, Yuan HA. Comparative evaluation of single-level closing-wedge vertebral osteotomies for the correction of fixed kyphotic deformity of the lumbar spine. A cadaveric study. *Spine (Phila Pa 1976).* 2001;26(21):2385-91.
- Shimode M, Kojima T, Sowa K. Spinal wedge osteotomy by a single posterior approach for correction of severe and rigid kyphosis or kyphoscoliosis. *Spine (Phila Pa 1976).* 2002;27(20):2260-7.
- Chang KW, Cheng CW, Chen HC, Chang KI, Chen TC. Closing-opening wedge osteotomy for the treatment of sagittal imbalance. *Spine (Phila Pa 1976).* 2008;33(13):1470-7.
- O'Shaughnessy BA, Kuklo TR, Hsieh PC, Yang BP, Koski TR, Ondra SL. Thoracic pedicle subtraction osteotomy for fixed sagittal spinal deformity. *Spine (Phila Pa 1976).* 2009;34(26):2893-9.
- Lehmer SM, Keppler L, Biscup RS, Enker P, Miller SD, Steffee AD. Posterior transvertebral osteotomy for adult thoracolumbar kyphosis. *Spine (Phila Pa 1976).* 1994;19(18):2060-7.
- Rajasekaran S, Vijay K, Shetty AP. Single-stage closing-opening wedge osteotomy of spine to correct severe post-tubercular kyphotic deformities of the spine: a 3-year follow-up of 17 patients. *Eur Spine J.* 2010;19(4):583-92.
- Kawahara N, Tomita K, Baba H, Kobayashi T, Fujita T, Murakami H. Closing-opening wedge osteotomy to correct angular kyphotic deformity by a single posterior approach. *Spine (Phila Pa 1976).* 2001;26(4):391-402.
- Tomita K, Kawahara N, Baba H, Tsuchiya H, Fujita T, Toribatake Y. Total em bloc spondylectomy. A new surgical technique for primary malignant vertebral tumors. *Spine (Phila Pa 1976).* 1997;22(3):324-33.
- Gertzbein SD, Harris MB. Wedge osteotomy for the correction of post-traumatic kyphosis. A new technique and a report of three cases. *Spine (Phila Pa 1976).* 1992;17(3):374-9.
- Buchowski JM, Bridwell KH, Lenke LG, Kuhns CA, Lehman RA Jr, Kim YJ, et al. Neurologic complications of lumbar pedicle subtraction osteotomy: a 10-year assessment. *Spine (Phila Pa 1976).* 2007;32(20):2245-52.
- Chunguang Z, Limin L, Rigao C, Yueming S, Hao L, Qingquan K, et al. Surgical treatment of kyphosis in children in healed stages of spinal tuberculosis. *J Pediatr Orthop.* 2010;30(3):271-6.
- Cheh G, Lenke LG, Padberg AM, Kim YJ, Daubs MD, Kuhns C, et al. Loss of spinal cord monitoring signals in children during thoracic kyphosis correction with spinal osteotomy: why does it occur and what should you do? *Spine (Phila Pa 1976).* 2008;33(10):1093-9.
- Bakaloudis G, Lolli F, Di Silvestre M, Greggi T, Astolfi S, Martikos K, et al. Thoracic pedicle subtraction osteotomy in the treatment of severe pediatric deformities. *Eur Spine J.* 2011;20 Suppl. 1:S95-104.
- Lenke LG, Sides BA, Koester LA, Hensley M, Blanke KM. Vertebral column resection for the treatment of severe spinal deformity. *Clin Orthop Relat Res.* 2010;468(3):687-99.
- Smith JA. Adult deformity - management of sagittal plane deformity in revision adult spine surgery. *Contemp Spine Surg.* 2002;3(2):9-18.
- Suk SI, Kim JH, Lee SM, Chung ER, Lee JH. Anterior-posterior surgery versus posterior closing wedge osteotomy in posttraumatic kyphosis with neurologic compromised osteoporotic fracture. *Spine (Phila Pa 1976).* 2003;28(18):2170-5.
- Herrero CFPS, Porto MA, Barbosa MHN, Defino HLA. Osteotomias segmentares múltiplas para a correção da cifose. *Rev Bras Ortop.* 2009;44(6):513-8.
- Suk SI, Kim JH, Kim WJ, Lee SM, Chung ER, Nah KH. Posterior vertebral column resection for severe spinal deformities. *Spine (Phila Pa 1976).* 2002;27(21):2374-82.
- Winter RB, Lonstein JE, Denis F. Sagittal spinal alignment: the true measurement, norms, and description of correction for thoracic kyphosis. *J Spinal Disord Tech.* 2009;22(5):311-4.
- Lafage V, Schwab F, Skalli W, Hawkinson N, Gagey PM, Ondra S, et al. Standing balance and sagittal plane spinal deformity: analysis of spinopelvic and gravity line parameters. *Spine (Phila Pa 1976).* 2008;33(14):1572-8.
- Schwab F, Lafage V, Boyce R, Skalli W, Farcy JP. Gravity line analysis in adult volunteers: age-related correlation with spinal parameters, pelvic parameters, and foot position. *Spine (Phila Pa 1976).* 2006;31(25):E959-67.
- Ondra SL, Marzouk S, Koski T, Silva F, Salehi S. Mathematical calculation of pedicle subtraction osteotomy size to allow precision correction of fixed sagittal deformity. *Spine (Phila Pa 1976).* 2006;31(25):E973-9.
- Rose PS, Bridwell KH, Lenke LG, Cronen GA, Mulconrey DS, Buchowski JM, et al. Role of pelvic incidence, thoracic kyphosis, and patient factors on sagittal plane correction following pedicle subtraction osteotomy. *Spine (Phila Pa 1976).* 2009;34(8):785-91.