

Critical COVID-19 in a 24-week pregnant woman with 32 days of invasive mechanical ventilation before delivery of fetus: a case of successful collaborative multidisciplinary care

Kaladerhan Osemwengie Agbontaen , Khevan Somasundram, Matthew Baker

Intensive Care Medicine,
Chelsea and Westminster
Hospital NHS Foundation Trust,
London, UK

Correspondence to

Dr Kaladerhan Osemwengie
Agbontaen;
kaladerhan.agbontaen@nhs.net

Accepted 29 July 2021

SUMMARY

We describe the successful treatment of a 24-week pregnant, 44-year-old woman with COVID-19. Management of this complex case required multidisciplinary collaboration and included prolonged invasive mechanical ventilation and prone positioning. Caesarean section delivery was delayed for 32 days, with no monitored fetal compromise, while stabilising the mother. To our knowledge, this is the longest reported duration of invasive ventilation while pregnant in a patient with COVID-19. COVID-19 has been shown to cause increased disease severity in pregnant women, and certain pregnancy-related physiological adaptations that occur could help explain this association. While COVID-19 has been shown to cause no increased adverse neonatal outcomes, clinicians should be aware that data show increased preterm birth in symptomatic pregnant women, thereby increasing the chance of prematurity-related complications. Further research on COVID-19 in pregnancy is crucial to facilitate better management, and full inclusion of pregnant women in therapeutic clinical trials will help achieve this.

BACKGROUND

The COVID-19 pandemic has posed a significant challenge to the healthcare systems of the world for over a year. Managing the complexities of the disease and the public health risk it presents remains of the utmost importance in the global effort to tackle the outbreak. Despite the extensive body of literature generated on COVID-19, there is a paucity of data on women in pregnancy, creating uncertainty and a lack of consensus surrounding management. Recent data show pregnancy to be a risk factor for more severe COVID-19.¹⁻⁴ In addition, COVID-19 has been linked with an increased incidence of preterm birth, but this has not been shown to increase adverse outcomes in preterm neonates.^{1,5} Previous studies on the similar respiratory viral infection outbreaks of severe acute respiratory syndrome (SARS), Middle East respiratory syndrome (MERS), and influenza H1N1 suggested higher rates of maternal and fetal morbidity and mortality.⁶

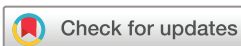We present a case of COVID-19 infection in a pregnant woman who presented to hospital at 24+3 weeks of gestation (WG) and underwent an extensive intensive care unit (ICU) stay (figure 1). This included successful trials of prone positioning

and 32 days of invasive ventilation prior to delivery of the fetus. To our knowledge, there are no other published case reports describing a patient with COVID-19 invasively ventilated for this length of time while pregnant. We explore the complex interplay between COVID-19 and pregnancy and highlight the importance of a multidisciplinary team (MDT) management approach to decision-making considering the availability of few formal guidelines. We outline some of the complications of prematurity the baby has experienced and provide a brief review of the contribution physiological changes during pregnancy may have to a more severe disease manifestation.

CASE PRESENTATION

A 42-year-old Caucasian pregnant woman presented with a 9-day history of anosmia, headaches, and subjective fever at 24+3 WG. The patient worked as a midwife and reported a number of work colleagues having similar symptoms. The patient has had a previous full-term, uncomplicated pregnancy and the current pregnancy was dated by a first trimester scan. Combined screening gave a low risk for the major chromosomal abnormalities and all antenatal booking bloods were normal. The patient had a booking body mass index of 27.6 kg/m² with no significant medical history. She had never smoked or taken illicit drugs and was abstinent from alcohol during her pregnancy, drinking on average one unit of alcohol per week prior to this.

On initial assessment, the patient was tachypnoeic with a respiratory rate of 45 breaths/min and requiring 15 L of oxygen via a non-rebreather mask to achieve a partial pressure of oxygen (PaO₂) of 9 kPa. She had a heart rate of 120 beats/min, non-invasive blood pressure of 126/80 mmHg and a temperature of 37.2°C. Initial blood tests were remarkable for a raised C-reactive protein and D-dimer (table 1), and a chest X-ray (CXR) (figure 2) demonstrated prominent bilateral peripheral airspace opacification radiologically suggestive of severe COVID-19 infection with additional consolidation in the right lower zone. A combined oropharyngeal and nasal swab confirmed SARS-CoV-2 infection with real-time reverse transcription PCR (rRT-PCR). The patient was started on a trial of continuous positive airway pressure (CPAP) and an obstetric review was sought with



© BMJ Publishing Group Limited 2021. No commercial re-use. See rights and permissions. Published by BMJ.

To cite: Agbontaen KO, Somasundram K, Baker M. *BMJ Case Rep* 2021;**14**:e243516. doi:10.1136/bcr-2021-243516

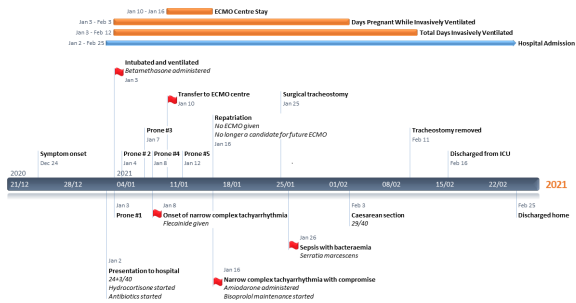


Figure 1 Timeline of pertinent events during the patient's admission. ECMO, extracorporeal membrane oxygenation; ICU, intensive care unit.

no fetal concerns identified. The patient did not tolerate the sensation of CPAP and was switched to high-flow nasal oxygen (HFNO) with an intensive care review requested in the emergency department. Due to ongoing symptoms and worsening gas exchange on serial arterial blood gas measurements, the patient was transferred to the ICU on HFNO with a fraction of inspired oxygen (FiO₂) of 0.75 at a flow rate of 50 L/min. Concomitantly, treatment had been started for severe COVID-19 infection with a 10-day course of hydrocortisone and empirical antibiotic cover of piperacillin-tazobactam and clindamycin.

TREATMENT

In the ICU, the patient continued to deteriorate on HFNO with profound tachypnoea and worsening gas exchange. She failed a further trial with CPAP and a decision was made to intubate and mechanically ventilate, with a lung protective ventilation strategy implemented for the treatment of her acute respiratory distress syndrome (ARDS). CT of the head and CT pulmonary angiogram (CTPA) were performed immediately following endotracheal intubation and they were unremarkable for any acute intracranial pathology or pulmonary embolism. The CTPA revealed dense right lower lobe consolidation on a background of extensive bilateral multifocal ground glass opacities (figures 3 and 4). A decision was made to delay delivery of the fetus as it was felt that the surgical stress and potential complications of a

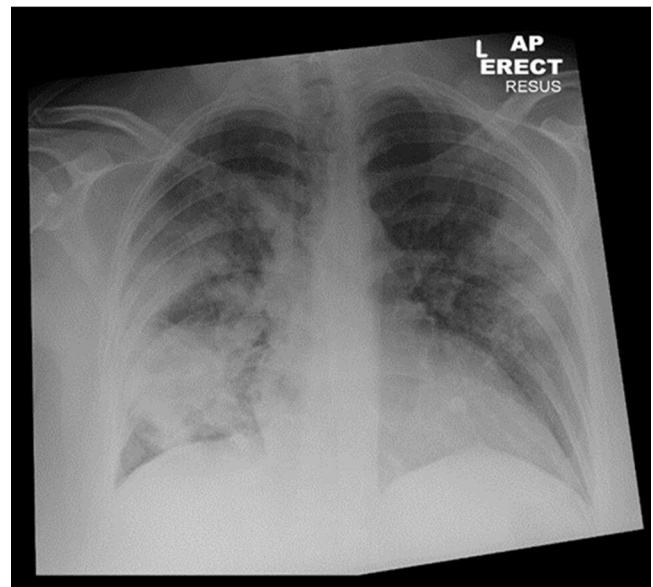


Figure 2 Day 0 admission: Anteroposterior erect chest X-ray which demonstrates bilateral, largely peripheral, multifocal airspace opacification with more confluent consolidation in the right lower zone.

likely technically challenging caesarean section would be detrimental to the patient. Given the patient's already rapid deterioration, discussions with the obstetric team led to antenatal corticosteroid administration of betamethasone to enhance fetal lung maturation and pre-empt preterm delivery. We are aware that the Royal College of Obstetricians and Gynaecologists (RCOG) have updated their guidance to suggest administering dexamethasone if corticosteroid use for fetal lung maturity is also desired; they then suggest switching the mother back to hydrocortisone or prednisolone¹ given that they are minimally transferred to the fetus. A perimortem caesarean kit was kept at the patient's bedside as a precaution.

Post-intubation, the patient maintained a PaO₂/FiO₂ ratio (PFR) of 15 despite ventilator optimisation, deep sedation, and

Table 1 Blood laboratory value comparisons from admission, day 21 and day 24 of hospital stay

Variables	Admission	Day 20	Day 24	Reference
Haemoglobin (g/L)	123	98	98	114–150
White cell count (×10 ⁹ /L)	8.0	5.2	8.4	4.2–11.2
Lymphocytes (×10 ⁹ /L)	1.5	1.3	2.0	1.1–3.6
Platelets (×10 ⁹ /L)	290	329	415	135–400
Mean cell volume (fl)	97.9	96.6	96.7	83.5–99.5
D-dimer (µg/L)	2355	2779	7693	<500
Fibrinogen (g/L)	6.6	5.80	7.27	1.90–4.30
Prothrombin time (s)	13	12.7	14.5	12.8–17.4
Activated partial thromboplastin time (s)	26.2	26.4	32.7	25.0–35.0
Sodium (mmol/L)	138	140	140	133–146
Potassium (mmol/L)	3.8	4.5	3.8	3.5–5.3
Urea (mmol/L)	2.0	3.2	4.8	2.5–7.8
Creatinine (µmol/L)	53	32	43	55–110
C-reactive protein (mg/L)	242	61	245	0.0–5.0
Procalcitonin (µg/L)	0.8	0.05		<0.5

Categories in bold delineate values that have been deranged on any of the 3 days. Blank fields mean blood marker was not tested on that day.

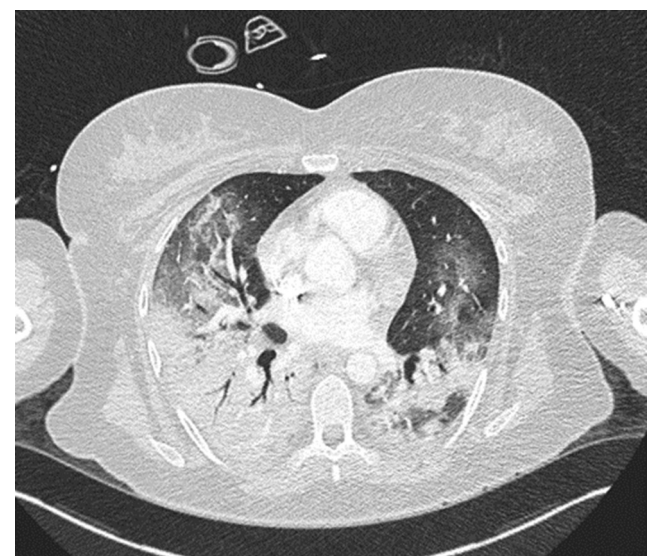

Figure 3 Day 1 admission: Axial slice of a CT chest in the lung window showing confluent consolidation in the dependent aspects of the lower lobes, more so on the right, with additional patchy ground-glass opacification seen elsewhere.

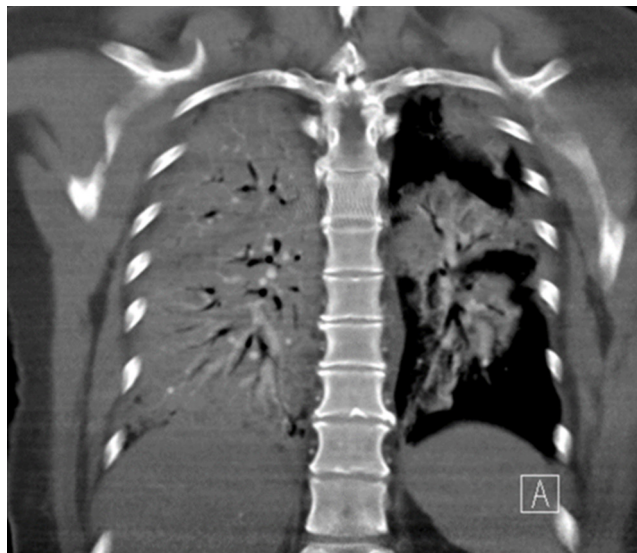


Figure 4 Day 1 admission: Coronal slice of a CT chest in the mediastinal window which shows dense right-sided consolidation with further multifocal consolidation on the left.

paralysis; it was felt that a trial of proning would be beneficial. The patient had her first proning manoeuvre on day 1 of her ICU admission and there were no fetal concerns. She demonstrated a good response in which her PFR incremented from 15 to 29 and her FiO_2 requirement reduced from 0.90 to 0.35 after 16 hours of being prone. Subsequent prones took place on days 2, 5, 6 and 10 of her ICU admission.

The patient developed a sustained narrow-complex tachyarrhythmia on day 7 of her admission with no associated haemodynamic compromise. Serial electrocardiograms revealed runs of sinus tachycardia, supraventricular tachycardia (SVT) and atrial fibrillation (AF), resistant to metoprolol and digoxin. Following discussion with the cardiology team, flecainide 150 mg intravenously was administered with successful cardioversion. Amiodarone, and its known effects on the fetal thyroid gland, was considered at the time but not required.

The association of COVID-19 with high rates of thromboembolic complications,⁷ and the fact that pregnancy is a hypercoagulable state meant we had a lower threshold for fully anticoagulating the patient. Anticoagulation with an unfractionated heparin infusion was started on day 7 due to concerns over a rising D-dimer exceeding 7000 $\mu\text{g/L}$ and findings of an internal jugular vein (IJV) thrombus with ultrasound (US) on central venous catheter siting. The patient had previously been receiving an enhanced two times per day regimen of low molecular weight heparin (LMWH) for venous thromboembolism prophylaxis with dosing titrated to achieve a target anti-Xa level of 0.2–0.4 IU/mL as per our hospital guidelines. The switch to unfractionated heparin allowed for quicker reversal of anticoagulation were the patient to have an emergency caesarean section.

Decreasing responses to proning with ongoing high oxygen requirements necessitated referral for extracorporeal membrane oxygenation (ECMO) therapy on day 8 of admission. Her Respiratory ECMO Survival Prediction (RESP) score was 5 and she was transferred to our regional ECMO unit. The patient was not initiated on ECMO following assessment and was prone once more while there. After a 7-day stay, she was deemed no longer a candidate for ECMO given her extended duration of invasive mechanical ventilation and was repatriated. On return, the patient still had a PFR of 16.

Table 2 Relevant positive microbiology from patient admission

Day of admission	Microbiology sample	Microorganisms
1	Combined oropharyngeal and nasal swab, real-time reverse transcription PCR	SARS-CoV-2
6	Sputum	Methicillin-resistant <i>Staphylococcus aureus</i>
14	Skin swab	Extended spectrum beta-lactamase <i>Escherichia coli</i>
14	Urinary catheter	<i>Enterococcus faecium</i>
22	Bronchial washings	<i>Raoultella ornithinolytica</i> , <i>Serratia marcescens</i>
24	Sputum	<i>Serratia marcescens</i>
24	Blood cultures	<i>Serratia marcescens</i>
25	Blood cultures	<i>Serratia marcescens</i>

On day 14 of her admission, the patient developed a further episode of narrow complex tachyarrhythmia (with similar runs of sinus tachycardia, SVT and AF) with haemodynamic compromise. This was resistant to labetalol and, after an MDT discussion, a decision was made to give a single dose of 300 mg intravenous amiodarone given her cardiovascular instability; this normalised her heart rate. The potential fetal risks of the amiodarone administration were acknowledged. Thereafter, the patient was started on regular bisoprolol for heart rate control. An echocardiogram performed to investigate the recurring tachyarrhythmias showed good biventricular function with no regional wall motion abnormalities and mild to moderate mitral regurgitation in the absence of any significant structural abnormality.

The patient's respiratory function went on to steadily improve with maintained cardiovascular stability. She was tolerating CPAP with assisted spontaneous breathing and had PFR of 30 with an FiO_2 of 0.35. To further aid respiratory and sedation weaning, improve secretion management and increase patient comfort, an elective tracheostomy was performed on day 23 of admission with an uneventful postoperative course.

Throughout her stay, the patient received multiple courses of antibiotics targeting positive microbiology (table 2) and raised inflammatory markers but initially had negative blood cultures. On day 24, the patient became septic from a *Serratia marcescens* (*S. marcescens*) bacteraemia, developing persistent fevers, hypotensive episodes, and rising inflammatory markers with intermittent need for vasopressor therapy in addition to aggressive fluid resuscitation. The source of the *S. marcescens* was unknown, and in the absence of an outbreak of the infection on our unit, a nosocomial source such as medical equipment or poor infection control practices, was felt to be unlikely. Patient carriage of the microorganism likely existed before her hospital admission; *S. marcescens* is an opportunistic organism that is known to be a commensal in the normal human microbiome^{8,9} with areas of colonisation including the nasopharynx.¹⁰ Seeding of the microorganism to cause a bacteraemia could have easily occurred from multiple sites including her respiratory tract (especially given *S. marcescens* growth from her sputum), urinary tract, and soft tissues. Indeed, the high number of invasive instrumentations carried out for central venous and urinary catheterisation along with the performance of a surgical tracheostomy greatly increased the chance of bacterial translocation to the bloodstream. *S. marcescens* becomes pathogenic and causes disease only in the suitably compromised host. Its ability to cause sepsis in our patient was further promoted by her immunocompromised state secondary to critical illness and corticosteroid use,

and the significant selective pressure caused by treatment with multiple broad-spectrum antibiotic regimens. A new antibiotic regimen of meropenem and amikacin was started and daily fetal cardiocotograph was introduced at 28 WG.

An MDT meeting involving obstetrics, anaesthetics, neonatology, and intensive care took place on day 27 of admission. It was collectively decided that after treatment and stabilisation of this septic episode, the opportunity should be taken, prior to any further recurrent deterioration and while respiratory function was still much improved with a stable cardiac rhythm, to deliver the baby in the patient's best interests. It was felt that a point had been reached whereby the risks to the patient posed by the physiological demands of a growing fetus and gravid uterus outweighed the risks of undertaking a surgical procedure. Delivery would ultimately improve her cardiovascular status and further facilitate her treatment and recovery, additionally making any future episodes of clinical deterioration easier to treat. Throughout her ICU admission, fetal growth scans were on the fifth percentile for the gestation, with normal amniotic fluid and normal fetal Doppler waveforms.

The patient responded well to treatment of her bacteraemia with reducing inflammatory markers and clinical stabilisation; an emergency caesarean section was performed on day 32 of admission at 29+0 WG. A baby boy was born and subsequently admitted to the neonatal intensive care unit (NICU). The operation was performed under general anaesthesia and was unremarkable with 350 mL estimated blood loss and no intraoperative complications.

In the days following delivery, the patient continued to make progress with her tracheostomy respiratory wean and physical rehabilitation. She was off all intravenous sedation by day 34 of admission and her tracheostomy was decannulated successfully on day 40. Repeat CXR showed significant resolution of lung field changes (figure 5). The patient was moved to the maternity high dependency unit and discharged from hospital 14 days later, ending a total 54 days of admission. US Doppler scans of the upper and lower limbs were performed prior to discharge to assess for thrombi given concerns earlier in the admission of possible IJV clot. Both scans demonstrated no acute echogenic thrombi in both the upper and lower limb major veins. The

patient's LMWH was subsequently reduced to a prophylactic dose.

OUTCOME AND FOLLOW-UP

The neonate, weighing 1164 g, was intubated immediately following delivery and a single dose of surfactant was given. In the NICU, he was extubated onto a Vapotherm high-flow respiratory support system of oxygen therapy 2 days later. His admission was complicated by necrotising enterocolitis (NEC) necessitating a 10 cm small bowel resection with an ileostomy and mucous fistula formation. Further complications while in the NICU included neonatal chronic lung disease (CLD) and late onset sepsis (LOS) from *Staphylococcus haemolyticus*. At the time of writing, the baby is 40 days old (34+5/40) and making a recovery in the NICU; he currently has requirements of 24% supplementary oxygen via high flow nasal cannulae. He is planned to return to theatre for stoma reversal within the next 2 weeks.

The mother continues to progress well with recovery in the community. She is to complete 6 weeks of prophylactic LMWH therapy. An outpatient echocardiogram and 24-hour ECG monitoring were performed (both unremarkable) and she was reviewed 2 weeks post discharge by the obstetric and cardiology teams with no concerns raised. She will additionally be seen by the outpatient physiotherapy and dietician teams.

This complex patient posed multiple management challenges requiring a dynamic and collaborative approach to decision-making. Treatment of differing clinical issues took priority throughout her admission including those of poor oxygenation, compromising tachyarrhythmias and septic shock. The mother's well-being was always paramount while we remained cognisant of the fact that prolongation of the pregnancy could improve fetal outcome. When to deliver the baby was repeatedly re-evaluated as we balanced the maternal risk of operative delivery with the benefits of alleviating the physiological demands posed by a growing fetus. The baby has suffered many of the complications of prematurity; however, prolongation of pregnancy for 32 days helped reduce his risks of more severe morbidity and mortality.

DISCUSSION

Increased disease severity of COVID-19 in pregnant women and the possible contributing physiological changes

The true interaction between COVID-19 and pregnancy requires further elucidation. Current data suggest that compared with non-pregnant women with COVID-19, infected pregnant women have more severe disease but no overall increase in mortality.¹⁻⁴ There is an increased likelihood of ICU admission and invasive ventilation along with an overall worse maternal outcome when compared with infected non-pregnant women. To date, the largest retrievable study demonstrating these conclusions is that by Allotey *et al* with the PregCOV-19 Living Systematic Review Consortium analysis²; this prospective study involved greater than 11 000 patients across 30 countries. Additional studies from the USA,³ Mexico,⁴ and France¹¹ have also reported similar findings. Several limitations exist with these studies including the inability to distinguish admission indication (those for pregnancy vs those for COVID-19) and missing pregnancy status in a large proportion of patients; this contributes to bias with results interpretation. There are currently no robust data from the UK comparing pregnant and non-pregnant women with COVID-19¹ and extrapolation of findings from the aforementioned studies needs to be done with caution given said

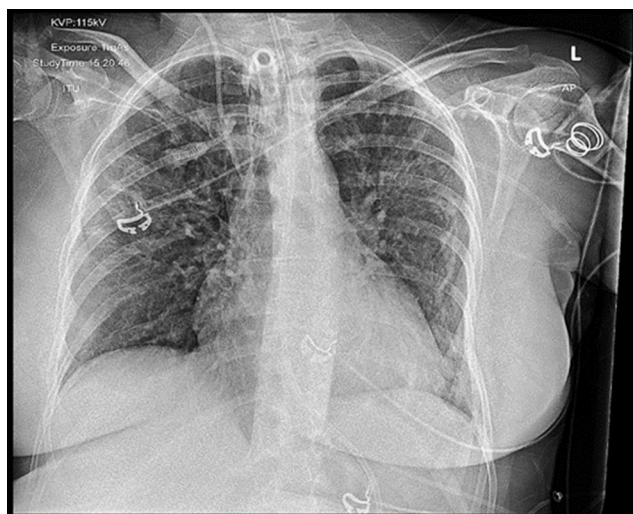


Figure 5 Day 40 admission: Anteroposterior erect chest X-ray demonstrating significant resolution of previous bilateral multifocal airspace opacification and right lower zone consolidation.

biases and the differing healthcare infrastructures and population characteristics of the countries involved.

The physiological changes during pregnancy could explain, in part, the proposed increased disease severity of COVID-19 in pregnant women. Respiratory and immune system adaptations can cause vulnerability to viral infections. Decreased chest wall compliance during pregnancy in combination with diaphragmatic splinting, secondary to a gravid uterus, results in a reduced chest volume and functional residual capacity.^{7 12} Additionally, impaired secretion clearance, due to progesterone-mediated mucosal surface hyperaemia and oedema, produces a state whereby women can be more susceptible to severe respiratory infections and rapid decompensation.⁷ The immunoregulatory changes that occur during pregnancy likely influence the immune system response to COVID-19. Altered production of certain immune mediators can impede clearance of viral infections. Increases in Th2 phenotype CD4 + cells and a reduction in natural killer cells and plasmacytoid dendritic cells (pDCs) can lead to altered clearance of virally infected cells.⁷ Indeed, reduced pDCs were felt to be one of the reasons pregnant women were so severely affected by the H1N1 pandemic in 2009.⁷ Hormonal changes during pregnancy also influence the immune system; notably, increased progesterone levels are known to have immunosuppressive effects, generally inhibiting inflammatory innate immune responses.¹³ Overall, further research is required to investigate the complex interplay between physiological adaptations in pregnancy and any consequences these have on COVID-19 severity.

Increased risk of preterm birth in symptomatic COVID-19 pregnant women is likely to lead to increased incidence of prematurity-related neonatal complications

Currently, symptomatic maternal COVID-19 has been shown to cause up to a three times greater risk of preterm birth¹ (mainly iatrogenic preterm birth for maternal reasons as opposed to for fetal distress) when compared with pregnant women without COVID-19; this is something that has been demonstrated by several studies including that by Allotey *et al*² and the UK Obstetric Surveillance System (UKOSS) study.⁵ Curiously, despite the increased likelihood of preterm birth, the data do not show COVID-19 causes poor fetal or neonatal outcomes in this population. Given that preterm birth is the single biggest cause of neonatal morbidity and mortality in the UK, it may well be that later studies find contrasting outcomes. Clinicians should bear this in mind during discussions with patients and their next of kin. Fetal monitoring of our patient's baby during her ICU stay was always reassuring but the baby did go on to develop the prematurity-related diseases of CLD, LOS and NEC. NEC is one of the most common life-threatening emergencies of the preterm infant, with prematurity being the most predominant risk factor; it occurs in up to 10% of all premature infants and carries with it an associated mortality as high as 30%.^{14 15}

Proning in pregnant patients with COVID-19 can be beneficial and undertaken in a safe manner

With support from the obstetric team, we decided to prone our patient at points in her care where we felt this was clinically indicated. To date, there is very little in the way of formal guidance available for the use of proning in pregnant patients with severe ARDS; in fact, guidance in the UK from the Intensive Care Society identifies it as relatively contraindicated in the second and third trimesters of pregnancy.¹⁶ However, data and expert anecdotal input suggest that pregnant women can

safely be proned and advocate its use¹⁷ given the relief from the compressive effects of a gravid uterus it provides.¹⁸ Our case adds to the growing body of literature demonstrating the safety, feasibility and benefit of proning in pregnancy.¹⁷⁻¹⁹ Helpfully, a review article by Tolcher *et al* provides a clinical guideline, algorithm and illustrations to help aid optimal proning in the second and early third trimesters.¹⁹

Increased inclusion of pregnant women in COVID-19 therapeutic trials will be beneficial

Despite the acknowledged vulnerability of, and concern for, pregnant women during the SARS-CoV-2 pandemic, clinical trials continue to exclude pregnant patients with over 300 doing so almost universally.⁶ Exclusions have even occurred with trials investigating repurposed drugs that have a well-established safety record in pregnancy; for example, hydroxychloroquine and lopinavir plus ritonavir.⁷ The inclusion of pregnant women in COVID-19 trials is crucial to achieving better management of COVID-19 in pregnancy, and pregnant women should be offered the opportunity to maintain their autonomy and enrol.

Acknowledgements We would like to thank Dr Marcela Vizcaychipi, Dr Linsey Christie, Dr Makrina Sawidou, and Dr Samir Alwan for their contributions, guidance, and supervision in producing this work. We would also like to thank the medical and nursing teams of the ICU and Obstetrics Unit at Chelsea and Westminster Hospital for their collective efforts in helping our patient return home from hospital.

Contributors The patient was under the care of KOA, KS and MB. All authors contributed substantially to the manuscript and were responsible for drafting the work and critically revising it. All authors approved the final version of the manuscript and accepted accountability for all aspects of the work. KOA is the guarantor.

Funding The authors have not declared a specific grant for this research from any funding agency in the public, commercial or not-for-profit sectors.

Competing interests None declared.

Patient consent for publication Obtained.

Learning points

- ▶ Severe COVID-19 infection in pregnancy is not in itself an indication for expedited delivery and an individualised multidisciplinary approach must be taken. Maternal stabilisation prior to delivery is the priority and safe prolongation of pregnancy will allow for further fetal maturation and optimisation of neonatal outcome.
- ▶ Current accessible literature suggests pregnant patients are at risk of increased disease severity from COVID-19.
- ▶ Current data point towards increased risk of preterm birth for pregnant women who are symptomatic with COVID-19 but suggest no increase in adverse fetal or neonatal outcomes. Preterm birth is the biggest cause of neonatal morbidity and mortality in the UK and clinicians need to be aware of this. Despite current findings, further studies will be required and will help guide family/next of kin discussions regarding neonatal outcomes.
- ▶ Proning when managing pregnant women with severe COVID-19 acute respiratory distress syndrome should be considered if clinically indicated and can be carried out safely and effectively at least until the early third trimester.
- ▶ Further research on COVID-19 in pregnancy is crucial to facilitate better management and a big factor in achieving this will be increasing full inclusion of pregnant women in therapeutic clinical trials.

Provenance and peer review Not commissioned; externally peer reviewed.

This article is made freely available for use in accordance with BMJ's website terms and conditions for the duration of the covid-19 pandemic or until otherwise determined by BMJ. You may use, download and print the article for any lawful, non-commercial purpose (including text and data mining) provided that all copyright notices and trade marks are retained.

ORCID iD

Kaladerhan Osemwengie Agbontaen <http://orcid.org/0000-0002-5571-230X>

REFERENCES

- 1 Coronavirus (COVID-19) Infection in Pregnancy [Internet]. Royal College of obstetricians and gynaecologists, the Royal College of midwives, Royal College of paediatrics and child health, public health England and public health Scotland, 2021. Available: <https://www.rcog.org.uk/globalassets/documents/guidelines/2021-02-19-coronavirus-covid-19-infection-in-pregnancy-v13.pdf> [Accessed 10 Mar 2021].
- 2 Allotey J, Stallings E, Bonet M, *et al*. Clinical manifestations, risk factors, and maternal and perinatal outcomes of coronavirus disease 2019 in pregnancy: living systematic review and meta-analysis. *BMJ* 2020;370:m3320.
- 3 Zambrano LD, Ellington S, Strid P, *et al*. Update: Characteristics of Symptomatic Women of Reproductive Age with Laboratory-Confirmed SARS-CoV-2 Infection by Pregnancy Status - United States, January 22-October 3, 2020. *MMWR Morb Mortal Wkly Rep* 2020;69:1641-7.
- 4 Martinez-Portilla RJ, Sotiriadis A, Chatzakis C, *et al*. Pregnant women with SARS-CoV-2 infection are at higher risk of death and pneumonia: propensity score matched analysis of a nationwide prospective cohort (COV19Mx). *Ultrasound Obstet Gynecol* 2021;57:224-31.
- 5 Vousden N, Bunch K, Morris E, *et al*. The incidence, characteristics and outcomes of pregnant women hospitalized with symptomatic and asymptomatic SARS-CoV-2 infection in the UK from March to September 2020: a national cohort study using the UK obstetric surveillance system (UKOSS). *PLoS One* 2021;16:e0251123.
- 6 Whitehead CL, Walker SP. Consider pregnancy in COVID-19 therapeutic drug and vaccine trials. *Lancet* 2020;395:e92.
- 7 Wastnedge EAN, Reynolds RM, van Boeckel SR, *et al*. Pregnancy and COVID-19. *Physiol Rev* 2021;101:303-18.
- 8 Amarsy R, Pean de Ponfilly GR, Benmansour HA, *et al*. Serratia marcescens outbreak in the intensive care unit during the COVID-19 pandemic: a paradoxical risk? *Med Mal Infect* 2020;50:750-1.
- 9 Mahlen SD. Serratia infections: from military experiments to current practice. *Clin Microbiol Rev* 2011;24:755-91.
- 10 Allen EK, Pitkäranta A, Mäki M, *et al*. Bacteria in the nose of young adults during wellness and rhinovirus colds: detection by culture and microarray methods in 100 nasal lavage specimens. *Int Forum Allergy Rhinol* 2013;3:731-9.
- 11 Badr DA, Mattern J, Carlin A, *et al*. Are clinical outcomes worse for pregnant women at ≥ 20 weeks' gestation infected with coronavirus disease 2019? A multicenter case-control study with propensity score matching. *Am J Obstet Gynecol* 2020;223:764-8.
- 12 Chen M, Zeng J, Liu X, *et al*. Changes in physiology and immune system during pregnancy and coronavirus infection: a review. *Eur J Obstet Gynecol Reprod Biol* 2020;255:124-8.
- 13 Hall OJ, Klein SL. Progesterone-based compounds affect immune responses and susceptibility to infections at diverse mucosal sites. *Mucosal Immunol* 2017;10:1097-107.
- 14 Masi AC, Stewart CJ. The role of the preterm intestinal microbiome in sepsis and necrotising enterocolitis. *Early Hum Dev* 2019;138:104854.
- 15 Silverman MA, Konnikova L, Gerber JS. Impact of antibiotics on necrotizing enterocolitis and antibiotic-associated diarrhea. *Gastroenterol Clin North Am* 2017;46:61-76.
- 16 Guidance For: Prone Positioning in Adult Critical Care [Internet]. Intensive care Society and faculty of intensive care medicine UK, 2019. Available: <file:///C:/Users/Wip%20User/Downloads/Prone%20position%20in%20adult%20critical%20care%202019.pdf> [Accessed 10 Mar 2021].
- 17 Ray BR, Trikha A. Prone position ventilation in pregnancy: concerns and evidence. *J Obstet Anaesth Crit Care* 2018;8:7.
- 18 Jacobson J, Antony K, Beninati M, *et al*. Use of dexamethasone, remdesivir, convalescent plasma and prone positioning in the treatment of severe COVID-19 infection in pregnancy: a case report. *Case Rep Womens Health* 2021;29:e00273.
- 19 Tolcher MC, McKinney JR, Eppes CS, *et al*. Prone positioning for pregnant women with hypoxemia due to coronavirus disease 2019 (COVID-19). *Obstet Gynecol* 2020;136:259-61.

Copyright 2021 BMJ Publishing Group. All rights reserved. For permission to reuse any of this content visit <https://www.bmj.com/company/products-services/rights-and-licensing/permissions/>
BMJ Case Report Fellows may re-use this article for personal use and teaching without any further permission.

Become a Fellow of BMJ Case Reports today and you can:

- ▶ Submit as many cases as you like
- ▶ Enjoy fast sympathetic peer review and rapid publication of accepted articles
- ▶ Access all the published articles
- ▶ Re-use any of the published material for personal use and teaching without further permission

Customer Service

If you have any further queries about your subscription, please contact our customer services team on +44 (0) 207111 1105 or via email at support@bmj.com.

Visit casereports.bmj.com for more articles like this and to become a Fellow