

MEETING ABSTRACT

Open Access

Combining MRI with PET for partial volume correction improves image-derived input functions in mice

Eleanor Evans^{1*}, Guido Buonincontri¹, David Izquierdo², Carmen Methner³, Rob C Hawkes¹, Richard E Ansorge⁴, Thomas Kreig³, T Adrian Carpenter¹, Stephen J Sawiak^{1,5}

From PSMR14: 3rd Conference in PET/MR and SPECT/MR
Kos Island, Greece. 19-21 May 2014

¹Wolfson Brain Imaging Centre,
University of Cambridge,
Cambridge, UK

Kinetic modelling in PET requires the arterial input function (AIF), defined as the time-activity curve (TAC) in plasma. This measure is challenging to obtain in mice due to low blood volumes, resulting in a reliance on image-based methods for AIF derivation. We present a comparison of PET- and MR-based region-of-interest (ROI) analysis to obtain image-derived AIFs from the left ventricle (LV) of a mouse model. ROI-based partial volume correction (PVC) was performed to improve quantification.

MRI and dynamic PET images were obtained from a recent study investigating treatment effects in 12 mice following myocardial infarction [1], where half the mice received a new treatment and half did not. Prospectively gated MRI (4.7T Bruker BioSpec, FLASH TR/TE 400/3ms, spatial resolution 140 μ m in 1mm slices) were acquired prior to PET acquisition (approx. 25MBq ¹⁸F-FDG bolus, 45 minute emission listmode acquisition reconstructed with 3DRP in four cardiac frames) on a split-magnet PET camera [2]. Images were co-registered using SPMMouse [3] (see Figure 1).

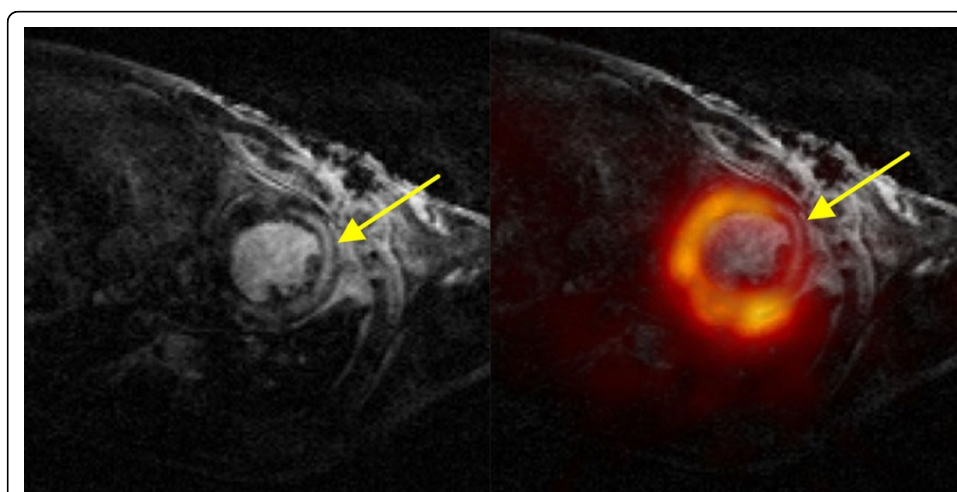


Figure 1 Mouse heart MR (left) and fused with ¹⁸F-FDG static PET (right). Arrow indicates infarcted region.

AIF extraction AIFs were obtained by taking mean time courses from LV Lumen ROIs, shown in Figure 2. The regional geometric transfer matrix (GTM) method was applied for PVC [4], using ROIs drawn on either the co-registered MR images or directly onto the last dynamic frame PET images. ROIs covered LV lumen,

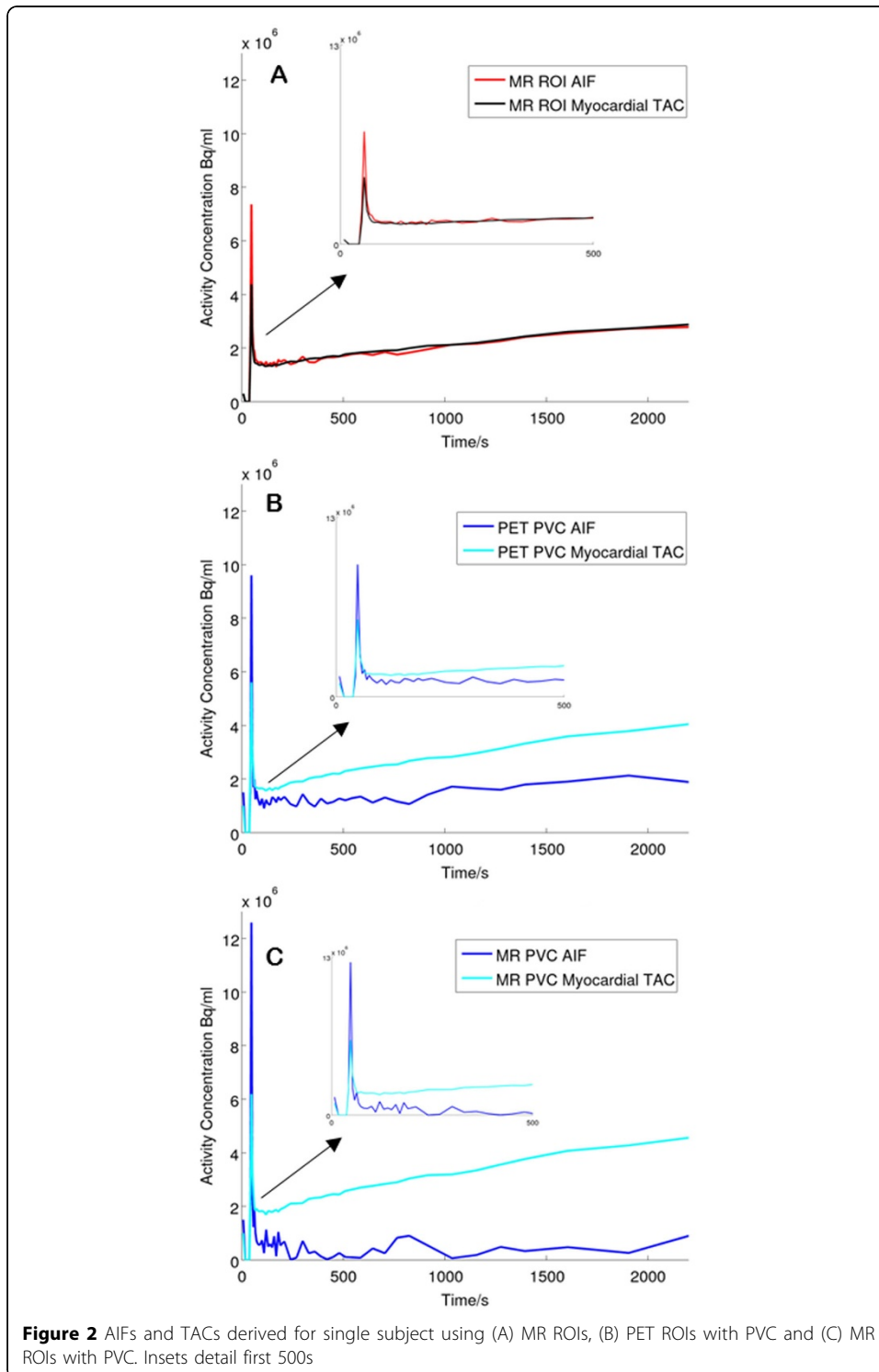


Figure 2 AIFs and TACs derived for single subject using (A) MR ROIs, (B) PET ROIs with PVC and (C) MR ROIs with PVC. Insets detail first 500s

Table 1

Group	Glucose metabolism K_i (ml/min/cm ³), Mean \pm SD			
	Without PVC		With PVC	
	PET ROIs	MR ROIs	PET ROIs	MR ROIs
Untreated	0.03 \pm 0.01	0.03 \pm 0.01	0.4 \pm 0.3	0.6 \pm 0.2*
Treated	0.03 \pm 0.01	0.03 \pm 0.02	0.2 \pm 0.3	0.2 \pm 0.2*

myocardium, lungs/body and background. Patlak [5] analysis was performed to evaluate glucose metabolism.

Uncorrected AIFs and myocardial TACs produced by manual ROI delineation displayed contamination with myocardial signal. AIFs and myocardial curves became distinguishable if GTM PVC was applied. Only MR-based PVC produced significant differences ($p < 0.05$) in K_i values between the treated and untreated groups (see Table 1).

GTM-based PVC gives best results in mice when ROIs are based on MRI data, due to its high-resolution and excellent soft-tissue contrast.

Authors' details

¹Wolfson Brain Imaging Centre, University of Cambridge, Cambridge, UK. ²Athinoula A Martinos Centre, Harvard University, Cambridge, MA, USA. ³Department of Medicine, University of Cambridge, Cambridge, UK. ⁴Department of Physics, University of Cambridge, Cambridge, UK. ⁵Behavioural and Clinical Neurosciences Institute, University of Cambridge, Cambridge, UK.

Published: 29 July 2014

References

1. Methner C, et al: **Riociguat Reduces Infarct Size and Post-Infarct Heart Failure in Mouse Hearts: Insights from MRI/PET Imaging.** *PLoS One* 2013, **8**(12):e83910, DOI: 10.1371/journal.pone.0083910.
2. Lucas AJ, et al: **Development of a combined microPET⁺-MR system.** *IEEE Nucl Sci Symp Record* 2006, **4**:2345-8.
3. Sawiak SJ, et al: **MRI reveals brain asymmetry following 6-OHDA lesions in the mouse brain.** *Proc. ISMRM 2009*, **17**:1077[http://cds.ismrm.org/protected/09MProceedings/files/01077.pdf].
4. Rousset OG, et al: **Correction for partial volume effects in PET: principle and validation.** *J Nucl Med* 1998, **39**(5):904-911.
5. Patlak CS, et al: **Graphical evaluation of blood-to-brain transfer constants from multiple-time uptake data.** *J Cereb Blood Flow Metab* 1983, **3**(1):1-7.

doi:10.1186/2197-7364-1-S1-A84

Cite this article as: Evans et al.: Combining MRI with PET for partial volume correction improves image-derived input functions in mice. *EJNMMI Physics* 2014 **1**(Suppl 1):A84.

Submit your manuscript to a SpringerOpen[®] journal and benefit from:

- Convenient online submission
- Rigorous peer review
- Immediate publication on acceptance
- Open access: articles freely available online
- High visibility within the field
- Retaining the copyright to your article

Submit your next manuscript at ► springeropen.com