

# Mini-open Subpectoral Biceps Tenodesis Using All-Suture Anchor



Abbott Gifford, Tracy Tauro, B.S., B.A., Eric Haunschild, B.S., Kelechi Okoroha, M.D., and Brian J. Cole, M.D., M.B.A.

**Abstract:** The proximal biceps tendon is a common source of shoulder pain and dysfunction. When patients continue to have pain after exhaustive nonoperative treatment, the long head of the biceps tendon can be effectively treated with a tenotomy or tenodesis. Although biceps tenotomy is a less complex and highly reliable treatment, there is the potential for suboptimal outcomes including muscle cramping, fatigue, cosmetic deformity, and supination weakness. Biceps tenodesis eliminates the source of shoulder pain while securing the tendon proximally. Currently, there are multiple techniques for performing a biceps tenodesis (arthroscopic, open suprapectoral, open subpectoral) and myriad fixation methods (bio-tenodesis screw, bone bridge, cortical button, all-suture anchor). Our article presents a technique for a mini-open subpectoral biceps tenodesis using an onlay technique with an all-suture anchor preloaded with needles. This technique allows efficient and proper tendon fixation while minimizing potential complications.

Pathology of the shoulder relating to the long head of the biceps (LHB) tendon can indicate a variety of different surgical treatments ranging from debridement to tenotomy and tenodesis depending on the specific patient characteristics. These surgical procedures are a viable next step for patients in whom all nonoperative management options have been exhausted and who have conditions including partial tearing of the biceps, biceps instability, subscapularis tendon tears, tenosynovitis, high-grade SLAP tears, and positive clinical

examination findings for LHB pain.<sup>1</sup> Surgery may also be indicated for patients who have specific rotator cuff pathologies and glenohumeral degenerative joint disease.<sup>2</sup> The senior author (B.J.C.) typically terminally indicates patients for biceps treatment after a reduction in symptoms immediately after an ultrasound-guided injection that includes local anesthetic.

Although some literature supports biceps tenotomy over tenodesis as a less complicated and more

From the Department of Orthopaedic Surgery, Division of Sports Medicine, Section of Cartilage Restoration, Rush University Medical Center, Chicago, Illinois, U.S.A.

The authors report the following potential conflicts of interest or sources of funding: B.J.C. receives research support and IP royalties from and is a paid consultant for Arthrex; receives research support from Aesculap and NIH; receives other financial or material support from Athletico, JRF Ortho, and Smith & Nephew; receives IP royalties from Elsevier Publishing; receives publishing royalties and financial or material support from OTSM; receives stock or stock options from Ossio; and is a paid consultant for and receives research support and stock or stock options from Regentis. Full ICMJE author disclosure forms are available for this article online, as supplementary material.

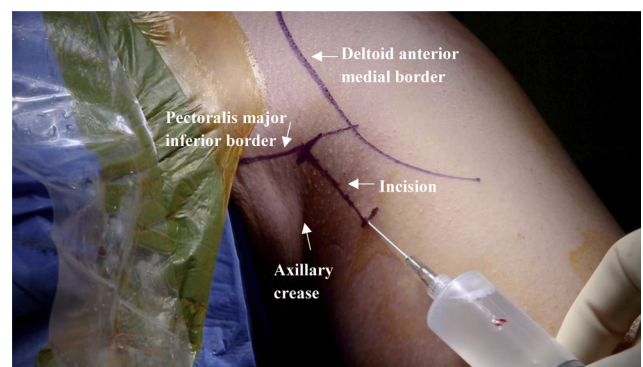
Received October 1, 2019; accepted November 19, 2019.

Address correspondence to Brian J. Cole, M.D., M.B.A., Department of Orthopaedic Surgery, Rush University Medical Center, 1611 W Harrison St, Ste 300, Chicago, IL 60612, U.S.A. E-mail: [bcole@rushortho.com](mailto:bcole@rushortho.com)

© 2020 by the Arthroscopy Association of North America. Published by Elsevier. This is an open access article under the CC BY-NC-ND license (<http://creativecommons.org/licenses/by-nc-nd/4.0/>).

2212-6287/191207

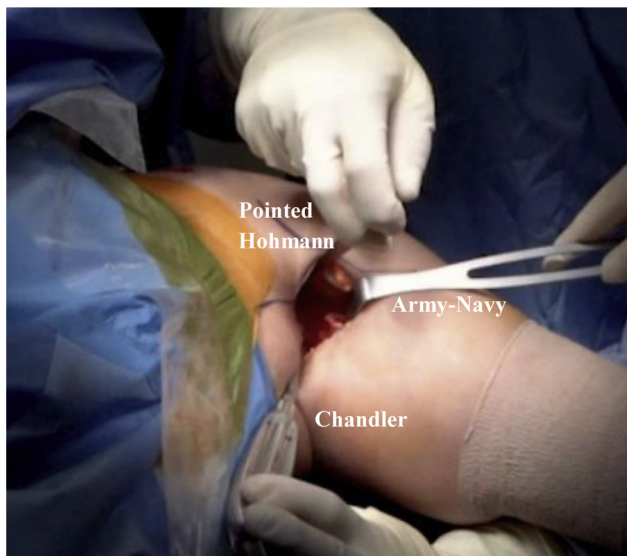
<https://doi.org/10.1016/j.eats.2019.11.017>



**Fig 1.** Intraoperative image of the left shoulder marked and draped to prepare for open biceps tenodesis. The patient is in the beach-chair position, and the arm is abducted 20° to 30°. A 3-cm longitudinal incision is marked just beneath the inferior border of the pectoralis major and medial to the anterior-medial border of the deltoid while remaining lateral to the axillary crease. Local anesthesia is administered to cover areas that are not predictably covered by the regional anesthesia, typically along the incision line.

reliable procedure, tenotomy may lead to a Popeye deformity and loss of supination strength.<sup>3</sup> More recent articles have shown that tenodesis provides better cosmesis, endurance, and strength outcomes in comparison to simple tenotomy and yields extremely low revision rates.<sup>4,5</sup> For these reasons, in our practice, tenotomy is reserved for patients who are at elevated risk of infection or for whom these factors are not relevant. In addition, tenodesis is especially indicated in younger athletes, with two-thirds of the population able to return to sport after surgery.<sup>6,7</sup>

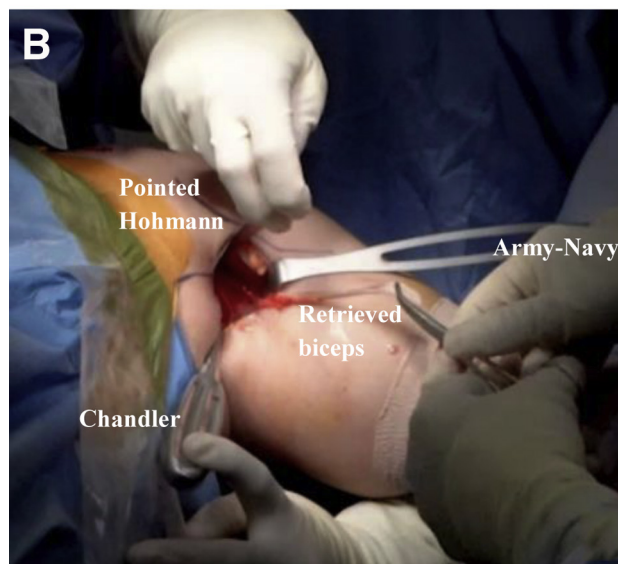
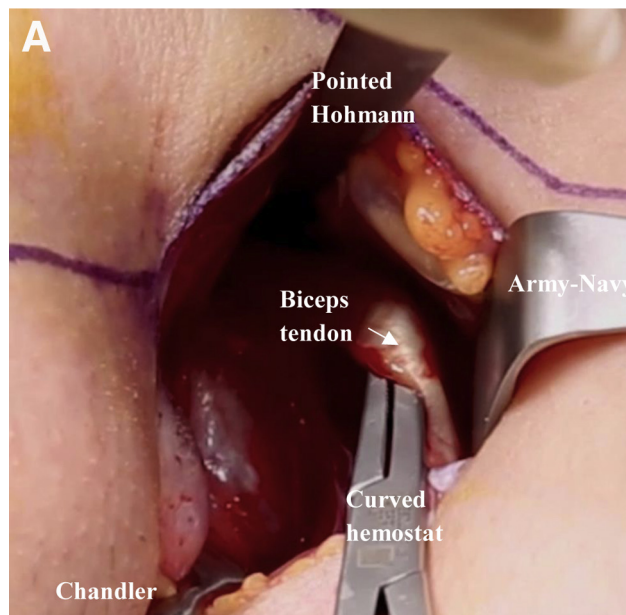
Biceps tenodesis can be performed using a variety of techniques including an arthroscopic versus open approach, proximal versus distal attachment, and numerous methods of suture fixation. We prefer a mini-open subpectoral biceps tenodesis because the literature and our experience suggest this procedure is accompanied by minimal residual pain and stiffness, as well as reliable clinical outcomes and a low complication rate.<sup>8-10</sup> We present the primary method of biceps tenodesis of the senior author (B.J.C.) using a mini-open subpectoral onlay technique with a double-loaded all-suture anchor (Biceps FiberTak; Arthrex, Naples, FL) loaded with broad 1.3-mm suture tape and swedged-on needles that prevent slippage while allowing the anchor to enter a small-diameter (1.9-mm) drill hole, which minimizes the risk of post-operative complications including fracture.



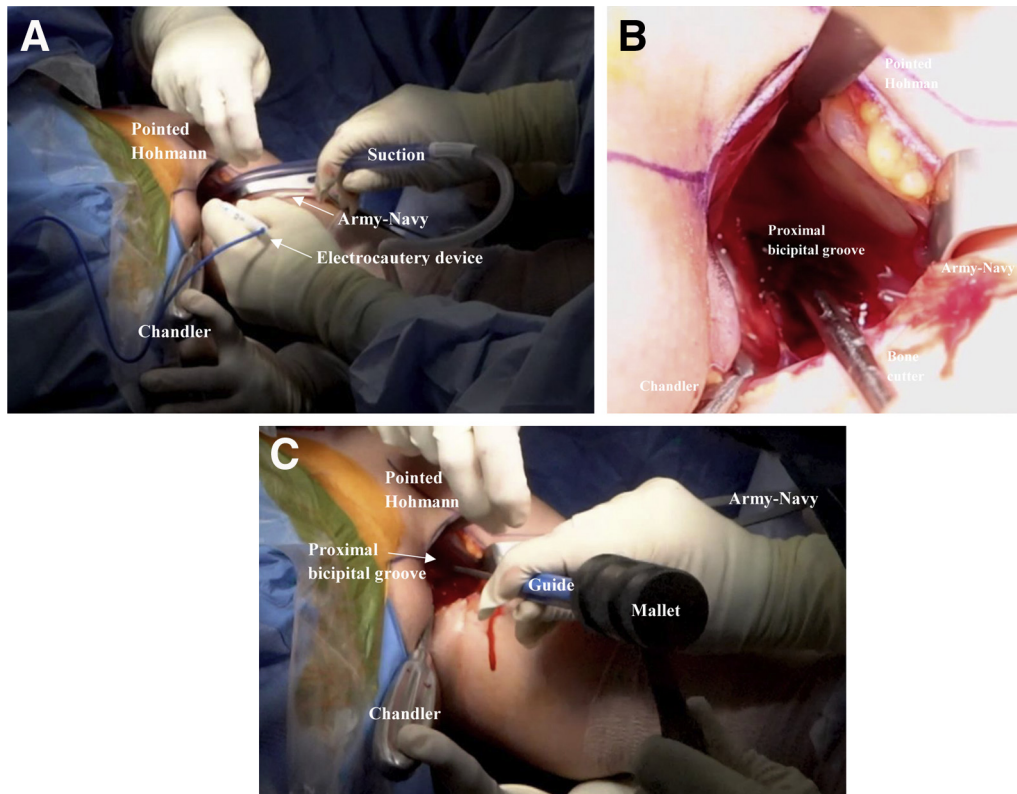
**Fig 2.** Intraoperative image of the left shoulder with the patient in the beach-chair position and the arm abducted 20° to 30°. The soft tissue is dissected, an Army-Navy retractor is placed laterally for exposure, and a Chandler retractor is placed medially adjacent to the humerus under minimal tension. A pointed Hohmann retractor is placed over the top, underneath the deltoid and pectoralis major junction.

## Positioning and Preparation

Before surgery, the patient is given an interscalene nerve block and placed under conscious sedation. An examination under anesthesia is performed to assess



**Fig 3.** Intraoperative image of the left shoulder with the patient in the beach-chair position and the arm abducted 20° to 30°. An Army-Navy retractor is placed laterally for exposure; a Chandler retractor is placed medially adjacent to the humerus under minimal tension; and a pointed Hohmann retractor is placed over the top, underneath the deltoid and pectoralis major junction. (A) After the biceps is located by use of finger palpation on the anterior aspect of the humerus, the biceps tendon is isolated using a curved hemostat. (B) The previously arthroscopically released biceps tendon is retrieved from the proximal aspect of the joint and secured with a hemostat.



**Fig 4.** Intraoperative image of the left shoulder with the patient in the beach-chair position and the arm abducted  $20^{\circ}$  to  $30^{\circ}$ . An Army-Navy retractor is placed laterally for exposure; a Chandler retractor is placed medially adjacent to the humerus under minimal tension; and a pointed Hohmann retractor is placed over the top, underneath the deltoid and pectoralis major junction. (A) An electrocautery device is used to create a landing zone at the bicipital groove. (B) A bone cutter is used to excoriate the landing-zone surface. (C) The desired area of the humerus is gently fish scaled using the drill guide and mallet to promote healing.

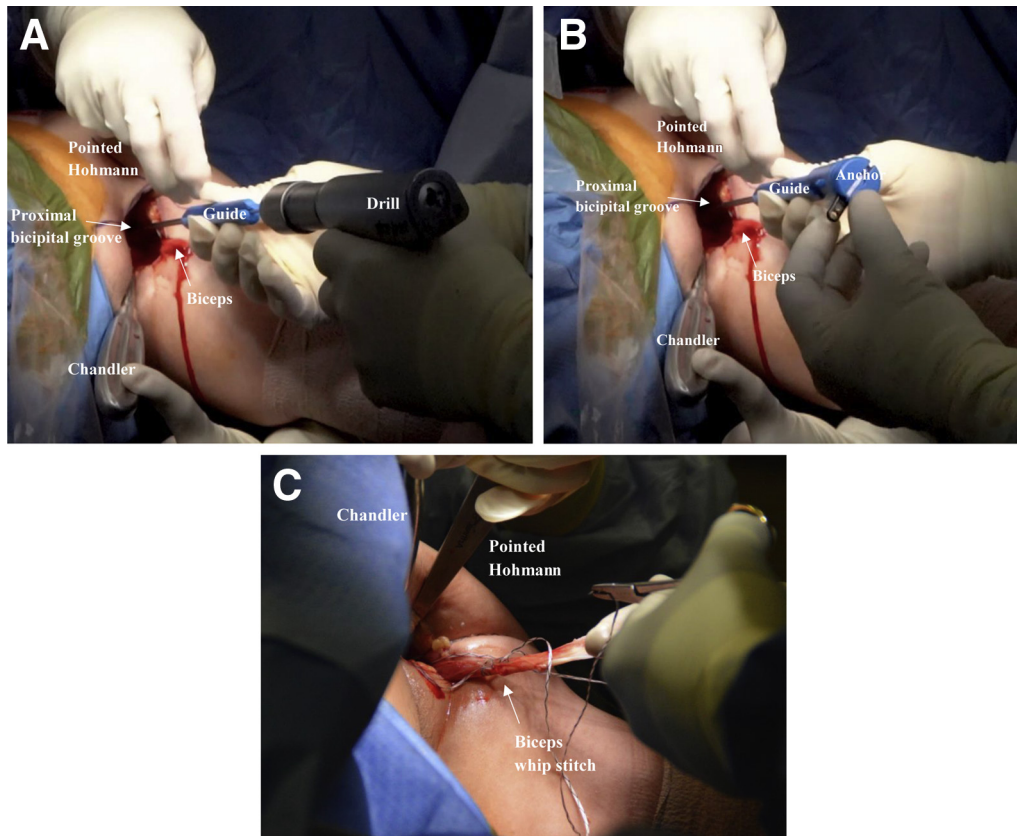
the patient's passive range of motion and stability. The patient is then secured in the beach-chair position, and the surgical site is prepared and draped in a standard fashion.

### Surgical Technique

A standard diagnostic arthroscopy is performed to evaluate the glenoid, humeral head, labrum, rotator cuff, and biceps tendon for possible pathology. The biceps is examined and pulled into the joint with a probe to inspect along the length of the tendon. Any erythema, fraying, or partial tears are correlated with the patient's symptoms, and a decision is made on treatment of the biceps. The stability of the biceps is also assessed as it relates to the upper border of the subscapularis tendon and the rotator interval–biceps sling. After the surgeon decides to proceed with the biceps tenodesis, an arthroscopic basket is introduced from the anterior portal while viewing from the posterior portal. The LHB is then incised at its attachment to the superior labrum with the basket (Video 1). An arthroscopic shaver (Torpedo; Arthrex) is used as needed to remove any residual biceps tendon. Before the biceps is secured with a mini-open approach, any additional pathology

relating to the shoulder, such as rotator cuff or labral tears, is addressed.

To perform the tenodesis portion of the procedure, the head of the bed is reclined an additional  $20^{\circ}$  to  $30^{\circ}$ . The arm is slightly supinated and abducted. A marking pen is used to mark the longitudinal incision just lateral to the axillary crease, and local anesthesia is administered at the incision site (Fig 1, Video 1). A small (3-cm) longitudinal incision is made just beneath the inferior border of the pectoralis major and just medial to the anterior-medial border of the deltoid but lateral to the axillary crease (Video 1). The subcutaneous tissue and fascial layer are exposed using Metzenbaum scissors, and the fascia is entered inferior to the pectoralis major and lateral to the short head of the biceps (Video 1). A subpectoral plane is then established in the direction of the humerus via blunt finger dissection, and the LHB tendon can be palpated in the bicipital groove adjacent to the pectoralis major tendon edge (Video 1). The LHB tendon is better visualized by placing a small pointed Hohmann retractor under the junction of the pectoralis major and anterior-lateral border of the deltoid (Fig 2, Video 1). A Chandler retractor can be carefully placed on the medial aspect of the humerus; the neurovascular

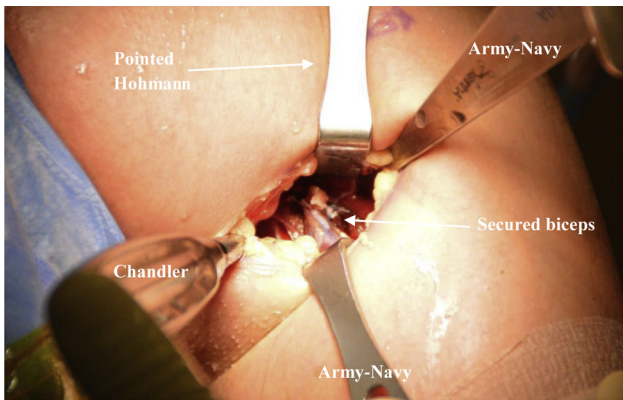


**Fig 5.** Intraoperative image of the left shoulder with the patient in the beach-chair position and the arm abducted 20° to 30°. An Army-Navy retractor is placed laterally for exposure; a Chandler retractor is placed medially adjacent to the humerus under minimal tension; and a pointed Hohmann retractor is placed over the top, underneath the deltoid and pectoralis major junction. (A) The straight, slotted drill guide is placed on the prepared surface of the desired proximal bicipital groove, and a 1.9-mm hole is drilled. (B) While the position of the drill guide is being maintained, a double-loaded all-suture anchor (Biceps FiberTak) is carefully impacted into the drill hole using a mallet or palm. (C) Anchor fixation has been established, and a running, reinforced suture is passed through the biceps. One side of each suture pair is passed through the biceps over a 2-cm length, about 1 cm proximal to the musculotendinous junction.

structures that lie medially should be avoided (Fig 2, Video 1). The relative position of the muscle-tendon junction along the length of the humerus and distal biceps groove is identified and marked using electrocautery to best re-establish normal tension after tenodesis. The previously released LHB tendon is then retrieved using a finger or curved hemostat (Fig 3, Video 1).

Electrocautery is used to decorticate a 1.5 × 1.5-cm area in the subpectoral region at the proximal aspect of the exposure (Fig 4A, Video 1). An arthroscopic bone cutter is also used to decorticate the bone (Fig 4B, Video 1). The area of the humeral cortex to which the remaining LHB tendon is to be attached is “fish scaled” using the drill guide or osteotome and mallet (Fig 4C, Video 1). This process stimulates bony bleeding, which augments healing and prevents the tendon from migrating once attached. By use of a straight, slotted drill guide placed in the desired location of the proximal bicipital groove, a 1.9-mm

hole is drilled (Fig 5A, Video 1). With the position of the drill guide being maintained, a double-loaded all-suture anchor (Biceps FiberTak) is carefully impacted into the drill hole (Fig 5B, Video 1). Once anchor fixation is established, 1 suture from each pair is passed through the LHB tendon with running, reinforced sutures over a 2-cm length of the tendon (Fig 5C, Video 1). The location chosen for the sutures is generally 1 cm from the musculotendinous junction to re-create normal tendon tension. The opposite ends of the paired sutures that were not passed are then used to tension and position the biceps tendon onto the humerus (Fig 6, Video 1). The sutures are tied sequentially to secure the tendon to bone (Video 1). The remaining LHB length and suture are excised, and the wound is copiously irrigated (Fig 6, Video 1). The wound is then closed in a standard staged subcutaneous and subcuticular fashion using Monocryl suture (Ethicon, Somerville, NJ) and Dermabond (Ethicon) (Video 1).



**Fig 6.** Intraoperative image of the left shoulder with the patient in the beach-chair position and the arm abducted 20° to 30°. Army-Navy retractors are placed anteriorly and distally for exposure; a Chandler retractor is placed medially adjacent to the humerus under minimal tension; and a pointed Hohmann retractor is placed over the top, underneath the deltoid and pectoralis major junction. The unpassed suture ends are then used as a post to secure the biceps tendon onto the humerus, and the sutures are tied over the tendon, securing it in place. The remaining biceps is trimmed.

### Postoperative Management

After the procedure, an ice pack is placed over the shoulder and an upper-extremity immobilizer is fitted to patients. Patients are instructed to wear the upper-extremity immobilizer for the first 2 weeks after surgery at all times except when performing instructed exercises or attending to personal hygiene. They are also advised to ice their shoulders for 20 minutes every 2 hours until their first postoperative visit (8-10 days). After their first visit, patients may begin hand and wrist range of motion and shoulder pendulum exercises no more than 2 or 3 times a day. They may not perform any more than active-assisted elbow flexion or supination exercises for 6 weeks after surgery.

Organized physical therapy begins 2 weeks after surgery. For the first 4 weeks after surgery, patients are

instructed to only engage in passive range-of-motion exercises with their upper extremity. After this period, they begin isometric exercises of the deltoid and rotator cuff as tolerated. All exercises involving the biceps are avoided until at least 6 weeks after surgery, when isometric exercises are slowly introduced. By 8 weeks, eccentric resisted exercises of the bicep are initiated as tolerated. At 12 to 16 weeks postoperatively, patients are allowed to return to all previous activities.

### Discussion

This article provides a simple and efficient technique for a mini-open subpectoral biceps tenodesis using an all-suture anchor with preloaded needles and suture tape. This technique is preferred because it is simple, increases operating room efficiency, and is reproducible. Biceps tenodesis is also associated with less muscle cramping, loss of supination strength, and cosmetic deformity. The use of an all-suture anchor allows the drilling of a much smaller hole in the humerus, which is associated with a decreased risk of postoperative fractures. In a study comparing methods of pectoralis major tendon repair, retears were only observed along the tendon-suture interface, highlighting the importance of suture construction as a limiting factor in postoperative outcomes.<sup>11</sup>

Although tenotomy and tenodesis are both viable options for treating pathologies relating to the LHB tendon, the senior author (B.J.C.) prefers a mini-open subpectoral biceps tenodesis. Tenodesis is especially beneficial for higher-activity patients who may be impaired by cramping and loss of elbow supination strength, as well as patients who are opposed to a Popeye deformity.<sup>10-13</sup> Although the rehabilitation period for biceps tenodesis is longer to ensure maintained fixation of the biceps, it helps maintain the length-tension relation of the LHB tendon. In addition, the literature indicates that the subpectoral approach prevents over-tensioning of the biceps,

**Table 1.** Pearls and Pitfalls

Steps	Pearls	Pitfalls
Patient positioning	The beach-chair position should be used with the head reclined 20°-30° and the arm slightly supinated and abducted.	
Incision	A 3-cm longitudinal incision should be made just beneath the inferior border of the pectoralis major and just medial to the anterior-medial border of the deltoid, lateral to the axillary crease.	Too medial of an incision presents potential harm to the neurovascular structures.
Exposure	A Chandler retractor should be placed on the medial aspect of the humerus to protect the neurovascular structures. One should ensure that the retractor is directly on bone and stays vertical without medial angulation.	Too medial of an exposure presents potential harm to the neurovascular structures.
Tenodesis site preparation	Fish scaling of the surface should be performed using a drill guide or osteotome and mallet. This process stimulates bony bleeding, which augments healing and prevents the tendon from migrating once attached.	
Drilling	A 1.9-mm drill hole reduces the risk of postoperative fracture.	Too large a drill hole increases the risk of postoperative fracture.

**Table 2.** Advantages and Disadvantages

Advantages	Disadvantages
Muscle cramping and loss of supination are reduced.	Tenodesis increases the operating time compared with tenotomy.
No cosmetic deformity (Popeye sign) occurs.	Postoperative fracture is a known complication of biceps tenodesis. <sup>16-18</sup>
The subpectoral approach prevents over-tensioning and decreases maximal load to failure. <sup>12</sup>	Tenodesis increases the rehabilitation time compared with tenotomy.
A slotted guide can be used to fish scale the desired fixation surface and allows for the use of swaged-on needles.	
The 1.3-mm suture tape with swaged-on needles prevents slippage while increasing efficiency and decreasing the operating time.	
A 1.9-mm drill hole minimizes the risk of postoperative complications including fracture.	
Unicortical drilling with an all-suture anchor protects the axial nerve in comparison to bicortical drilling and reduces the chance of fracture.	

decreases the maximum load to failure, and is associated with the lowest rate of persistent postoperative pain and stiffness.<sup>12</sup>

Interference screws, cortical buttons, and suture anchors have all been shown to provide successful functional outcomes with no significant difference between arthroscopic and open fixation techniques.<sup>8,13-15</sup> Although some cadaveric studies have shown that interference screws provide superior fixation strength to knotless sutures, more recent literature has suggested that all-suture anchors are just as strong as interference screws for both subpectoral and suprapectoral approaches yet reduce the incidence of postoperative fracture as a known complication after biceps tenodesis.<sup>16-18</sup>

Although subpectoral biceps tenodesis with an all-suture anchor is a safe and well-tolerated procedure, there are some risks associated with the procedure that can be minimized with proper technique. As with any mini-open biceps tenodesis, there is a risk of injuring the musculocutaneous nerve during medial retraction of the surgical site. This can be avoided by applying gentle retraction throughout the procedure. Another risk, as mentioned earlier, is postoperative fracture, but this risk is reduced compared with other common techniques. All-suture anchors require smaller-bore drill holes, minimizing bone loss and associated complications. Cases have been reported involving proximal

humeral fractures during biceps tenodesis with interference screw fixation, which can be avoided through reducing the drill size in the humerus.<sup>19,20</sup> In addition, a recent study has shown that biceps tenodesis with interference screw fixation had significantly reduced maximum torque and rotation failure, putting overhead throwers at risk.<sup>21</sup> Furthermore, unicortical drilling with the all-suture anchor protects the axial nerve, which is at greater risk when using bicortical drilling.<sup>22</sup> Finally, suture tape reduces the risk of slippage and other complications sometimes seen with smaller-bore sutures.<sup>23,24</sup> Table 1 presents pearls and pitfalls, and Table 2 lists advantages and disadvantages.

In conclusion, this article presents a technique for a mini-open subpectoral biceps tenodesis using an onlay technique with an all-suture anchor preloaded with needles and suture tape. This technique allows proper tendon fixation while minimizing potential complications.

## References

1. Creech MJ, Yeung M, Denkers M, Simunovic N, Athwal GS, Ayeni OR. Surgical indications for long head biceps tenodesis: a systematic review. *Knee Surg Sports Traumatol Arthrosc* 2016;24:2156-2166.
2. Christian DRM, Cvetanovich G, Beer A, Cole BJ. Mini-open subpectoral biceps tenodesis with an all-suture anchor. *Oper Tech Sports Med* 2018;26:105-109.
3. Meeks BD, Meeks NM, Froehle AW, Wareing E, Bonner KF. Patient satisfaction after biceps tenotomy. *Orthop J Sports Med* 2017;5: 2325967117707737.
4. Hassan S, Patel V. Biceps tenodesis versus biceps tenotomy for biceps tendinitis without rotator cuff tears. *J Clin Orthop Trauma* 2019;10:248-256.
5. Shang X, Chen J, Chen S. A meta-analysis comparing tenotomy and tenodesis for treating rotator cuff tears combined with long head of the biceps tendon lesions. *PLoS One* 2017;12: e0185788.
6. Abdul-Rassoul H, Defazio M, Curry EJ, Galvin JW, Li X. Return to sport after the surgical treatment of superior labrum anterior to posterior tears: A systematic review. *Orthop J Sports Med* 2019;7: 2325967119841892.
7. Griffin JW, Cvetanovich GL, Kim J, et al. Biceps tenodesis is a viable option for management of proximal biceps injuries in patients less than 25 years of age. *Arthroscopy* 2019;35:1036-1041.
8. Gombera MM, Kahlenberg CA, Nair R, Saltzman MD, Terry MA. All-arthroscopic suprapectoral versus open subpectoral tenodesis of the long head of the biceps brachii. *Am J Sports Med* 2015;43:1077-1083.
9. Walch G, Edwards TB, Boulahia A, Nové-Josserand L, Neyton L, Szabo I. Arthroscopic tenotomy of the long head of the biceps in the treatment of rotator cuff tears: Clinical and radiographic results of 307 cases. *J Shoulder Elbow Surg* 2005;14:238-246.
10. Werner BC, Pehlivan HC, Hart JM, et al. Increased incidence of postoperative stiffness after arthroscopic compared with open biceps tenodesis. *Arthroscopy* 2014;30:1075-1084.

11. Sherman SL, Lin EC, Verma NN, et al. Biomechanical analysis of the pectoralis major tendon and comparison of techniques for tendo-osseous repair. *Am J Sports Med* 2012;40:1887-1894.
12. Werner BC, Lyons ML, Evans CL, et al. Arthroscopic suprapectoral and open subpectoral biceps tenodesis: A comparison of restoration of length-tension and mechanical strength between techniques. *Arthroscopy* 2015;31:620-627.
13. Duchman KR, DeMik DE, Uribe B, Wolf BR, Bollier M. Open versus arthroscopic biceps tenodesis: A comparison of functional outcomes. *Iowa Orthop J* 2016;36:79-87.
14. Green JM, Getelman MH, Snyder SJ, Burns JP. All-arthroscopic suprapectoral versus open subpectoral tenodesis of the long head of the biceps brachii without the use of interference screws. *Arthroscopy* 2017;33:19-25.
15. Park JS, Kim SH, Jung HJ, Lee YH, Oh JH. A prospective randomized study comparing the interference screw and suture anchor techniques for biceps tenodesis. *Am J Sports Med* 2016;45:440-448.
16. Baleani M, Francesconi D, Zani L, Giannini S, Snyder SJ. Suprapectoral biceps tenodesis: A biomechanical comparison of a new "soft anchor" tenodesis technique versus interference screw biceps tendon fixation. *Clin Biomech* 2015;30:188-194.
17. Chiang FL, Hong C-K, Chang C-H, Lin C-L, Jou IM, Su W-R. Biomechanical comparison of all-suture anchor fixation and interference screw technique for subpectoral biceps tenodesis. *Arthroscopy* 2016;32:1247-1252.
18. Patzer T, Santo G, Olender GD, Wellmann M, Hurschler C, Schofer MD. Suprapectoral or subpectoral position for biceps tenodesis: Biomechanical comparison of four different techniques in both positions. *J Shoulder Elbow Surg* 2012;21:116-125.
19. Reiff SN, Nho SJ, Romeo AA. Proximal humerus fracture after keyhole biceps tenodesis. *Am J Orthop (Belle Mead NJ)* 2010;39:E61-E63.
20. Sears BW, Spencer EE, Getz CL. Humeral fracture following subpectoral biceps tenodesis in 2 active, healthy patients. *J Shoulder Elbow Surg* 2011;20:e7-e11.
21. Beason DP, Shah JP, Duckett JW, Jost PW, Fleisig GS, Cain EL. Torsional fracture of the humerus after subpectoral biceps tenodesis with an interference screw: A biomechanical cadaveric study. *Clin Biomech* 2015;30:915-920.
22. Lancaster S, Smith G, Ogunleye O, Packham I. Proximity of the axillary nerve during bicortical drilling for biceps tenodesis. *Knee Surg Sports Traumatol Arthrosc* 2016;24:1925-1930.
23. Edgar CM, Singh H, Obopilwe E, et al. Pectoralis major repair: A biomechanical analysis of modern repair configurations versus traditional repair configuration. *Am J Sports Med* 2017;45:2858-2863.
24. Gregory JM, Klosterman EL, Thomas JM, et al. Suture technique influences the biomechanical integrity of pectoralis major repairs. *Orthopedics* 2015;38:e746-e752.