

Accuracy and Reliability of Intraoral Radiographs in Determining the Cleanliness of Root Canals after Endodontic Retreatment

 Lars SCHROPP,  Lise-Lotte KIRKEVANG,

ABSTRACT

Objective: This study aimed to evaluate the accuracy and reliability of periapical radiographs obtained with two different projections in determining the cleanliness of root canals in endodontic retreatment using the sectioned roots as a gold standard.

Methods: The amount of residual root-filling material after endodontic retreatment procedures in 42 roots was assessed in radiographs and in microscopic photographs of the sectioned roots by five observers. Furthermore, the cleanliness of 80 roots was assessed based on orthogonal and mesio-angulated radiographs. Four parameters were used for the evaluation of cleanliness. Wilcoxon signed-rank tests and percentage agreement calculations were used for comparisons between the radiographs and the gold-standard observations and between the orthogonal and mesio-angulated radiographs, respectively. Intra- and inter-observer reproducibility was tested using Kappa statistics and intra-class correlation tests. The statistically significance level was 0.05.

Results: In general, significantly more residual root-filling material was detected in the photographs of the split roots (gold standard) than in the radiographs. Comparing orthogonal and eccentric projections, only slight differences in cleanliness were found. The intraobserver reproducibility was fair to almost perfect for radiographs and microscopic photographs. For all parameters, the reproducibility was better for the radiographs than for the microscopic photographs. The interobserver variability ranged from fair to almost perfect agreement for the radiographs.

Conclusion: The accuracy of periapical radiographs was poor in determining the cleanliness of root canals after endodontic retreatment, whereas the reliability of the radiographs was fair. A mesio-angulated projection did not contribute essentially to the detection of residual root-filling materials.

Keywords: Eccentric radiographs, endodontics, gold standard, orthogonal radiographs, reproducibility

Please cite this article as: Schropp L, Kirkevang LL. Accuracy and reliability of intraoral radiographs in determining the cleanliness of root canals after endodontic retreatment. *Eur Endod J* (2017) 2:20.

From the Department of Dentistry and Oral Health (L.S. ✉ lars.schropp@dent.au.dk), Aarhus University, Aarhus, Denmark; Department of Endodontics (L.L.K.), School of Dentistry, University of Oslo, Oslo, Norway.

Received 22 February 2017, revision requested 5 April 2017, last revision received 9 May 2017, accepted 30 May 2017.

Published online: 11 June 2020
DOI 10.14744/eej.2017.17014

This work is licensed under a Creative Commons Attribution-NonCommercial 4.0 International License.



HIGHLIGHTS

- The accuracy of periapical radiographs was poor in determining the cleanliness of root canals after endodontic retreatment.
- Eccentric projections are not recommended to be routinely performed when controlling the cleaning of single-canal teeth during endodontic retreatment.

INTRODUCTION

The success of endodontic retreatment demands a sufficient removal of existing root-filling materials before a subsequent obturation of the root canals (1-3). To determine the quality of an endodontic retreatment of a root canal, it is crucial that the tool for the assessment of removal of the filling materials is accurate and reliable, as well as workable in the clinic. For

many years, radiography has been the method of choice for evaluating the length of the root filling, the quality of the seal, overfilling, as well as the quality of cleaning in relation to retreatment of root canals. More recently, dental-operating microscopes have been introduced as a tool in endodontic therapy with the potential to improve the inspection of root canal anatomy and potential remnants of root-filling materials (4-6). However, microscopy is associated with higher costs and may be expected to have some limitations as regards inspection of the full root canal length in case of curved canals.

Previous studies have investigated advanced methods for the evaluation of removal of root-filling material, such as stereomicroscopy, scanning electron microscopy, micro-computed tomography

phy (micro-CT) and computed tomography (7-10). Micro-CT is a novel non-invasive technique, which may have the potential to reveal the truth about the effectiveness of root-filling removal of different root canal retreatment procedures (11, 12). Furthermore, studies have evaluated the influence of radiographic projection geometry on the estimation of the quality of root canal treatment (13-17). However, the latter *ex vivo* studies have mainly exposed the extracted teeth perpendicular to the mesial or distal surface, which would not be possible with the tooth *in situ*. To the best of our knowledge, no previous studies have compared the efficiency of different, clinically relevant radiographic projections for the assessment of cleanliness of single-canal teeth after retreatment.

The aim of the study was to evaluate the accuracy and reliability of periapical radiographs obtained with two different projections in determining the cleanliness of root canals in endodontic retreatment using the sectioned roots as a gold standard.

MATERIALS AND METHODS

The study material comprised extracted single-canal incisors, canines and premolars. Eighty teeth were collected from general dentists over a period of 3 months. The availability of teeth dictated the sample size of the study, and the 80 teeth were considered to be sufficient to determine the accuracy of the radiographic method and detect a clinically relevant difference between two radiographic projections. The research was performed according to the World Medical Association Declaration of Helsinki. Ethics committee approval for using extracted human teeth collected from dental clinics was not required according to the national rules and was thus not obtained for this study. The majority of the roots were straight; approximately 25% of the roots had a slight curvature mesio-distally of maximum 10 degrees in the apical part and 40% in the bucco-lingual plane. Fewer than 5% curved more than 10 degrees in one or both planes.

The teeth had previously been root-filled and later reinstrumented for removal of the filling materials in conjunction with two *in vitro* studies performed by dental students. The root canals were filled using lateral condensation technique with AH+ and gutta-percha (Dentsply Maillefer, Ballaigues, Switzerland). The retreatments were performed either by hand instrumentation using Hedtröm files (Kerr Endodontics, Orange, USA) or by rotary instrumentation using ProTaper D files (Dentsply Maillefer). Cleaning was assessed complete when the last file reached the working length, there was no filling material covering the instrument, and the canal walls were smooth and free of visible debris.

Radiographic examination and evaluation

Each tooth was incorporated into a base of foam and attached with adhesive wax on top of a dental X-ray film holder (Take-All™; Denbur, Inc., Oak Brook, IL) and placed just in front of a photo-stimulable phosphor plate with a size of 22 mm×31 mm (Digora; Soredex, Tuusula, Finland) (Figure 1). The examination was standardised in order to obtain the same distance




Figure 1. Setup for periapical radiography

TABLE 1. Score sheet for evaluation of radiographs and photographs of the roots (both halves)

1. How does the worst part of the canal look?
0=Totally clean
1=Thin layer on one side
2=Thin layer on two sides but less than half of the canal width filled
3=More than half of the width filled but not totally
4=Canal totally filled
2. What percentage of the total root length amounts the worst part?
0-100%
3. Where is the worst part located in the root?
1=Coronally
2=In the middle
3=Apically
4. What percentage of the total root length is seen with residual root-filling material, irrespective of the degree?
0-100%

(8 cm) and angulation between the radiographic tube and the receptor. The X-ray beam was aimed perpendicular to the long axis of the tooth and receptor (paralleling technique) and the first radiograph exposed with an orthogonal (bucco-oral) projection, whereas the second radiograph was obtained with a mesio-angulated projection of 10 degrees. A paper with lines indicating the correct distance and the two angulations was used for the purpose of standardisation. The exposure settings were 60 kV, 15 mA and 0.2 s for all images.

After a preceding calibration, five observers (fifth-year dental students) assessed individually the extent of remaining root-filling materials. The radiographs were blinded as to projection angulation and evaluated on a Lenovo Thinkvision 21-inch monitor (Lenovo, Morrisville, NC, USA). Four parameters were scored for each radiograph (Table 1). In case of a not totally clean root canal (score 0), the part with most residual root-filling material (worst) was scored (scores 1-4), and how large a proportion of the total root length it affected (0%-100%), and where it was located (scores 1-3). Finally, it was assessed how large a proportion of the total root length had visible residual material (0%-100%), irrespective of the degree.

Root sectioning and evaluation

After the radiographic evaluation, the roots were sectioned longitudinally in two halves for the purpose of reassessing the efficacy of the root canal cleaning. All teeth were cut longitudinally in the mesio-distal plane with a Leitz 1600 Microtome (Leitz, Wetzlar, Germany) and a 300- μ m sawblade thickness attempting to section the root in the middle part. Thirty-eight teeth were withdrawn from the study, as the whole length of

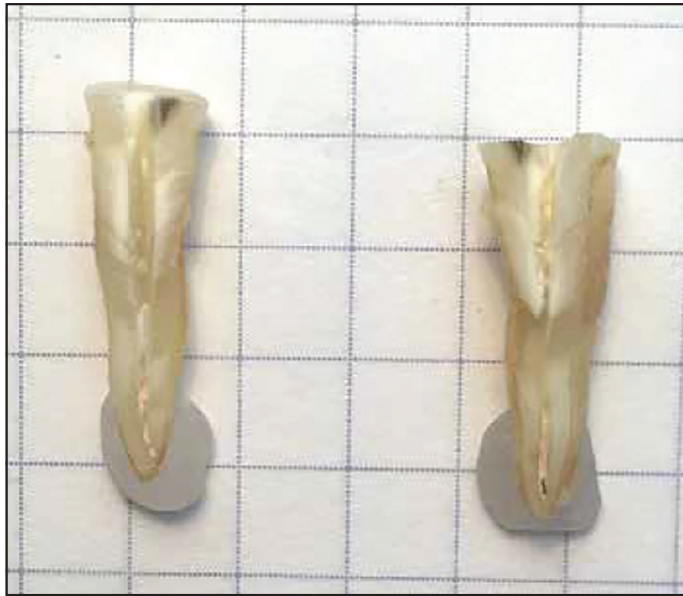

Figure 2. Setup for evaluation of root segments in microscopic photographs

TABLE 2. Frequencies of the scores for parameter 1, How does the worst part of the canal look?, comparing the radiographs and the microscopic photographs (gold standard)

Scores	Radiographs					Total
	0	1	2	3	4	
Gold standard	0	0	0	0	0	0
	1	0	0	1	0	1
	2	1	0	0	0	1
	3	4	2	0	4	10
	4	3	1	2	9	15
Total	8	3	3	13	15	42

Blue=same score, green=higher score for the gold standard, red=lower score for the gold standard

the root canal was not visible after the division mainly due to curvature in the bucco-oral plane. The buccal and oral parts of the remaining roots were then placed on a checkered paper and photographed with a Zeiss S100 OPMI pico microscope (Carl Zeiss Meditec AG, Jena, Germany) (Figure 2). After a calibration session, the five observers assessed individually each segment of the split roots on the photographs using the same four parameters as for the radiographs (Table 1).

The evaluations based on the radiographs as well as the photographs were repeated after at least one week.

Statistical analysis

The root segment with the highest score (poorest removal of filling materials) was applied for the statistical analyses in each case. For parameters 1 and 3, the mode (most frequent score) was found for the 10 (5 observers×2 registrations each) registrations and used for the analyses, and likewise, the average score for the 10 registrations was used for parameters 2 and 4.

The scores based on the orthogonal radiographs and the photographs of the segmented roots (42 cases) were compared

and differences for parameters 2 and 4, respectively were tested using Wilcoxon signed-rank test, whereas the percentage agreement between the scores was calculated for parameter 1.

The scores for the orthogonal and mesio-angulated radiographs (80 cases) were compared for all four parameters using Wilcoxon signed-rank test for parameters 2 and 4, and the percentage agreement between the scores was calculated for parameters 1 and 3.

Intra- and interobserver reproducibility was tested using Kappa statistics for parameters 1 and 3 and intra-class correlation tests for parameters 2 and 4.

Commercially available software Statistical Package for Social Sciences version 21 (IBM Corp.; Armonk, NY, USA) was used for data evaluation, and the level of statistical significance was set to 0.05.

RESULTS

When comparing the scores for question one: How does the worst part of the canal look? based on the evaluation of the radiographs and photographs of the roots (gold standard), agreement was found in 45.2% of the cases (Tables 1, 2). In 52.4% of the cases, the score for the gold standard was higher (more root-filling material left in the canal) than that for the radiograph, whereas the score was higher for the radiograph in 2.4% of the cases. For question two: *What percentage of the total root length amounts the worst part?*, a statistically significant difference between the radiographs and the gold standard was found ($P=0.0001$); the average score was $15.0\% \pm 11.4\%$ for the radiographs and $25.2\% \pm 12.6\%$ for the gold standard. For question four: *What percentage of the total root length is seen with residual root-filling material, irrespective of the degree?*, the average score was $36.1\% \pm 29.9\%$ for the radiographs and $51.0\% \pm 20.1\%$ for the gold standard ($P=0.0001$).

A comparison between the orthogonal and mesio-angulated radiographs for question one showed agreement in 78% of the cases; the score was higher for the orthogonal radiographs in 10% of the cases, whereas a higher score was seen for the eccentric radiographs in 12% of the cases. For question two, no statistically significant difference ($P=0.17$) was found (orthogonal $14.4\% \pm 10.6\%$; eccentric $15.4\% \pm 10.8\%$), whereas a significant difference ($P=0.005$) in average percentage for question four between orthogonal and eccentric radiographs was revealed ($34.9\% \pm 27.2\%$ and $36.2\% \pm 28.1\%$, respectively). For question three: *Where is the worst part located in the root?*, the scores were the same for the orthogonal and eccentric radiographs in 81% of the cases.

The interobserver variability for the first registration of all radiographs and photographs is displayed in Table 3. The intraobserver reproducibility when comparing the first and second registration of all radiographs and photographs was also tested (Table 4).

DISCUSSION

In the present study, the cleanliness of the root canal after an attempt to remove all root-filling material was assessed on

TABLE 3. Interobserver variability for the first evaluation of the two halves of the root (microscopic photographs) and the orthogonal and eccentric radiographs. Kappa and ICC coefficients.

Questions one and three for the two halves of the root (Kappa)			
Q1 Root 1	Q1 Root 2	Q3 Root 1	Q3 Root 2
0.31-0.65	0.19-0.61	0.26-0.53	0.18-0.62
/P<0.001	/P<0.051	/P<0.001	/P<0.024
Questions two and four for the two halves of the root (ICC)			
Q2 Root1	Q2 Root 2	Q4 Root 1	Q4 Root 2
0.28-0.83	0.43-0.83	0.51-0.89	0.88-0.96
/P<0.151	/P<0.039	/P<0.014	/P<0.001
Questions one and three for the orthogonal and eccentric radiographs (Kappa)			
Q1 Orthogonal	Q1 Eccentric	Q3 Orthogonal	Q3 Eccentric
0.39-0.61	0.36-0.55	0.51-0.69	0.42-0.63
/P<0.001	/P<0.001	/P<0.001	/P<0.001
Questions two and four for the orthogonal and eccentric radiographs (ICC)			
Q2 Orthogonal	Q2 Eccentric	Q4 Orthogonal	Q4 Eccentric
0.65-0.85	0.51-0.73	0.93-0.97	0.91-0.97
/P<0.001	/P<0.002	/P<0.001	/P<0.001

TABLE 4. Intraobserver reproducibility for the evaluation of the two halves of the root (microscopic photographs) and the orthogonal and eccentric radiographs by five observers. Kappa and ICC coefficients.

	Q1 (Kappa)	Q2 (ICC)	Q3 (Kappa)	Q4 (ICC)
Microscopic photographs	0.39-0.93 P<0.0001	0.61-0.98 P<0.001	0.52-0.85 P<0.0001	0.67-0.96 P<0.0001
Orthogonal	0.50-0.76 P<0.0001	0.75-0.92 P<0.0001	0.61-0.86 P<0.0001	0.94-0.99 P<0.0001
Eccentric	0.61-0.85 P<0.0001	0.84-0.98 P<0.0001	0.63-0.94 P<0.0001	0.96-1.0 P<0.0001

radiographs and by inspection of the split root. Microscopic photographs of the two halves of each root were used as a gold standard (the 'truth'). The results demonstrated that the amount of residual root-filling material estimated on the basis of the gold standard differed significantly from what was seen on the radiographs. For the three questions, the observers scored lower - in other words detected less residual material - when evaluating the orthogonal radiographs compared with the gold standard. This is in accordance with previous studies. Duarte et al. evaluated the effectiveness of rotary or manual techniques for removing root fillings and found that microscopic analysis detected a significantly higher percentage of residual filling material than radiographs (8). Another *ex vivo* study concluded that evaluation of split roots using a photomicrographic method by epiluminescence was more effective than the radiographic method to evaluate filling debris after endodontic retreatment (18). In a study comparing a dental-operating microscope and radiographs for detect-

ability of residual Epiphany and gutta-percha after root canal retreatment, it was found that using radiographic examination gave an over-optimistic impression of cleanliness compared with the scores determined by the visualisation through the microscope (15).

It must be recognised that sectioning of roots may be associated with displacement of root-filling remnants and thus the assumption that direct inspection of the roots gives the 'true picture' is indeed an approximation. In this study, only the root half with the highest score (less cleanliness) was applied for the analyses and that may similarly underestimate the amount of left filling material. To overcome these drawbacks of sectioning techniques, which in turn should be considered as limitations of the present study, the use of micro-CT in experimental endodontics is appealing. A recent systematic review found several studies, which have investigated the effectiveness of different procedures in removing root canal filling materials using micro-CT imaging (11). This tool may in this context be more reliable than the sectioning technique, but currently, accessibility to micro-CT in research is somewhat restricted due to high acquisition costs.

Radiographs of the roots were obtained with two different projections in this study. The results showed only slight differences between orthogonal and eccentric (10-degree deviation) projections. The scores when evaluating the amount of filling material in the 'worst' part of the root (question 1) and in which third of the root the 'worst' part was located (question 3) agreed between the orthogonal and eccentric radiographs in approximately 80% of the cases. No statistically significant difference was found when assessing how much of the full root length the 'worst' part amounted (question two; orthogonal 14% vs. eccentric 15%), whereas a significant difference between orthogonal and eccentric radiographs was revealed when assessing the percentage of the full root length filled with material (question four; 35% and 36%, respectively). However, this difference of approximately one percent may not be clinically relevant. These findings were partly in contradiction to those from a previous *in vitro* study that showed significantly more anterior teeth classified as having an inadequate root canal seal in the mesio-distal projection than in the bucco-oral projection (14). For premolar and molar roots, no significant differences were found between the two projections. However, it should be noted that the mesio-distal radiographs herein were exposed with a 90-degree angulation relative to the bucco-oral projection, which may not be considered clinically relevant (in contrast to the smaller angulation chosen in the present study). On the basis of our study, it seems not indicated to supplement the periapical radiograph with one or more eccentric projections deviating 10 degrees from the orthogonal plane - and as a consequence inflict increased radiation doses to the patient and additional costs - when the clinician wish to control the cleaning of a root canal in retreatment of single-canal teeth.

It should be emphasised that the present *ex vivo* results may not be extrapolated to the clinic. Intraoral radiographs in patients would be affected by superimposed surrounding hard and soft tissues. This was indicated by Eckerbom & Magnus-

son who evaluated the reliability of intraoral radiographs in estimating the technical quality of endodontic treatment (14). They found statistically significant differences between recordings of the root canal seal in clinical radiographs and *in vitro* radiographs taken in the bucco-oral projection. The length of the root filling was interpreted to be the same in bucco-oral and mesio-distal (*in vitro*) projections and clinical radiographs (bucco-oral projection); however, both inadequate seal and visible lumen apical to the root filling were recorded less frequently in the clinical radiographs than in either of the two *in vitro* projections.

The interobserver variability ranged from slight to substantial agreement in the assessment of the microscopic photographs and from fair to substantial agreement when assessing the radiographs for questions one and three. For questions two and four expressing the percentage fill of the root canal, a slight to almost perfect agreement was seen for the microscopic photographs and a moderate to almost perfect agreement for the radiographs.

The intraobserver reproducibility was fair to almost perfect. For all questions, the reproducibility was better for the radiographs than for the microscopic photographs.

CONCLUSION

Within the limitations of this *ex vivo* study, it can be concluded that the accuracy of periapical radiographs was poor in determining the cleanliness of root canals after endodontic retreatment, whereas the reliability of the radiographs was fair. Eccentric (mesio-angulated) projections did not contribute essentially to the detection of filling material remnants and are not recommended to be routinely performed when controlling the cleaning of single-canal teeth during endodontic retreatment.

Disclosures

Acknowledgements: The authors would like to thank Anne Juul Olsen, Maibritt Halkalar, Laura Sloth, Marthe Pettersen, and Diana Absalonsen for assessing the radiographs and microscopic photographs.

Conflict of Interest: No conflict of interest was declared by the authors.

Ethical Approval: Authors declared that the research was conducted according to the principles of the World Medical Association Declaration of Helsinki "Ethical Principles for Medical Research Involving Human Subjects", (amended in October 2013).

Informed Consent: N/A.

Peer-review: Externally peer-reviewed.

Financial Disclosure: The authors declared that this study has received no financial support.

Authorship Contributions: Concept – L.L.K., L.S.; Design – L.S., L.L.K.; Supervision – L.S., L.L.K.; Funding – L.L.K., L.S.; Materials – L.L.K.; Data collection &/or processing – L.L.K., L.S.; Analysis and/or interpretation – L.S., L.L.K.; Literature search – L.S.; Writing – L.S., L.L.K.; Critical Review – L.L.K., L.S.

REFERENCES

1. Wilcox LR, Krell KV, Madison S, Rittman B. Endodontic retreatment: evaluation of gutta-percha and sealer removal and canal instrumentation. *J Endod* 1987; 13(9):453-7.
2. Friedman S. Expected outcomes in the prevention and treatment of apical periodontitis. In: Ørstavik D, Pitt Ford T, editors. *Essential Endodontology*. 2nd ed. Oxford: Blackwell Munksgaard; 2008. p. 408-69.
3. Colaco AS, Pai VA. Comparative evaluation of the efficiency of manual and rotary gutta-percha removal techniques. *J Endod* 2015; 41(11):1871-4.
4. Del Fabbro M, Taschieri S. Endodontic therapy using magnification devices: a systematic review. *J Dent* 2010; 38(4):269-75.
5. Kim S, Baek S. The microscope and endodontics. *Dent Clin North Am* 2004; 48(1):11-8.
6. Pecora G, Andreana S. Use of dental operating microscope in endodontic surgery. *Oral Surg Oral Med Oral Pathol* 1993; 75(6):751-8.
7. Kasam S, Mariswamy AB. Efficacy of different methods for removing root canal filling material in retreatment - an *in-vitro* study. *Journal of clinical and diagnostic research: JCDR* 2016; 10(6):Zc06-10.
8. Duarte MA, So MV, Cimadon VB, Zucatto C, Vier-Pelisser FV, Kuqa MC. Effectiveness of rotary or manual techniques for removing a 6-year-old filling material. *Braz Dent J* 2010; 21(2):148-52.
9. Zanettini PR, Barletta FB, de Mello Rahde N. *In vitro* comparison of different reciprocating systems used during endodontic retreatment. *Aust Endod J* 2008; 34(3):80-5.
10. Bernardes RA, Duarte MA, Vivan RR, Alcalde MP, Vasconcelos BC, Bramante CM. Comparison of three retreatment techniques with ultrasonic activation in flattened canals using micro-computed tomography and scanning electron microscopy. *Int Endod J* 2015.
11. Rossi-Fedele G, Ahmed HM. Assessment of root canal filling removal effectiveness using micro-computed tomography: a systematic review. *J Endod* 2017; 43(4):520-6.
12. Martins MP, Duarte MA, Cavenago BC, Kato AS, de Silveira Bueno CE. Effectiveness of the ProTaper next and reciproc systems in removing root canal filling material with sonic or ultrasonic irrigation: a micro-computed tomographic study. *J Endod* 2017; 43(3):467-71.
13. Kersten HW, Wesselink PR, Thoden van Velzen SK. The diagnostic reliability of the buccal radiograph after root canal filling. *Int Endod J* 1987; 20(1):20-4.
14. Eckerbom M, Magnusson T. Evaluation of technical quality of endodontic treatment-reliability of intraoral radiographs. *Endod Dent Traumatol* 1997; 13(6):259-64.
15. Schirrmeister JF, Hermanns P, Meyer KM, Goetz F, Hellwig E. Detectability of residual Epiphany and gutta-percha after root canal retreatment using a dental operating microscope and radiographs-an *ex vivo* study. *Int Endod J* 2006; 39(7):558-65.
16. Gergi R, Sabbagh C. Effectiveness of two nickel-titanium rotary instruments and a hand file for removing gutta-percha in severely curved root canals during retreatment: an *ex vivo* study. *Int Endod J* 2007; 40(7):532-7.
17. Hörsted-Bindslev P, Andersen MA, Jensen MF, Nilsson JH, Wenzel A. Quality of molar root canal fillings performed with the lateral compaction and the single-cone technique. *J Endod* 2007; 33(4):468-71.
18. de Carvalho Maciel AC, Zaccaro Scelza MF. Efficacy of automated versus hand instrumentation during root canal retreatment: an *ex vivo* study. *Int Endod J* 2006; 39(10):779-84.