

HOSTED BY




ELSEVIER

Available online at [www.sciencedirect.com](http://www.sciencedirect.com)

ScienceDirect

journal homepage: <http://www.elsevier.com/locate/ijpam>



Instructive Case

# Esophageal perforation: An uncommon initial manifestation of eosinophilic esophagitis



Thirumazhisai S. Gunasekaran <sup>a,\*</sup>, James Berman <sup>b</sup>,  
Jennifer E. Lim-Dunham <sup>c</sup>

<sup>a</sup> Advocate Children's Hospital, Loyola Medical Center, Park Ridge, IL 60068, USA

<sup>b</sup> University of Illinois, Advocate Children's Hospital, Park Ridge, IL 60068, USA

<sup>c</sup> Loyola Medical Center, Maywood, IL 60153, USA

Received 27 January 2016; received in revised form 12 March 2016; accepted 24 March 2016

Available online 1 May 2016

## KEYWORDS

Eosinophilic  
esophagitis;  
Perforation;  
Endoscopy

**Abstract** EoE-Perforation: Eosinophilic esophagitis (EoE) is commonly observed in children and young adults. Common manifestations of EoE include dysphagia and food impaction in adolescents and adults, whereas children present with failure to thrive, regurgitation, or heartburn and abdominal pain. We describe two patients presenting with esophageal perforation and EoE. Diagnosing perforation promptly is critical to minimize and/or to avoid the multitude of complications resulting from esophageal perforation and to treat EoE because if left untreated, this condition may result in the recurrence of perforation, major morbidity, or rarely death.

Copyright © 2016, King Faisal Specialist Hospital & Research Centre (General Organization), Saudi Arabia. Production and hosting by Elsevier B.V. This is an open access article under the CC BY-NC-ND license (<http://creativecommons.org/licenses/by-nc-nd/4.0/>).

## 1. Introduction

Eosinophilic esophagitis (EoE), an immune-mediated disorder, is diagnosed by the combination of eosinophilic infiltration of the esophagus and esophageal dysfunction [1,2]. EoE is an increasingly recognized disease with a prevalence of 1–5 per 100,000 persons in the USA and Europe [2]. As a 'newer' disease, its natural history remains unclear; however, evidence has shown that EoE is not a premalignant condition and that the disease course

\* Corresponding author. 1775 Dempster Street, Park Ridge, IL 60068, USA. Tel.: +1 847 723 5962; fax: +1 847 723 9418.

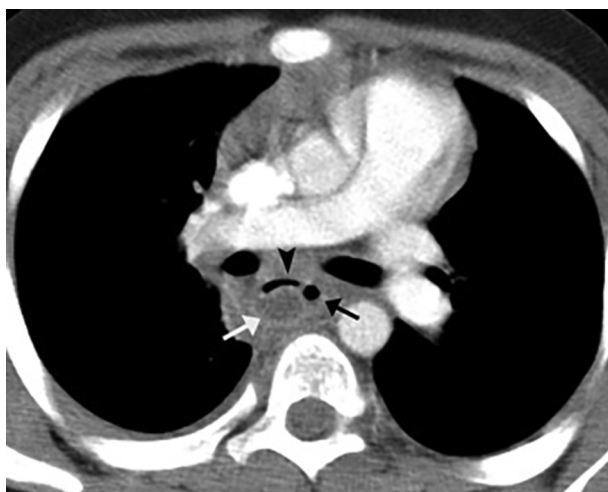E-mail address: [ts.gunasekaran@advocatehealth.com](mailto:ts.gunasekaran@advocatehealth.com) (T.S. Gunasekaran).

Peer review under responsibility of King Faisal Specialist Hospital & Research Centre (General Organization), Saudi Arabia.

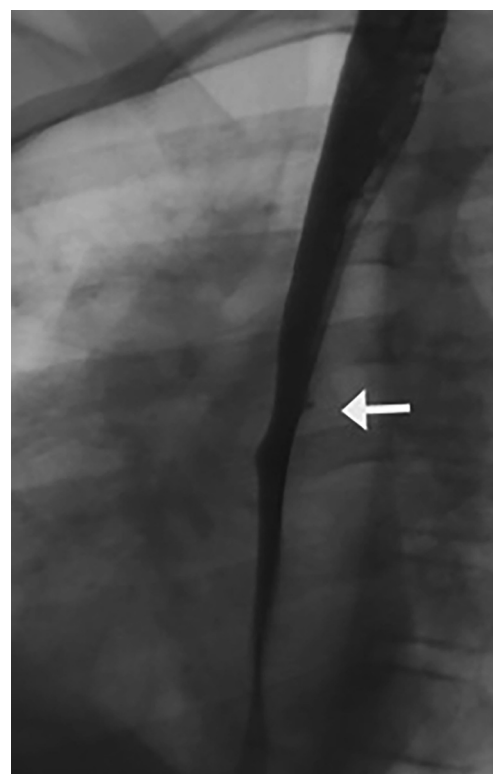
varies from a prolonged spontaneous remission with or without treatment to a waxing and waning course; it can also be progressive, leading to strictures [2]. EoE usually presents insidiously with feeding difficulty, abdominal pain, gastroesophageal reflux-like symptoms, and dysphagia or acutely with food impaction. A rare and dramatic initial manifestation of EoE is esophageal perforation. We describe two adolescent males with esophageal perforation associated with eosinophilic esophagitis.

## 2. Case 1

L.C. was a 10-year-old boy, who complained of chest pain and a fever of 103 F for the duration of two weeks in December 2010. He had no difficulty breathing, pain on inspiration, breathlessness, trauma, history of illicit drug, or alcohol use. Past medical history included mild intermittent asthma and intermittent dysphagia for solid food for approximately one year. He had no prior esophageal or gastric surgery. On physical examination, his weight, height, and vital signs were normal. His lungs were clear to auscultation bilaterally, and he had no abdominal tenderness or masses. No crepitations were found in the neck or chest. His WBC count was 11,800/ml, his hemoglobin level was 12.8 gm/dl, and his platelets were 392,000/ml. The absolute eosinophil count was 440/ml, and the chest X-ray was normal. A computed tomography (CT) of the chest showed esophageal perforation with extra fluid and gas in the mediastinum adjacent to the esophagus (Fig. 1). The thoracic portion of the esophageal wall was thickened. An esophagram confirmed a contained esophageal perforation (Fig. 2). He was initially treated with intravenous antibiotics, and no drugs were administered orally. After one week, his symptoms improved, and he was started on omeprazole at 40 mg/day. Two weeks later, the follow-up CT scan was normal. At two months later, upper



**Figure 1** CT scan of the chest shows evidence of esophageal perforation, including a mediastinal fluid collection (white arrow) and extraluminal gas (black arrow). The fluid collection causes anterior displacement and narrowing of the esophagus (black arrowhead).



**Figure 2** Esophagram performed with water soluble contrast material shows a small outpouching from posterior wall of esophagus indicating a contained esophageal perforation. Diffuse narrowing of a long segment of the mid esophagus is consistent with underlying eosinophilic esophagitis.

gastrointestinal endoscopy showed linear furrows, multiple white exudates throughout the esophagus, and a small diverticulum in the midesophagus (site of perforation). Biopsies noted 23 eosinophils/HPF in the distal esophagus and 26/HPF (normal-usually none) in the proximal esophagus, along with marked basal cell hyperplasia and eosinophilic microabscesses. Gastric antral and duodenal biopsies were normal. He was started on topical fluticasone 440 mcg, four times a day, for 8 weeks. He was non-adherent to the treatment regimen, and he missed his follow up appointment. He presented himself two years later with chest pain and fever as before and had similar findings on examination. An esophagram showed a contained perforation at the same site where an outpouching was previously observed. He had medical management as before, and his symptoms, including fever, improved within a week. His follow up esophagram was normal. Additionally, he had two follow up endoscopies, and the last one, three years after the initial presentation, showed mild furrows and a few white spots, with esophageal eosinophil count as 50–75/HPF in the distal esophagus and 25–45/HPF in the midesophagus. Allergy evaluation was recommended, but it was not followed through by the patient. Despite counseling, the patient continued to be non-adherent and had waxing and waning dysphagia. However, he had not experienced food impaction, perforation, heartburn, regurgitation, or chest pain. Growth continued normally.

### 3. Case 2

N.H., a 15-year-old boy with a history of intermittent dysphagia for solids, suffered two episodes of non-bloody, non-bilious emesis in July 2010. Shortly afterward, he developed chest pain and breathlessness. No pain on inspiration was observed, and the patient had trauma, history of illicit drug, or alcohol use. He had no prior esophageal, gastric surgery, and no allergic diseases. On physical examination, his weight was 60 kg (50th percentile) and his height was 160 cm (10th percentile). He was afebrile, his chest and abdominal examination were normal. No crepitations were found in the neck or chest. His WBC count was 9800/ml, hemoglobin level was 12.8 gm/dl, platelets were 292,000/ml, and absolute eosinophil count was 340. His chest X-ray and ECG were normal. An esophagram demonstrated a contained perforation in the mid esophagus anteriorly. No pneumomediastinum was observed. He was treated with intravenous antibiotics and was not administered any oral drugs. The symptoms improved over a week, and a repeat esophagram showed the perforation had sealed with no residual ulceration or narrowing. A soft diet was introduced, which was then changed to a normal diet, and he was started on omeprazole 40 mg BID. To conservatively allow the perforation to heal, the endoscopy was performed three months later, which revealed a stricture in the mid esophagus, 6–7 mm in width and 3 cm in length, between 22 and 25 cm from the incisors, and a diverticulum proximal to the site of perforation. Linear furrows and multiple white spots were observed throughout the esophagus. Balloon dilation of the stricture was performed to 10 mm (Bard). Biopsies showed up to 40 eosinophils/HPF in the distal, mid, and proximal esophagus, with microabscess formation, superficial layering, and desquamation of the eosinophils. Gastric antral and duodenal biopsies were normal. He was treated with topical fluticasone 1760 mcg daily for eight weeks, and the omeprazole was discontinued. Follow up endoscopy two months later showed that the stricture was open, and he had faint furrows and a few white spots. Biopsies of the distal and mid esophagus showed 20 eosinophils/HPF and proximal 5 eosinophils/HPF. He was maintained on fluticasone 220–440 mcg/day. He had intermittent mild dysphagia for solid foods but no regurgitation, heartburn, chest pain, abdominal pain, early satiety, or food impaction. Two subsequent endoscopies over the following 24 months showed mild vertical lines, white spots and no strictures. Eosinophils in the distal esophagus varied from 15 to 50/hpf, 5 to 20/hpf in the mid esophagus, and 4 to 15/hpf in the proximal esophagus. Follow up for up to four years revealed normal growth and intermittent mild dysphagia without food impaction, heart burn, or regurgitation.

### 4. Discussion

Our two patients exemplify an uncommon manifestation of EoE, perforation. For the clinician, this manifestation of EoE is vital to recognize because the complications of esophageal perforation are significant. These complications include mediastinitis, which involves abscess formation, peritonitis, pleural effusion, and/or empyema, as well as

osteomyelitis of the spine with spinal cord compression and sepsis, which could ultimately lead to multiple organ failure and death [3–5].

EoE is a commonly diagnosed disease both in children and adults. Common initial manifestations in children include feeding difficulty, failure to thrive, vomiting, or gastroesophageal reflux (GERD)-like symptoms, abdominal pain, and dysphagia. In adults, dysphagia or GERD-like symptoms predominate [1,2]. A significant complication of EoE is food impaction or esophageal stricture [2]. Both conditions warrant endoscopic management, and perforation is known to occur with endoscopic treatment. However, spontaneous perforation is an uncommon initial manifestation of EoE [6]. This condition was first described by Hermann Boerhaave in 1724 in an autopsy and was thought to be secondary to forceful vomiting, especially in alcoholics [4].

Typical presenting manifestations of esophageal perforation include vomiting, followed by chest pain, and emphysema of the neck, known as Mackler's triad, although this triad is only observed in a minority of patients. Other manifestations are sharp chest pain, which varies in position depending on the site of the perforation, dysphagia, dyspnea or tachypnea, tachycardia, hypotension, and fever. Emphysema of the neck is a late finding that may not be present on the first day; therefore, a high index of suspicion for perforation is needed. Plain radiographs may reveal the V-sign of Naclerio, a linear density corresponding to fascial planes of the mediastinal, and diaphragmatic pleura adjacent to the lower esophagus. Diagnosis is confirmed with a contrast study of the esophagus. Often a CT scan of the chest is required because this method confirms the diagnosis and provides additional details, such as the pleural effusion and size of the perforation, which helps plan the management. Endoscopy generally is contraindicated but may be carefully performed in certain circumstances to localize the site of perforation, placement of NG tube, or to detect the health of the esophagus at the rupture site [4,5].

Once the diagnosis is determined, prompt medical treatment is initiated. Next, the patient is made NPO and administered intravenous fluids with broad-spectrum antibiotic coverage for aerobes and anaerobes. Antifungal treatment should also be started in certain cases, such as patients receiving antimicrobial therapy prior to perforation, patients on long-term antacid therapy, patients who are immunosuppressed or immune-compromised, and patients who fail to improve after prolonged antibacterial therapy. Criteria for conservative management are based on the clinical findings of minimal symptoms, no signs of sepsis, and a well-contained rupture. Cervical perforations have a much better prognosis because they are more likely to be instrument-induced and detected early. Cervical perforations can more often be successfully managed conservatively than thoracic perforations. A patient may need surgery based on the length and location of the perforation and is best performed within 12–24 h of occurrence of the perforation. Criteria that may exclude primary closure include diffuse mediastinal necrosis, a perforation too large for the esophagus to be re-approximated, esophageal malignancy, pre-existing end-stage benign esophageal disease, or if the patient is clinically unstable. Surgical approaches can be cervical, thoracic, or abdominal depending on the site of the rupture [4,5].

The cause of perforation in EoE is not clearly known, but it likely results from inflammation caused by eosinophils infiltrating into the deeper layers, resulting in wall weakness and/or changes in compliance from the increased fibrosis observed in several of these patients. Previous reports included 12 adults and two pediatric patients in EoE with spontaneous esophageal perforation as the initial manifestation. The adults were aged 26–65 years-old (mean 36.5) and included 10 males, and the pediatric patients were 9 and 12 years-of-age who were both males. The perforation sites were mid or distal esophagus, and in several patients, the site was not documented. Diagnosis was confirmed with a CT scan; surgical intervention was performed in seven adults, and the remaining five adults recovered with conservative management [6,7]. The two pediatric patients as well as our two patients recovered with conservative management. Children may potentially recover with conservative management alone. No deaths were recorded. In addition to the initial management, all of these patients, including ours, needed long term treatment for EoE with steroids and/or diet. The outline of the medical management, including diet, is given in Table 1. In patients with strictures, dilation is required [8–11].

pressure of the esophagus with contained air. Additionally, perforation secondary to direct trauma can occur with a penetrating injury, such as gunshot wounds, stabbing, or iatrogenic secondary to foreign body removal; instrumentation, including dilation; or from surgery in the adjacent area, such as in the Fontan or spine surgery [4,5,12,13]. History and evaluation were not supportive of any of these etiologies in our patients.

In conclusion, our Instructive Case emphasizes that patients with eosinophilic esophagitis can present with Boerhaave's syndrome, an uncommon manifestation of a common disorder. Pediatricians should have a high index of suspicion to diagnose esophageal perforation. Once esophageal perforation is diagnosed, EoE should be included as one of the causes of perforation, particularly in a young male patient who has a history of dysphagia and associated allergic diseases. If EoE is left untreated, the condition may result in recurrence of perforation. Because esophageal perforation has increased morbidity and/or mortality, these patients should be aggressively treated either conservatively or with surgery, and the pros and cons of these options should be thoroughly discussed with the family.

**Table 1** Medical treatment of active eosinophilic esophagitis.

Method	Specific recommendation or dosage
Elemental diet therapy	
Elimination diet therapy	
Six-Food elimination	Elimination of milk, wheat, eggs, soy, seafood, and nuts
Four-food elimination	Elimination of milk, wheat, eggs, and soy
Allergy testing-based	Elimination of foods on the basis of radioallergosorbent testing, skin-prick testing, or atopy-patch testing <sup>a</sup>
Omeprazole (proton pump inhibitor) <sup>b</sup>	Children with body weight 10–20 kg: 10 mg twice a day Children with body weight >20 kg: 20 mg twice a day Adults: 40 mg once or twice a day
Glucocorticoids	
Fluticasone	Children: 220–440 µg twice a day Adults: 440–880 µg twice a day
Budesonide	Children: 0.25–0.5 mg twice a day Adults: 1–2 mg twice a day

Furuta G [2].

<sup>a</sup> Approximately 45% of patient have a sustained response to this type of diet therapy.

<sup>b</sup> An equivalent proton-pump inhibitor can be administered.

Spontaneous esophageal perforation apart from violent vomiting is reported with abdominal straining associated with lifting weights or coughing. This condition may also occur with contiguous lesions of the esophagus, such as Barrett's ulceration, esophageal lymphoma, bronchogenic carcinoma, benign leiomyoma, sarcoidosis, and dissecting aortic aneurysm, as reported in adults. External blunt trauma of the thorax or neck injury leading to perforation is also reported secondary to a sudden increase in the

## Financial disclosure

All authors have no financial relationship related to this article to disclose.

## Funding source

None.

## Conflict of interest

All authors indicate they have no potential conflicts of interest to disclose.

## References

- [1] Liacouras CA, Furuta GA, Hirano I, Atkins D, Attwood SE, Bonis PA, et al. Eosinophilic esophagitis: updated consensus recommendations for children and adults. *J Allergy Clin Immunol* 2011;128:1–41.
- [2] Furuta GT, Katzka DA. Eosinophilic esophagitis. *NEJM* 2015; 373:1640–8.
- [3] Salo J, Sihvo E, Kauppi J, Rasanen J. Boerhaave's syndrome; lessons learned from 83 cases over three decades. *Scand J Surg* 2013;102:271–3.
- [4] Lindenmann J, Matzi V, Neuboeck N, Anegg U, Maier A, Smolle J, et al. Management of esophageal perforation in 120 consecutive patients: clinical impact of a structured treatment algorithm. *J Gastrointest Surg* 2013;17:1036–43.
- [5] Abel AG, Brown WA, Smith A, Nottle P. Spontaneous esophageal perforation leading to vertebral osteomyelitis and spinal cord compression. *Dis Esophagus* 2013;26:334–5.
- [6] Lucendo AJ, Frigal-Ruiz AB, Rodriguez B. Boerhaave's syndrome as a primary manifestation of adult eosinophilic esophagitis. Two case reports and a review of the literature. *Dis Esophagus* 2011;24:E11–5.
- [7] Sgrò A, Betalli P, Battaglia G, Bardini R, Crivellaro MA, Svaluto G, et al. An unusual complication of eosinophilic esophagitis in an adolescent: intramural esophageal dissection. *Endoscopy* 2012;44:E419–20.
- [8] Markowitz JE, Spergel JM, Ruchelli E, Liacouras CA. Elemental diet is an effective treatment for eosinophilic esophagitis in children and adolescents. *Am J Gastroenterol* 2003;98: 777–82.
- [9] Liacouras CA, Spergel JM, Ruchelli E, Verma R, Mascarenhas M, Semeao E, et al. Eosinophil esophagitis: a 10 year experience in 381 children. *Clin Gastroenterol Hepatol* 2005;3. 1198–120.6.
- [10] Schaefer ET, Fitzgerald JF, Molleston JP, Croffie JM, Pfeifferkorn MD, Corkins MR, et al. Comparison of oral prednisone and topical fluticasone in the treatment of eosinophilic esophagitis: a randomized trial in children. *Clin Gastroenterol Hepatol* 2008;6:165–73.
- [11] Straumann A, Spichtin HP, Grize L, Bucher KA, Beglinger C, Simon HU. Natural history of primary eosinophilic esophagitis: a follow-up of thirty patients for up to 11.5 years. *Gastroenterology* 2003;125:1660–9.
- [12] Kumar G, Provenzano S, Alphonso N, Karl TR. Esophageal perforation associated with fontan operation. A complication of transesophageal echocardiography. *World J Pediatr Congenit Heart Surg* 2013;4:293–5.
- [13] Rustagi T, Majumder S. Dysphagia and spontaneous esophageal perforation in sarcoidosis. *Dig Dis Sci* 2013;58:282–5.